



Mycobacterial skin infection

Giulia Gardini^{a,*}, Natalia Gregori^{a,*}, Alberto Matteelli^{a,b},
and Francesco Castelli^{a,c,d}

Purpose of review

The aim of this article is to review the most recent evidences concerning mycobacterial skin infections, limiting the period of literature research to 2020–2021.

Recent findings

Mycobacterial skin infections include a heterogeneous group of cutaneous diseases. Cutaneous tuberculosis is usually the result of hematogenous dissemination or spread from underlying foci and it must be distinguished from tuberculids, resulting from the immunological reaction to *Mycobacterium tuberculosis* antigens. Leprosy prevalence was drastically reduced after introduction of multidrug therapy in the 1980s, but cases are still reported due to underdiagnosis, and animal and environmental reservoirs. Recent advances concentrate in the diagnostic field. Specific guidelines for the treatment of nontuberculous mycobacteria skin infections are missing and surgical procedures may be required. Prognosis is better as compared to nontuberculous mycobacteria lung disease. Rapid laboratory-confirmed diagnosis of Buruli ulcer may be achieved by the IS2404 PCR. Among new drugs, telacebec is promising in terms of potency, shorter duration and tolerability in animal studies. A clinical trial in humans is planned.

Summary

Mycobacterial cutaneous lesions are nonpathognomonic and clinical suspicion must be confirmed by culture or molecular detection. Long-course multidrug treatment is required based on susceptibility tests. Surgical intervention may also be required. Rehabilitation and psychosocial support reduce long-term physical and mental consequences mostly in Buruli ulcer and leprosy.

Keywords

Buruli ulcer, leprosy, nontuberculous mycobacteria, tuberculosis

INTRODUCTION

The *Mycobacterium* genus, the only entity within the *Mycobacteriaceae* family (order *Actinomycetales*, phylum *Actinobacteria*), consists of a distinct group of aerobic, nonmotile, nonspore-forming, Gram-positive bacilli. They are characterized by the slow rate of growth and the high content of mycolic acids within the cell wall, which makes them resistant to alcohol and acid rinsing.

Skin and soft tissue infection (SSTI) by *Mycobacterium tuberculosis* complex is rare but remains a potential threat in developing regions. Cutaneous tuberculosis (CTB) must be differentiated from tuberculids, based on the demonstration, in the former, of vital mycobacterial bacilli in biopsies. Among 10 million TB cases estimated globally by WHO in 2019 [1], extra-pulmonary localization accounted for 16% and CTB for less than 2% of all extra-pulmonary cases [1,2].

In 2001, leprosy was declared eliminated as a public health problem globally (prevalence rate < 1/10 000 population) [3]. However, it still remains endemic in some areas of the world (Fig. 1). Stigmatization and

discrimination against affected people continue to represent a barrier for leprosy elimination.

Nontuberculous Mycobacteria (NTM) are ubiquitous microorganisms, divided into hundreds of

^aUniversity Department of Infectious and Tropical Diseases, University of Brescia and ASST Spedali Civili, Brescia, Italy, ^bWHO Collaborating Centre on TB/HIV collaborative activities and for the TB Elimination Strategy, University of Brescia, Brescia, Italy, ^cUNESCO Chair Training and Empowering Human Resources for Health Development in Resource-Limited Countries, University of Brescia, Brescia, Italy and ^dESCMID Study Group for Infections in Travelers and Migrants (ESGITM), Basel, Switzerland

Correspondence to Francesco Castelli, MD, FRCP (Lond.), FFCM RCPS (Glasgow), FRCP (Edinburgh), University Department of Infectious and Tropical Diseases, University of Brescia and ASST Spedali Civili, Piazza Spedali Civili, 1 - 25123 Brescia, Italy.
Tel: +39 030 3995664; e-mail: francesco.castelli@unibs.it

*Giulia Gardini and Natalia Gregori contributed equally to the article.

Curr Opin Infect Dis 2022, 35:79–87

DOI:10.1097/QCO.0000000000000820

This is an open access article distributed under the Creative Commons Attribution License 4.0 (CCBY), which permits unrestricted use, distribution, and reproduction in any medium, provided the original work is properly cited.

KEY POINTS

- Mycobacterial cutaneous lesions are nonpathognomonic.
- Clinical suspicion must be confirmed by culture or molecular tests.
- Long-course multidrug treatment is required based on susceptibility tests.
- Rehabilitation and psycho-social support reduce long-term physical and mental consequences mostly in Buruli ulcer and leprosy.

species, with variable relationship with humans. Differently from *M. tuberculosis*, they may simply colonize humans. Skin infections are associated typically to *M. marinum* and few other species. NTM are clearly neglected: the 2007 ATS/IDSA guidelines [4] dedicated only a short paragraph to skin involvement, describing causative species and how to prevent healthcare associated disease. The ATS/ERS/ESCMID/IDSA Clinical Practice Guideline of 2020 [5] updates treatment recommendations only of pulmonary NTM (pNTM).

Buruli ulcer is a cutaneous and subcutaneous often disfiguring disease caused by *M. ulcerans*. WHO first declared Buruli ulcer a neglected emerging tropical disease in 1998 and launched a Global Buruli Ulcer Initiative [6].

Differently from other NTM, this disease has gained global attention possibly due to a higher

incidence within endemic areas and in infant populations, and the psychosocial impact due to functional impairment and stigma.

Among clinical diseases due to mycobacteria, SSTIs continue to be poorly investigated despite their impact on persons' quality of life and the evidence of increasing incidence in recent years [7,8].

We have performed a nonsystematic revision of the literature, limited to the period from January 2020 to August 2021, searching for epidemiological, clinical, diagnostic and treatment publications on cutaneous manifestations in tuberculosis, leprosy, Buruli ulcer and NTM infections.

MYCOBACTERIAL SKIN INFECTIONS

Cutaneous tuberculosis

M. tuberculosis, *M. bovis* and, less commonly, the bacillus of Calmette-Guerin (BCG) (an attenuated strain of *M. bovis*) are the etiologic agents of CTB.

Development of CTB depends on load and pathogenicity of the infecting strain, the route of infection, the patient's prior sensitization to tuberculosis and state of the patient's cell-mediated immunity [9]. Head and neck are the most involved sites (about 90% of CTB patients) with predilection of nose and cheek. Ear involvement is very rare with only a few case reports in the literature [10].

The skin can be affected by *M. tuberculosis* through inoculation from an exogenous source,

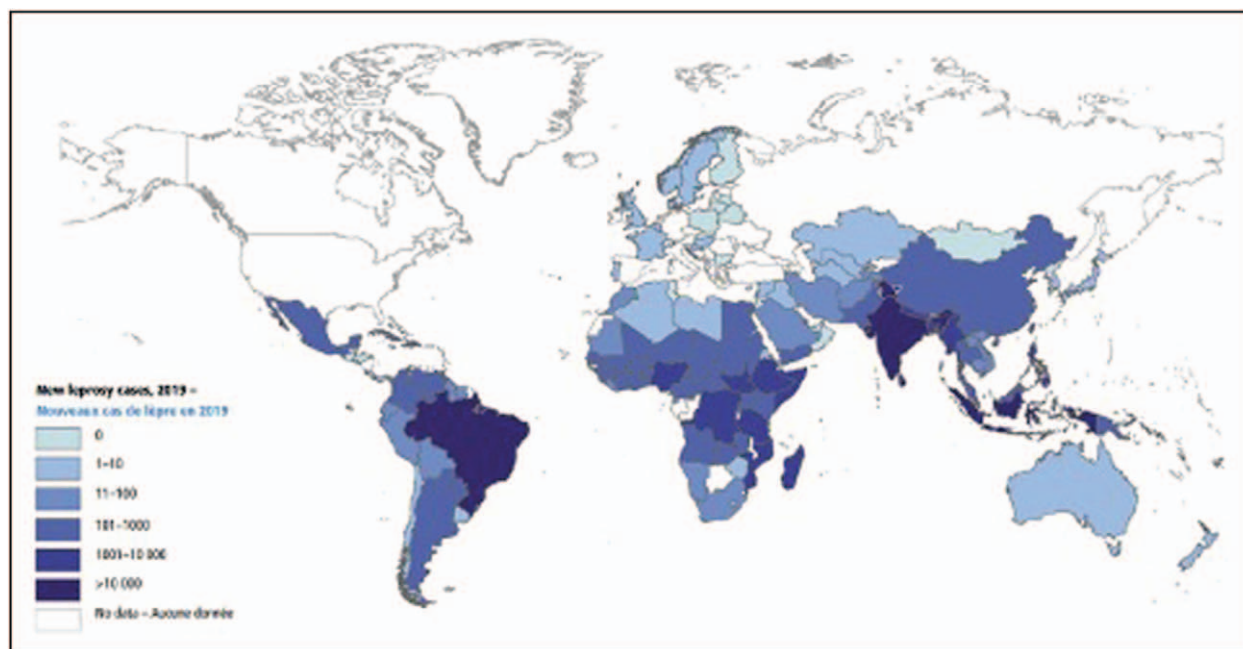


FIGURE 1. New leprosy cases in 2019 (Source: WHO, Weekly Epidemiological Record No 36, 2020, 95, 417–440).

spread from a contiguous source and haematogenic dissemination [9,11].

'TB chancre' identifies the form that results from the entry of mycobacteria through skin or mucosa lesions. It has been largely correlated to occupational exposure in healthcare settings due to injuries with poorly sterilized equipment, but it is also associated with highly risky procedures as tattooing, circumcision, piercing and acupuncture [12].

TB verrucosa cutis is the consequence of re-exposure to mycobacteria in individuals with preexisting immunity to *M. tuberculosis*. It is observed more commonly in children and young adults because of their efficient lymphatic drainage, and their greater risk for traumatic injuries [13]. This rare entity might be confused with diseases such as leishmaniasis, sporotrichosis, nocardiosis, atypical mycobacteria (*M. marinum*), pyogenic infections (*Staphylococcus aureus*, *Streptococcus spp*) and deep fungal infections [14[¶]].

CTB from an endogenous source, also known as 'scrofuloderma', originates from a contiguous tuberculosis focus (e.g. lymphadenitis, osteomyelitis, epididymitis), which spreads to the overlying skin leading to local tissue destruction (Figs. 2 and 3). Neck, axillae, groin and chest are the most commonly involved sites [15]. Orificial TB (or *TB cutis orificialis*) is a rare postprimary CTB caused by auto-inoculation of mycobacteria in middle-aged to elderly patients with advanced forms of lung, intestinal or genitourinary TB [16]. Lesions appear more frequently in oral mucosa, but the perianal area can also be affected [16]. Differential diagnoses of perianal ulcers include inflammatory processes (e.g. Crohn's disease), neoplasms, sarcoidosis and sexually transmitted diseases [16].

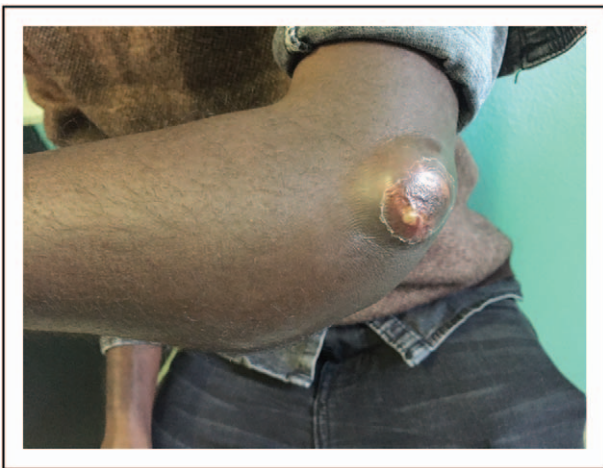

FIGURE 2. Bone and cutaneous tuberculosis in Ethiopian migrant.

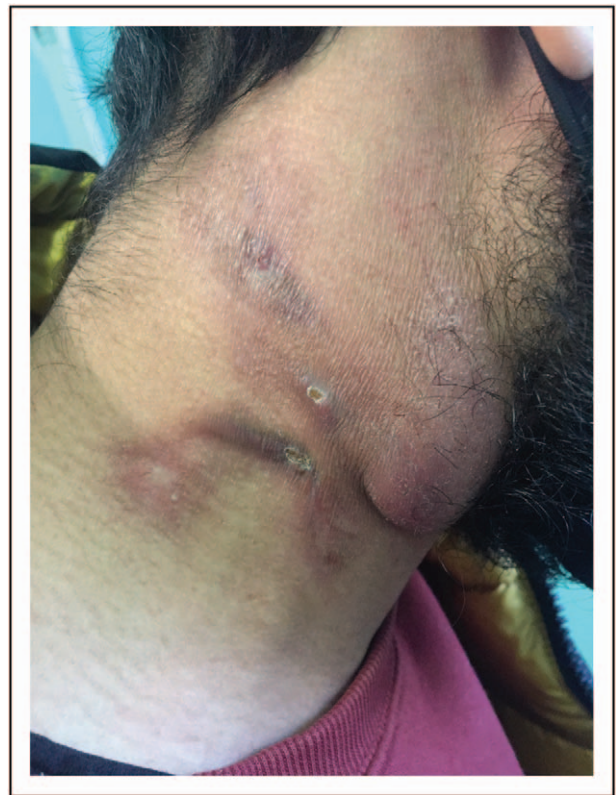

FIGURE 3. Lymph nodal and cutaneous tuberculosis in a man from Morocco.

Haematogenous or lymphatic dissemination accounts for the majority of cutaneous cases of TB. Among them, *lupus vulgaris* is a chronic, progressive, postprimary form of CTB, following a regional lymphatic or blood stream spread in individuals with moderate or high level of TB immunity [17[¶]]. Various clinical forms are observed: papular, nodular, with plaques, vegetative, ulcerative, mutilating, hypertrophic, atrophic, tumour-like type [17[¶]]. The buttocks and the extremities are usually involved in tropical and subtropical settings, face and neck in the West [17[¶]]. Ramesh *et al.* [10] recently described an Indian case series of *lupus vulgaris* affecting the pinna [10]. Family history of *lupus vulgaris* has been described in high endemic areas [17[¶]]. Main differential diagnosis include leprosy, sarcoidosis, discoid lupus, leishmaniasis [17[¶]]. Acute miliary skin TB and gummatous TB are more commonly seen in patients with immunosuppressive disorders (i.e. AIDS, users of tumour necrosis factor alpha antagonists) [18].

Tuberculids are a form of hypersensitivity reaction to mycobacterial antigens in cutaneous blood vessels in patients with high immunity to *M. tuberculosis*. Their clinical appearance is heterogeneous: papulonecrotic lesions, *lichen scrofulosorum*, reported as the most common tuberculid lesion in children [19[¶]], and *erythema induratum* of Bazin

(EIB), the latter is the most frequent form of tuberculoid, commonly seen on the posterior part of the legs [20[•]].

Also, *BCG vaccination or immunotherapy* has been related to local cutaneous complications including localized abscess, scrofuloderma, *lupus vulgaris* and nonhealing ulcers.

Disseminated cutaneous tuberculosis is rarely reported both in immunosuppressed and immunocompetent children receiving the vaccine at birth [21].

As CTB is rare and with no typical manifestations, the diagnosis is challenging and easily mistaken with other skin diseases [2]. Histopathology is not specific, as it shows granulomatous lesions both in true infections and in immunological reactions. The sensitivity of Ziehl-Nielsen AFB stain is low in CTB [2,22]. Thus, culture and amplification of *M. tuberculosis* DNA by PCR in skin biopsies are the gold standard for diagnosis [11]. *M. tuberculosis* cannot be found in smear nor cultured from tuberculoid lesions, although mycobacterial DNA may occasionally be detected by PCR [2,19[•]].

In case of high index of suspicion but lack of microbiological confirmation, empirical tuberculosis treatment is warranted [10].

Cutaneous TB is treated using the WHO standard regimen: 2 months of rifampicin, isoniazid, pyrazinamide and ethambutol followed by 4 months of rifampicin and isoniazid [23]. Recently, in-vivo pharmacokinetic studies have shown promising results from transdermal delivery of rifampicin as strategy for the treatment of systemic and cutaneous tuberculosis [24^{••}]. TB treatment is not recommended for tuberculoid lesions. A retrospective study of 22 patients with EIB found that the rate of recovery was 75% in patients receiving TB treatment and 87.5% in patients without TB treatment [20[•]].

In addition to chemotherapy, surgical intervention may be required [9,25].

Leprosy (or Hansen's disease)

Leprosy, or Hansen's disease, is a chronic mycobacterial infection caused by *M. leprae* or the recently discovered *M. lepromatosis*.

The upper respiratory tract (in particular the nose) and skin lesions are considered the main source of transmission and acquisition of *M. leprae* [26]. Solid evidence exists on the increased risk of infection in household contacts of leprosy patients [27,28^{••}]. Mother-to-child transmission has also been described [27]. TNF alpha inhibitors (infliximab, etanercept, adalimumab) have been proposed as facilitators of leprosy reactivation [29].

Although the incidence of leprosy has declined by 95% since the introduction of multidrug therapy (MDT) in the 1980s, it has plateaued in the last decade [30,31^{••}]. The current stagnation in leprosy incidence has been attributed both to the large number of undetected cases, who contribute to furthering human to human transmission, and to the role of animal and environmental reservoirs [28^{••},31^{••},32]. Armadillo species and red squirrels were found to be wildlife reservoirs of *M. leprae* [31^{••},33]. Viable *M. leprae* has also been detected from environmental sources (water and soil) in Indonesia, India, Brazil and Bangladesh [34]. Recent studies have shown a potential role of vectors like kissing bugs and free-living amoebas [28^{••}].

The clinical presentation is determined by the microorganism's tropism for skin and peripheral nerves (preferentially Schwann cells) and its variability by the genetic background and the immune response of the host [27,33,35[•]]. Murine models have shown that the Th1 cascade, with IL-2 and IFN-gamma production, may be responsible for tuberculoid lesions (Fig. 4). On the contrary, Th2 cytokine cascade (IL-4 and IL-5) is responsible for lepromatous lesions (Fig. 5) [35[•]].

Pure neuritic leprosy without skin lesions is common in Nepal, Brazil and India (4–18% of Indian leprosy cases). In such cases, mononeuritis is the most common presentation [36], especially in older patients, suggesting the effectiveness of national control measures against child leprosy [31^{••}].

Suspicion of the disease may be triggered, in an endemic context, by the onset of sensory impairment, paraesthesia, motor involvement, nerve enlargement. The diagnosis is based on skin and nerve biopsies for histopathology and PCR, or by slit skin smears for AFB detection through Ziehl-

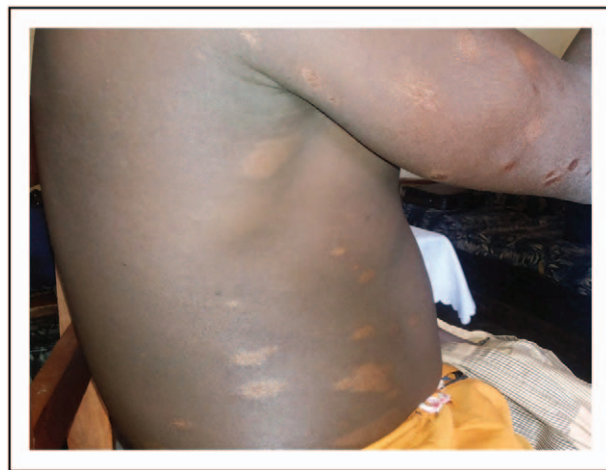

FIGURE 4. Tuberculoid leprosy lesions on the trunk (Courtesy of Damien Foundation Burundi).

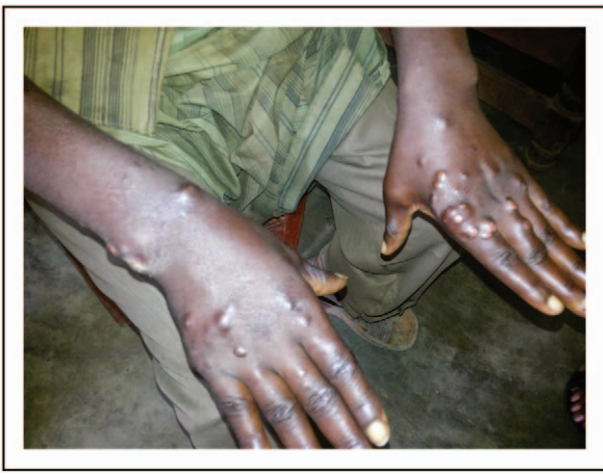

FIGURE 5. Lepromatous leprosy lesions on the hands (Courtesy of Damien Foundation Burundi).

Neelsen staining [27,36]. Calculating the bacillary index on a biopsy allows to establish whether the disease is multi or paucibacillary and determines the treatment.

Rapid diagnostic tests based on the detection of an IgM antibodies response against *M. leprae* specific antigens have shown utility in detecting multibacillary patients but limited sensitivity in paucibacillary ones. The most studied serological platforms are those directed to phenolic glycolipid I (PGL-I) and NDO-LID antigens [27,36–38]. Intradermal skin testing, based on delayed type hypersensitivity (DTH) reaction to various antigen preparations, may reach the sensitivity required for a *M. leprae* screening/surveillance tool. New *M. leprae* skin tests based on candidate antigens are under investigation. The submerged proportion of individuals with latent disease is a main target for serological diagnosis. Combination of two biomarkers of leprosy as serology (positive anti PGL-I via ELISA essay) and *M. leprae* DNA detection (positive PCR from earlobe skin smears) is a promising approach in detecting people with latent leprosy [30]. Moreover, elaboration of host immune profiling of household contacts through molecular methods may help in identifying biomarkers associated with *M. leprae* exposure or asymptomatic infection [39].

Multidrug therapy is the cornerstone of leprosy treatment, consisting in the WHO recommended three-drug regimen (rifampicin as well as clofazimine and dapsone) for 6 months in paucibacillary forms and for 12 months in multibacillary forms [40]. As MDT is not able to reverse nerve damage, a timely treatment of leprosy reactions with corticosteroids is recommended to control acute inflammation. However, the exact duration of steroid treatment has not been established.

Although BCG vaccination confers some level of protection [41], no vaccine is currently available that specifically targets *M. leprae*. Exposed individuals may effectively receive chemoprophylaxis with a single dose of rifampicine (SDR) 600 mg per day (adults and children >2 years of age) [42]. A new subunit vaccine containing recombinant polyprotein LEP-F1 (LepVax) started the development programme: a single-centre Phase 1, open-label clinical trial provided encouraging safety and immunogenicity results [43[□]].

Nontuberculous mycobacteria skin infection

Potentially all NTM species can cause skin infections; however, for the slow growing mycobacterium (SGM) *M. marinum*, the skin is the typical site of infection, and the rapidly growing mycobacteria (RGM) *M. fortuitum*, *M. abscessus* and *M. chelonae* may also give cutaneous disease. MAC complex [44] and less pathogenic NTM may also determine SSTIs, as reported for *M. haemophilum* [7,45,46], *M. goodii* [47] and *M. agri* [48].

Skin is the second more common site of NTM infection both in immunocompromised and immunocompetent individuals, following lung disease in adults and lymphadenopathy in children.

NTM are ubiquitous organisms, thanks to their resistance to high temperature, disinfectants and limited need for nutrients and oxygen. Several factors influence the frequency of NTM skin infections in different areas, such as frequency and quality of medical invasive procedures, common activities and habits (e.g. gardening, farming, swimming, fishing). Climatic and environmental conditions may also play a role: paediatric skin infections due to *M. haemophilum* increased in tropical coastal areas in Australia after a major flooding [49].

Skin infection usually follows inoculation through contact of damaged skin with environmental niches such as tap water or through invasive medical procedures. Pavli *et al.* [50[□]] reviewed the studies from 2010 and 2019 reporting medical tourism-related infections, in particular after cosmetic surgery and transplantation, and NTM emerged as a significant cause. Human-to-human transmission has not been postulated in mycobacterial skin infections. Animals may be colonized and infected by NTM [51–54], but animal to human transmission has not been demonstrated, except from *M. marinum* that can be transmitted to humans by contact with aquatic animals.

NTM skin lesions have no pathognomonic characteristics. Clinical manifestation and incubation period are heterogeneous depending on modality of mycobacterial acquisition, bacterial load and

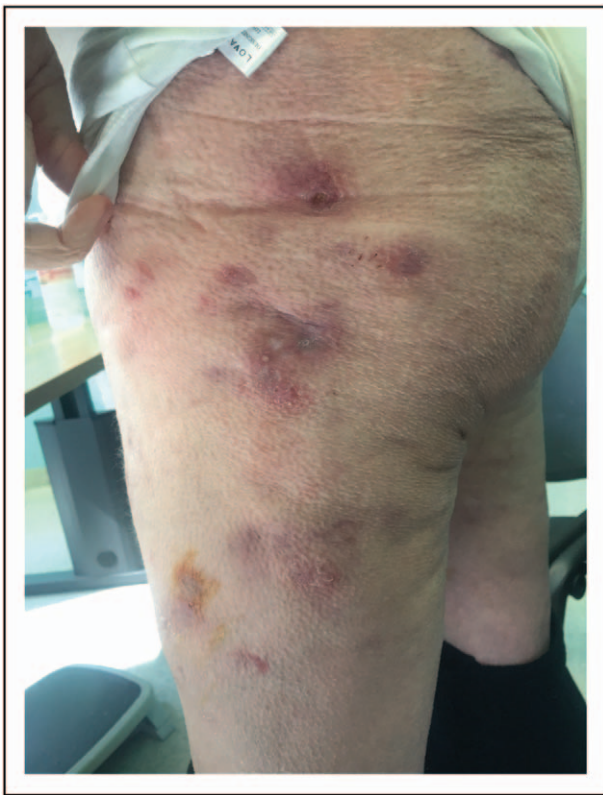

FIGURE 6. Disseminated skin infection by *M. chelonae* in immunocompromised woman.

virulence and host immune status [55]. Immunocompromised individuals are more susceptible to less pathogenic NTM (i.e. *M. haemophilum*) and dissemination (cutaneous and/or subcutaneous and/or systemic) (Fig. 6).

Diagnosis requires culture for mycobacteria. *M. haemophilum*, *M. genavense*, *M. avium* subsp. paratuberculosis and *M. ulcerans* require specific supplements in culture media. In-vitro antimicrobial susceptibility testing is recommended.

Specific guidelines for the treatment of NTM skin infections are missing. Multidrug regimens are recommended, as for pNTM infections (three in-vitro active agents for MAC and *M. abscessus*; two for *M. chelonae*, *M. fortuitum* and *M. marinum*), but duration is generally shorter (6–12 months for MAC and *M. abscessus*; at least 4 months for *M. chelonae* and *M. fortuitum*; 3–4 months or 1–2 months after resolution of symptoms for *M. marinum*) [4]. Chirasuthat *et al.* [7] reported a higher rate of relapse [odds ratio (OR) 65.86; $P=0.02$] in a cohort of 88 patients with cutaneous infections by *M. abscessus* (61.4%), *M. haemophilum* (10.2%) and *M. marinum* (8.1%) if treated with less than three antibiotics. *M. abscessus* remains a challenge for clinicians due to its large spectrum of virulence and resistance mechanisms [56[¶]]. A few case reports

described the use of bedaquiline to treat cutaneous NTM disease [57,58]. The use of omadacycline [59], tedizolid [60[¶]] and linezolid [61] was also reported in single cases.

Additional surgery may be needed for the management of cutaneous NTM [62].

Prognosis for cure is better as compared to pNTM infection. Hannah *et al.* [62] reported complete healing in 83.9% of cases (47 out of 56).

Behavioural precautions to limit environmental NTM exposure are recommended only for solid organ transplant recipients, due to lack of evidence in terms of harms and benefits [63]. The existing guidelines strongly recommend not to use tap water for healthcare and hygiene procedures [4].

Buruli ulcer

Buruli ulcer is caused by *M. ulcerans*, whose ancestor is *M. marinum*. *M. ulcerans* grows at temperature between 28°C and 33°C and its main virulence factor is the plasmid-encoded toxin mycolactone that downregulates host innate and Th1 response and induces tissue damage determining host cell apoptosis [64]. Foulon *et al.* [65] emphasized the pro-inflammatory activity of the toxin in later stages of the infection that leads to destructing lesions.

West Africa and Australia are endemic regions for Buruli ulcer. Sepulcri *et al.* [66] described recently the first case of the disease in a traveller returning from Madagascar. Surveillance of Buruli ulcer cases is a main target for WHO [67].

Global annual incidence of Buruli ulcer varies and in 2020 a reduction of about 1000 notified cases compared to the previous year has been reported [64]. However, this might be associated to the limited active screening campaigns during COVID-19 pandemic. Temperature increase may also negatively affect environmental reservoir (reduced water basins) and mycobacterial survival [68^{¶¶}].

Aquatic environments may represent the natural niches for *M. ulcerans*. Aquatic insects in West Africa, and mosquitoes in Australia have been proposed as vectors in Buruli ulcer, but their role remains unclear [69^{¶¶}]. Australian opossums have been investigated as animal reservoirs, as they are affected by Buruli ulcer and *M. ulcerans* DNA has been detected in their faeces [69^{¶¶}]. A few cases of Buruli ulcer have been described also in other mammals in Australia, but animal-to-human transmission has not been demonstrated yet.

The exact modality of *M. ulcerans* transmission and contributing actors are still objects of research and debate. Contact between wounds and contaminated water may generate skin infection, as suggested by the detection of *M. ulcerans* DNA in

aquatic habitats, the increased Buruli ulcer incidence during wet and rainy seasons, the closeness of water habitats as predictor for Buruli ulcer occurrence in spatial models, and results of prevention case-control studies [69^{***}]. Most environmental studies have used molecular probes; therefore, they cannot inform about viability and transmissibility of the bacteria. Human-to-human transmission has not been demonstrated.

Genome-wide association studies demonstrated the presence of genetic susceptibility factors that may explain familial cluster of Buruli ulcer and heterogeneity of clinical patterns and prognosis [70–72]. Fevereiro *et al.* [73] identified the extreme ages and HIV coinfection as risk factors for Buruli ulcer. HIV-positive status may also determine a more aggressive form of disease and a poorer treatment outcome [64].

The first lesion may appear at the site of inoculation as a nodule, plaque or oedema to evolve afterwards in a disfiguring often painless ulcer with yellowish surface, red based and surrounded oedema [74] (Fig. 7). Limbs are mostly affected. The clinical pattern distinguishes three categories according to increasing severity and involvement of deeper tissues [64]. During treatment, a paradoxical worsening of the lesion may be observed.

Social stigma segregates patients and their family, due to low awareness of transmission modality. Depression and anxiety may affect patients and may persist even after recovery [75,76].

A mobile application may be used in cases with possible disease [74]. Prompt laboratory-confirmed diagnosis is a main goal of WHO 2030 targets [77]. A rapid diagnostic tool is IS2404 PCR. The test is supported by WHO in African endemic regions to limit misdiagnosis and diagnostic delay [64]. Direct

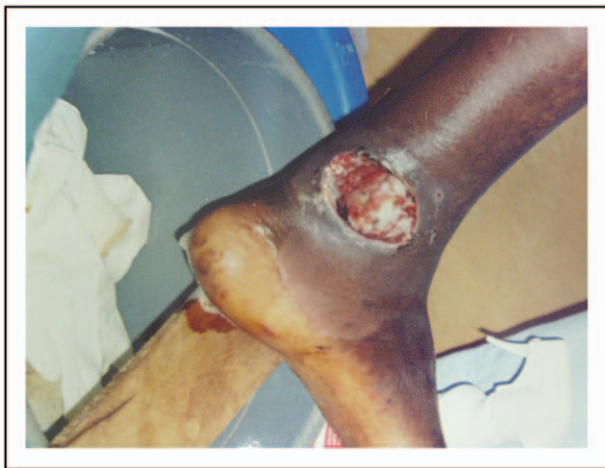

FIGURE 7. Buruli ulcer in a man from Ivory Coast (Courtesy of Dr Antonella Bertolotti).

microscopy, culture and histopathology require more time and laboratory experience.

Recommended treatment is rifampicin 10 mg/kg/day with clarithromycin 7.5 mg/kg twice daily for 8 weeks [64,78]. Moxifloxacin 400 mg/die may substitute clarithromycin and is commonly used in Australia [79]. Combination with streptomycin is also effective, but less tolerated [78,80]. Treatment failure is uncommon; O'Brien *et al.* [79] identified in an Australian cohort weight more than 90 kg ($P < 0.001$), male sex ($P = 0.02$), immune suppression ($P = 0.04$) and rifampicin-clarithromycin regimen instead of rifampicin-fluoroquinolone ($P = 0.05$) as risk factors for failure.

Among new drugs, telacebec is promising in terms of potency, shorter duration (2 weeks) and tolerability in animal studies [64,81–83]. In January 2021, telacebec was recognized as an orphan drug by US Food and Drug Administration. A clinical trial in humans is being planned [64].

Surgical intervention may be required in selected cases, always in conjunction with chemotherapy [78]. Prolonged wound medications, management of lymphoedema and functional rehabilitation are often necessary, as ulcers require months to heal [84].

Educational activities, periodic screening campaigns, diffusion of molecular rapid diagnostic tests and free and integrated treatment are WHO-sustained tools to limit the psycho-social-economic burden of Buruli ulcer in endemic regions [77].

CONCLUSION

Cutaneous mycobacteriosis remain underdiagnosed and undertreated due to economic reasons, low awareness and stigmatization. A reduction in the burden of these diseases requires a comprehensive approach, including community education in endemic areas, increased understanding of animal and environmental reservoirs, diffusion of rapid diagnostic tools, universal accessibility to free multidrug treatments and a multidisciplinary approach.

Acknowledgements

None.

Financial support and sponsorship

None.

Conflicts of interest

There are no conflicts of interest.

Disclaimer

The author is responsible for the views contained in this article and for opinion expressed therein, which are not

necessarily those of UNESCO and do not commit the organization.

REFERENCES AND RECOMMENDED READING

Papers of particular interest, published within the annual period of review, have been highlighted as:

- of special interest
- of outstanding interest

1. WHO. Global tuberculosis report 2020. <https://www.who.int/publications/item/9789240013131>. [Accessed 22 September 2021].
2. Chatterjee D, Saikia UN, Ramesh V. Diagnostic dilemma of cutaneous tuberculosis: opening of the Pandora's box. *Am J Dermatopathol* 2021; 43:871–880.
3. WHO. Weekly Epidemiological record 4 September 2020, 95th Year No 36, 2020, 95, 417–440. <http://www.who.int/wer>. [Accessed 8 September 2021].
4. Griffith DE, Aksamit T, Brown-Elliott BA, et al. An official ATS/IDSA statement: diagnosis, treatment, and prevention of nontuberculous mycobacterial diseases. *Am J Respir Crit Care Med* 2007; 175:367–416.
5. Daley CL, Iaccarino JM, Lange C, et al. Treatment of nontuberculous mycobacterial pulmonary disease: an official ATS/ERS/ESCMID/IDSA clinical practice guideline. *Clin Infect Dis* 2020; 71:e1–e36.
6. WHO. The Yamoussoukro declaration on Buruli ulcer. 1998. <<https://www.who.int/publications/m/item/the-yamoussoukro-declaration-on-buruli-ulcer>>. [Accessed 19 October 2021].
7. Chirasuthat P, Triyankulsri K, Rutnin S, et al. Cutaneous nontuberculous mycobacterial infection in Thailand: a 7-year retrospective review. *Medicine (Baltimore)* 2020; 99:e19355.
8. Ricotta EE, Adjemian J, Blakney RA, et al. Extrapulmonary nontuberculous Mycobacteria infections in hospitalized patients, United States, 2009–2014. *Emerg Infect Dis* 2021; 27:845–852.
9. Chen Q, Chen WC, Hao F. Cutaneous tuberculosis: a great imitator. *Cid* (2019). <https://doi.org/10.1016/j.clinidmatol.2019.01.008>. [Accessed date 8th Sept 2021]
10. Ramesh V, Gupta J. Cutaneous tuberculosis of the pinna. *Int J Dermatol* 2021; 60:363–367.
11. Charifa A, Mangat R, Oakley AM. Cutaneous tuberculosis. 1 September 2020. In: StatPearls [Internet]. Treasure Island, FL: StatPearls Publishing; 2021 Jan–.
12. Soto-Febres F, Ballena-López J, Alva D, et al. Cutaneous inoculation tuberculosis in a healthcare worker: case report and literature review. *IDCases* 2020; 20:e00788.
13. Azendour H, Meziane M, Znati K, et al. A polymorphous cutaneous tuberculosis. *Int J Mycobacteriol* 2021; 10:85–88.
14. Arora K, Dhanta A, Kansal NK, Joshi P. Tuberculous verrucosa cutis with a sporotrichoid distribution. *Int J Mycobacteriol* 2020; 9:220–222. This article reports a rare clinical presentation of TB verrucosa cutis other than the classic single verrucous plaque.
15. Maghwal N, Jain VK, Chouhan C, et al. A clinicopathological pattern of cutaneous tuberculosis and HIV concurrence in western Rajasthan. *Int J Mycobacteriol* 2020; 9:429–434.
16. An Q, Zheng S, Gao XH, Zhang L. Extensive perianal ulcer: a case of tuberculosis cutis orificialis. *Dermatol Ther* 2020; 33:e13698.
17. Arora K, Batra A, Dhanta A, et al. Lupus vulgaris in a mother and child. *BMJ Case Rep* 2021; 14:e240591. This quite unique case report reminds us the possibility of family history of *lupus vulgaris* in high endemic areas.
18. Garcia LC, Vale ECS, Ferrari ML, Faria LDC. Gummatous cutaneous tuberculosis associated with the use of infliximab for Crohn's disease. *An Bras Dermatol* 2021; 96:228–230.
19. Singal A, Kaur I, Pandhi D, et al. Clinico-epidemiological profile of lichen scrofulosorum: a 22-year, single-center, retrospective study. *Int J Dermatol* 2021; 60:1278–1284. This case series of lichen scrofulosorum express the impression that this entity is not so uncommon but requires a high grade of suspicion to be more frequently diagnosed.
20. Kara Polat A, Gore Karaali M, Esra Koku Aksu A, et al. A rare cutaneous tuberculosis form, erythema induratum of Bazin: 6 years' experience. *Acta Dermatovenerol Alp Pannonica Adriat* 2020; 29:123–128. This retrospective study highlights the controversial role of *M. tuberculosis* in the EIB pathogenesis.
21. Dhar S, Ganjoo S, Dhar S, Srinivas SM. Disseminated cutaneous tuberculosis from BCG vaccination site in an immunocompetent child. *Pediatr Dermatol* 2021; 38:294–295.
22. Brown AE, Ibraheim MK, Petersen E, et al. An evolving presentation of cutaneous tuberculosis. *Dermatol Online J* 2020; 26: 13030/qt55d3f43c.

23. WHO. Guidelines for treatment of drug-susceptible tuberculosis and patient care, 2017 Uptodate. <https://apps.who.int/iris/bitstream/handle/10665/255052/9789241550000-eng.pdf>. [Accessed 2 September 2021].
24. Hussain A, Altamimi MA, Alshehri S, et al. Novel approach for transdermal delivery of rifampicin to induce synergistic antimycobacterial effects against cutaneous and systemic tuberculosis using a cationic nanoemulsion gel. *Int J Nanomed* 2020; 15:1073–1094. This article underlines the role of transdermal delivery of rifampicin as an alternative future option for TB treatment.
25. Didace MM, Ida LL, Irène O, Félix PJ. Management of tuberculous cutaneous fistula. *Case Rep Surg* 2020; 2020:7840963.
26. Kundakci N, Erdem C. Leprosy: a great imitator. *Clin Dermatol* 2019; 37:200–212.
27. Mungroo MR, Khan NA, Siddiqui R. Mycobacterium leprae: pathogenesis, diagnosis, and treatment options. *Microb Pathog* 2020; 149:104475.
28. Ploemacher T, Faber WR, Menke H, et al. Reservoirs and transmission routes of leprosy; a systematic review. *PLoS Negl Trop Dis* 2020; 14:e0008276. This systematic review gives an exhaustive overview of most recent findings regarding the role of animal and environmental reservoirs in leprosy transmission other than human-to-human way.
29. Cogen AL, Lebas E, De Barros B, et al. Biologics in leprosy: a systematic review and case report. *Am J Trop Med Hyg* 2020; 102:1131–1136.
30. da Silva MB, Li W, Bouth RC, et al. Latent leprosy infection identified by dual RLEP and anti-PGL-I positivity: implications for new control strategies. *PLoS One* 2021; 16:e0251631.
31. Hambridge T, Nanjan Chandran SL, et al. Mycobacterium leprae transmission characteristics during the declining stages of leprosy incidence: a systematic review. *PLoS Negl Trop Dis* 2021; 15:e0009436. This is the first systematic review investigating the aspects of ongoing *M. leprae* transmission using case data from endemic areas and comparing results to previous control measures.
32. Sarode G, Sarode S, Anand R, et al. Epidemiological aspects of leprosy. *Dis Mon* 2020; 66:100899.
33. Carlock S, Fulton EH, Rosenbaum E, et al. Hansen disease (leprosy) and Armadillo exposure in Arkansas: a case series. *Am J Dermatopathol* 2020; 42:769–773.
34. Singh V, Turankar RP, Goel A. Real-time PCR-based quantitation of viable Mycobacterium leprae strain from clinical samples and environmental sources and its genotype in multicase leprosy families of India. *Eur J Clin Microbiol Infect Dis* 2020; 39:2045–2055.
35. Mi Z, Liu H, Zhang F. Advances in the immunology and genetics of leprosy. *Front Immunol* 2020; 11:567. This article well summarizes advances in the fields of immunology and genetic of leprosy. The combination of immune response and genetic approaches may be important for elucidation of both leprosy pathogenesis and therapeutic interventions.
36. Khadiilkar SV, Patil SB, Shetty VP. Neuropathies of leprosy. *J Neurol Sci* 2021; 420:117288.
37. Duthie MS, Pena MT, Khandhar AP, et al. Development of LepReact, a defined skin test for paucibacillary leprosy and low-level *M. leprae* infection. *Appl Microbiol Biotechnol* 2020; 104:3971–3979.
38. Duthie MS, Reed SG. Skin tests for the detection of Mycobacterial infections: achievements, current perspectives, and implications for other diseases. *Appl Microbiol Biotechnol* 2021; 105:503–508.
39. van Hooij A, van den Eeden S, Richardus R, et al. Application of new host biomarker profiles in quantitative point-of-care tests facilitates leprosy diagnosis in the field. *EBioMedicine* 2019; 47:301–308.
40. Guidelines for the diagnosis, treatment and prevention of leprosy. New Delhi: World Health Organization, Regional Office for South-East Asia; 2017. Licence: CC BY-NC-SA 3.0 IGO.
41. BCG vaccines: WHO position paper – February 2018. *Wkly Epidemiol Rec* 2018; 93:73–96. English, French. PMID: 29474026.
42. Richardus JH, Tiwari A, Barth-Jaeggi T, et al. Leprosy postexposure prophylaxis with single-dose rifampicin (LPEP): an international feasibility programme. *Lancet Glob Health* 2021; 9:e81–e90.
43. Duthie MS, Frevol A, Day T, et al. A phase 1/301 immunogenicity trial to evaluate safety, tolerability, and immunogenicity of the leprosy vaccine candidate LepVax (LEP-F1+GLA-SE) in healthy adults. *Vaccine* 2020; 38:1700–1707. This is the clinical trial of the first defined leprosy vaccine candidate, demonstrating its safety and immunogenicity and supporting its advancement to testing in leprosy-endemic regions.
44. Pampaloni A, Tosto S, Locatelli ME, et al. Skin and soft tissue infection by Mycobacterium intracellulare in an immunocompetent patient. *IDCases* 2020; 19:e00720.
45. Jurairattanaporn N, Vachiramon V, Bruminhent J. Mycobacterium haemophilum skin and soft tissue infection in a kidney transplant recipient: a case report and summary of the literature. *Transpl Infect Dis* 2020; 22:e13315.
46. Chang HY, Tsai WC, Lee TF, Sheng WH. Mycobacterium gordonae infection in immunocompromised and immunocompetent hosts: a series of seven cases and literature review. *J Formos Med Assoc* 2021; 120:524–532.
47. Pamparino S, Valente I, Tagliafico A, et al. A very rare case of mycobacterium gordonae infection of the breast. *Breast J* 2020; 26:2229–2232.

48. Xu C, Wu W, Pan H, *et al.* Mycobacterium agri skin infection in a previously healthy patient: a case study. *Infect Drug Resist* 2021; 14:2965–2968.
49. Aliano D, Thomson R. The epidemiology of extrapulmonary nontuberculous mycobacterial infection in a pediatric population. *Pediatr Infect Dis J* 2020; 39:671–677.
50. Pavli A, Maltezou HC. Infectious complications related to medical tourism. *J Travel Med* 2021; 28:taaa210.
- The manuscript highlights NTM as relevant infectious risk related to medical tourism.
51. Asaava LLA, Githui WA, Mwangi M, *et al.* Isolation, identification and associated risk factors of nontuberculous mycobacteria infection in humans and dromedary camels in Samburu County, Kenya. *Zoonoses Public Health* 2020; 67:713–731.
52. Peterhans S, Landolt P, Friedel U, *et al.* Mycobacterium microti: not just a coincidental pathogen for cats. *Front Vet Sci* 2020; 7:590037.
53. Černá P, Mitchell JL, Lodzinska J, *et al.* Systemic Mycobacterium kansasii infection in two related cats. *Pathogens* 2020; 9:959.
54. Puk K, Guz L. Occurrence of Mycobacterium spp. in ornamental fish. *Ann Agric Environ Med* 2020; 27:535–539.
55. Bezerra GH, Honório MLP, Costa VLDC, *et al.* Mycobacterium marinum infection simulating chromomycosis: a case report. *Rev Inst Med Trop Sao Paulo* 2020; 62:e95.
56. Johansen MD, Herrmann JL, Kremer L. Nontuberculous mycobacteria and the rise of Mycobacterium abscessus. *Nat Rev Microbiol* 2020; 18:392–407. This is a very complete review on virulence and resistance factors of *M. abscessus*.
57. Erber J, Weidlich S, Tschakowsky T, *et al.* Successful bedaquiline-containing antimycobacterial treatment in posttraumatic skin and soft-tissue infection by Mycobacterium fortuitum complex: a case report. *BMC Infect Dis* 2020; 20:365.
58. Meybeck A, Tetart M, Baclet V, *et al.* A disseminated Mycobacterium marinum infection in a renal transplant HIV-infected patient successfully treated with a bedaquiline-containing antimycobacterial treatment: a case report. *Int J Infect Dis* 2021; 107:176–178.
59. Frizzell M, Carr E, Brust K. Omadacycline for treatment of Mycobacterium chelonae skin infection. *Proc (Bayl Univ Med Cent)* 2020; 33:610–611.
60. Shaw TD, Smyth M, Turner G, Hunter M. Prolonged tedizolid use in cutaneous nontuberculous mycobacterial infection. *J Clin Tuberc Other Mycobact Dis* 2021; 24:100261.
- This is a case report on *M. chelonae* skin infection cured with multidrug regimen including tedizolid instead of less tolerated linezolid.
61. McNally MA, Farooq S, Tschlen J, Koshelev MV. Linezolid as a treatment option for cutaneous nontuberculous mycobacterial infections. *Dermatol Online J* 2020; 26: 13030/qt01q4m0p0.
62. Hannah CE, Ford BA, Chung J, *et al.* Characteristics of nontuberculous Mycobacterium infections at a midwestern tertiary hospital: a retrospective study of 365 patients. *Open Forum Infect Dis* 2020; 7:ofaa173.
63. Longworth SA, Daly JS; AST Infectious Diseases Community of Practice. Management of infections due to nontuberculous mycobacteria in solid organ transplant recipients—Guidelines from the American Society of Transplantation Infectious Diseases Community of Practice. *Clin Transplant* 2019; 33:e13588.
64. WHO. Buruli ulcer (Mycobacterium ulcerans infection). 17 May 2021. <[https://www.who.int/news-room/fact-sheets/detail/buruli-ulcer-\(mycobacterium-ulcerans-infection\)](https://www.who.int/news-room/fact-sheets/detail/buruli-ulcer-(mycobacterium-ulcerans-infection))> [Accessed 31 August 2021].
65. Foulon M, Robbe-Saule M, Manry J, *et al.* Mycolactone toxin induces an inflammatory response by targeting the IL-1 β pathway: mechanistic insight into Buruli ulcer pathophysiology. *PLoS Pathog* 2020; 16:e1009107.
66. Sepulcri C, Di Biagio A, Tutino S, *et al.* Buruli ulcer in a traveller returning from Madagascar: the first report of Mycobacterium ulcerans infection from the region. *J Travel Med* 2021; 28:taaa199.
67. WHO. Updated Buruli ulcer recording and reporting forms are now available. 24.08.2020. <https://www.who.int/news/item/24-08-2020-updated-buruli-ulcer-recording-and-reporting-forms-are-now-available>. [Accessed 24 August 2021].
68. Drancourt M, Zingue D. Variations in temperatures and the incidence of Buruli ulcer in Africa. *Travel Med Infect Dis* 2020; 36:101472.
- This study correlates retrospectively temperature changes and Buruli ulcer incidence in Africa from 2002 to 2015.
69. Muleta AJ, Lappan R, Stinear TP, Greening C. Understanding the transmission of Mycobacterium ulcerans: a step towards controlling Buruli ulcer. *PLoS Negl Trop Dis* 2021; 15:e0009678.
- This is a review about the role of humans, animals, aquatic reservoirs and vectors in Buruli ulcer transmission in Australia and West Africa.
70. Manry J. Human genetics of Buruli ulcer. *Hum Genet* 2020; 139:847–853.
71. Manry J, Vincent QB, Johnson C, *et al.* Genome-wide association study of Buruli ulcer in rural Benin highlights role of two LncRNAs and the autophagy pathway. *Commun Biol* 2020; 3:177.
72. Feveiro J, Fraga AG, Capela C, *et al.* Genetic variants in human BCL2L1 (BIM) are associated with ulcerative forms of Buruli ulcer. *Emerg Microbes Infect* 2021; 10:223–225.
73. Feveiro J, Sajjadi N, Fraga AG, *et al.* Individual and clinical variables associated with the risk of Buruli ulcer acquisition: a systematic review and meta-analysis. *PLoS Negl Trop Dis* 2020; 14:e0008161.
74. WHO. Neglected tropical diseases of the skin: WHO launches mobile application to facilitate diagnosis. 16.07.2020. <https://www.who.int/news/item/16-07-2020-neglected-tropical-diseases-of-the-skin-who-launches-mobile-application-to-facilitate-diagnosis>. [Accessed 25 August 2021]
75. Amoako YA, Ackam N, Omuojine JP, *et al.* Caregiver burden in Buruli ulcer disease: evidence from Ghana. *PLoS Negl Trop Dis* 2021; 15:e0009454.
76. Amoako YA, Ackam N, Omuojine JP, *et al.* Mental health and quality of life burden in Buruli ulcer disease patients in Ghana. *Infect Dis Poverty* 2021; 10:109.
77. WHO. Ending the neglect to attain the Sustainable Development Goals: a road map for neglected tropical diseases 2021–2030. November 2020. <https://www.who.int/publications/i/item/9789240010352>. [Accessed 24 August 2021]
78. Phillips RO, Robert J, Abass KM, *et al.* Rifampicin and clarithromycin (extended release) versus rifampicin and streptomycin for limited Buruli ulcer lesions: a randomised, open-label, noninferiority phase 3 trial. *Lancet* 2020; 395:1259–1267.
79. O'Brien DP, Friedman ND, Walton A, *et al.* Risk factors associated with antibiotic treatment failure of Buruli ulcer. *Antimicrob Agents Chemother* 2020; 64:e00722–e820.
80. Collinson S, Frimpong VNB, Agbavor B, *et al.* Barriers to Buruli ulcer treatment completion in the Ashanti and Central Regions, Ghana. *PLoS Negl Trop Dis* 2020; 14:e0008369.
81. Thomas SS, Kalia NP, Ruf MT, *et al.* Toward a single-dose cure for Buruli ulcer. *Antimicrob Agents Chemother* 2020; 64:e00727–e820.
82. de Jager VR, Dawson R, van Niekerk C, *et al.* Telacebec (Q203), a new antituberculosis agent. *N Engl J Med* 2020; 382:1280–1281.
83. Almeida DV, Converse PJ, Omansen TF, *et al.* Telacebec for ultrashort treatment of Buruli ulcer in a mouse model. *Antimicrob Agents Chemother* 2020; 64:e00259–e320.
84. Johnson PDR. Buruli ulcer: cured by 8 weeks of oral antibiotics? *Lancet* 2020; 395:1231–1232.