



Modification of Technique of Temporalis Transfer for Lagophthalmos and Lip Animation

Sridhar Krishnamurthy¹ Indumathi Kathappan²

¹Institute of Aesthetic, Craniofacial and Plastic Surgery, SIMS Hospital, Chennai, Tamil Nadu, India

²Department of Plastic Surgery, Dr Indu's Cosmetic Surgery, Salem, Tamil Nadu, India

Address for correspondence Indumathi Kathappan, MBBS, MS, DNB, Department of Plastic Surgery, Dr Indu's Cosmetic Surgery, Door Number 55/1, Shankar Nagar, Salem 636007, Tamil Nadu, India (e-mail: indumathi0022@yahoo.com).

Indian J Plast Surg 2022;55:396–399.

Abstract

Keywords

- ▶ orthodromic transfer
- ▶ eye closure
- ▶ symmetry of mouth at repose
- ▶ elevation of angle of mouth

The aim of this case report is to describe a modification of the technique of temporalis transfer for patients with paralysis of the facial nerve. Primary fixation of fascia lata strips to the medial canthus, angle of mouth, lips, and ala of nose, and later executing the orthodromic transfer of a relevant segment of the muscle are the modifications to be described. Symmetry of the face, mouth, eye closure, and smooth elevation of angle of mouth were the measured outcomes by the surgeon. Our refinement of the technique is easy to perform with good results.

Introduction

The goal of facial reanimation is to restore symmetry in repose, and on animation as much as possible. Reinnervation techniques are not possible in delayed cases, and where proximal nerve end is not available. Hence, free functioning muscle transfer (FFMT) becomes the ideal option, with a multistage cross-facial innervation. The delay and multistage procedures are not acceptable to many and are also not feasible in Hansen's.

The temporalis transfer has the advantages of providing symmetry at rest and controlled movement of the angle of the mouth, with immediate results, and is especially good for lagophthalmos where delay may cause loss of vision. Lateral tarsorrhaphy is a temporary procedure with suboptimal aesthetic results. Of the static procedures available, lid springs have unacceptable complications. Lid loading with gold weights have a high extrusion rate.

Case Report

Transfer for Lagophthalmos

An incision is made just above the root of the helix curving upward and backward to expose temporalis muscle. Poste-

rior one-inch strip of temporalis muscle that is in alignment with the horizontal axis of the eye is isolated, and the insertion is divided just above the zygomatic arch (▶ Fig. 1). The muscle is dissected upward for an inch. Fascia lata graft of ~5–6 mm breadth and 15 cm length is harvested, split into two except at one end. A 4–0 nylon suture is used to transfix the undivided end. The nylon thread helps to position the two slings of fascia as shown under the exposed canthal ligament (▶ Fig. 2). Fascia is sutured to the medial canthal ligament. The fascial slings are tunneled from medial to lateral under the skin of both eyelids close to the lid margins and brought out through an incision made lateral to the orbit (▶ Fig. 3). The sling is then tunneled to the temporal wound and fixed to the muscle at a tension, removing all slackness and both lids opposing each other (▶ Fig. 4).

Transfers for Face

The ideal vector of pull needed is upward and backward and hence mid portion of temporalis muscle is chosen. Preoperatively, the patient is asked to say E and the horizontal, vertical, and oblique movements needed are assessed (▶ Fig. 5). For the face, a two-finger breadth of

article published online
December 30, 2022

DOI <https://doi.org/10.1055/s-0042-1759501>.
ISSN 0970-0358.

© 2022. Association of Plastic Surgeons of India. All rights reserved. This is an open access article published by Thieme under the terms of the Creative Commons Attribution-NonDerivative-NonCommercial-License, permitting copying and reproduction so long as the original work is given appropriate credit. Contents may not be used for commercial purposes, or adapted, remixed, transformed or built upon. (<https://creativecommons.org/licenses/by-nc-nd/4.0/>)

Thieme Medical and Scientific Publishers Pvt. Ltd., A-12, 2nd Floor, Sector 2, Noida-201301 UP, India

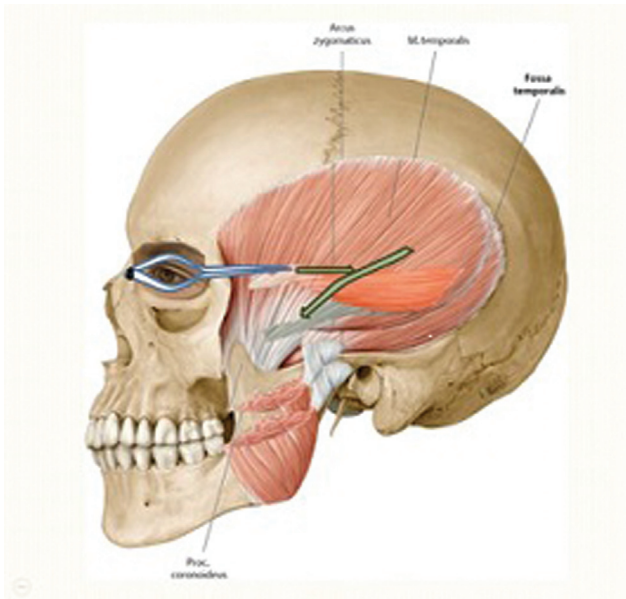


Fig. 1 Posterior strip of muscle disinserted and attached to the medial canthus gives a straight line of pull.

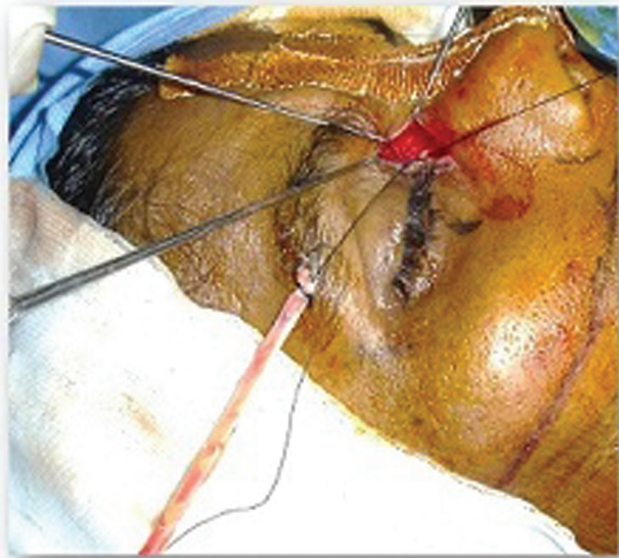

Fig. 2 Suture threads tunneled under medial canthus help pull the fascia lata graft in place.

mid part of temporalis muscle is isolated, divided, and dissected as before. A broad long strip of fascia lata is divided into four strips with one end undivided. An incision is made in nasolabial groove, just outside the angle, over the philtral column, midline of lower lip at labio-mental groove and junction of ala with face. Fascial slings are tunneled from nasolabial area to these sites and broader undivided end tunneled proximally to temporal area. The fascial sling to the lower lip is sutured first across the midline into muscle; then pulling at the undivided end and maintaining same tension, other slings are sutured to angle, and upper lip, using 4-0 nylon and the incisions

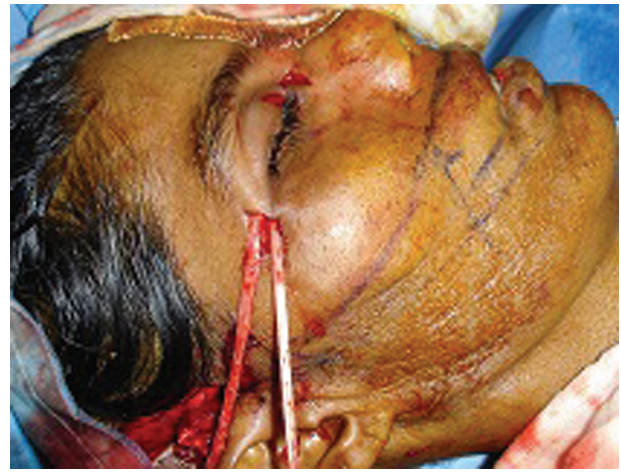

Fig. 3 Distal end of graft transixed to medial canthus. The tails are tunneled under the skin of the eyelids close to the lid margins.

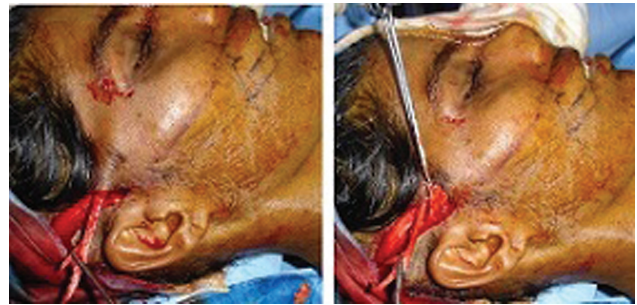

Fig. 4 The fascia lata grafts are fixed in a retrograde fashion to the temporalis tendon with adequate tension just enough to close the eye.

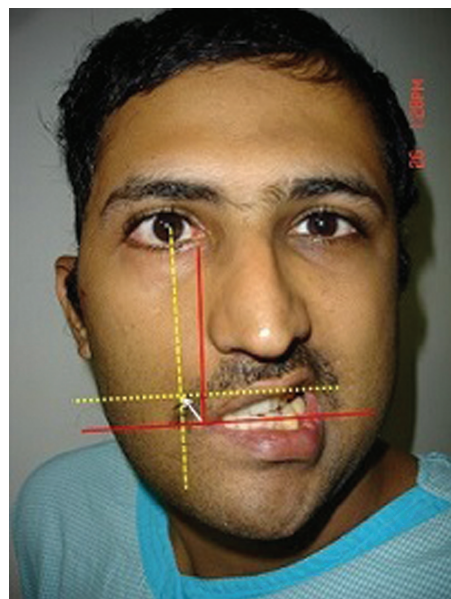


Fig. 5 Preoperatively, the patient is asked to say E and the horizontal, vertical, and oblique movements needed are assessed. The horizontal movement needed will be the difference in distance between the medially displaced angle of the mouth and the mid-pupillary line. The vertical movement needed is the difference in height between the deviated angles of the mouth on the normal side from that on the affected side.

closed. Temporalis tendon is pulled to remove slack from the muscle. A slit is made on the tendon and proximal end of the graft pulled out through it. The undivided proximal fascia strip is pulled upward and outward along the preoperatively measured vector and dimensions. It is now sutured to the temporalis tendon using 3-0 nylon (–Video 1).

A rough estimate of the *muscle excursion* was judged on the table. Performing the procedure under local anesthesia, an intramuscular needle was inserted into the cut end of the chosen strip of muscle. The patient was asked to bite and the movement of the needle was measured, which was found to be around 1 cm. After fixing the slings at the medial canthus and tunneling them to the temporal wound, the amount of pull on the sling needed to bring eyelids together was measured. It was also found to be around 1 cm. This helped in understanding the success of the procedure.

Video 1

Strips of fascia lata are first fixed to the lips and angle of mouth. They are then pulled to preoperatively measured vertical and horizontal dimensions. Temporalis tendon is stretched enough to remove slack and fascia lata strips are sutured at the determined level. Online content including video sequences viewable at: <https://www.thieme-connect.com/products/ejournals/html/10.1055/s-0042-1759501>.

Rehabilitation protocol: For the eye, looking at the mirror patient attempts eye closure, then bites, which causes gentle complete eye closure. He then releases the bite and opens the eye. Over time, with neural adaptation, he can close his affected eye along with the normal one without biting. For the commissure, he first attempts to elevate angle of mouth on the affected site, then bites, which causes elevation of angle of mouth followed by releasing the bite and regaining resting position. Over time, he fine tunes the strength of the bite and is able to elevate the angle by contracting temporalis muscle imperceptibly. Anatomically, the fascia grafts from the eyelids are tunneled at different planes as that to the mid and lower face where the two come close to each other at the temporal area. Over time, with neuro adaptation the two movements get isolated.

This modified transfer performed by the senior author (S. K.) on 15 patients has given comparable results.

Preoperative (–Video 2) and postoperative videos (–Video 3) clearly demonstrate the success of the procedure. Reducing the tension in the upper eyelid sling corrects the narrowing of the aperture that is seen in –Video 3.

Video 2

Preoperative video showing the asymmetry of the angle of the mouth when the patient says E. Lagophthalmos on gentle closing of the eyes, which gets obliterated only on tight closure of the eyes, is demonstrated. Drooping of the paralyzed side angle of the mouth on repose can be observed. Online content including video sequences viewable at: <https://www.thieme-connect.com/products/ejournals/html/10.1055/s-0042-1759501>.

Video 3

Postoperative video of the patient. Temporalis transfer to the right side of the face has been performed. Good symmetry of the face and angle of the mouth at repose are seen. Adequate gentle excursion of the paralyzed side angle of the mouth on attempted smile is demonstrated. Isolated gentle, smooth eye closure has been achieved with practice. Online content including video sequences viewable at: <https://www.thieme-connect.com/products/ejournals/html/10.1055/s-0042-1759501>.

Discussion

Sir Harold Gillies published his technique of temporalis transfer in the *Proceedings of Royal Society of Medicine* around the year 1930.¹ A fascia lata sling is looped as a double loop from the angle of the mouth encircling the upper and lower lips on the paralyzed side, getting a purchase from the nonparalyzed side. Temporalis muscle is turned down. Fascia lata is attached to the turned down raw area of the muscle and attached to previously prepared fascial sling encircling the lips. The tension is adjusted to give a straight mouth and nose at rest and a simulation of expression when the muscle is contracted. Sir Gillies turned down a flap of muscle further forward and split the deep temporal fascia into two slips, tunneled them to meet each other at the medial canthus, and attached them to the periosteum. When the muscle contracts, the eyelids were squeezed close.

Later on, as a modification, the temporal fascia was extended with the attached pericranium and split into many tails.

Several modifications of the procedure are in vogue.² McLaughlin³ in 1952 attached temporalis muscle tendon to the lips with fascial grafts after detaching at the coronoid process. Labbé⁴ in 1997 in addition performed an osteotomy of the zygomatic arch, and repositioned/lengthened the temporalis by detaching the posterior third of the muscle resulting in a “temporalis slide.”

Breidahl et al⁵ divided the zygomatic arch and cut the temporalis tendon just before its insertion.

The advantages of our technique include: (1) easy to fix to canthus as it is in lax position (suturing under tension is difficult, may over- or under-correct, and readjustment will damage the canthal ligament); (2) retrograde tension adjustment can be revised as many times as required; (3) no bulge over the zygomatic area; (4) no hollowness in the temporal fossa; and (5) direction of muscle fiber is in the line of pull.

The limitation of the modification in our experience is that there is a learning curve to get the tension adjustment right. We are yet to publish a case series to substantiate our results. We have not done any comparative study with other techniques for lagophthalmos

Excursion of the angle of the mouth following temporalis tendon transfer and gracilis free muscle transfer have been compared by Oyer et al.⁶ Commissure symmetry during smile improved significantly for the temporalis transfer patients in the vertical and angular dimensions, while the gracilis FFMT group had significant improvement in the vertical and horizontal dimensions. Commissure excursion significantly improved in both groups following surgery, with a larger improvement seen in the gracilis FFMT group.

Ahn et al⁷ suggest steps to correct the resultant ptosis—the fascia sling in the upper lid could be terminated just short of medial canthus to reduce tension and weight. Lid loading to correct lagophthalmos⁸ has resulted with a 25% need for removal due to complications. The advantage is ability to close eyes without conscious effort. The technique was developed in a leprosy center and patients here could not afford gold weights.

Conclusion

Refinements to the technique of temporalis transfer as described by us for correction of lagophthalmos results in smooth eye closure with adequate tendon excursion. Further fine tuning of the technique to minimize the resultant mild ptosis is being explored. Reanimation of nose and lips as addressed by us is simple and easy to perform.

Conflict of Interest

None declared.

References

- 1 Gillies H. Experiences with fascia lata grafts in the operative treatment of facial paralysis. *Proc R Soc Med* 1934;27(10):1372–1382
- 2 Ghali S, MacQuillan A, Grobbelaar AO. Reanimation of the middle and lower face in facial paralysis: review of the literature and personal approach. *J Plast Reconstr Aesthet Surg* 2011;64(04):423–431
- 3 McLaughlin CR. Permanent facial paralysis; the role of surgical support. *Lancet* 1952;2(6736):647–651
- 4 Labbé D [Lengthening of temporalis myoplasty and reanimation of lips. Technical notes]. *Ann Chir Plast Esthet* 1997;42(01):44–47
- 5 Breidahl AF, Morrison WA, Donato RR, Riccio M, Theile DR. A modified surgical technique for temporalis transfer. *Br J Plast Surg* 1996;49(01):46–51
- 6 Oyer SL, Nellis J, Ishii LE, Boahene KD, Byrne PJ. Comparison of objective outcomes in dynamic lower facial reanimation with temporalis tendon and gracilis free muscle transfer. *JAMA Otolaryngol Head Neck Surg* 2018;144(12):1162–1168
- 7 Ahn SY, Park HJ, Kim JP, Park TH. Temporalis muscle transfer for the treatment of lagophthalmos in patients with leprosy: refinement in surgical techniques to prevent postoperative ptosis. *J Craniofac Surg* 2016;27(01):94–96
- 8 Ueda K, Harii K, Yamada A, Asato H. A comparison of temporal muscle transfer and lid loading in the treatment of paralytic lagophthalmos. *Scand J Plast Reconstr Surg Hand Surg* 1995;29(01):45–49