

# Curative effect and prognosis of 3D printing titanium alloy trabecular cup and pad in revision of acetabular defect of hip joint

LEI WAN, GUANGLIANG WU, PENGKE CAO, KUI LI, JUNMING LI and SHAOAN ZHANG

Department of Osteology, The Second Affiliated Hospital of Luohe Medical College, Luohe, Henan 462300, P.R. China

Received December 26, 2018; Accepted April 25, 2019

DOI: 10.3892/etm.2019.7621

**Abstract.** Curative effect and prognosis of 3D printing titanium alloy trabecular cup and pad in revision of acetabular defect of hip joint were investigated. Forty-two patients who underwent acetabular revision in the Second Affiliated Hospital of Luohe Medical College were divided into observation and control groups according to different methods of acetabular revision and revision materials. 3D printed titanium alloy trabecular cups and pads were used in the observation group, and non-3D printed titanium trabecular cups and pads were used in the control group. Preoperative and postoperative pain visual analog scale (VAS score), hip Harris scores and quality of life Health Survey Scale (SF-36) scores were compared between the groups. At 3, 6 and 12 months after operation, Harris score and SF-36 score of the observation group were significantly higher than those of the control group, and VAS score was significantly lower than that of the control group ( $P < 0.05$ ). Stability and bone ingrowth of prosthesis in the observation group were better than those in the control group. Revision of the hip prosthesis with 3D printed titanium trabecular metal cups and pads resulted in satisfactory outcomes. Short-term prognosis is satisfactory but the long-term prognosis remains to be further investigated.

## Introduction

Debris generated by prosthetic wear after artificial total hip arthroplasty and the osteolysis caused by inflammation cause symptoms such as pain, movement disorder and bone defect in the hip joint. At this time, acetabular prosthesis needs to be repaired to improve the therapeutic effect of hip replacement and prolong the service life of the prosthesis (1,2).

At present, there are many repair methods for acetabular prostheses, such as titanium mesh reconstruction, structural

bone graft reconstruction and acetabular plate readdition. There are also many types of materials needed to repair the prosthesis, such as hydroxyapatite, Cage and Bio-type cups, the various prosthetic materials have their own advantages and disadvantages, but the common purpose is to repair and reconstruct the appropriate acetabulum to achieve good stability of the cup prosthesis (3,4). In recent years, 3D printing technology has developed rapidly and a variety of 3D technologies have been applied in the medical field (5). 3D printed titanium alloy is widely used in the repair and re-treatment of various types of bone and joint injuries. Compared with traditional bone and joint defects repair materials, 3D printed titanium alloy has the advantages of strong forming ability and short processing cycle, and is tailor-made according to the patient.

In this study, 3D printed titanium alloy trabecular cup and titanium alloy block were used to repair the acetabular defect after hip replacement. The curative effect and prognosis were satisfactory.

## Patients and methods

**Research subjects.** Forty-two patients who underwent acetabular repair in the Second Affiliated Hospital of Luohe Medical College (Luohe, China) from July 2014 to June 2017 were enrolled in observation and control groups according to acetabular revision methods and materials. There were 22 patients in the observation group, including 12 males and 10 females, aged 22-58 years, with a mean age of  $35.8 \pm 6.7$  years. There were 20 patients in the control group, including 11 males and 9 females, aged 23-57 years, with a mean age of  $34.9 \pm 5.9$  years.

This study was approved by Ethics Committee of the Second Affiliated Hospital of Luohe Medical College. Patients who participated in this study, signed the informed consent and had complete clinical data.

**Inclusion and exclusion criteria.** Inclusion criteria were: i) patients who had undergone total hip arthroplasty with only one side; ii) volumetric or structural bone defects, pain and mobility disorders in acetabular weight-bearing area, anterior-posterior column and inner wall; iii) image examination showed that the displacement of the cup in the vertical and horizontal directions exceeded 2.0 mm; iv) rotation of the cup exceeded  $5.0^\circ$ ; and v) acetabulum was rotated and the screw

---

*Correspondence to:* Dr Shaoan Zhang, Department of Osteology, The Second Affiliated Hospital of Luohe Medical College, 463 Haihe Road, Yancheng, Luohe, Henan 462300, P.R. China  
E-mail: sep2sw@163.com

**Key words:** 3D printing, titanium alloy, hip replacement, revision

Table I. Comparison of preoperative and postoperative patient hip function Harris scores between the two groups.

Groups	Cases	Before treatment	3 months after treatment	6 months after treatment	12 months after treatment
Control group	20	44.53±8.83	53.52±9.11	67.62±8.20	72.15±8.30
Observation group	22	45.11±8.93 <sup>a</sup>	68.35±9.57 <sup>a</sup>	82.52±9.01 <sup>a</sup>	88.57±9.25 <sup>a</sup>

<sup>a</sup>Compared with control group, P<0.05.

was broken. Exclusion criteria were: i) trauma caused by peri-prosthetic fracture; ii) first total hip arthroplasty; iii) infection around the prosthesis; and iv) patients or family members did not agree to participate in the study.

**Renovation method.** The patients were placed in lateral position. General anesthesia was performed. Through posterior lateral approach, incision of the sac, exposing the hip prosthesis, fully revealing the acetabular rim, removing the prosthesis, removing scars, bone cement and conjunctiva around the acetabulum were performed. Bone was polished and the defect area of the acetabulum and the extent of bone defect were evaluated. After treatment and evaluation, patients in control group were equipped with non-3D printed titanium alloy revision artificial hip joint for revision in the acetabular defect. Patients in the observation group were fitted with 3D printed pad at the acetabular defect to restore acetabular edge of defect. A small amount of allogeneic or autologous bone was placed to fill the bone defect cavity and reconstruct the acetabulum. After that, installation of 3D printed titanium trabecular cup was performed. If the femoral head prosthesis was severely rubbed, femoral head prosthesis was replaced intraoperatively. After the revision of the prosthesis, saline was used to wash the cavity and wound was sutured. Postoperative routine anti-infective treatment and other basic treatments were performed. Patients were asked to wear anti-spinning shoes to prevent hemorrhoids and ankle joint contraction movement was performed within 6 weeks after surgery. After 6 weeks, weight-bearing exercise was started according to the bone growth of the interface.

**Follow-up and efficacy evaluation.** Patients were followed up at 3, 6 and 12 months after surgery. Radiographic assessment and scale assessment were performed during follow-up. Visual analog scale (VAS score) was used to evaluate the preoperative and postoperative pain level (6). Harris score was used to evaluate the preoperative and postoperative hip function (7). Quality of life before and after surgery was assessed using the Health Survey Scale (SF-36) (8). Assessment of acetabular prosthesis position was performed using the DeLee and Charnley zoning method (9): acetabular component is unstable: a displacement of the cup or an outer acetabulum, and a translucent line of at least 1.0 mm in the lower rim of the acetabulum were considered as unstable acetabular component. Loose acetabular prosthesis: acetabular abduction angle varies by >10°, or a displacement of >6.0 mm occurs vertically or horizontally. Evaluation of the ingrowth of the prosthesis was performed using the bone growth evaluation

criteria of the Anderson Orthopaedic Institute (10): i) the bright line disappeared; ii) the outer upper part of the acetabulum and the inner lower acetabular bone edge were enhanced; iii) stress shielding on the inner wall of the acetabulum; and iv) radial trabecular bones are arranged perpendicular to the acetabular outer upper part and the inner wall of the acetabulum and the acetabular surface.

**Statistical analysis.** Statistical analysis was performed on the data in this study using SPSS 19.0 statistical software (SPSS, Inc., Chicago, IL, USA). Measurement data were expressed as mean ± standard deviation. Difference of measurement data between groups were statistically analyzed by t-test. P<0.05 was considered to indicate a statistically significant difference.

## Results

**Comparison of preoperative and postoperative patient hip function Harris scores between two groups.** Hip function Harris scores were compared between the groups before and 3, 6 and 12 months after surgery. There was no significant difference in Harris score between the two groups before operation (P>0.05). At 3, 6 and 12 months after operation, Harris scores of the observation group were significantly higher than those of the control group (P<0.05; Table I and Fig. 1).

**Comparison of preoperative and postoperative pain VAS scores between the groups.** Pain VAS scores of the two groups were compared before and 3, 6 and 12 months after surgery. There was no significant difference in pain VAS score between the groups before operation (P>0.05). Pain VAS scores of the observation group were significantly lower than those of the control group at 3, 6 and 12 months after operation (P<0.05; Table II).

**Comparison of preoperative and postoperative quality of life SF-36 scores between the groups.** Quality of life SF-36 scores were compared between the groups before and 3, 6 and 12 months after surgery. There was no significant difference in the quality of life SF-36 scores between the two groups before treatment (P>0.05). The quality of life SF-36 scores of the observation group were significantly higher than those of the control group at 3, 6 and 12 months after treatment (P<0.05; Table III).

**Comparison of postoperative acetabular component position and bone ingrowth between the groups of patients.** There

Table II. Comparison of preoperative and postoperative pain VAS scores between the two groups (points).

Groups	Cases	Before treatment	3 months after treatment	6 months after treatment	12 months after treatment
Control group	20	5.88±1.12	3.89±0.87	2.66±0.54	2.34±0.49
Observation group	22	5.79±1.14 <sup>a</sup>	2.79±0.69 <sup>a</sup>	1.04±0.48 <sup>a</sup>	0.85±0.36 <sup>a</sup>

<sup>a</sup>Compared with control group, P<0.05. VAS, visual analog scale.

Table III. Comparison of preoperative and postoperative quality of life SF-36 scores between the two groups (points).

Groups	Cases	Before treatment	3 months after treatment	6 months after treatment	12 months after treatment
Control group	20	330.13±90.34	501.25±86.36	620.41±90.44	650.62±90.11
Observation group	22	334.57±91.31 <sup>a</sup>	589.32±83.16 <sup>a</sup>	735.67±92.46 <sup>a</sup>	752.41±90.56 <sup>a</sup>

<sup>a</sup>Compared with control group, P<0.05. SF-36, Health Survey Scale.

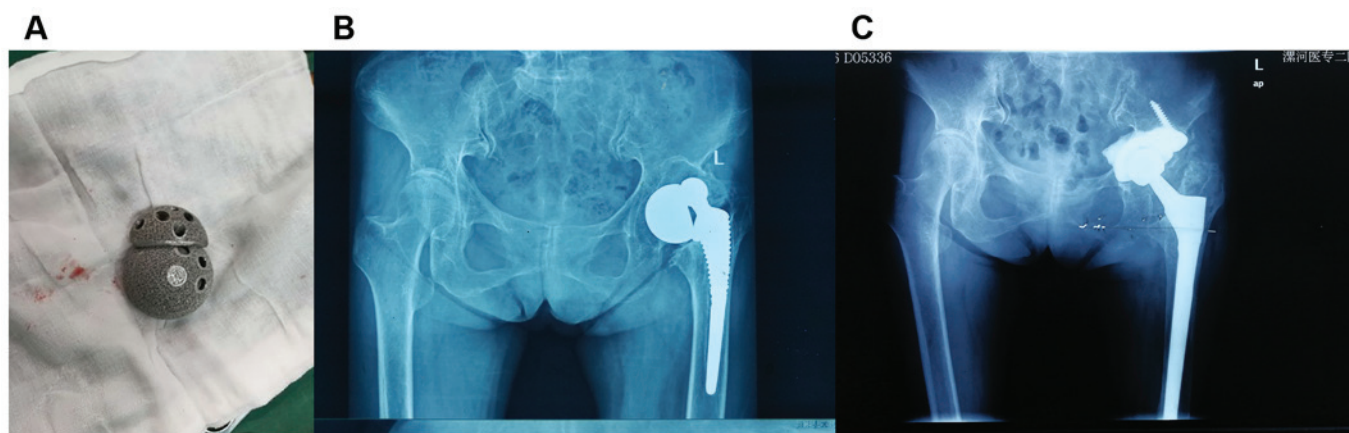


Figure 1. Images of 3D printed titanium alloy trabecular metal cups and pads and images of hip before and after total hip revision. (A) 3D printed titanium alloy trabecular metal cup and pad, (B) total hip replacement failed (preoperative X-ray film), (C) 3D printed titanium alloy trabecular metal cup and pad after renovation (postoperative X-ray film).

was no change in displacement and abduction angle in the observation group. In 20 patients, the cup was in close contact with the bone surface 1 week after surgery and there was no bright line under the X-ray. Two cases had bright lines 1 week after surgery, but the bright lines disappeared 6 months after operation. None of the patients showed a bright line at the last follow-up. None of the patients had loosening of the prosthesis 6 months after surgery. There was continuous trabecular passage at the junction of all the patients' prosthesis and host bone. In the control group, 15 patients had tight contact with bone surface at 1 week after surgery but no bright lines were observed under X-ray and 4 patients had bright lines at 1 week after surgery, but lines disappeared at 6 months after surgery. None of the patients showed bright line at the last follow-up. Revision failed in one patient, 18 patients had no loosening at 6 months after surgery and 18 patients had continuous trabecular passage at the junction of prosthesis and host bone.

## Discussion

In recent years, the number of patients undergoing total hip arthroplasty increased year by year and the patients are becoming younger and younger. Artificial total hip joints are worn away during daily work and life activities and they need to be refurbished after a long period of time. The difficulty of revision surgery is greater than that of primary hip replacement (11). A large number of clinical applications have found some methods and material design of hip replacement in the past, such as placement of cups in high-rotation centers, structural bone grafting of large bones, rotating reinforcing rings, titanium mesh combined with particle bone crushing and bone grafting, which have their own problems, such as complicated operation procedures, long duration of surgery, large amount of allogeneic bone, high replacement cost, easy infection, poor biological stability and insufficient biomechanical efficacy (12-14). Therefore, how to safely and

effectively repair the artificial hip joint has become a difficult problem in orthopedics.

Electron beam melting technology is an important part of 3D printing technology. Ideal bone growth interface can be obtained by electron beam melting technology. Metal solid layer and the surface porous layer of the printed prosthesis are formed once. Preparation of titanium alloy trabecular cup used in hip repair in this study is completed in a vacuum environment, so contamination of the cup by external environment was avoided. In addition, it is done at a constant temperature, resulting in good shape stability and low residual stress in the printed cups (2). At present, non-cemented prosthesis is often used in clinical revision of the hip joint. However, prosthesis of these materials has a low porosity and a non-uniform aperture. After revision, bone is difficult to grow into the prosthesis, resulting in an unsatisfactory revision effect. 3D printed titanium alloy trabecular cup and the pad have good bio-identity and the cells are easy to attach and grow on the surface of the prosthesis, which is beneficial to the osteogenic differentiation of stem cells. In this study, 3D printed titanium alloy trabecular metal cups and pads were used to repair the hip joint. Postoperative hip function Harris scores, pain VAS scores and quality of life SF-36 scores were improved compared with non-3D printed titanium alloy trabecular metal cups and pads. In addition, the stability and bone stenosis of hip prosthesis were better than non-3D printed titanium trabecular metal cups and pads. Therefore, use of 3D printed titanium trabecular metal cups and pads to repair the hip joint can better restore patients' hip function, reduce pain and improve the quality of life of patients. Improved clinical outcomes were achieved due to sufficient porosity, uniform pore size and excellent surface friction coefficient of 3D printed titanium alloy trabecular metal cups and pads.

It was found that when using 3D printed titanium alloy trabecular metal cups and pads to repair the hip joint, there are a few points to note: i) posterior lateral surgical approach can fully reveal the femoral shaft and posterior column of acetabulum, but it also increases the risk of dislocation; ii) when the acetabular prosthesis is removed with a thin bone knife, it can be operated between the cup and the bone cement. Operation between the acetabular wall and the bone cement can damage the acetabulum and increase the risk of fracture; iii) when the acetabular component is dislocated to acetabulum, care should be taken to avoid damage to the blood vessel during revision surgery; iv) when removing the bone cement at the bottom of the acetabulum, breaking the acetabular humerus into the pelvic cavity must be avoided; and v) when removing the bio-fixed cup prosthesis, a special acetabular neutral locator should be used to avoid damage to the acetabular wall.

Clinical effect of revision of the hip prosthesis was satisfactory with 3D printed titanium alloy trabecular metal cups and pads. However, the long-term efficacy is uncertain because follow-up was only performed for 1 year after surgery. Further research is needed to monitor long-term efficacy.

#### Acknowledgements

Not applicable.

#### Funding

No funding was received.

#### Availability of data and materials

The datasets used and/or analyzed during the present study are available from the corresponding author on reasonable request.

#### Authors' contributions

LW and GW worked on the renovation method. PC and KL collected and analyzed general data of patients. JL and SZ were responsible for follow-up analysis. LW wrote the manuscript. All authors read and approved the final manuscript.

#### Ethics approval and consent to participate

The study was approved by the Ethics Committee of the Second Affiliated Hospital of Luohe Medical College (Luohe, China). Patients who participated in this study, signed the informed consent and had complete clinical data.

#### Patient consent for publication

Not applicable.

#### Competing interests

The authors declare that they have no competing interests.

#### References

- Gladnick BP, Fehring KA, Odum SM, Christie MJ, DeBoer DK and Fehring TK: Midterm survivorship after revision total hip arthroplasty with a custom triflange acetabular component. *J Arthroplasty* 33: 500-504, 2018.
- Nakashima Y, Mashima N, Imai H, Mitsugi N, Taki N, Mochida Y, Owan I, Arakaki K, Yamamoto T, Mawatari T, *et al*: Clinical and radiographic evaluation of total hip arthroplasties using porous tantalum modular acetabular components: 5-year follow-up of clinical trial. *Mod Rheumatol* 23: 112-118, 2013.
- Pierannunzii L, Mambretti A and D'Imporzano M: Trabecular metal cup without augments for acetabular revision in case of extensive bone loss and low bone-prosthesis contact. *Int J Immunopathol Pharmacol* 24 (Suppl 2): 133-137, 2011.
- Sadhu A, Nam D, Coobs BR, Barrack TN, Nunley RM and Barrack RL: Acetabular component position and the risk of dislocation following primary and revision total hip arthroplasty: a matched cohort analysis. *J Arthroplasty* 32: 987-991, 2017.
- Wang B, Hao Y, Pu F, Jiang W and Shao Z: Computer-aided designed, three dimensional-printed hemipelvic prosthesis for peri-acetabular malignant bone tumour. *Int Orthop* 42: 687-694, 2018.
- Dimitroulis G, Austin S, Sin Lee PV and Ackland D: A new three-dimensional, print-on-demand temporomandibular prosthetic total joint replacement system: Preliminary outcomes. *J Craniomaxillofac Surg* 46: 1192-1198, 2018.
- Gustke KA, Levering MF and Miranda MA: Use of jumbo cups for revision of acetabulae with large bony defects. *J Arthroplasty* 29: 199-203, 2014.
- Adelani MA, Crook K, Barrack RL, Maloney WJ and Clohisy JC: What is the prognosis of revision total hip arthroplasty in patients 55 years and younger? *Clin Orthop Relat Res* 472: 1518-1525, 2014.
- Nie WB, Ye FG, Ma JL, Yu JP, Wang MX, Zhang ZH and Sun FJ: Three-dimensional (3D) printing technology assisted by minimally invasive surgery for pubic rami fractures. *Curr Med Sci* 38: 827-833, 2018.

10. Flecher X, Ollivier M, Maman P, Pesenti S, Parratte S and Argenson JN: Long-term results of custom cementless-stem total hip arthroplasty performed in hip fusion. *Int Orthop* 42: 1259-1264, 2018.
11. Lenguerrand E, Whitehouse MR, Beswick AD, Kunutsor SK, Burston B, Porter M and Blom AW: Risk factors associated with revision for prosthetic joint infection after hip replacement: A prospective observational cohort study. *Lancet Infect Dis* 18: 1004-1014, 2018.
12. Huang P, Lyons M and O'Sullivan M: The infection rate of metal-on-metal total hip replacement is higher when compared to other bearing surfaces as documented by the Australian Orthopaedic Association National Joint Replacement Registry. *HSS J* 14: 99-105, 2018.
13. Meek RM, Norwood T, Smith R, Brenkel IJ and Howie CR: The risk of peri-prosthetic fracture after primary and revision total hip and knee replacement. *J Bone Joint Surg Br* 93: 96-101, 2011.
14. Panagiotidou A, Meswania J, Hua J, Muirhead-Allwood S, Hart A and Blunn G: Enhanced wear and corrosion in modular tapers in total hip replacement is associated with the contact area and surface topography. *J Orthop Res* 31: 2032-2039, 2013.



This work is licensed under a Creative Commons Attribution-NonCommercial-NoDerivatives 4.0 International (CC BY-NC-ND 4.0) License.