

Case Report

Insulin overdose complicated by treatment-induced acute hepatic steatosis in a nondiabetic patient

Noriyuki Okamoto,¹ Shinsuke Onishi, Toshiyuki Onodera, Toshihiro Tawara, Hiroyuki Okamoto, Takafumi Shimizu, Akiko Oshiro, Yuka Morishita, and Satoshi Nara

Emergency and Critical Care Medical Center, Teine Keijinkai Hospital, Sapporo, Hokkaido, Japan

Background: There are few reports of dextrose-associated hepatic steatosis during insulin overdose treatment. Reports in nondiabetic patients are extremely rare. There is inadequate knowledge about the clinical course and treatment.

Case Presentation: A 37-year-old previously healthy, nondiabetic man self-administered 5,925 IU of insulin. On admission, his liver function tests were normal. However, following continued dextrose treatment, they increased, and he was diagnosed with hepatic steatosis. The liver function tests improved with decreasing dextrose dosage, and he was asymptomatic on discharge.

Conclusion: Acute hepatic steatosis may occur in nondiabetic and diabetic patients during treatment requiring large doses of dextrose infusion, such as for an insulin overdose. In addition, the degree of liver damage might also be related to the dextrose dose. Therefore, careful glycemic control and minimization of the dextrose dosage are recommended for diabetic and nondiabetic patients.

Key words: Dextrose, drug overdose, hepatic steatosis, insulin, liver injury

BACKGROUND

THE PRIMARY TREATMENT for an insulin overdose is intravenous dextrose administration.¹ There are few reports of dextrose-associated hepatic steatosis during the treatment of an insulin overdose.² Furthermore, reports in nondiabetic patients are extremely rare, with only one case³ reported in our search, and the knowledge of the clinical course or treatment in such cases is insufficient. We report a case of insulin overdose complicated by acute hepatic steatosis during treatment in a nondiabetic patient.

CASE PRESENTATION

A HEALTHY, NONDIABETIC 37-year-old man was hospitalized after self-administering a massive dose of

insulin with the intention of suicide. He was a pharmacist and used insulin available at his workplace to inject a total insulin dose of 5,925 IU subcutaneously (4,725 IU of fast-acting insulin and 1,200 IU of long-acting insulin). The patient was found in a lethargic state. He had some snacks while waiting for the Emergency Medical Service. On admission, he was alert with stable vital signs. His plasma glucose level was 45 mg/dl, potassium was 2.2 mmol/L, aspartate aminotransferase was 28 IU/L, and the alanine aminotransferase was 21 IU/L (Table 1). A continuous infusion of 50% dextrose and potassium was commenced with 2-hourly arterial blood gas analysis measurements. A target blood glucose level of 90–180 mg/dl was set to prevent hypoglycemia. Hypoglycemia and its complications did not occur after the start of the correction. On day 3, the patient developed abdominal discomfort. On day 4, although his abdominal symptoms had improved, his liver function tests (LFTs) were elevated: aspartate aminotransferase, 307 IU/L; alanine aminotransferase, 311 IU/L; and total bilirubin, 1.7 mg/dl. On day 5, the abdominal ultrasound showed hepatomegaly with hyperechoic spots and dull edges; hepatic steatosis was diagnosed. The LFTs were peaking. On day 6, the continuous dextrose infusion was stopped, and on day 8, he was discharged from the hospital without any symptoms and placed on outpatient observation. On day 12, the LFTs improved (Table 1).

FUNDING INFORMATION

This research did not receive any specific grant from the public, commercial, or not-for-profit funding agencies.

*Corresponding: Noriyuki Okamoto, MD, Emergency and Critical Care Medical Center, Teine Keijinkai Hospital, 1-40 Maeda 1-jo 12-chome, Teine-ku, Sapporo, Hokkaido, Japan. E-mail: no.okamoto2016@gmail.com.

Received 29 Apr, 2022; accepted 8 Jul, 2022

Table 1. Laboratory results for a 37-year-old nondiabetic man with insulin overdose, days 1–47

Day	1	2	3	4	5	6	7	8	12	47
T.Bil (mg/dl)	1.5	1	1.1	1.7	1	0.8	0.6	0.6	0.8	0.8
AST (IU/L)	28	20	32	307	202	156	85	79	56	25
ALT (IU/L)	21	15	27	311	328	291	210	179	125	17
Insulin (μ U/mL)	7.26	4.54	21.8	30.2	37	14.8	3.2	2.44	ND	ND
Lowest BGL (mg/dl)	45	87	110	117	120	83	80	ND	ND	ND
Highest BGL (mg/dl)	269	174	177	152	146	100	101	ND	ND	ND
Lactate (mmol/L)	6.5	2.3	3.2	4	5.1	4.2	2.9	ND	ND	ND

AST, aspartate aminotransferase; ALT, alanine aminotransferase; CT, computed tomography; F, female; M, male; ND, no data; RUQ, right upper quadrant; US, ultrasound.

DISCUSSION

HEPATIC STEATOSIS IS a complication of dextrose administration to treat an insulin overdose.³ The massive dose of insulin with the subsequent high doses of dextrose administration advances glycogen formation and its storage in the liver and inhibits glycogenolysis.⁴ The excess glycogen accumulation in the hepatocytes causes liver dysfunction with elevated liver enzymes and associated hepatomegaly.^{5–7} Hepatic steatosis, known as glycogenic hepatopathy, has been reported as a complication in diabetic patients, even if not due to insulin overdose.⁶ Our patient had no other drug overdose and had normal LFTs on admission. Nevertheless, his LFTs increased on hospital day 4, and he developed acute hepatic steatosis, so we controlled the blood glucose level even more carefully. As a result, the LFTs improved with decreasing dextrose dosage (Fig. 1). No other medications were provided during the hospitalization.

We searched for cases of acute hepatic steatosis when treating insulin overdose with a dextrose infusion^{3,4,8–10} (Table 2). Most of the reported cases were patients with type 1 diabetes mellitus using self-administered insulin and who,

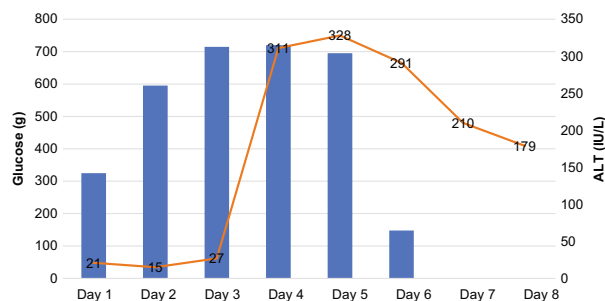


Fig. 1. Change in alanine aminotransferase (ALT) with decreased dosage of glucose in a 37-year-old nondiabetic man with insulin overdose.

in all cases, had been treated with a massive dose of dextrose for multiple days to avoid hypoglycemia caused by the high amount of self-administered insulin. As a result, the LFTs progressively increased while administering dextrose and rapidly corrected after the glucose level stabilized without dextrose infusion. Almost all the cases presented with hepatomegaly, and all showed some abdominal symptoms, mostly visceral pain. The duration of dextrose treatment was at least 4 days, and the average time to onset of liver injury was 3.3 days. The average dosage of dextrose before the development of liver injury was approximately 2,920 g, and all the patients, including the present case, had received more than 2,000 g of glucose. The duration of treatment and the susceptibility to liver injury appears to be unrelated to the amount or type of insulin.

Of the six cases, only ours and the case reported by Jolliet *et al.*³ were cases of an insulin overdose in nondiabetic patients. The degree of liver injury in these two cases appears to be less severe, especially considering they administered more than 4,000 g of glucose. Sasidharan *et al.*² stated that chronic hyperglycemia in diabetics might increase glucose influx into the hepatocytes and predispose them to hepatic steatosis under conditions that exceed the physiological insulin doses. Therefore, it is hypothesized that diabetic patients might be more susceptible to hepatic steatosis relative to the amount of dextrose administered.

In such situations, because of the strong awareness of the need to avoid hypoglycemia, physicians could inadvertently administer dextrose excessively. As a result, acute hepatic steatosis could occur even with a moderate degree of glycemic control. Therefore, attention should be paid to the glucose dosage with more stringent glycemic control. It is important to monitor blood glucose levels and LFTs frequently and titrate glucose infusions.

The goal should be to maintain the lowest blood glucose level without hypoglycemic symptoms.

Table 2. Comparison of data from six cases of acute hepatic steatosis during treatment for insulin overdose with dextrose infusion

Reference	Age/sex Type of diabetes	Total insulin (short/long)	Liver injury onset (day)	Dextrose dosage before development of liver injury (g)	Peak AST/ALT	Dextrose duration (days)	Symptoms	Examination findings
Jolliet ³	48/F Nondiabetic	2,000 (1,000/1,000)	3	4,040	420/610	4	Nausea RUQ pain	Hepatomegaly on US
Tsujimoto ⁴	41/M Type 2	180 (0/180)	3	2,063	1,064/1,178	5	Upper abdominal pain	Hepatomegaly and elevated attenuation on CT, liver biopsy
Warriner ⁸	26/M Type 1	4,800 (0/4,800)	3	Approximately 2,400	1,294/520	6	Epigastric and right hypochochondrial pain	Hepatomegaly on US
Endall ⁹	45/F Type 1	4,350 (300/4,050)	3	3,062.5	1,437/991	7	Nausea, abdominal pain	N/A
Fujisaki ¹⁰	25/M Type 1	5,700 (2,100/3,600)	4	3,600	1,441/1,117	>8	Fatigue, right hypochochondrial pain, abdominal discomfort	Hepatomegaly and elevated attenuation on CT
This case	37/M Nondiabetic	5,925 (4,725/1,200)	4	2,355	307/328	6	Abdominal discomfort	Hepatomegaly on US

CONCLUSION

EMERGENCY PHYSICIANS MIGHT be required to treat patients with insulin overdose, including nondiabetic patients who sometimes require massive doses of dextrose. Acute hepatic steatosis could occur in nondiabetic as well as diabetic patients during the administration of large dextrose infusions, such as those exceeding 2,000 g for insulin overdose. The degree of liver damage could be related to the dextrose dose, so careful glycemic control and minimization of the dextrose dosage are recommended for both diabetic and nondiabetic patients.

ACKNOWLEDGMENTS

WE WOULD LIKE to thank Editage (www.editage.com) for the English language editing.

DISCLOSURE

APPROVAL OF THE research protocol with approval no. and committee name: All procedures complied with relevant laws and institutional guidelines. The work described was carried out in accordance with The Code of Ethics of the World Medical Association (Declaration of Helsinki) for experiments involving humans.

Informed consent: Written informed consent for the publication. Of this case report was obtained from the patient.

Registry and registration no. of the study/trial: N/A.

Animal studies: N/A.

Conflict of interest: None.

REFERENCES

- Johansen NJ, Christensen MB. A systematic review on insulin overdose cases: clinical course, complications and treatment options. *Basic Clin. Pharmacol. Toxicol.* 2018; 122: 650–9.
- Sasidharan Pillai S, Quintos JB, Topor LS. Acute hepatitis due to hepatic glycogenosis after insulin overdose and oral glucose administration in an adolescent. *J. Endocr. Soc.* 2021; 5: bvab142.
- Jolliet P, Leverve X, Pichard C. Acute hepatic steatosis complicating massive insulin overdose and excessive glucose administration. *Intensive Care Med.* 2001; 27: 313–6.
- Tsujimoto T, Takano M, Nishiofuku M *et al.* Rapid onset of glycogen storage hepatomegaly in a type-2 diabetic patient after a massive dose of long-acting insulin and large doses of glucose. *Intern. Med.* 2006; 45: 469–73.
- Julián MT, Alonso N, Ojanguren I, Pizarro E, Ballestar E, Puig-Domingo M. Hepatic glycogenosis: an underdiagnosed complication of diabetes mellitus? *World J. Diabetes* 2015; 6: 321–5.
- Sherigar JM, Castro J, Yin YM, Guss D, Mohanty SR. Glycogenic hepatopathy: a narrative review. *World J. Hepatol.* 2018; 10: 172–85.
- Giordano S, Martocchia A, Toussan L *et al.* Diagnosis of hepatic glycogenosis in poorly controlled type 1 diabetes mellitus. *World J. Diabetes* 2014; 5: 882–8.
- Warriner D, Debono M, Gandhi RA, Chong E, Creagh F. Acute hepatic injury following treatment of a long-acting insulin analogue overdose necessitating urgent insulin depot excision. *Diabet. Med.* 2012; 29: 232–5.
- Endall R, McCallum R, Burgess J. Case report: high-concentration insulin glargine overdose complicated by hepatic steatosis. *J. Endocr. Soc.* 2020; 4: bvz020.
- Fujisaki N, Kosaki Y, Nojima T *et al.* Glycogenic hepatopathy following attempted suicide by long-acting insulin overdose in patient with type 1 diabetes. *J. Am. Coll. Emerg. Physicians Open.* 2020; 1: 1097–100.