

## Congenital feline tuberculosis: the first case report

Osman Dağar<sup>1\*</sup>, Mehmet Burak Ateş<sup>2</sup>, Mustafa Ortatlı<sup>2</sup>, Fatih Mehmet Öztürk<sup>2</sup>

<sup>1</sup> Department of Veterinary Medicine, Eskil Vocational School, Aksaray University, Aksaray, Türkiye; <sup>2</sup> Department of Pathology, Faculty of Veterinary Medicine, Selçuk University, Konya, Türkiye.

Article Info	Abstract
<b>Article history:</b> Received: 16 January 2024 Accepted: 05 February 2024 Available online: 15 April 2024	<p>This study presents the first report of congenital tuberculosis in an 8-month-old male British Shorthair cat. The case was examined using histopathological and immunohistochemical methods. The cat was referred to a private veterinary clinic with general respiratory system problems and subsequent deterioration, leading to death. The cat owner granted permission for the cat necropsy and pathological examinations at Department of Pathology, Faculty of Veterinary Medicine, Selçuk University, Konya, Türkiye. During systemic necropsy, white round foci with diameters ranging from 3.00 to 5.00 mm were observed in the lung and spleen. Tissue samples were collected from the lung, spleen, liver, heart, kidney, mediastinal lymph nodes and brain for histopathological examinations. The tissues were subjected to routine histological tissue processing and sections were stained with Hematoxylin and Eosin and Ziehl-Neelsen. Additionally, <i>Mycobacterium spp.</i> antibodies were used for immunohistochemical staining. Microscopic examination revealed exudative tuberculosis lesions, areas of necrosis without a fibrous capsule and karyorrhectic cells only in the lung and spleen. Acid-resistant bacteria observed by ZN staining in the lesioned areas of the lung and spleen were identified as <i>Mycobacterium spp.</i> using immunohistochemical staining. No positive staining was observed in other organs using ZN and immunohistochemical methods. As a result, congenital tuberculosis was diagnosed in a cat for the first time, especially in relation to lesions in the spleen.</p>
<b>Keywords:</b> Congenital tuberculosis Feline Histopathology Immunohistochemistry	

© 2024 Urmia University. All rights reserved.

### Introduction

Animal tuberculosis is a worldwide disease caused by *Mycobacterium tuberculosis* complex members that can infect humans and a wide range of domestic and wild mammals.<sup>1</sup> Mycobacteria are Gram positive, non-sporulating, non-motile and acid-fast bacilli appearing as straight or slightly curved rods at a length of 1.00 to 4.00 µm and a width of 0.30 to 0.60 µm under the microscope.<sup>2</sup> *Mycobacterium* infections are most transmitted through the respiratory and alimentary tracts; genital, congenital and cutaneous routes of transmission are rare.<sup>3</sup>

Congenital tuberculosis may happen as a result of maternal tuberculosis affecting the genital system or placenta. It can spread to the fetus through the umbilical cord vessels or ingested or aspirated infected amniotic fluid during pregnancy or birth.<sup>3-5</sup> This manifestation is important in regions where tuberculosis in cattle is common and approximately 0.50% of new-born calves are infected with tuberculosis. Since endometritis tuberculosa is common only in cows, this route of transmission is of

little importance in other species (*e.g.*, cats and dogs). Congenital tuberculosis spreads quickly, and the animals usually die within a few weeks or months. During this time, the disease becomes generalized, and lesions can be found especially in the lungs, regional lymph nodes and spleen. Splenic lesions of tuberculosis are rare in adult animals, and at the time of their presence, irrespective of the age of the animal, they are regarded as an indicator of congenital infection.<sup>3</sup>

The purpose of this report was to describe the first case of feline congenital tuberculosis in the world using histopathological and immunohistochemical methods, and raise awareness regarding this disease, having zoonotic potential and therefore, is a public health concern among academic and clinical veterinarians as well as cat owners.

### Case Description

An 8-month-old male British Shorthair domestic cat was referred to a private veterinary clinic with respiratory distress and abdominal breathing. Unfortunately, the cat's

#### \*Correspondence:

Osman Dağar. PhD candidate

Department of Veterinary Medicine, Eskil Vocational School, Aksaray University, Aksaray, Türkiye

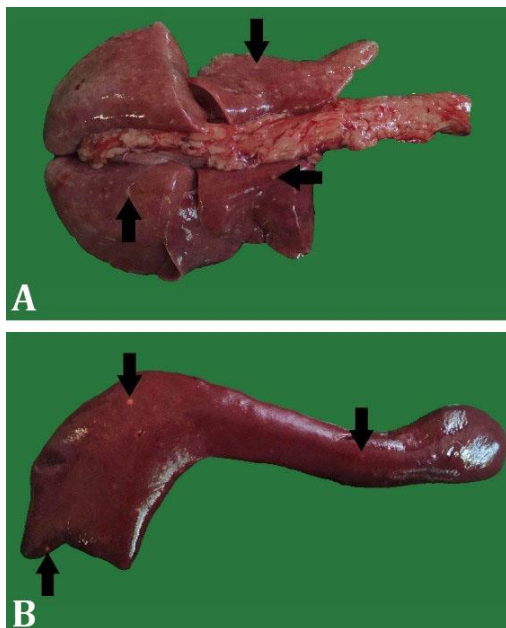
E-mail: osman.dagar@aksaray.edu.tr



This work is licensed under a Creative Commons Attribution-NonCommercial-ShareAlike 4.0 International (CC BY-NC-SA 4.0) which allows users to read, copy, distribute and make derivative works for non-commercial purposes from the material, as long as the author of the original work is cited properly.

condition was deteriorated, and the animal passed away 12 hr after admission. With the owner's consent, the cat was sent to the Department of Pathology, Faculty of Veterinary Medicine, Selçuk University, Konya, Türkiye, for necropsy and pathological examinations.

During systemic necropsy, white round foci with diameters ranging from 3.00 to 5.00 mm were observed in the lung (Fig. 1A) and spleen (Fig. 1B). Additionally, hydrothorax and hydropericardium were identified. Meningeal hyperemia as well as hepatic and renal degenerations were also observed. No macroscopically pathological findings were observed in the lymph nodes or other organs.

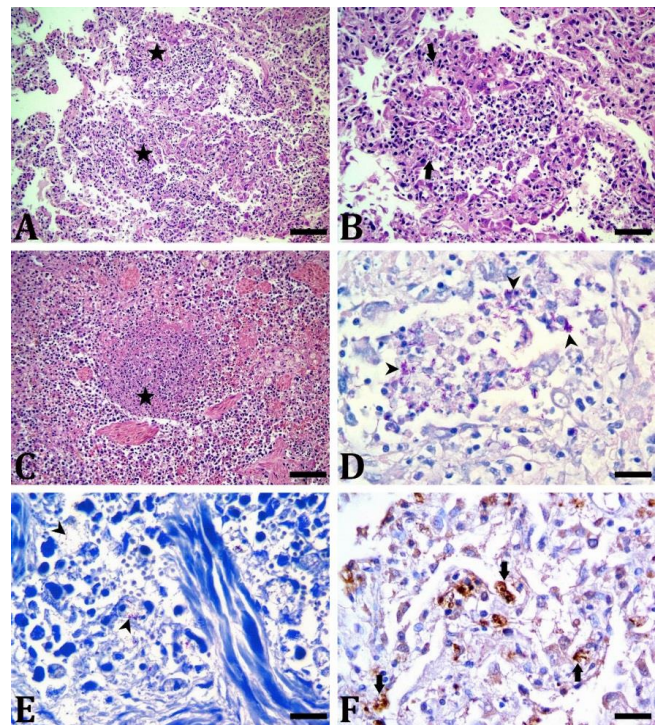


**Fig. 1.** Macroscopic findings of congenital tuberculosis in an 8-month-old male British Shorthair cat. White round foci (arrows) with diameters ranging from 3.00 to 5.00 mm can be seen in the **A)** lung and **B)** spleen.

For histopathological examination, tissue samples taken from lung, spleen, liver, heart, kidney, mediastinal lymph nodes and brain were fixed in 10.00% neutral buffered formaldehyde solution. Tissues were embedded in paraffin after routine histopathological tissue processing and sections having 5.00  $\mu\text{m}$  thickness were prepared from the paraffin blocks using microtome (Leica RM2125, Germany) and stained with Hematoxylin and Eosin (H & E) and Ziehl-Neelsen (ZN).<sup>6</sup> Selected sections were also immunohistochemically stained with the anti-*M. tuberculosis* antibody (1:100; Abcam, Cambridge, UK) according to the previously reported method in the immunohistochemistry staining device (Bond-Max; Leica Biosystems, Deer Park, United States) using the Bond™ polymer refine detection kit (DS9800; Leica Biosystems, Deer Park, United States) procedure.<sup>7</sup> In negative controls, phosphate-buffered saline was used instead of primer

antibody. Microscopic slides were examined by binocular light microscope (BX51; Olympus Tokyo, Japan) and photographed (EP50; Olympus, Tokyo, Japan).

Microscopically, multi-focal nodular areas consisting of necrosis without fibrous capsule and karyorrhectic cells were also identified in the lung (Figs 2A, and 2B) and spleen (Fig. 2C). These tuberculous lesions were widely observed in the lung and spleen. Several lymphohistiocytic cell infiltrations were observed around the nodular areas. While there were very few epithelioid histiocytes around the lesions in the lung and spleen, no giant cell type was found. In the liver, hepatocytes degeneration and mononuclear cell infiltration in the portal area were obvious. In the kidney, tubular degeneration and amyloid-like accumulations in the glomeruli were detected. In addition, hyperemia and inflammatory cell infiltration were seen in the meninges. No histopathological alteration was found in the heart and mediastinal lymph nodes.



**Fig. 2.** Histopathological and immunohistochemical analyses of lung and spleen in an 8-month-old male British Shorthair cat with congenital tuberculosis. **A)** Areas of necrosis without fibrous capsule (asterisks) in the lung (H & E staining bar = 100  $\mu\text{m}$ ); **B)** Karyorrhectic cells (arrows) and lymphohistiocytic cell infiltration in necrosis areas of the lung; (H & E staining, bar = 50.00  $\mu\text{m}$ ); **C)** Area of necrosis without fibrous capsule (asterisk) in the spleen (H & E staining, bar = 100  $\mu\text{m}$ ); **D)** Acid-fast bacteria (arrowheads) in necrosis areas of the lung (Ziehl-Neelsen staining, bar = 20.00  $\mu\text{m}$ ); **E)** Acid-fast bacteria (arrowheads) in necrosis areas of the spleen (Ziehl-Neelsen staining, bar = 20.00  $\mu\text{m}$ ); **F)** Positive immunostaining (arrows) in the lung using *Mycobacterium spp.* antibody (Immunohistochemical staining, bar = 20.00  $\mu\text{m}$ ).

The ZN staining of lung (Fig. 2D) and spleen (Fig. 2E) sections revealed acid-fast bacteria presence in the areas of exudative type caseous necrosis. No acid-fast bacterium was found following ZN staining of other organs. Immunohistochemical staining of lung (Fig. 2F) and spleen sections revealed positive immunostaining using *Mycobacterium spp.* antibody, particularly in areas of necrosis.

## Discussion

Congenital tuberculosis spreads without symptoms and causes animals death, usually when they are a few months old. For this reason, lesions are observed in the lungs, regional lymph nodes and spleen of dead animals. Tuberculous lesions are rarely seen in the spleen of adult animals. If a tuberculosis lesion is seen in the spleen, it is regarded as an indicator of congenital tuberculosis; regardless of the age of the animal.<sup>3</sup> In the current report, congenital tuberculosis was diagnosed in an 8-month-old cat presenting general respiratory system symptoms through detecting tuberculosis lesions and the agent in the spleen using H&E, ZN and immunohistochemistry methods.

Congenital tuberculosis may occur when the disease affects the genital tract or placenta.<sup>8</sup> Tuberculosis bacilli are transmitted to the fetus either hematogenously *via* the umbilical vein or through infected amniotic fluid being ingested or aspirated during pregnancy or birth.<sup>4,9</sup> In this case, transmission is believed to be occurred both by aspiration of infected amniotic fluid and hematogenously through the umbilical vein. Presence of tuberculosis lesions and causative agent only in the spleen and lung, and absence of tuberculosis lesion or agent in the mediastinal lymph nodes support this situation.

The lesions of tuberculosis in carnivores differ from those in other species. Typical tuberculous granulomas are not common, and when they occur, caseous necrosis is not a prominent gross feature. More often there is a non-specific granulation tissue in which macrophages are scattered - randomly and giant cells are rare or absent.<sup>3</sup> Reportedly, feline tuberculosis-linked necrosis was characterized as areas where cellular and structural features were lost due to the eosinophilic or basophilic (karyorrhctic) residues accumulation, being called caseous necrosis.<sup>10</sup> In this case, areas of necrosis were found without a fibrous capsule, karyorrhctic cells were seen in abundance, only small numbers of epithelioid histiocytes were present and giant cells were not observed.

In conclusion, this is the first case report of feline congenital tuberculosis in the world being confirmed using

histopathological and immunohistochemical methods. This case highlights the severity of the disease that can emerge if proper preventative and control procedures are not followed. Since tuberculosis is a zoonoanthropotic and zoonotic disease, suspected or infected cats with respiratory symptoms should be examined regularly because they may pose a zoonotic risk to cat owners, children and clinician veterinarians.

## Acknowledgments

None.

## Conflict of interest

The authors declare no conflict of interest.

## References

1. Thomas J, Balseiro A, Gortázar C, et al. Diagnosis of tuberculosis in wildlife: a systematic review. *Vet Res* 2021; 52: 31. doi: 10.1186/s13567-020-00881-y.
2. Barry 3<sup>rd</sup> CE, Lee RE, Mdluli K, et al. Mycolic acids: structure, biosynthesis and physiological functions. *Prog Lipid Res* 1998; 37(2-3): 143-179.
3. Jubb K, Kennedy P, Palmer N. Pathology of domestic animals. 3<sup>rd</sup> ed. Cambridge, USA: Academic Press 1985; 493-504.
4. Gnehm HE, Stähelin-Massik J, Zeilinger G. Congenital tuberculosis in a premature infant. *Swiss Med Wkly* 2002; 132(4142): 598. doi: 10.4414/smw.2002.10101.
5. M'Fadyean J. Congenital tuberculosis in the calf. *J Comp Pathol Ther* 1899; 12: 156-162.
6. Luna L. Manual of histologic staining methods of the armed forces institute of pathology. 3<sup>rd</sup> ed. New York, USA: McGraw-Hill 1968; 43-43.
7. Ates MB, Çiftçi MK, Oruç E, et al. Mycobacterium bovis tuberculosis in a neonatal Holstein calf [Turkish]. *Eurasian J Vet Sci* 2019; 35(3): 175-179.
8. Ozyigit MO, Senturk S, Akkoc A. Suspected congenital generalised tuberculosis in a newborn calf. *Vet Rec* 2007; 160(9): 307-308.
9. Dungworth D. The respiratory system. In: Jubb KVF, Kennedy PC, Palmer N (Eds). Pathology of domestic animals. 3<sup>rd</sup> ed. London, UK: Academic Press 1993; 641-648.
10. Mitchell JL, Del Pozo J, Woolley CSC, et al. Histological and immunohistochemical features suggesting aetiological differences in lymph node and (muco)cutaneous feline tuberculosis lesions. *J Small Anim Pract* 2022; 63(3):174-187.