



Case report

Anterior infectious necrotizing scleritis secondary to *Pseudomonas aeruginosa* infection following intravitreal ranibizumab injection

Razek Georges Coussa*, Susan M. Wakil, Hady Saheb, David E. Lederer, Karin M. Oliver, Devinder P. Cheema

Department of Ophthalmology, McGill Academic Eye Centre, 5252 Boulevard de Maisonneuve Ouest, 4th Floor, Montréal, Québec H4A 3S5, Canada

ARTICLE INFO

Article history:

Received 7 July 2016

Received in revised form

10 October 2016

Accepted 28 October 2016

Available online 29 October 2016

Keywords:

Infectious scleritis

Intravitreal ranibizumab injection

Pseudomonas aeruginosa

ABSTRACT

Purpose: To report the occurrence and management of severe infectious scleritis in a 75 year-old woman following intravitreal ranibizumab injection.**Observations:** A 75 year-old monocular woman receiving monthly intravitreal ranibizumab injection for wet age related macular degeneration in the left eye presented with severe dull pain, decreased vision, and scleral melt with discharge 2 weeks after her last injection. The dilated fundus exam was devoid of vitritis. The patient was admitted to our hospital for both diagnostic and therapeutic purposes. She was initially started on aggressive oral and topical antibiotics, but showed no significant improvement. The scleral cultures were positive for *Pseudomonas aeruginosa*. In view of the aggressive nature of her infection, intravenous antibiotics were added to the treatment regimen. The patient recovered her baseline visual function after two weeks of intravenous, oral and, topical antibiotics.**Conclusions and importance:** To our knowledge, this is the first case of anterior infectious necrotizing scleritis secondary to *Pseudomonas aeruginosa* infection following intravitreal ranibizumab injection. Clinicians performing intravitreal injections should have a high index of suspicion for iatrogenic infections including scleritis and endophthalmitis, as these infections require aggressive topical and systemic antibiotics as well as possible hospitalization.© 2016 The Authors. Published by Elsevier Inc. This is an open access article under the CC BY-NC-ND license (<http://creativecommons.org/licenses/by-nc-nd/4.0/>).

1. Introduction

Necrotizing anterior scleritis is the most severe form of infectious scleritis and represents a serious threat to vision.^{1,2} This presents with a gradual onset of pain that becomes extreme, persistent and may radiate to the temple, brow or jaw.^{1,2} Scleral involvement is characterized by severe vasculitis and closure of the episcleral vascular bed with apparent areas of capillary non-perfusion, infarction, and necrosis of the involved area.¹ The extent of scleral necrosis may either be sectoral or diffuse and may also rapidly progress, exposing the underlying choroid.¹ Disseminating inflammation with involvement of the cornea, ciliary body, and trabecular meshwork is common and may result in severe ocular morbidity including, keratitis, anterior uveitis, and elevated intraocular pressure.¹

1.1. Case report

A 75 year-old woman, known for controlled hypertension and dyslipidemia, was followed for geographic atrophy secondary to age related macular degeneration (AMD) in the right eye (OD) and exudative AMD in the left eye (OS), for which she was being treated with ranibizumab intravitreal injections (inferotemporal quadrant of injection). Her baseline best corrected visual acuity (BCVA) was CF at 1 m OD and 20/50 OS. Her right eye showed significant macular scarring and an advanced cataract.

Two weeks following her 20th intravitreal injection in the left eye by the same retina specialist,¹ the patient presented with

¹ The injection protocol included a drop of topical anesthesia followed by a drop of 5% povidone-iodine applied at the following times: 30 minutes before the injection, 5 minutes before the injection and 30 seconds before the injection. A lid speculum was used and the injection of anti-VEGF was made in the inferotemporal quadrant. Both patient and doctor employed no talking during the injection procedure. The retina specialist performing the injection did not wear gloves during the procedure. However, both hands were thoroughly cleaned with waterless soap alcohol-based solution using 20 seconds of scrub. Furthermore, no hand jewelry was worn during the procedure.

* Corresponding author.

E-mail address: razek.coussa@hotmail.com (R.G. Coussa).

purulent discharge, photophobia and ocular pain. Her BCVA OS was CF and IOP was 12 mmHg, respectively. The slit lamp exam showed 4+ conjunctival injection, 3+ inferotemporal corneal folds and 1+ anterior chamber cells, in addition to an inferotemporal 12 mm (horizontally) by 6 mm (vertically) area of white scleral necrosis with an overlying epithelial defect (Fig. 1A and B). This area was adjacent to an anterior 5 mm by 3 mm area of scleral thinning characterized by uveal show (Fig. 1A and B). The dilated fundus exam was within her baseline without any vitritis or vitreal infiltrates. There were also no pertinent findings on B-scan ultrasonography. The working diagnosis was infectious scleritis. The patient was then started on ciprofloxacin 500 mg po BID and topical fortified vancomycin 50 mg/ml and tobramycin 14 mg/ml q1h, alternating every 30 minutes. The sclera was cultured for bacteria and fungus.

The patient denied any autoimmune diseases, recent trauma, and travel history. However, an immunological and infectious blood workup as well as a chest x-ray were ordered to rule out serious conditions including sarcoidosis and tuberculosis. The patient was then admitted for further management due to the severity of her condition. Infectious disease services were consulted for co-management of the patient condition.

The workup was negative for autoimmune diseases and the scleral cultures were positive for *Pseudomonas aeruginosa*. Despite the initial treatment, the patient showed new satellite lesions and enlargement of the necrotic area with increased scleral thinning and significantly dilated scleral vessels on further follow-ups (Fig. 1C–E). A second scleral culture was also positive for *Pseudomonas aeruginosa*.

In view of the lack of significant improvement, a more aggressive treatment was started under the guidance of the infectious disease services. The modified treatment consisted of two weeks of topical fortified tobramycin q1h, topical ciprofloxacin QID, intravenous meropenem 2g q8h and intravenous tobramycin 7 mg/kg (430mg) once daily. She remained on this treatment regimen for 2 weeks during which significant improvement in her ocular status was noted (Fig. 1F–H). The patient was discharged after 3 weeks of in-patient stay with a BCVA of 20/50 after pinhole correction, IOP of 12 mmHg, ½+ anterior chamber cells and 1+ corneal folds. Importantly, the necrotic scleral area was reduced to 7 mm by 2.5 mm (Fig. 1I and J). The antibiotic regimen was tapered to topical fortified tobramycin q6h for 3 days while keeping ciprofloxacin, both topically QID and 500 mg po BID for a total of 10 weeks post discharge. The patient was then followed closely and remained stable.

At six-month follow-up, her BCVA and IOP were 20/50 and 13 mmHg, respectively. The previously infected scleral area was completely healed (4.5 mm by 2 mm) but nonetheless markedly thinned (Fig. 1K–M). The choroidal neovascular lesion has remained inactive after one year follow-up and repeated OCT examinations. The patient did not need further injections. Her vision remains stable at 20/50 at one year follow-up.

2. Discussion

Inflammatory disorders of the sclera comprise diverse clinical presentations and encompass a broad spectrum of etiologies ranging from idiopathic to autoimmune to infectious.^{1,2} Though infectious etiologies of scleritis are rare, representing about 5–10% of cases, the high disease burden associated with infectious scleritis warrants its increased scrutiny.²

The main etiology of infectious scleritis is predominantly bacterial.² *Pseudomonas aeruginosa* is the most common organism implicated in this condition, isolated from up to 85% of bacterial cultures.^{2,3} This has been associated with post-traumatic or post-

surgical processes in several recent studies.^{4,5} Cases following pterygium surgery are most frequently reported, but infectious scleritis has also been described after excisions of conjunctival neoplasms, as well as cataract, vitreoretinal, and glaucoma surgeries.^{3,4,6–8}

The most feared complication of intravitreal injections is endophthalmitis. Its incidence varies between studies and ranges between 0.0053% (equivalent to 1 in every 18,839 injections)⁹ and 0.21%.¹⁰ Staphylococcus and Streptococcus species are reported to be the most and second most common infectious organisms. In a study by Simunovic et al., coagulase negative Staphylococcus, Streptococcus and *Staphylococcus aureus* represented 42.4%, 39.4% and 9.1%, respectively, of the microbiologic profile of post-intravitreal injections related endophthalmitis.¹¹

Currently, there is still no preferred method for reducing the incidence of post-intravitreal injections endophthalmitis. The use of topical antibiotics after intravitreal injection is still controversial. In fact, one study found no statistical differences in the incidence of post-intravitreal injections endophthalmitis (0.052% in the group with antibiotics vs. 0.048% in the group without antibiotics¹²). Compared to povidone–iodine alone before intravitreal injections, the combination of topical antibiotics and povidone–iodine did not statistically reduce the incidence of post-intravitreal injections endophthalmitis.¹³ Furthermore, the repeated use of topical antibiotics can predispose to antibiotic resistance.¹⁴

The use of 5% povidone–iodine on the lids and ocular surface is a very common standard practice. Applying povidone–iodine 30 seconds before the injections was shown to statistically reduce the conjunctival bacterial load.¹⁵ Interestingly, the bactericidal effect of a single drop of povidone–iodine was estimated to be equivalent to a three-day course of topical antibiotics.¹⁶

The high rate of contamination with Staphylococcus and Streptococcus species was thought to be related to inoculation from oropharyngeal flora.¹⁷ The use of a surgical mask was associated with a significant statistical reduction in bacterial colonies compared to no-mask technique.¹⁸ Along the same reasoning, Garg et al. showed a statistically significant reduction in the rate of post-injection endophthalmitis following strict 'No-Talking' policy during injection procedure.¹⁹

Speculum placement prior to injections was not reported to affect the conjunctival bacterial counts.¹⁵ The use of gloves and/or patient draping is not a standard office practice. It is likely more common in Europe where intravitreal injections are administered in operating rooms. The latter practice was associated with a lower rate of endophthalmitis compared to in-office injections as per Abell et al.²⁰

Infectious necrotizing scleritis, although extremely rare, is another very severe ocular complication that is occasionally iatrogenic. To our knowledge, this is the first case of anterior infectious necrotizing scleritis secondary to *Pseudomonas aeruginosa* infection following intravitreal ranibizumab injection. Our initial treatment was likely not sufficient given the aggressiveness of the bacteria and the severity of the infection. However, our revised treatment protocol eliminated the infection effectively and restored the patient's visual function.

Clinicians performing intravitreal injections should have a high index of suspicion for iatrogenic infections including scleritis and endophthalmitis, especially in patients with poor baseline visual acuity. Referral to anterior segment specialists should be without delay as such severe infections are not only difficult to diagnose and manage, but also require aggressive topical and systemic antibiotics and possible hospitalization.

Patient consent

The patient consented in writing to publication of the case.

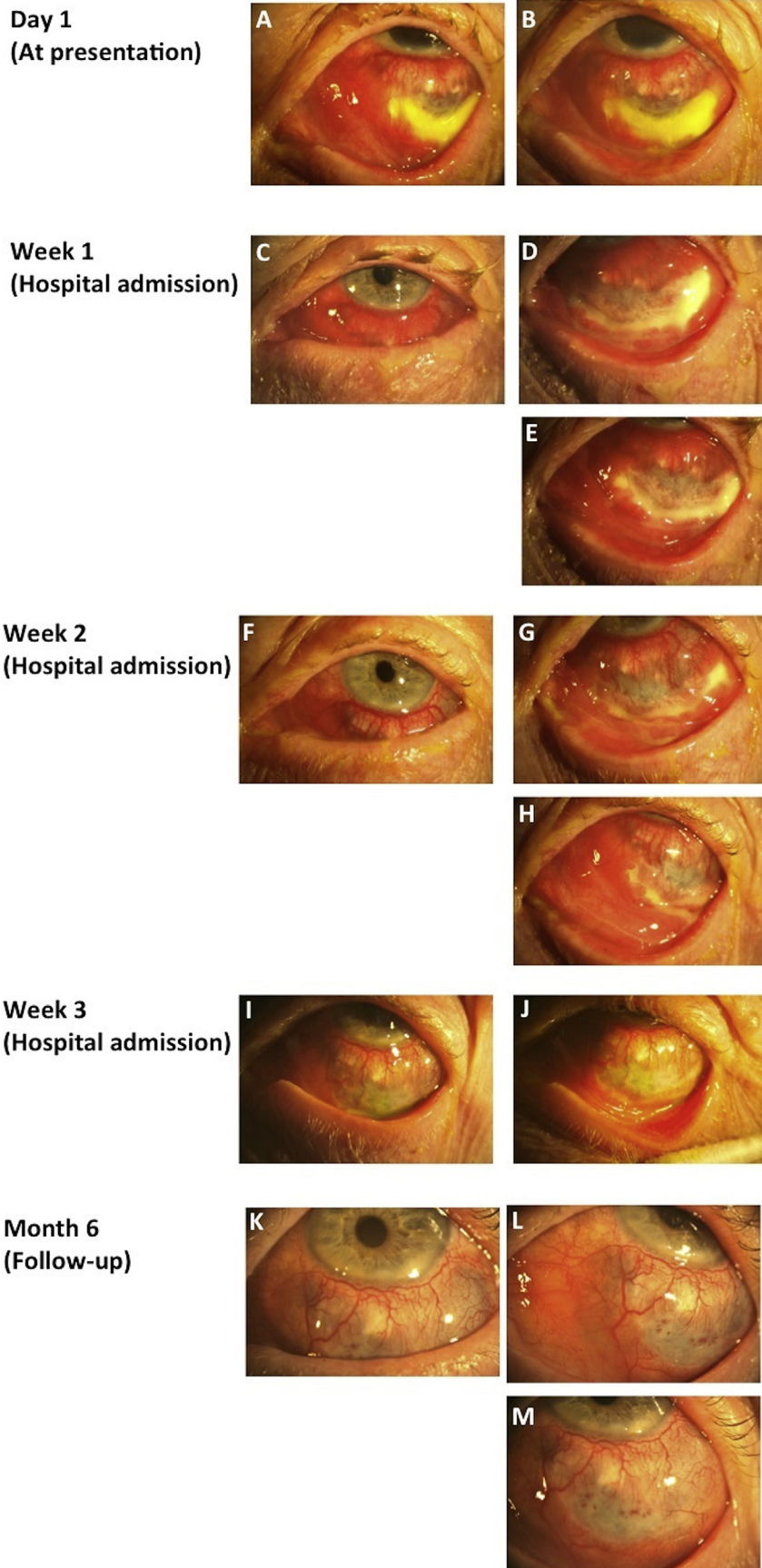


Fig. 1. OS Anterior infectious necrotizing scleritis. A–B. Photos taken at presentation showing an inferotemporal 12 mm horizontal by 6 mm vertical area of white scleral necrosis with an overlying epithelial defect. This area was adjacent to an anterior 5 mm horizontal by 3 mm vertical area of scleral thinning characterized by uveal show. C–E. Photos taken four days after presentation showing significant worsening of the infectious process that is characterized by new nasal and temporal satellite lesions, enlargement of the necrotic area with increased scleral thinning and significantly dilated scleral vessels. F–H. Photos taken 1 week after presentation while on intravenous meropenem and intravenous tobramycin. There is significant improvement in the size of the necrotic area. I–J. Photos at discharge following 2 weeks of intravenous treatment. There is marked shrinkage of the necrotic scleral area to 7 mm horizontal by 2.5 mm vertical. K–M. Photos taken six months post discharge showing a final necrotic healed area of 4.5 mm horizontal by 2 mm vertical with a resultant uveal show.

Funding

No funding or grant support.

Conflict of interest

The following authors have no financial disclosures: RGC, SMR, KMO and DPC. We have the following financial and/or commercial disclosures to disclose:

- DEL is a consultant for Alcon, Bayer, and Novartis Pharmaceuticals.
- HS is a consultant for Alcon, Allergan, AMO, B&L, Ivantis, Aerie and the FDA.

Authorship

Each of the authors has contributed to, read and approved this manuscript. All authors attest that they meet the current ICMJE criteria for Authorship.

Acknowledgements

None.

References

1. Okhravi N, Odufuwa B, McCluskey P, et al. Scleritis *Surv Ophthalmol.* 2005;50(4):351–363.
2. Ramenaden ER, Rajji VR. Clinical characteristics and visual outcomes in infectious scleritis: a review. *Clin Ophthalmol.* 2013;7:2113–2122.
3. Paula JS, Simao ML, Rocha EM, et al. Atypical pneumococcal scleritis after pterygium excision: case report and literature review. *Cornea.* 2006;25(1):115–117.
4. Hodson KL, Galor A, Karp CL, et al. Epidemiology and visual outcomes in patients with infectious scleritis. *Cornea.* 2013;32(4):466–472.
5. Gharaee H, Khalife M, Poor SS, et al. Infectious scleritis after subtenon triamcinolone acetonide injection. *Ocul Immunol Inflamm.* 2011;19(4):284–285.
6. Cunningham MA, Alexander JK, Matoba AY, et al. Management and outcome of microbial anterior scleritis. *Cornea.* 2011;30(9):1020–1023.
7. Rich RM, Smiddy WE, Davis JL. Infectious scleritis after retinal surgery. *Am J Ophthalmol.* 2008;145(4):695–699.
8. Meyer JJ, Espandar L, Marx DP, et al. Pseudomonas scleritis resistant to fourth-generation fluoroquinolones in a patient without prior trauma or surgery. *Ocul Immunol Inflamm.* 2008;16(3):127–129. LeLorier J, Gregoire G, Benhaddad A, Lapierre J, Derderian F (1997) Discrepancies between meta-analyses and subsequent large randomized, controlled trials. *N Engl J Med.* 1997;337(8):536–42.
9. Bhatt SS, Stepien KE, Joshi K. Prophylactic antibiotic use after intravitreal injection: effect on endophthalmitis rate. *Retina.* 2011;31(10):2032–2036.
10. Simunovic MP, Rush RB, Hunyor AP, et al. Endophthalmitis following intravitreal injection versus endophthalmitis following cataract surgery: clinical features, causative organisms and post-treatment outcomes. *Br J Ophthalmol.* 2012;96(6):862–886.
11. Benoit d'Azy C, Pereira B, Naughton G, et al. Antibioprophylaxis in prevention of endophthalmitis in intravitreal injection: a systematic review and meta-analysis. *PLoS One.* 2016;11(6):e0156431.
12. Moss JM, Sanislo SR, Ta CN. A prospective randomized evaluation of topical gatifloxacin on conjunctival flora in patients undergoing intravitreal injections. *Ophthalmology.* 2009;116(8):1498–1501.
13. Yin VT, Weisbrod DJ, Eng KT, et al. Antibiotic resistance of ocular surface flora with repeated use of a topical antibiotic after intravitreal injection. *JAMA Ophthalmol.* 2013;131(4):456–461.
14. Friedman DA, Mason 3rd JO, Emond T, et al. Povidone–iodine contact time and lid speculum use during intravitreal injection. *Retina.* 2013;33(5):975–981.
15. Senberg SJ, Apt L, Yoshimori R, et al. Chemical preparation of the eye in ophthalmic surgery. IV. Comparison of povidone-iodine on the conjunctiva with a prophylactic antibiotic. *Arch Ophthalmol.* 1985;103:1340–1342.
16. McCannel CA. Meta-analysis of endophthalmitis after intravitreal injection of anti-vascular endothelial growth factor agents: causative organisms and possible prevention strategies. *Retina.* 2011;31(4):654–661.
17. Wen JC, McCannel CA, Mochon AB, Garner OB. Bacterial dispersal associated with speech in the setting of intravitreal injections. *Arch Ophthalmol.* 2011;129(12):1551–1554. Garg SJ, Dollin M, Hsu J, et al. Effect of a 'No-Talking' Policy During Intravitreal Injection on Post-Injection Endophthalmitis. *Ophthalmic Surg Lasers Imaging Retina* 2015;46(10):1028–34.
18. Abell RG, Kerr NM, Allen P, et al. Intravitreal injections: is there benefit for a theatre setting? *Br J Ophthalmol.* 2012;96(12):1474–1478.