Internal Medicine
The Japanese Society of Internal Medicine

doi: 10.2169/internalmedicine.1060-18
Intern Med 57: 3551-3557, 2018
http://internmed.jp

【 CASE REPORT 】

# Coronary Artery Plaque Regression by a PCSK9 Antibody and Rosuvastatin in Double-heterozygous Familial Hypercholesterolemia with an *LDL Receptor* Mutation and a *PCSK9* V4I Mutation

Ryo Shirahama[1], Takamichi Ono[1], Suguru Nagamatsu[2], Daisuke Sueta[2], Seiji Takashio[2], Tadasuke Chitose[1], Koichiro Fujisue[2], Kenji Sakamoto[2], Eiichiro Yamamoto[2], Yasuhiro Izumiya[2], Koichi Kaikita[2], Seiji Hokimoto[2], Mika Hori[3], Mariko Harada-Shiba[3], Ichiro Kajiwara[1], Hisao Ogawa[4] and Kenichi Tsujita[2]

**Abstract:**
The low-density lipoprotein-cholesterol (LDL-C) level of a 38-year-old man diagnosed with acute coronary syndrome was 257 mg/dL. The administration of a proprotein convertase subtilisin-kexin type 9 (PCSK9) antibody in addition to rosuvastatin plus ezetimibe was initiated, reducing his LDL-C level to 37 mg/dL. A genetic analysis revealed both an *LDL receptor* (*LDLR*) mutation and a *PCSK9* V4I mutation. Nine months after revascularization, intravascular ultrasound revealed plaque regression in the coronary arteries. *LDLR*/*PCSK 9* mutation carriers are prone to coronary artery disease. Intensive LDL-C lowering by including PCSK9 antibody was associated with coronary plaque regression, suggesting the expectation of prognosis improvement.

**Key words:** Double-heterozygous familial hypercholesterolemia, PCSK9 inhibitor, plaque regression

**(Intern Med 57: 3551-3557, 2018)**
**(DOI: 10.2169/internalmedicine.1060-18)**

## Introduction

Familial hypercholesterolemia (FH) is characterized by marked hypercholesterolemia since birth, and FH patients are known to develop early coronary artery diseases (CADs) (1). Therefore, the early diagnosis of this disease is important for the prognosis.

Evolocumab (AMG-145; Repatha™, Amgen, Thousand Oaks, USA) is a monoclonal antibody that inhibits proprotein convertase subtilisin-kexin type 9 (PCSK9) and lowers the low-density lipoprotein cholesterol (LDL-C) levels (2). The Further Cardiovascular Outcomes Research with PCSK9 Inhibition in Subjects with Elevated Risk (FOURIER) trial recently revealed that the inhibition of PCSK9 with evolocumab combined with statin therapy lowered LDL-C levels and reduced the risk of cardiovascular events (3). Furthermore, the Global Assessment of Plaque Regression with a PCSK9 Antibody as Measured by Intravascular Ultrasound (GLAGOV) Randomized Clinical Trial demonstrated that the addition of evolocumab to statin therapy produced greater LDL-C-lowering effects and atheroma regression than statin monotherapy (4).

The combination of an LDL receptor (*LDLR*) gene mutation and a *PCSK9* V4I mutation in clinically diagnosed FH is a severe state and causes an individual to be prone to CAD (5). We herein report the first case of acute coronary syndrome in a double-heterozygous FH patient (*LDLR*/*PCSK9*) who received a PCSK9 antibody associated with coronary plaque regression.

[1]Department of Cardiovascular Medicine, Arao City Hospital, Japan, [2]Department of Cardiovascular Medicine, Graduate School of Medical Sciences, Kumamoto University, Japan, [3]Department of Molecular Innovation in Lipidology, National Cerebral and Cardiovascular Center Research Institute, Japan and [4]National Cerebral and Cardiovascular Center, Japan
Received for publication February 20, 2018; Accepted for publication May 10, 2018
Correspondence to Dr. Daisuke Sueta, sueta-d@kumamoto-u.ac.jp

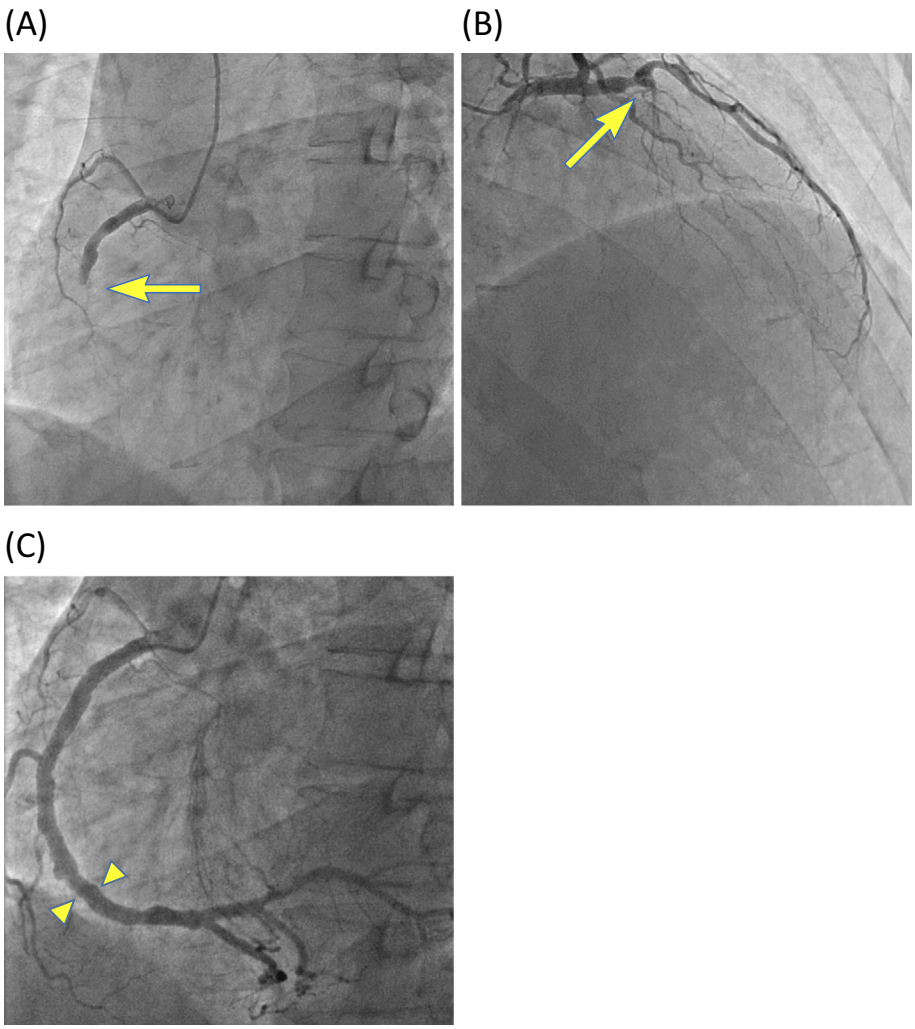


**Figure 1. Coronary angiography. (A) Total occlusion of the mid right coronary artery (arrow). (B) Total occlusion of the proximal left anterior descending coronary artery (arrow). (C) Post-stent deployment, with excellent results.**

## Case Report

A 38-year-old man was admitted to the emergency department complaining of sudden left-sided chest compression. His cardiac risk factors were dyslipidemia, current smoking status and a family history. His father had suffered from myocardial infarction at 40 years of age, and his mother and older sister showed lipid abnormalities. His body height was 176 cm, and his body weight was 75 kg. Dyslipidemia had been noted at 18 years of age. His medications included atorvastatin 10 mg daily, but his adherence was poor.

An electrocardiogram (ECG) in the emergency department showed severe ST-segment elevation in leads II, III, and aVF and depression in leads V1-V6. His echocardiogram results showed hypokinesis in the posterior wall and septum in the left ventricle. All cardiac enzyme levels, including those of troponin-T, were normal. Considering these findings, he was diagnosed with ST elevation myocardial infarction and underwent emergent coronary angiography (CAG) because his symptoms persisted and his cardiac enzyme levels had increased over time. CAG revealed occlusion of the proximal right coronary artery (RCA) and the proximal left anterior descending coronary artery (LAD) (Fig. 1A and B). ECG and echocardiogram results showed that the culprit lesion was in the RCA, as indicated by the presence of hypokinesis in its posterior wall. Therefore, a 3.5×28-mm biolimus-eluting stent (BMX-J™; Terumo, Tokyo, Japan) and a 4.0×33-mm everolimus-eluting stent (Xience Alpine ™; Abbott Vascular, Santa Clara, USA) were implanted in the RCA, generating excellent results on both angiography (Fig. 1C) and intravascular ultrasound (IVUS), without any stent edge dissection or incomplete dilatation.

At the emergency department, the patient's LDL-C, high-density lipoprotein-cholesterol (HDL-C) and triglyceride (TG) levels were 257, 38 and 378 mg/dL, respectively. These levels were measured using the direct method according to the protocol supplied by the manufacturer. This patient exhibited dyslipidemia at a young age and had a family history of dyslipidemia. According to his home doctor, the LDL-C level while untreated was 272 mg/dL. Therefore, the patient was suspected of having FH. In addition to his LDL-

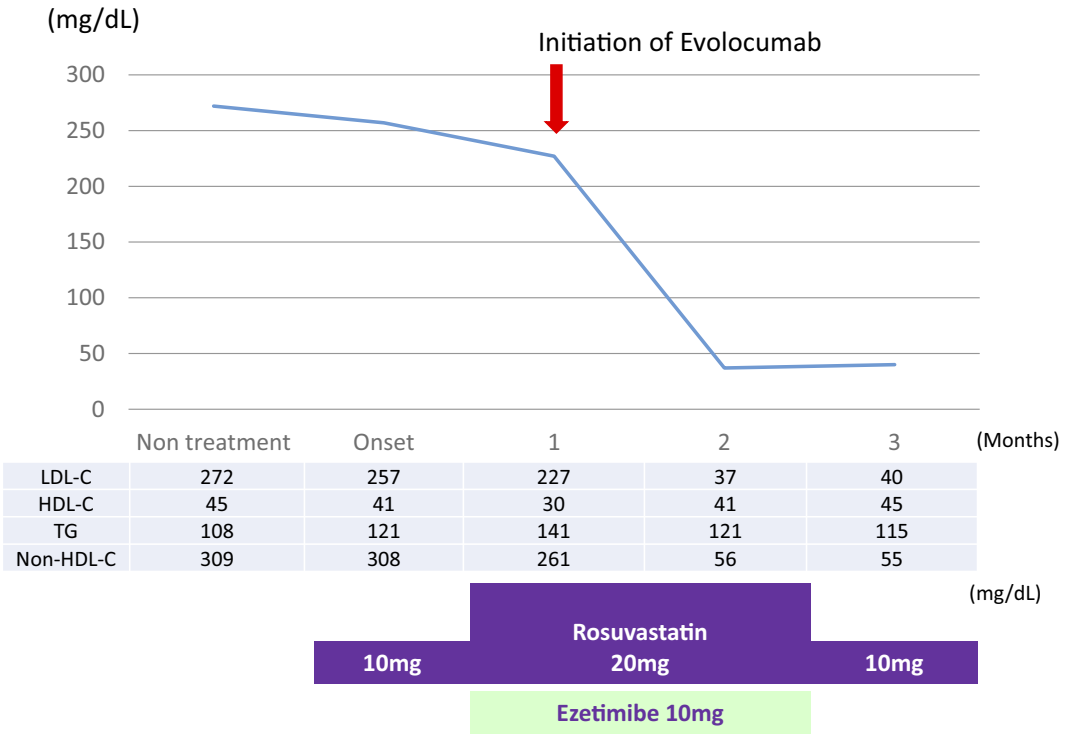


**Figure 2. Clinical courses of the LDL cholesterol concentration levels (upper panel) and detailed serial changes in the lipid parameters (lower panel). LDL: low-density lipoprotein**

C level and family history, Achilles' tendon thickening and the presence of corneal rings were observed. Achilles tendon xanthoma (right 11 mm, left 13 mm) confirmed the diagnosis of FH according to both Japanese (6) and Western (7-9) diagnostic criteria. Lipid management combined with rosuvastatin 20 mg and ezetimibe 10 mg did not achieve the target level of the guidelines (10), so a human anti-PCSK9 monoclonal antibody, evolocumab, was introduced. After 2 months, the patient's LDL-C, HDL-C and TG levels had improved to 37, 41 and 121 mg/dL, respectively, with rosuvastatin 10 mg daily and evolocumab 140 mg administered percutaneously every 2 weeks.

Detailed serial changes in the lipid parameters are shown in Fig. 2. The time of lipid measurement was just before evolocumab injection. PCSK9 antibody was initiated to achieve the target level of the guidelines. As the target level of the guideline was achieved by the introduction of PCSK9 antibody, the rosuvastatin dose was reduced and ezetimibe was withdrawn. Evolocumab is approved for subcutaneous injection at 140 mg once every 2 weeks or 420 mg once every 4 weeks; given that the effects of these approaches considered equivalent, injecting 140 mg subcutaneously once every 2 weeks is more economical.

To examine the phenotype of FH, we performed a genetic analysis as described previously (5). The genetic analysis revealed that the patient had an *LDLR* frameshift mutation (c.1655delT, p.I531TfsX15) and a *PCSK9* V4I mutation. Figs. 3 and 4 show the DNA sequence data of exon 11 of *LDLR* gene and exon 1 of *PCSK9* gene, respectively.

Three months after the initial percutaneous coronary intervention (PCI), the LAD lesion was successfully stented with a 3.0×33-mm everolimus-eluting stent (Xience Alpine™; Abbott Vascular) at a university hospital. No further stent thrombosis or stent restenosis had occurred at nine months of follow-up.

In intravascular studies, serial changes on IVUS (40-MHz Intrafocus® WR, Terumo, at the acute phase; and 60-MHz AltaView®, Terumo, at the follow-up phase) demonstrated that the percent atheroma volume (PAV) (4, 11) was decreased at 9 months (41.6%, Fig. 5D) compared with immediately after PCI (45.3%, Fig. 5B). The detailed measurement results are shown in Table. Aggressive LDL-C-lowering therapy with PCSK9 antibody plus rosuvastatin resulted in coronary plaque regression. The patient's other family members were not genotyped.

The patient provided their consent for the publication of this study. The protocol for the genetic analysis was approved by the Ethics Review Committee of the National Cerebral and Cardiovascular Center (M17-56).

## Discussion

The c.1655delT, p.I531TfsX15 mutation present in exon 11 of the *LDLR* gene detected in this report has already been reported (1). Because this mutation alters the reading frame of the codon, inducing a stop codon in the EGF precursor homology region of mature LDLR, it produces truncated LDLR protein lacking the EGF precursor homology region, the O-linked carbohydrate region, the membrane-spanning domain and the cytoplasmic-tail region. Although

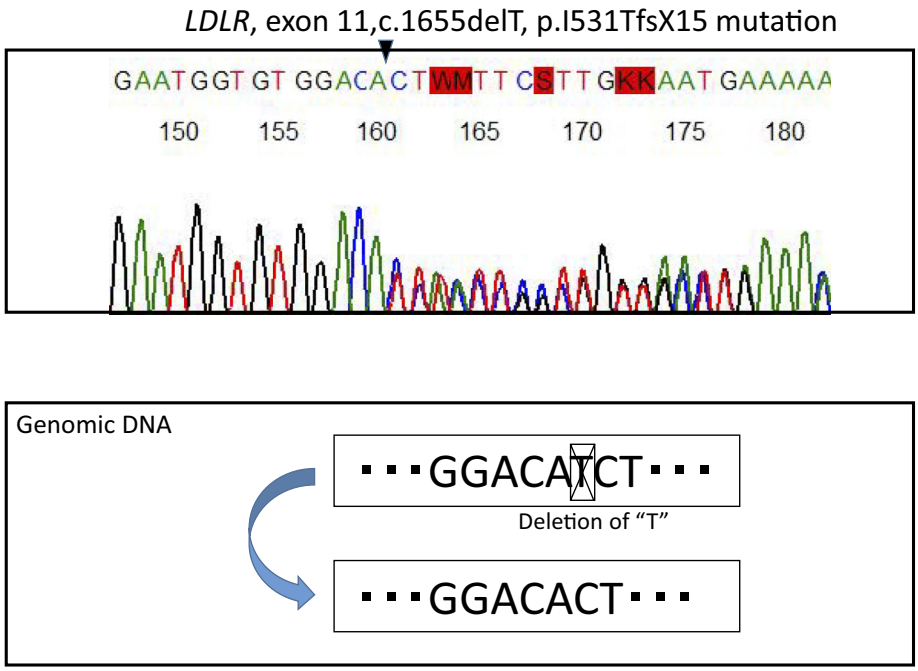


**Figure 3.** **DNA sequence data of exon 11 of *LDLR* gene. The arrowhead in the upper panel indicates the c.1655delT, p.I531TfsX15 mutation. (···ACACT···) instead of the normal subject data (···ACATCT···).**

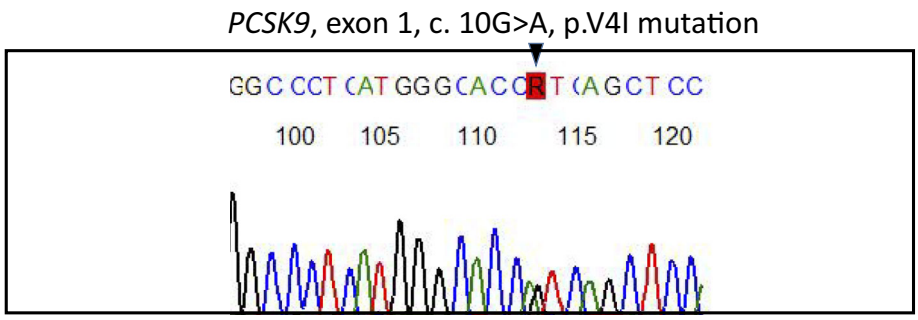


**Figure 4.** **DNA sequence data of exon 1 of the *PCSK9* gene. The arrowhead indicates the c.10G>A, p.V4I mutation [GGGCACC(G/A)TCA] instead of the normal subject data (GGGCACCGTCA).**

no functional assay has been reported for this mutation, the truncated protein is considered to lose its function as a cell surface LDLR protein (12). In addition, this mutation is defined as pathogenic in ClinVar (13). Therefore, the LDLR activity is considered to have been completely lost.

We recently reported that there were no changes in the levels of serum lipids, such as LDL-C, due to the presence or absence of V4I mutation in the *PCSK9* gene in FH heterozygotes, but patients with both V4I mutation in the *PCSK9* gene and a mutation in the *LDLR* gene showed a 30% increase in the serum untreated LDL-C level and frequency of coronary artery disease compared with patients with a mutation in the *LDLR* gene only (5). Therefore, in patients with a mutation in the *LDLR* gene, the PCSK9 V4I mutant may function as a modifier of the clinical manifestation. In addition, when we prepared a plasmid with a V4I mutation in the *PCSK9* gene, introduced it into HEK 293 cells, and compared it with a wild-type (WT) plasmid-introduced strain, we confirmed that PCSK9 V4I mutant was expressed intracellularly and secreted outside the cell, and the expression of LDLR and the uptake of LDL into the cell were also the same as with the PCSK9 WT plasmid (Hori et al. in preparation). Therefore, we believe that the presence of only the V4I mutation in the *PCSK9* gene does not affect the LDLR activity. In contrast, in patients with a truncated mutation in LDLR (resulting in half of the typical LDLR activity), overlapping of the V4I mutation in the PCSK9 gene may further reduce the LDLR activity. However, the mechanism has not been clarified.

Arteriosclerotic plaques can regress for a long time (14), according to large-scale clinical studies (15), thus verifying the close relationship between LDL-C levels and the incidence of atherosclerotic diseases and eliciting significant interest in the mechanism underlying this interaction. Further-

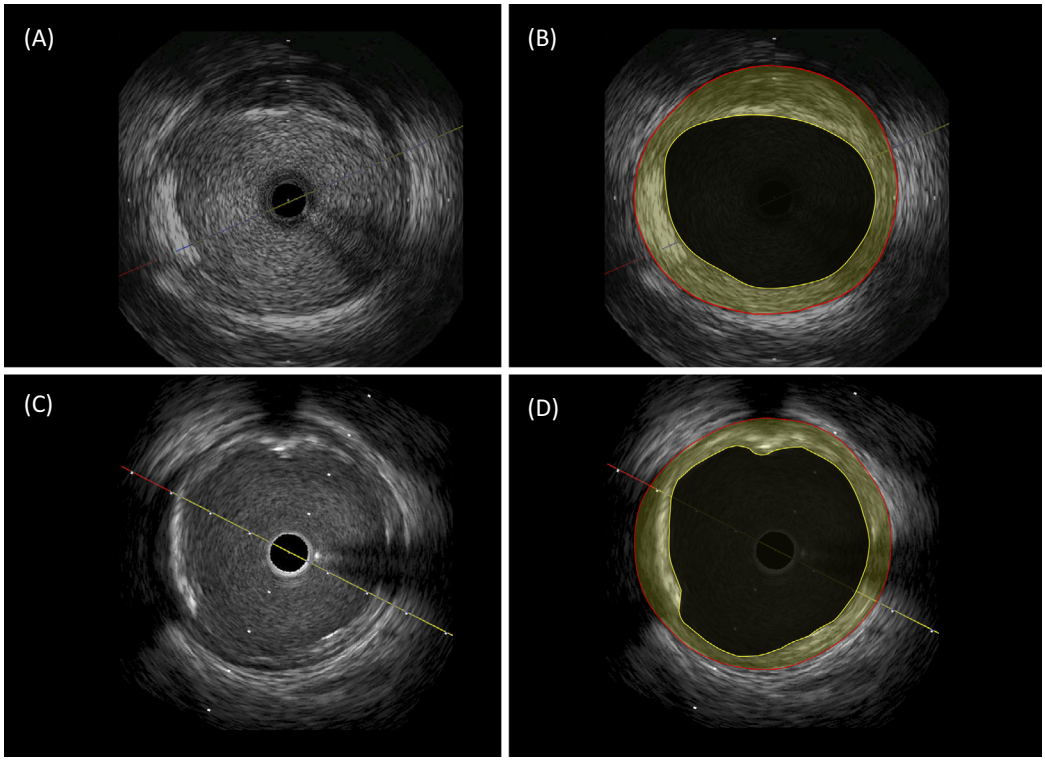


**Figure 5. (A) Intravascular ultrasound (IVUS) images (arrowhead site in Fig. 1C) immediately after PCI. (B) IVUS images (arrowhead site in Fig. 1C) immediately after PCI. The yellow zones indicate plaque. (C) IVUS images (arrowhead site in Fig. 1C) nine months after PCI. (D) IVUS images (arrowhead site in Fig. 1C) nine months after PCI. The yellow zones indicate plaque. PCI: percutaneous coronary intervention**

**Table. Detailed Measurement Results Obtained by Intravascular Ultrasounds (IVUSs).**

| Status | Lumen volume ($mm^3$) | Vessel volume ($mm^3$) | TAV ($mm^3$) | Length (mm) | PAV (%) | ΔPAV (%) | ΔTAV ($mm^3$) |
|---|---|---|---|---|---|---|---|
| initial IVUS | 145 | 264 | 120 | 10 | 45.3 | | |
| 9 months IVUS | 151 | 259 | 108 | 10 | 41.6 | -3.7 | -12 |

TAV: total atheroma volume, PAV: percent atheroma volume, ΔPAV: differences in PAV between initial and 9 month IVUS, ΔTAV: differences in TAV between initial and 9 month IVUS

more, with IVUS, changes in coronary plaques over time can be observed easily. In addition, with the introduction of statins, which can significantly improve the lipid profile, plaque regression following drug intervention has been confirmed. Recently, with the advent of intravascular endoscopy and optical coherence tomography (OCT), aspects of plaque regression have gradually become apparent. We analyzed coronary plaque progression/regression using IVUS and reported that combination therapy with a statin and ezetimibe resulted in coronary plaque regression after 9 to 12 months of treatment (11).

FH is an autosomal-dominant inherited disorder that is caused by mutations in the *LDLR* and *PCSK9* genes (16). In Japan, one FH homozygote patient is estimated per million, and one FH heterozygote patient is estimated per 500 (17). In 1973, Khachadurian et al. reported on families with a background of genetically dominant hypercholesterolemia and on those with recessive inheritance (18). In 1974, Brown and Goldstein found that genetically dominant hypercholesterolemia was caused by mutations in the *LDLR* gene, which became known as FH (19). It has become clear, however, that some patients with the FH phenotype do not exhibit mutations in the *LDLR* gene. A report in 1986 found that a mutation in the apolipoprotein B-100 (*APOB*) gene, which is a ligand for LDLR, resulted in a decreased binding affinity to LDLR and defective familial apoB-100 (FDB), producing the pathology of FH (20). Two frameshift mutations (the 5-bp insertion at codon 395 in exon 9 and the single-nucleotide deletion at codon 531 in exon 11) were detected in the mutant *LDLR* genes responsible for FH (12). In the present case, we detected the second of these two mutations by a genetic analysis. In 2003, Abifadel reported that PCSK9 is the third leading causative gene of FH (21). Conversely, autosomal recessive hypercholesterolemia (ARH) has been clarified as a genetic disease of the autosomal recessive genetic form (22, 23), and its pathogenic

genes have been reported (24).

*LDLR* gene abnormalities have been confirmed in 53% of FH patients (5). In Japan, FH due to an APOB gene abnormality has not been described. The frequency of the E32K mutation in the *PCSK9* gene has been reported to be approximately 5% in FH cases (5, 25, 26). In Western countries, the incidence of FH with a *PCSK9* gene mutation is as low as 0% to 1.5% (27, 28). However, Japan has many cases of FH due to *PCSK9* gene mutations. Indeed, in Japan, the V41 mutation of the *PCSK9* gene is relatively frequent. It has been reported that the double heterozygote combined with an *LDLR* gene mutation results in a high LDL-C level (5). We recently reported that double heterozygotes are classified as homozygotes and that evolocumab was more effective in double heterozygote cases than in other homozygote cases in a study of 106 FH homozygote cases (29).

FH results in a higher LDL-C level than non-FH with hypercholesterolemia (30), and a person with an FH-causative gene mutation has a higher risk of CAD than does a person without the mutation, even if they have similar LDL-C levels (31). CAD is believed to develop when the lifetime cumulative LDL-C level exceeds a certain level in FH patients with delayed treatment initiation and in patients with other risk factors who require stronger lipid-lowering agents (7).

Although the effects of plaque regression on other phenotypes, such as ARH, should be investigated, it is more important to note the family history and to focus on physical findings, such as Achilles tendon hypertrophy, in patients with markedly high LDL-C levels.

In a meta-analysis of clinical test results using statin preparations, a linear correlation was reported between the LDL-C levels and plaque regression, and the degree of plaque regression reportedly increased as the LDL-C levels decreased (32, 33). In the present case, using evolocumab, we reduced the LDL-C levels from 257 to 37 mg/dL. Therefore, this regression of plaque might be a natural result.

A limitation of this study was that we were unable to observe the plaque volume and characteristics using OCT. Therefore, the plaque regression that was observed using IVUS may have been reasonable. Another limitation of this study is that plaque regression by statin therapy could not be ruled out. The use of PCSK9 antibody is allowed only in combination with statin therapy, according to the Japanese health insurance system. Finally, the IVUS images from two time points were acquired at different facilities, so our analysis may not have been appropriately conducted.

To our knowledge, this is the first report of a case of reduced LDL-C levels and plaque regression in a double-heterozygous FH patient with an *LDLR* mutation and a *PCSK9* V4I mutation following treatment with PCSK9 antibody and statin.

**Author's disclosure of potential Conflicts of Interest (COI).**
Kenji Sakamoto: Research funding, Daiichi Sankyo. Koichi Kaikita: Honoraria, Bayer Yakuhin and Daiichi Sankyo; Research funding, Bayer Yakuhin, Daiichi Sankyo, Novartis Pharma and SBI Pharma. Mariko Harada-Shiba: Honoraria, Aegerion, Astellas Amgen, Astellas, Sanofi, Astrazeneca, JCR Pharm, Daiichi-Sankyo, MSD, Phizer, Torii, Shionogi and Tanabe-Mitsubishi; Research funding, Astellas, Kaneka Medics, MSD, Takeda, Asttellas Amgen and Aegerion. Kenichi Tsujita: Honoraria, Amgen Astellas BioPharma, Bayer Yakuhin, Daiichi Sankyo, MSD and Sanofi; Research funding, AstraZeneca, Astellas Pharma, Bayer Yakuhin, Boehringer Ingelheim Japan, Boston Scientific Japan, Chugai Pharmaceutical, Daiichi Sankyo, Eisai, Kowa Pharmaceutical, Mitsubishi Tanabe Pharma, MSD, Pfizer Japan, Sanofi, Shionogi and Takeda Pharmaceutical.

**Acknowledgement**
We thank all paramedical staff and clinical secretaries for their kind support during this study.

## References

1. Bujo H, Takahashi K, Saito Y, et al. Clinical features of familial hypercholesterolemia in Japan in a database from 1996-1998 by the Research Committee of the Ministry of Health, Labour and Welfare of Japan. J Atheroscler Thromb **11**: 146-151, 2004.
2. Raal F, Scott R, Somaratne R, et al. Low-density lipoprotein cholesterol-lowering effects of AMG 145, a monoclonal antibody to proprotein convertase subtilisin/kexin type 9 serine protease in patients with heterozygous familial hypercholesterolemia: the reduction of LDL-C with PCSK9 inhibition in heterozygous familial hypercholesterolemia disorder (RUTHERFORD) randomized trial. Circulation **126**: 2408-2417, 2012.
3. Sabatine MS, Giugliano RP, Keech AC, et al. Evolocumab and clinical outcomes in patients with cardiovascular disease. N Engl J Med **376**: 1713-1722, 2017.
4. Nicholls SJ, Puri R, Anderson T, et al. Effect of evolocumab on progression of coronary disease in statin-treated patients: the GLAGOV randomized clinical trial. JAMA **316**: 2373-2384, 2016.
5. Ohta N, Hori M, Takahashi A, et al. Proprotein convertase subtilisin/kexin 9 V4I variant with *LDLR* mutations modifies the phenotype of familial hypercholesterolemia. J Clin Lipidol **10**: 547-555. e55, 2016.
6. Harada-Shiba M, Arai H, Oikawa S, et al. Guidelines for the management of familial hypercholesterolemia. J Atheroscler Thromb **19**: 1043-1060, 2012.
7. Nordestgaard BG, Chapman MJ, Humphries SE, et al. Familial hypercholesterolaemia is underdiagnosed and undertreated in the general population: guidance for clinicians to prevent coronary heart disease. Eur Heart J **34**: 3478-3490, 2013.
8. Genest J, Hegele RA, Bergeron J, et al. Canadian Cardiovascular Society position statement on familial hypercholesterolemia. Can J Cardiol **30**: 1471-1481, 2014.
9. Gidding SS, Champagne MA, de Ferranti SD, et al. The agenda for familial hypercholesterolemia. Circulation **132**: 2167-2192, 2015.
10. Group JJW. Guidelines for secondary prevention of myocardial infarction (JCS 2011). Circ J **77**: 231-248, 2013.
11. Tsujita K, Sugiyama S, Sumida H, et al. Impact of dual lipid-lowering strategy with ezetimibe and atorvastatin on coronary plaque regression in patients with percutaneous coronary intervention: the multicenter randomized controlled PRECISE-IVUS trial. J Am Coll Cardiol **66**: 495-507, 2015.
12. Yamakawa-Kobayashi K, Kobayashi T, Saku K, Arakawa K, Hamaguchi H. Two novel frameshift mutations associated with the presence of direct repeats of the LDL receptor gene in familial hypercholesterolemia. Hum Genet **92**: 331-335, 1993.

**13.** ClinVar [Internet]. [cited 2018 Apr. 1]. Available from: https://www.ncbi.nlm.nih.gov/clinvar/variation/251954/
**14.** Friedman M, Byers SO, Rosenman RH. Resolution of aortic atherosclerotic infiltration in the rabbit by phosphatide infusion. Proc Soc Exp Biol Med **95**: 586-588, 1957.
**15.** Cholesterol Treatment Trialists' (CTT) Collaboration, Baigent C, Blackwell L, et al. Efficacy and safety of more intensive lowering of LDL cholesterol: a meta-analysis of data from 170,000 participants in 26 randomised trials. Lancet **376**: 1670-1681, 2010.
**16.** Mabuchi H, Nohara A, Noguchi T, et al. Molecular genetic epidemiology of homozygous familial hypercholesterolemia in the Hokuriku district of Japan. Atherosclerosis **214**: 404-407, 2011.
**17.** Japan Intractable Diseases Information Center [Internet]. [cited 2017 Oct. 1]. Available from: http://www.nanbyou.or.jp/entry/65 (in Japanese).
**18.** Khachadurian A, Uthman S. Experiences with the homozygous cases of familial hypercholesterolemia. Ann Nutr Metab **15**: 132-140, 1973.
**19.** Brown MS, Goldstein JL. Expression of the familial hypercholesterolemia gene in heterozygotes: mechanism for a dominant disorder in man. Science **185**: 61-63, 1974.
**20.** Vega G, Grundy S. *In vivo* evidence for reduced binding of low density lipoproteins to receptors as a cause of primary moderate hypercholesterolemia. J Clin Invest **78**: 1410, 1986.
**21.** Abifadel M, Varret M, Rabès JP, et al. Mutations in PCSK9 cause autosomal dominant hypercholesterolemia. Nat Genet **34**: 154-156, 2003.
**22.** Harada-Shiba M, Tajima S, Yokoyama S, et al. Siblings with normal LDL receptor activity and severe hypercholesterolemia. Arterioscler Thromb **12**: 1071-1078, 1992.
**23.** Harada-Shiba M, Takagi A, Miyamoto Y, et al. Clinical features and genetic analysis of autosomal recessive hypercholesterolemia. J Clin Endocrinol Metab **88**: 2541-2547, 2003.
**24.** Garcia CK, Wilund K, Arca M, et al. Autosomal recessive hypercholesterolemia caused by mutations in a putative LDL receptor adaptor protein. Science **292**: 1394-1398, 2001.
**25.** Noguchi T, Katsuda S, Kawashiri MA, et al. The E32K variant of PCSK9 exacerbates the phenotype of familial hypercholesterolaemia by increasing PCSK9 function and concentration in the circulation. Atherosclerosis **210**: 166-172, 2010.
**26.** Yu W, Nohara A, Higashikata T, Lu H, Inazu A, Mabuchi H. Molecular genetic analysis of familial hypercholesterolemia: spectrum and regional difference of LDL receptor gene mutations in Japanese population. Atherosclerosis **165**: 335-342, 2002.
**27.** Fouchier SW, Kastelein JJ, Defesche JC. Update of the molecular basis of familial hypercholesterolemia in The Netherlands. Hum Mutat **26**: 550-556, 2005.
**28.** Humphries SE, Whittall RA, Hubbart CS, et al. Genetic causes of familial hypercholesterolaemia in patients in the UK: relation to plasma lipid levels and coronary heart disease risk. J Med Genet **43**: 943-949, 2006.
**29.** Raal FJ, Hovingh GK, Blom D, et al. Long-term treatment with evolocumab added to conventional drug therapy, with or without apheresis, in patients with homozygous familial hypercholesterolaemia: an interim subset analysis of the open-label TAUSSIG study. Lancet Diabetes Endocrinol **5**: 280-290, 2017.
**30.** Harada-Shiba M, Arai H, Okamura T, et al. Multicenter study to determine the diagnosis criteria of heterozygous familial hypercholesterolemia in Japan. J Atheroscler Thromb **19**: 1019-1026, 2012.
**31.** Khera AV, Won HH, Peloso GM, et al. Diagnostic yield and clinical utility of sequencing familial hypercholesterolemia genes in patients with severe hypercholesterolemia. J Am Coll Cardiol **67**: 2578-2589, 2016.
**32.** Nicholls SJ, Ballantyne CM, Barter PJ, et al. Effect of two intensive statin regimens on progression of coronary disease. N Engl J Med **365**: 2078-2087, 2011.
**33.** Puri R, Nissen SE, Ballantyne CM, et al. Factors underlying regression of coronary atheroma with potent statin therapy. Eur Heart J **34**: 1818-1825, 2013.

The Internal Medicine is an Open Access journal distributed under the Creative Commons Attribution-NonCommercial-NoDerivatives 4.0 International License. To view the details of this license, please visit (https://creativecommons.org/licenses/by-nc-nd/4.0/).

© 2018 The Japanese Society of Internal Medicine
*Intern Med 57: 3551-3557, 2018*