

The Successful Treatment of Refractory Polyarteritis Nodosa Using Infliximab

Satoko Matsuo, Keigo Hayashi, Eisaku Morimoto, Ayako Kato, Ken-Ei Sada, Haruki Watanabe, Mariko Takano-Narazaki, Katsue Sunahori-Watanabe, Tomoko Kawabata and Jun Wada

Abstract

Polyarteritis nodosa (PAN), characterized by arteritis of medium-sized blood vessels, is usually treated with a combination of glucocorticoids and immunosuppressants; however, some cases are refractory to these treatments. We herein report the case of a man with PAN that was refractory to various immunosuppressive treatments, including cyclophosphamide, methotrexate, and rituximab. After infliximab (IFX) treatment was initiated, his symptoms improved dramatically and remission was maintained. IFX is considered to be an effective alternative treatment for PAN which proves to be refractory to several immunosuppressive treatments.

Key words: infliximab, polyarteritis nodosa, rituximab

(Intern Med 56: 1435-1438, 2017)

(DOI: 10.2169/internalmedicine.56.8235)

Introduction

Polyarteritis nodosa (PAN) is characterized by inflammatory necrotizing arteritis of the medium- or small-sized blood vessels (1). A combination of glucocorticoids (GC) and immunosuppressants, such as cyclophosphamide (CY) or methotrexate (MTX), is recommended as the standard treatment to induce remission of PAN; however, some cases are refractory to various immunosuppressive treatments (2). We herein report the case of a male patient who had refractory PAN. Treatment with multiple immunosuppressive drugs, including rituximab (RTX), failed to achieve remission; however, treatment with infliximab (IFX) was found to be very effective, and his symptoms improved dramatically within 3 months of the start of IFX treatment.

Case Report

A 64-year-old man visited his physician in July 2011 with a chief complaint of swelling and pain in his ankles. The symptoms worsened over time, and he was referred and ad-

mitted to our hospital 1 month later.

On physical examination, his blood pressure was 153/82 mmHg, heart rate regular (61 beats/min), and body temperature 36.7°C. His heart sounds were regular without any cardiac murmurs or rubs, and his lungs were also clear on auscultation bilaterally. His abdomen was flat and soft. He had right testicular tenderness, edema in both lower legs, ulcers on both toes, and an abnormal sensation in the left lateral lower leg. The laboratory values were as follows: WBC count, 13,450/ μ L; red blood cells, 291×10^4 / μ L; Hb, 8.1 g/dL; hematocrit, 25.3%; platelets, 65.8×10^4 / μ L; C-reactive protein, 17.83 mg/dL; creatine kinase, 28 U/L. Urinalysis results were normal. Test results for rheumatoid factor, proteinase 3-antineutrophil cytoplasmic antibodies (PR3-ANCA), and myeloperoxidase-(MPO) ANCA were all negative. Enhanced magnetic resonance imaging revealed a testicular tumor-like lesion and a slight contrast enhancement in the left anterior and posterior tibial muscles (Fig. 1). A biopsy of a skin sample taken from the left lower leg revealed fibrinoid necrosis of medium- and small-sized blood vessels and histiocyte and neutrophil infiltration around the blood vessels, indicative of PAN (Fig. 2). The results of a surgical bi-

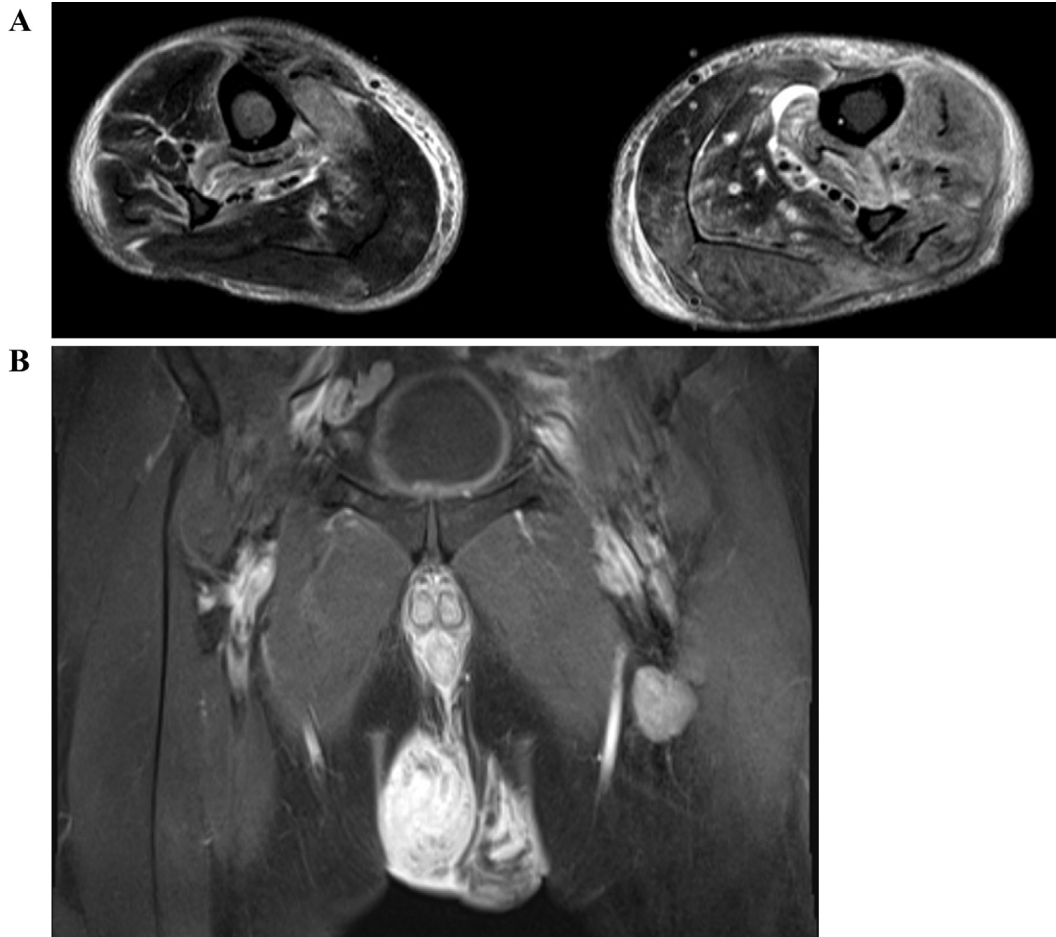


Figure 1. Magnetic resonance imaging. A: Axial short-TI inversion recovery (lower legs). B: Coronal T1 (testicles).

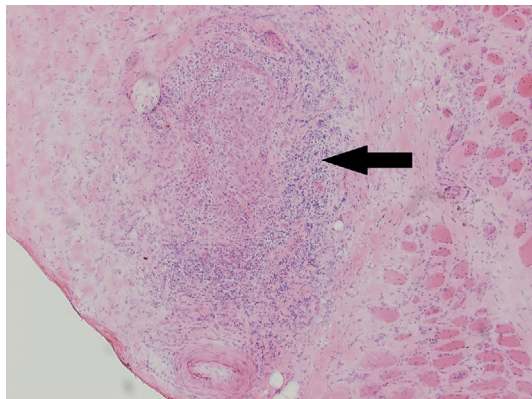


Figure 2. Histopathology of the anterior tibial muscle. Hematoxylin and Eosin staining×200. The black arrow indicates fibrinoid necrosis of small arteries with histiocytes and neutrophil infiltration around the blood vessels.

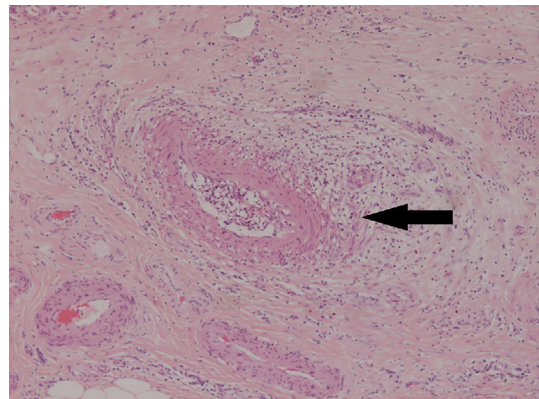


Figure 3. Histopathology of the right testicle. Hematoxylin and Eosin staining×100. The black arrow indicates fibrinoid necrosis of the small arteries with histiocytes and neutrophil infiltration around blood vessels.

opsy of the right testis also indicated PAN (Fig. 3).

In January 2012, a daily dose of prednisolone (70 mg) and concomitant administration of a weekly dose of MTX (8 mg) were initiated to induce remission. Although the leg pain and swelling improved temporarily, his symptoms relapsed in September 2012. After the second relapse while

under treatment with a combination of MTX and GC, daily oral CY was initiated in September 2014, but this treatment failed to alter the disease activity. Next, a treatment combination of CY, RTX, and tacrolimus (TAC) was initiated, but these immunosuppressive treatments were also ineffective (Fig. 4).

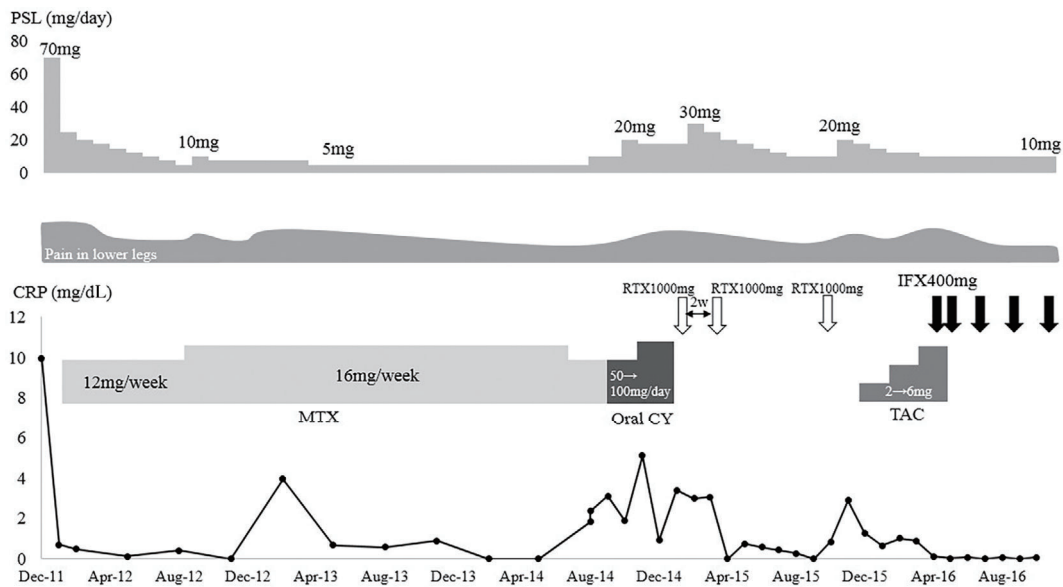


Figure 4. Clinical course. PSL: prednisolone, IFX: infliximab, RTX: rituximab, MTX: methotrexate, CY: cyclophosphamide, TAC: tacrolimus

Table. Case Reports of Refractory Adult-onset PAN Successfully Treated with Anti-TNF Treatment.

Age	Sex	Clinical symptoms	Treatment before anti-TNF treatment	Anti-TNF drug	Time from onset to anti-TNF treatment
33	F	Diarrhea, abdominal pain, livedo reticularis, polyarthralgia	GC, IVCY, IVIG, MTX, AZA	Infliximab	5 years
45	M	Spondyloarthritis, purpura	MTX, SASP	Infliximab	18 months
69	M	Purpura, renal artery aneurysm	GC, AZA, IVCY	Infliximab	6 weeks
60	F	Arthritis, purpura, livedo reticularis, subcutaneous nodules	GC, MTX, TAC, CyA, AZA, IVCY	Etanercept	7 years

GC: glucocorticoids, IVCY: intravenous cyclophosphamide, IVIG: intravenous immunoglobulin, MTX: methotrexate, AZA: azathioprine, SASP: sulfasalazine, TAC: tacrolimus, CyA: cyclosporine

Four years after the first remission induction treatment was initiated and after the fifth relapse had occurred, treatment with IFX was started in March 2016. After the administration of 400 mg (5 mg/kg) of IFX at 0, 2, and 6 weeks, 400 mg of IFX was administered every 8 weeks. Thereafter, both the clinical symptoms and laboratory values improved dramatically, and the daily prednisolone dose was later tapered to 10 mg after the third cycle of IFX treatment.

Discussion

IFX was found to be very effective in our patient who had refractory PAN, and his symptoms improved dramatically within 3 months of starting IFX treatment. This is the first report on the use of IFX to successfully treat PAN which is refractory to RTX.

GC with concomitant use of CY or MTX is recommended as a standard treatment for PAN (2), and various immunosuppressive treatments, including RTX, have been used for refractory cases (3-5).

IFX is a biological agent that neutralizes the effects of tumor necrosis factor (TNF) by blocking soluble TNF- α and binding to transmembrane TNF- α . On binding to transmem-

brane TNF- α , it destroys macrophages via complement fixation or antibody-dependent cell-mediated cytotoxicity. In patients with PAN, endothelial cell activation caused by several cytokines, such as TNF- α , interleukin (IL)-1, and interferon- γ , plays an important role in the development of vasculitis (6). A previous report showed the enhanced TNF- α gene expression in mononuclear cells from patients with PAN and granulomatosis with polyangiitis (GPA), thus indicating the importance of TNF- α in the pathogenesis of systemic vasculitis (7). In patients with GPA, autoantibody, such as anti-neutrophil cytoplasmic antibody, play a pathogenic role and therefore B cell depletion therapy is effective. Although the pathogenesis of PAN has not yet been fully elucidated, some refractory cases may not be related to humoral immunity. Therefore, IFX may be effective rather than targeting humoral immunity using immunosuppressants such as RTX.

There are a few case reports on the use of anti-TNF treatments for adult-onset PAN that was refractory to immunosuppressants, such as CY, MTX, and TAC (8-11) (Table) and our search of the literature could not find any report about PAN refractory to anti-TNF treatment, though some potential publication bias should be considered. Further,

there are reports on the use of IFX for the successful treatment of refractory childhood or juvenile PAN (12, 13). In addition, in our case, IFX was effective in the treatment of PAN which was refractory to RTX. Taken together, the previous reports and our case together suggest that anti-TNF treatment can be an alternative treatment option for refractory PAN.

In conclusion, IFX is considered to be an effective alternative treatment for PAN which is refractory to immunosuppressive treatments, including RTX.

Author's disclosure of potential Conflicts of Interest (COI).

Jun Wada: Honoraria, Astellas, Boehringer Ingelheim, Novartis, and Tanabe Mitsubishi; Research funding, Astellas, Bayer, Chugai, Daiichi Sankyo, Kissei, Kyowa Hakko Kirin, MSD, Otsuka, Teijin, Torii, Pfizer, Takeda, and Taisho Toyama.

Financial Support

This work was supported by grants from the Research Committee of Intractable Vasculitis Syndrome of the Ministry of Health, Labour, and Welfare of Japan, and the Study Group for Strategic Exploration of Drug Seeds for ANCA-associated Vasculitis and Construction of Clinical Evidence from the Japan Agency for Medical Research and Development (AMED).

References

- Jennette J, Falk R, Bacon P, et al. 2012 revised International Chapel Hill Consensus Conference Nomenclature of Vasculitides. *Arthritis Rheum* **65**: 1-11, 2013.
- Mukhtyar C, Guillevin L, Cid MC, et al. EULAR recommendations for the management of primary small and medium vessel vasculitis. *Ann Rheum Dis* **68**: 310-317, 2009.
- Pego PM, Camara IA, Andrade JP, Costa JM. Intravenous immunoglobulin therapy in vasculitic ulcers: a case of polyarteritis nodosa. *Auto Immun Highlights* **4**: 95-99, 2013.
- Seri Y, Shoda H, Hanata N, et al. A case of refractory polyarteritis nodosa successfully treated with rituximab. *Mod Rheumatol* **1-3**, 2015 (Epub ahead of print).
- Campanilho-Marques R, Ramos F, Canhao H, Fonseca JE. Remission induced by infliximab in a childhood polyarteritis nodosa refractory to conventional immunosuppression and rituximab. *Joint Bone Spine* **81**: 277-278, 2014.
- Pall AA, Savage CO. Mechanisms of endothelial cell injury in vasculitis. *Springer Semin Immunopathol* **16**: 23-37, 1994.
- Deguchi Y, Shibata N, Kishimoto S. Enhanced expression of the tumour necrosis factor/cachectin gene in peripheral blood mononuclear cells from patients with systemic vasculitis. *Clin Exp Immunol* **81**: 311-314, 1990.
- Garcia-Porrua C, Gonzalez-Gay MA. Successful response to infliximab in a patient with undifferentiated spondyloarthritis coexisting with polyarteritis nodosa-like cutaneous vasculitis. *Clin Exp Rheumatol* **21**: S138, 2003.
- Wu K, Throssell D. A new treatment for polyarteritis nodosa. *Nephrol Dial Transplant* **21**: 1710-1712, 2006.
- Al-Bishri J, le Riche N, Pope JE. Refractory polyarteritis nodosa successfully treated with infliximab. *J Rheumatol* **32**: 1371-1373, 2005.
- Zoshima T, Matsumura M, Suzuki Y, et al. A case of refractory cutaneous polyarteritis nodosa in a patient with hepatitis B carrier status successfully treated with tumor necrosis factor alpha blockade. *Mod Rheumatol* **23**: 1029-1033, 2013.
- Keystone EC. The utility of tumour necrosis factor blockade in orphan diseases. *Ann Rheum Dis* **63** (Suppl 2): ii79-ii83, 2004.
- Vega Gutierrez J, Rodriguez Prieto MA, Garcia Ruiz JM. Successful treatment of childhood cutaneous polyarteritis nodosa with infliximab. *J Eur Acad Dermatol Venereol: JEADV* **21**: 570-571, 2007.

The Internal Medicine is an Open Access article distributed under the Creative Commons Attribution-NonCommercial-NoDerivatives 4.0 International License. To view the details of this license, please visit (<https://creativecommons.org/licenses/by-nc-nd/4.0/>).