



EFFECT OF METHIMAZOLE THERAPY ON THYROID PATHOLOGY THAT MAY MIMIC THYROID MALIGNANCY

Ante Punda¹, Ana Barić¹, Zaviša Čolović², Mirko Kontić²,
Hrvoje Punda³ and Valdi Pešutić Pisac⁴

¹University Hospital of Split, Nuclear medicine department, Split, Croatia;

²University Hospital of Split, ENT department, Split, Croatia;

³University Hospital of Split, Radiology department, Split, Croatia;

⁴University Hospital of Split, Department for pathology, Split, Croatia

SUMMARY – Diffuse toxic goiter, as the most common cause of hyperthyroidism, is usually initially treated with thyrostatic drugs such as methimazole, followed by radioiodine therapy or surgery which may be indicated as definitive treatment. Radioactive iodine therapy has a known association with various histopathologic features including cytologic atypia, but herein we present a rare example of morphological thyrocyte changes induced by long-term pharmacological treatment with methimazole that mimicked thyroid malignancy in a pathohistological sample.

Key words: *hyperthyroidism, thyrostatic drugs, thyroid neoplasms*

Introduction

Diffuse toxic goiter is the most common cause of hyperthyroidism, with an overall prevalence up to 1.3% and clinical symptoms of hypermetabolism and some extrathyroidal manifestations like ophthalmopathy and dermopathy. It is an autoimmune disease caused by interplay of genetic and environmental factors, with higher incidence in women than in men [1]. Therapy includes thyrostatic drugs or radioiodine therapy and surgery if spontaneous remission is not achieved. In the past, the association of radioactive iodine therapy with various histopathologic features including cytologic atypia has been described [2-6]. In this paper, we present a rare example of morphological thyrocyte changes induced with long-term methimazole therapy that mimicked thyroid malignancy in a pathohistological sample.

Case report

A 67-year-old female patient presented with tremor, palpitations, sweating, and weight loss that lasted for 2 months; laboratory findings indicated high level of total thyroxine and triiodothyronine with suppressed TSH levels. The patient also presented with atrial fibrillation.

Thyroid ultrasound revealed diffuse thyroid goiter that indicated diffuse toxic goiter. Thyrostatic therapy was introduced as a 60 mg dose of methimazole daily for the first 7 days with gradual decrease in 10-day intervals. After 5 weeks, the patient showed good therapy response with normalization of thyroid hormone levels and clinical remission, so maintenance therapy was continued with 10 mg of methimazole daily. Two years later, the patient developed mild to severe ophthalmopathy. Despite suggestions and indications, the patient rejected surgery so methimazole therapy was continued with some relapses and dose adjustment. Four years later, the patient agreed to surgical treatment and total thyroidectomy was per-

Corresponding author: Ana Barić, MD, PhD
E-mail: ana.baaric@gmail.com

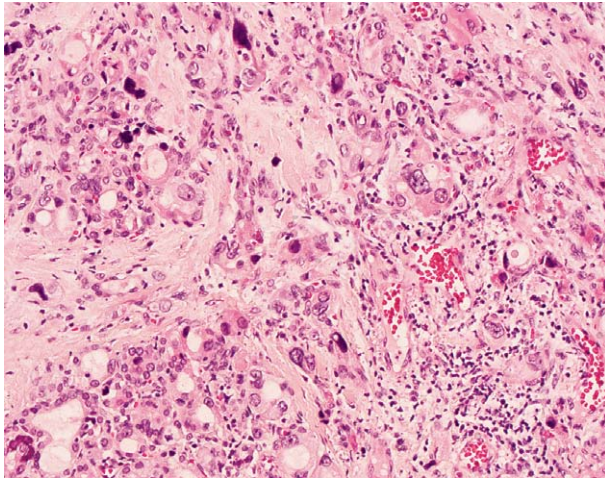


Figure 1a. High-power view showing foci of cytologic atypia (hematoxylin and eosin $\times 20$)

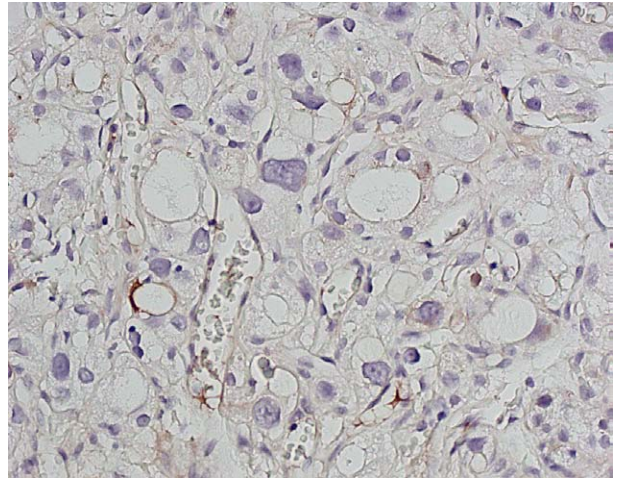


Figure 1c. Lack of Immunoreactivity for CK 19 ($\times 20$).

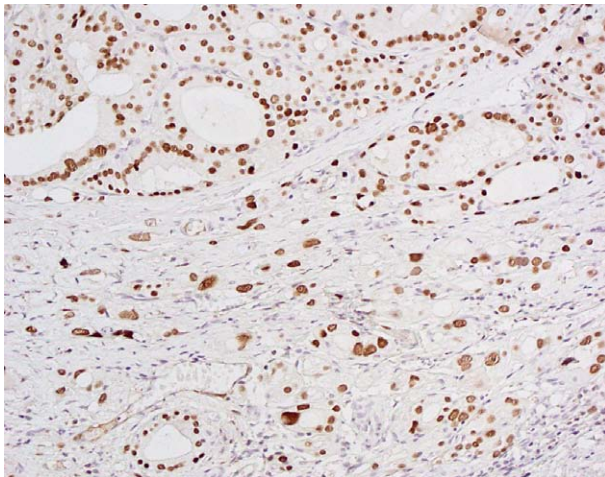


Figure 1b. Diffuse immunoreactivity for TTF-1 ($\times 20$).

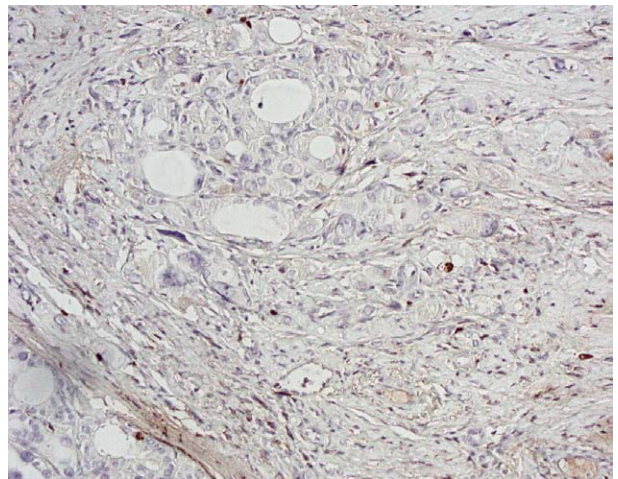


Figure 1d. Low proliferative Ki-67 index ($\times 20$).

formed. At the time of the surgery the patient was receiving a lower dose of 10-15 mg methimazole daily. In the early postoperative period, the patient presented with a complication that consisted of hemorrhage with urgent tracheotomy and 24 h mechanic ventilation and good recovery during next few days.

Histologic features

Gross features: The left lobe measured 5×4×2 cm in diameter while the right lobe measured 5×4×3 cm. Histologic features: surgically resected thyroid gland showed incomplete regression combined with hyperplastic changes. Thyroid tissue showed pronounced

nodularity accompanied with perinodular fibrosis. The amount of lighter colloid varied in different areas, and epithelial hyperplasia with focal papillary hyperplasia was observed. Psammoma bodies were also present. Follicular cells focally showed marked cellular polymorphism with nuclear atypia and hyperchromasia (Figure 1a). Immunostains revealed cells positive for TTF-1 (Figure 1b), negative for CK 19 (Figure 1c), and with proliferative activity below 5% measured by expression of the Ki-67 proliferative marker (Figure 1d).

Discussion

Our case report represents rare example of methimazole-induced morphological change in thyroid

cells that may mimic thyroid malignancy on pathohistological examination.

On a histologic basis, differential diagnosis comprised thyroid neoplasia, particularly papillary carcinoma. The morphological differentiation between these two entities, accompanied with clinical history and laboratory tests, posed a great challenge and required detailed analysis to exclude the malignancy [7,8].

Compliance with Ethical Standards:

Funding: None.

Conflict of interest: All the authors declare that they have no conflict of interest. This article does not include any studies with human participants or animals performed by any of the authors.

References

1. De Leo S, Lee SY, Braverman LE. Hyperthyroidism. *Lancet*. 2016 Aug 27;388(10047):906-918. doi: 10.1016/S0140-6736(16)00278-6.
2. Friedman NB, Catz B. The reactions of euthyroid and hyperthyroid glands to radioactive iodine. *Arch Pathol Lab Med*. 1996 Jul;120(7):660-1.
3. Mizukami Y, Michigishi T, Nonomura A, Hashimoto T, Noguchi M, Ohmura K, Matsubara F. Histologic changes in Graves' thyroid gland after 131I therapy for hyperthyroidism. *Acta Pathol Jpn*. 1992 Jun;42(6):419-26. doi: 10.1111/j.1440-1827.1992.tb03247.x
4. El Hussein S, Omarzai Y. Histologic Findings and Cytological Alterations in Thyroid Nodules After Radioactive Iodine Treatment for Graves' Disease: A Diagnostic Dilemma. *Int J Surg Pathol*. 2017 Jun;25(4):314-318. doi: 10.1177/1066896917693091.
5. Carnell NE, Valente WA. Thyroid nodules in Graves' disease: classification, characterization, and response to treatment. *Thyroid*. 1998 Jul;8(7):571-6. doi: 10.1089/thy.1998.8.571
6. Centeno BA, Szyfelbein WM, Daniels GH, Vickery AL Jr. Fine needle aspiration biopsy of the thyroid gland in patients with prior Graves' disease treated with radioactive iodine. Morphologic findings and potential pitfalls. *Acta Cytol*. 1996 Nov-Dec;40(6):1189-97. doi: 10.1159/000333979.
7. Biddinger PW: Diffuse and Nodular Hyperplasia; p 69-91. In: Nikiforov Ye, Biddinger PW, Thompson LDR. *Diagnostic Pathology and Molecular Genetics of the Thyroid*. Second edition Wolters Kluwer/Lippincott Williams&Wilkins. 2012.
8. Ranjan D, Mohan Rao B, Rao E. Carbimazole-induced histomorphological changes simulating malignancy in toxic goiter. *Thyroid Research and Practice*. 2015;12(1):29-31

Sažetak

UČINAK TERAPIJE METIMAZOLOM NA PATOHISTOLOŠKI IZGLED TKIVA ŠTITNJAČE KOJI MOŽE OPONAŠATI MALIGNNE PROMJENE

A. Punda, A. Barić, Z. Čolović, M. Kontić, H. Punda i V. Pešutić Pisac

Difuzna toksična struma, kao najučestaliji uzrok hipertireoze, se uglavnom liječi tireostaticima kao što je metimazol a nakon početne farmakološke terapije, ukoliko ne dođe do spontane remisije bolesti, liječenje se nastavlja primjenom radioaktivnog joda (I-131) ili kirurškim zahvatom.

Primjena radioaktivnog joda dovodi do brojnih histopatoloških izmjena u parenhimu štitnjače, uključujući i staničnu atipiju, no u našem radu prikazujemo rijedak slučaj utjecaja dugotrajne farmakološke terapije metimazolom na izmjenu morfologije tireocita koja može oponašati izgled malignih stanica na histološkom uzorku tkiva štitnjače.

Ključne riječi: *hipertireoza, tireostatska terapija, neoplazme štitnjače*