

# New evolution of cone-beam computed tomography in dentistry: Combining digital technologies

Supreet Jain<sup>1</sup>, Kartik Choudhary<sup>2</sup>, Ravleen Nagi<sup>3,\*</sup>, Stuti Shukla<sup>1</sup>, Navneet Kaur<sup>4</sup>, Deepak Grover<sup>4</sup>

<sup>1</sup>Department of Oral Medicine and Radiology, New Horizon Dental College and Research Institute, Sakri, Bilaspur, India

<sup>2</sup>Department of Pedodontics and Preventive Dentistry, Mansarovar Dental College, Bhopal, India

<sup>3</sup>Department of Oral Medicine and Radiology, Swami Devi Dayal Hospital and Dental College, Panchkula, India

<sup>4</sup>Department of Periodontology, National Dental College and Hospital, Dera Bassi, Mohali, India

## ABSTRACT

Panoramic radiographs and computed tomography (CT) play a paramount role in the accurate diagnosis, treatment planning, and prognostic evaluation of various complex dental pathologies. The advent of cone-beam computed tomography (CBCT) has revolutionized the practice of dentistry, and this technique is now considered the gold standard for imaging the oral and maxillofacial area due to its numerous advantages, including reductions in exposure time, radiation dose, and cost in comparison to other imaging modalities. This review highlights the broad use of CBCT in the dentomaxillofacial region, and also focuses on future software advancements that can further optimize CBCT imaging. (*Imaging Sci Dent 2019; 49: 179-90*)

**KEY WORDS:** Cone-Beam Computed Tomography; Image Quality, Perspectives; Radiography

## Introduction

Since the discovery of the X-ray, dental radiology has played a vital role as an important diagnostic adjunct to the clinical assessment of dental patients, treatment planning, and prognostic evaluation of dental diseases.<sup>1</sup> Intraoral and conventional radiographic procedures suffer from the limitations of 2-dimensional (2D) projections, which include magnification, distortion, superimposition, and misrepresentation of structures.<sup>1</sup> Cone-beam computed tomography (CBCT) presents as a separate C-arm to conventional computed tomography (CT) and it has gained broad acceptance in dentistry in the last 5 years as it generates 3-dimensional (3D) data at lower radiation dose and cost and a higher spatial resolution than conventional CT.<sup>2</sup>

CBCT has revolutionized the imaging of the maxillo-

facial region due to its wide range of applications across the fields of dentistry, ranging from diagnosis to treatment planning. However, a lack of proper education and awareness among dentists is leading to unnecessary referrals for CBCT imaging. Early CBCT machines used image intensifiers with large fields of view (FOVs), thus exposing patients to higher doses of radiation, although these doses were still less than those associated with medical CT. Recently, advances in software have enabled the optimization of CBCT scanners via improvements that reduce the radiation dose, such as the incorporation of a small FOV, pulsed radiation exposure, and collimation. In addition, CBCT exposure should be clinically justified for each patient based on the principle of keeping radiation dose “as low as reasonably achievable (ALARA),” which is supported by the American Dental Association.<sup>3</sup> CBCT should not be considered a replacement of panoramic or conventional projection radiographic applications, but rather a complementary modality used for specific applications.<sup>4</sup> This review aims to emphasize the broad nature of CBCT usage in maxillofacial imaging. Additionally, it aims to discuss the non-den-

Received December 31, 2018; Revised April 24, 2019; Accepted May 8, 2019

\*Correspondence to : Dr. Ravleen Nagi

Department of Oral Medicine and Radiology, Swami Devi Dayal Hospital and Dental College, Barwala, Panchkula, India  
Tel) 91-7999874122, E-mail) ravleennagi@yahoo.in

Copyright © 2019 by Korean Academy of Oral and Maxillofacial Radiology

This is an Open Access article distributed under the terms of the Creative Commons Attribution Non-Commercial License (<http://creativecommons.org/licenses/by-nc/3.0>) which permits unrestricted non-commercial use, distribution, and reproduction in any medium, provided the original work is properly cited.

Imaging Science in Dentistry · pISSN 2233-7822 eISSN 2233-7830

**Table 1.** Clinical applications of cone-beam computed tomography (CBCT) in dental practice

I. Dental assessment	II. Bony assessment
Normal anatomy	Normal anatomy
Impacted teeth	Alveolar bone
Root canals	Inferior alveolar canal
Pathologies	Implant assessment
Dental anomalies/malformed teeth	Other structures
Caries detection	Pathologies
Root fractures	Periapical lesions
Root resorption	Tumors
Internal resorption	Fractures
	Cleft lip and palate
	Temporomandibular joint pathosis
III. Soft tissue assessment	IV. Orthodontics
Gingival swellings	V. Forensic odontology
Salivary gland lesions	
Calcifications	

tal applications of CBCT, the recently-introduced possibility for enhancement of CBCT using artificial intelligence or machine-based learning, and the combination of CBCT with optical imaging to facilitate the better diagnosis and treatment of complex dental pathologies. In addition, this review also focuses on optimization of CBCT with the goal of reconstructing each image at a low exposure rate. Table 1 details the clinical applications of CBCT in dental practice, while Table 2 summarizes studies from the existing literature that highlight the application of this emerging 3D imaging modality in dentistry.<sup>5-14</sup>

## Applications of CBCT in dentistry

### Endodontics

Intraoral radiography is the preferred imaging method for the evaluation of endodontically treated teeth. Recently, however, CBCT has proven to be a promising diagnostic aid for complex endodontic cases, including the detection and visualization of extra canals, lateral canals, perforations, obturations, canal shape, and vertical root fractures.<sup>15-20</sup> High-resolution CBCT images, limited FOV, and small voxel sizes provide dentists better visualization of the full length of the root canal. Kottoor et al.<sup>17</sup> used CBCT to detect 7 root canals in the maxillary first molar.

CBCT has superior diagnostic efficacy in the assessment of complex dental pathologies, malformed teeth, caries extension, differentiation of periapical pathologies, external and internal root resorption, and root fractures.<sup>18-20</sup> Patel<sup>21</sup> reported a case of dens invaginatus in which a CBCT scan revealed no communication between the invagination and the main root canal, thus preventing unnecessary root canal

treatment of the concerned tooth. Akgül et al.<sup>5</sup> used CBCT scans to detect a relatively high frequency of enamel pearls in the maxillary second and third molars. Young et al.<sup>22</sup> found that 3DX high-resolution CBCT images displayed better detection of proximal surface caries extension than digital intraoral 2D images. Root fracture is the most common cause of root canal failure that cannot be seen in conventional periapical radiographs due to the superimposition of anatomical structures. Conventional CT may detect around 70% of root fractures, but the higher cost and larger amount of radiation exposure limit the use of this technology by oral radiologists. For this reason, CBCT is currently thought to be superior to CT in diagnosing root fractures, visualizing external and internal root resorption, and visualizing the repair of resorptive defects accurately and with higher resolution.<sup>23-25</sup>

### Periodontics

CBCT is a more reliable and reproducible method of assessing incipient furcation involvement, buccal and lingual periodontal bone defects, and the extent of intrabony defects than 2D radiography. Volume rendering by CBCT can facilitate the assessment of preoperative alveolar bone volume and the postoperative adequacy of bone fill. Moreover, CBCT enables an accurate assessment of the outcome of regenerative periodontal therapy and bone grafts.<sup>26-28</sup> It has been suggested that, although CBCT has significant diagnostic applications in periodontics, conventional radiography can better depict bone quality, periodontal ligament space, and bone levels; accordingly, the decision to use CBCT imaging should only be made after careful consideration of its potential risks and benefits. In addition, differences in imaging protocol parameters can affect the reproducibility and reliability of CBCT used for the measurement of alveolar bone height and thickness.<sup>28,29</sup> Peterson et al.<sup>29</sup> concluded that CBCT underestimated alveolar bone height; mean facial bone height on CBCT images ranged from  $0.33 \pm 0.78$  mm to  $0.88 \pm 1.14$  mm, which was less than the absolute bone height of  $0.56 \pm 0.35$  mm to  $1.08 \pm 0.92$  mm.

In the detection of fenestrations and dehiscence, the efficacy of CBCT was found to be poorer than that of conventional 2D radiography, although CBCT provided better image quality. It has been suggested that the lower accuracy of CBCT may be due to the presence of teeth, metallic dental fillings, or other beam-hardening artifacts. Full-scan CBCT (360°) with a 0.2-mm voxel size using a small FOV is more effective in the detection of both fenestrations and dehiscence, especially in peri-implant cases. Peterson et

**Table 2.** Studies from the existing literature showing the application of cone-beam computed tomography (CBCT) in dentistry

Authors (Year)	Intervention	Outcome	Conclusion
Akgül et al. (2012) <sup>5</sup>	Evaluation of enamel pearls using CBCT	Enamel pearls were detected in 36 subjects (4.69%). All of the enamel pearls were detected in molar teeth, with a prevalence rate of 0.83%.	CBCT is an effective tool in the assessment of the prevalence of enamel pearls compared to conventional radiography.
Villaça-Carvalho et al. (2016) <sup>6</sup>	Evaluation of the prevalence of bifid mandibular canals (BMC) using CBCT	BMC was observed in 80 cases (26.67%), of which 39 (48.75%) were in males and 41 (51.25%) in females. The right side was more frequently affected (66.67%).	The visibility of BMC was higher with CBCT imaging.
Deeb et al. (2016) <sup>7</sup>	Assessment of the necessity of CBCT in dental implant placement	Panoramic radiographs and CBCT accurately predicted implant width to within 1.5 mm of the implant in 100% of cases and length to within 1.5 mm in more than 95% of cases.	CBCT is more accurate in predicting implant length and width and the need for bone grafting procedures.
Lo Giudice et al. (2018) <sup>8</sup>	Evaluation of the accuracy of CBCT in the detection of periapical pathologies	A radiolucent area was detected in CBCT scans in 46% of cases, while the intraoral periapical X-ray was positive in only 18%.	CBCT is an essential diagnostic tool for the proper management of various endodontic problems.
Shweel et al. (2013) <sup>9</sup>	A comparison of the accuracy of CBCT and multi-detector computed tomography (MDCT) in radiological assessment of odontogenic cysts and tumors	MDCT underestimated mean depth by 1.7 mm, underestimated mean width by 0.9 mm, and overestimated mean height by 1.7 mm, whereas CBCT underestimated mean depth by 0.9 mm, underestimated mean width by 0.7 mm, and overestimated mean height by 1 mm.	CBCT was superior to MDCT for the detection of thinning and perforation of the buccal cortical plate and displacement of teeth.
Nah (2012) <sup>10</sup>	Evaluation of condylar bony changes in TMD patients using CBCT	The most frequent condylar bony change observed was sclerosis (133 joints, 30.2%), followed by surface erosion (129 joints, 29.3%), flattening of the articular surface (112 joints, 25.5%), and deviation in form (58 joints, 13.2%).	CBCT was more accurate in determining osteoarthritic condylar bony changes than conventional CT.
Nunes et al. (2011) <sup>11</sup>	Assessment of the prevalence of soft tissue calcifications in the mandible using CBCT	Soft tissue calcifications are predominant in the posterior mandible (18.9%), with no relation to sex and age. 73% were seen in patients aged 35 to 55 years old.	CBCT scans can be used to analyze the presence of soft tissue calcifications, but more research is required to prove its diagnostic utility.
Bertin et al. (2016) <sup>12</sup>	Evaluation of the accuracy of 3D CBCT in detection of non-tumor salivary gland pathologies	The main findings were stones, stenosis, dilatations, and a “dead tree” appearance of the ductal system.	CBCT sialography is a non-invasive and relatively more reliable diagnostic tool for ductal salivary diseases than conventional sialography.
de Moraes et al. (2011) <sup>13</sup>	Evaluation of craniofacial asymmetry	The right side was larger than the left for most of the 20 distances evaluated using digital 2D and CBCT imaging; perfect agreement ( $\kappa = 0.92$ ) between CBCT and the individual measurements of the human skull was observed.	CBCT can better evaluate craniofacial morphology when compared with digital 2D images.
Pinchi et al. (2015) <sup>14</sup>	Assessment of the accuracy of CBCT for age estimation via calculation of pulp volume reduction with advancing age	Pulp height proved to be a significant predictor of age ( $P < 0.001$ ). A negative correlation was found between pulpal cavity volume and advancing age.	CBCT allows accurate calculation of pulpal volume.

TMD: temporomandibular joint disorder

al.<sup>29</sup> found that CBCT overestimated the presence of dehiscence and fenestration defects, and inter-examiner reliability ranged from poor to moderate (Cohen's kappa = -0.09 to 0.66). In another study, Xu et al.<sup>30</sup> found limited diagnostic value of CBCT in clinical practice, as the technique overestimated the presence of dehiscence and fenestrations in the maxillary anterior teeth of patients with Angle class III malocclusion; however, the level of agreement between clinical examination and CBCT imaging was higher for dehiscence than fenestration. Contrary to this observation, Leung et al.<sup>31</sup> found a higher rate of diagnostic accuracy for the detection of root fenestrations than for the detection of dehiscence.

### Mandibular canal assessment

Accurate assessment of the variation and position of the inferior alveolar canal relative to the mandibular third molar roots may reduce the risk of injury to the nerve during extraction and implant placement, thus preventing further complications.<sup>32,33</sup> Panoramic imaging may be adequate when the canal is relatively distant from the third molar, but in the case of radiographic superimposition, use of a 3D imaging approach is preferable. Lee et al.<sup>34</sup> reported 4 cases and Villaco-Carvalho et al.<sup>6</sup> reported 80 cases of bifid mandibular canal visualized using CBCT imaging. Lofthag-Hansen et al.<sup>35</sup> suggested that the visibility of the mandibular canal and the marginal crest, as well as the level of observer agreement regarding the location of these structures, is higher with CBCT.

### Implantology

CBCT provides cross-sectional images in several planes that help with the accurate assessment of the height, width, and angulation of bone, as well as with visualization of the position of the inferior alveolar canal and mental foramen in the mandible and the sinus in the maxilla. In edentulous patients, CBCT provides better visualization of buccolingual alveolar ridge patterns, such as irregular, narrow crestal, or knife-edge ridge, undulating concavities, and alveolar bone quality and quantity. In many situations, CBCT implantology has minimized or eliminated the need for procedures like bone and tissue grafts, as it enables precise measurement of the distance, area, and volume of the bone in which the implant is to be placed.<sup>36,37</sup> Computer-generated surgical guides (termed stereolithographic models) can be generated using Digital Imaging and Communications in Medicine data, thus eliminating the possible inaccuracy involved in making traditional guide stents. The use of software planning prior to implant placement helps surgeons

position the implants more accurately and safely. Using this technology, minimally invasive surgery can be performed without raising a flap, thereby minimizing surgery time, postoperative pain and swelling, and recovery time. The stored information from the scan can be used pre-surgically to fabricate a master cast, and provisional restoration could be placed immediately after surgery (Teeth-in-an-Hour™; Nobel Biocare, Kloten, Switzerland).<sup>7,36-38</sup>

Studies have suggested that assessment of the course of the vascular canals in the maxillary sinus walls, as well as the distance between the sinus floor, the edentulous alveolar crest, and the vascular canal using CBCT, can prevent unnecessary bleeding during implant placement. This technique accurately measures the thickness of the hard palate and its overlying mucosa for the purpose of miniscrew placement.<sup>39,40</sup> However, the American Academy of Radiologists (AAOR) has recommended panoramic radiography as the primary imaging modality for the initial assessment of the implant site. Cross-sectional CBCT images should be considered only when clinical conditions require sinus augmentation procedures or bone grafting, or if the patient reports implant mobility post-surgery.<sup>39</sup>

### Periapical and bony pathologies

The literature confirms that CBCT has higher diagnostic accuracy for the visualization of periapical lesions and their differentiation from other similar-appearing lesions.<sup>41</sup> In clinical practice, radiological evaluation of periapical status is essential for both establishment of a treatment plan and better prognosis of the tooth. Intraoral periapical radiographs are routinely used in endodontics, but they present some limitations, such as the 2D nature of the produced images, geometric compression, and superimposition of anatomical structures, thus obscuring the area of interest; these limitations may lead to misdiagnosis or unnecessary exposure to radiation.<sup>8,42</sup> New CBCT scanners that deliver a lower radiation dose have become an important diagnostic tool to address most endodontic problems, and these devices can be used in all phases of endodontic treatment. CBCT imaging is highly useful in the post-treatment assessment of endodontically treated teeth; it is also very helpful for the determination of the cause of a persistent periapical lesion, as well as the visualization of root canal morphology, the localization of accessory canals and calcified canals, the detection of acute root fractures, and the visualization of external and internal resorption.<sup>36-39</sup> According to the recommendations put forth by the American Academy of Oral and Maxillofacial Radiology (AAOMR) for endodontic treatment, intraoral radiography should

be considered the primary imaging modality, and CBCT should be recommended only if the patient's condition cannot be accurately diagnosed using intraoral 2D radiography or the patient presents with non-specific clinical signs and symptoms associated with untreated or endodontically treated teeth.<sup>35,36</sup> CBCT defines the extent and internal structure of large intraosseous pathologies such as cysts and tumors more precisely than intraoral radiography and also effectively analyzes the proximity of these lesions to vital structures.<sup>9</sup> Thus, CBCT images can serve as a useful guide for surgeons as they carry out appropriate early surgical interventions, especially in the treatment of oral malignancies.<sup>43</sup>

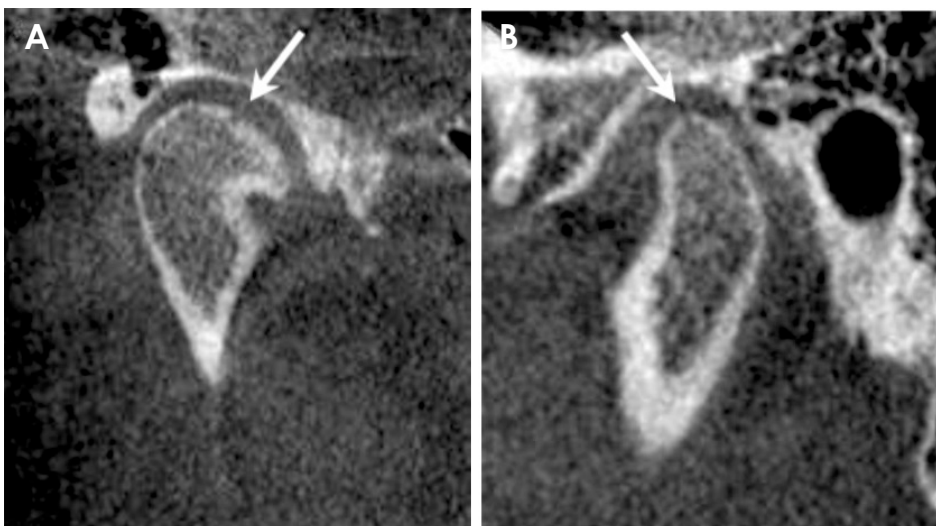
### Maxillofacial fractures

Evaluation of a fracture - especially in the maxillary complex region - using conventional 2D radiography is very challenging due to the overlapping of various structures. Additionally, radiographic evaluation of patients with maxillofacial injuries can be very difficult due to their clinical condition and the fact that these patients are often uncooperative. Instead, 3D CBCT is a cost- and dose-effective alternative to conventional 2D imaging for the diagnosis of complex maxillary fractures.<sup>44</sup> It provides the surgeon with 3D-reconstructed images for analysis of the nature of the injury, the location of the fracture, and the degree of displacement of the fractured segments. These images guide the surgeon to plan the appropriate surgical approach for the reduction and stabilization of the fractured segments.<sup>45</sup> Mandibular fractures are easily visualized on a panoramic radiograph in most cases; however, some cases require further confirmation by CBCT, including dislocation of fracture fragments in the mandibular corpus and

split fractures in which the fracture line is not parallel to the X-ray beam.<sup>46</sup> To facilitate better treatment of trauma patients, CBCT should be made mandatory in maxillofacial and suspected mandibular fractures. This technique should be used in conjunction with panoramic radiographs, which are useful for the initial screening of complicated fractures.<sup>45,46</sup>

### Temporomandibular joint disorders

Temporomandibular joint disorders (TMDs) constitute the most common category of orofacial pain conditions of the temporomandibular joint (TMJ) and its associated musculature.<sup>47</sup> As of now, CBCT has been found to be most useful in the evaluation of bony changes of the TMJ, such as fractures, ankylosis, dislocation, growth abnormalities, and various degenerative joint diseases including osteophytes, erosions, flattening, subchondral sclerosis, and pseudocysts (Fig. 1). Analysis of the dynamic relationship of the articular surfaces of the TMJ is necessary to determine the strain undergone by the articular disc while chewing; this strain, if high, may compromise the integrity of the disc. CBCT provides 3D images of the mandibular condyle and surrounding structures to facilitate the analysis and diagnosis of bone morphological features, joint space, and the dynamic function, which serve as the critical keys to treatment outcome in patients with signs and symptoms of TMD.<sup>10,47,48</sup> Studies have suggested that the diagnostic accuracy of CBCT in the evaluation of erosive changes of the condyle is influenced by FOV, with these studies utilizing FOVs of 12, 9, and 6 inches with voxel sizes of 0.6, 0.3, and 0.2 mm, respectively. It has been reported that a CBCT scanner with high resolution and the smallest FOV (voxel size, 0.2 mm) detected condylar defects with greater than



**Fig. 1.** Cone-beam computed tomographic (CBCT) images depict condylar erosion as a small circular radiolucency in a patient with temporomandibular joint arthralgia.

80% sensitivity.<sup>48</sup> Previous studies have shown magnetic resonance imaging (MRI) to be the preferred imaging modality for evaluation of anterior disc displacement without reduction, but this technique has low accuracy in diagnosing bony changes, which should be further examined using CBCT.<sup>47</sup> Recently, automatic registration of CBCT scans with MRI has been developed to provide complementary images of the hard and soft tissues of the TMJ in a single picture frame, facilitating accurate diagnosis and optimal treatment outcomes. Al-Saleh et al.<sup>49</sup> found that fused magnetic resonance imaging-cone-beam computed tomography (MRI-CBCT) registered images improved intra- and inter-examiner consistency and displayed better diagnostic value in the evaluation of internal derangement of the TMJ. More clinical research must be conducted to establish the reliability and accuracy of MRI-CBCT registration for TMDs.

#### Soft tissue assessment

In dentistry, CBCT scanners are exclusively used for imaging of the hard tissues of the oro-facial complex. These scanners have a limited ability to differentiate soft tissues. To address this issue, Januario et al.<sup>50</sup> developed soft tissue CBCT that scanned the maxilla using an i-CAT<sup>TM</sup> scanner (Imaging Sciences International, Hatfield, PA, USA) for 40 seconds with a focal spot of 0.5 mm, voxel size of 0.2 mm, and grayscale 14-bit resolution. This technique improved the image quality of the soft tissue by reconstructing the images in all 3 orthogonal planes (axial, sagittal, and coronal). It allowed precise measurement of the thickness of gingival tissues, and i-CAT<sup>TM</sup> software was used to determine the relationship of the periodontal structures and dentogingival unit. According to the guidelines set forth by the AAOR, CBCT constitutes a valuable tool for determining the location of soft tissue calcifications by oral and maxillofacial radiology specialists.<sup>51,52</sup> Soft tissue calcifications are usually asymptomatic and appear incidentally on radiographs. One of the greatest difficulties in the diagnosis of soft tissue calcifications is the determination of their exact location. This is especially challenging when using panoramic radiographs, since 2D imaging techniques can create ghost images.<sup>52,53</sup> Nunes et al.<sup>11</sup> reported that a higher prevalence of soft tissue calcifications was found on CBCT images as compared to conventional images.

#### Salivary gland pathologies

Imaging-based diagnostic measures for sialolithiasis include ultrasonography, panoramic radiography, sialendoscopy, sialography, MRI, and CT. Although CT and MRI

are more advantageous in salivary gland evaluation, ultrasonography and 2D radiography are routinely used due to their cost-effectiveness and availability. Recently, superimposition-free, 3D CBCT images have shown higher sensitivity and specificity for salivary calculus diagnosis, stenosis, and dilatations of the salivary ductal system than images obtained with other diagnostic methods.<sup>12,54,55</sup> CBCT sialography is considered a noninvasive diagnostic tool used for the visualization of salivary glands and ductal pathologies. Drage and Brown<sup>54</sup> first described the use of CBCT sialography for complex cases of salivary gland obstruction. They proposed that CBCT sialography would expose the patient to higher radiation doses than plain film sialography, and therefore it should be reserved for complicated cases. Jadu et al.<sup>55</sup> suggested that the delicate secretory branches of salivary gland ducts and the parenchyma of the salivary glands were more easily detectable on CBCT images via the maximization of the image signal difference-to-noise ratio. They achieved moderate to very good inter-observer agreement in the visualization of normal gland structures and in the determination of abnormal findings (i.e., sialoliths, ductal strictures, and secondary inflammatory changes) by CBCT sialography than plain film sialography.

#### Orthodontics

Orthodontists routinely use 2D conventional radiographs (such as cephalometric and panoramic radiographs) to diagnose and plan treatment for patients with malocclusions and facial disproportions. However, many complex orthodontic and dentofacial orthopedic problems require 3D analysis. To address this, CBCT has been introduced as a technique for comprehensive orthodontic imaging and for the assessment of tooth movement in all 3 planes.<sup>3</sup> Although it has numerous benefits, one major concern regarding CBCT is the higher radiation dose delivered from CBCT scanners with large FOV. Therefore, the decision to conduct CBCT imaging on an orthodontic patient should be solely based on the patient's history and on the clinical examination, where CBCT should only be used if these factors indicate that CBCT is required for proper diagnosis and optimal treatment outcome. Some CBCT scanners have a small FOV, which minimizes radiation exposure; in these scanners, the number of projection images still allows for adequate visualization of the region of interest.<sup>56,57</sup>

CBCT imaging in orthodontics is selectively indicated for the assessment of complex dentoskeletal relationships and facial esthetics, for severe skeletal discrepancies requiring orthognathic surgery, and for the assessment of the

position of impacted and supernumerary teeth and their relationships to adjacent roots and other anatomical structures, thus facilitating planning of the subsequent tooth movement.<sup>56</sup> Compared to 2D radiographs, CBCT imaging better facilitates the accurate determination of tooth and root length, the assessment of the minute details of root resorption, the determination of available bone width (to evaluate the buccolingual movement of teeth), the assessment of tooth inclination, the calculation of torque, and the visualization of soft tissue relationships, and it provides detailed information regarding craniofacial morphology and maxillary and mandibular changes resulting from rapid maxillary expansion.<sup>57</sup>

### Forensic odontology

Estimation of the ages of living or deceased individuals is an important aspect of forensic investigation. Several techniques to estimate the age of individuals by analyzing teeth have been reported in the literature. One avenue that offers new opportunities in dental age identification is examination of the pulp space. Various methods have been developed to study the size of the pulp chamber, including tooth cross-sections and radiographs; however, CBCT provides a 3D view of the pulpal cavity, facilitating a more accurate estimation of the dental age of an individual. CBCT is a reliable imaging technique for the analysis of secondary dentin apposition with advancing age, and it simultaneously measures both the buccolingual and the mesiodistal dimensions of the tooth.<sup>14,58</sup> Yang et al.<sup>58</sup> developed a custom-made voxel-counting software that can be used to calculate the ratio of pulp canal volume to tooth volume based on CBCT tooth images, and they obtained promising results for non-invasive dental age estimation. CBCT also provides accurate and reliable measurements of soft tissue thickness for specific landmarks of the face and scalp by producing facial reconstruction at reduced exposure and increased speed, and it provides higher-quality images than spiral CT and other methods. Facial reconstruction requires knowledge of the average thickness of the soft tissues of the face, which varies among individuals from different geographical locations. This technique is very useful in forensic investigations for the identification of skeletal remains, and it aims to recreate the facial appearance of an individual using the skull.<sup>13,59</sup>

CBCT is currently used in forensic investigations for postmortem imaging and for imaging high-density metal projectiles in cases of gunshot injury. Its use is mainly due to its small apparatus size, portability, low cost, and the reduction of metal artifacts on the images that it provides.

CBCT showed superior results to multidetector CT in the detection of structural hard-tissue damage in the immediate vicinity of high-density metal projectiles and in the identification of the precise location of a projectile in the body.<sup>60</sup>

## Future perspectives

### Optimization of CBCT images

Compared with other modalities, CBCT has been documented to have high diagnostic efficacy in the accurate detection of complex oral and maxillofacial pathologies. This efficacy could be increased further by the optimization of CBCT with respect to various parameters, such as reduction in focal spot size, alteration of beam geometry, an increase in detector efficiency, and optimization of exposure and image reconstruction. Moreover, old CBCT scanners mostly have large FOV that results in the production of more scattered radiation, which contributes to an increased radiation dose delivered to the patient. Optimization of old scanners could be achieved by using a small-diameter FOV that covers only the region of interest.<sup>61</sup> Table 3 shows the future innovations of CBCT.

Focal spot size was the first parameter of CBCT to be improved; it was decreased from the standard focal spot size of 0.5 mm, thus improving the image resolution. Another important improvement was the development of adaptive exposure, which enables the clinician to select the optimal exposure according to the size of the patient. In most CBCT machines, current and tube voltage is determined based on the gray values of scout images, which results in an automatic reduction of exposure levels for patients of small size and mass. Recently, some machines have utilized the concept of dynamic automatic exposure control, in which exposure is adjusted during acquisition of the image. Image performance could be increased by altering the geometric shape of the beam; this has been achieved by a technique termed off-axis scanning, which utilizes a half cone with a small overlap in the iso-center that increases the FOV to almost twice the diameter as that involved in full-cone scanning. This contributes to a reduction in the dose administered to the patient. It has also been reported that use of 180° rotation in comparison to 360° rotation led to a dose reduction of 40% in the anterior region and 60% in the posterior region. Off-axis scanning reduces the radiation dose, but its effect on image quality is still under study. Optimization could also be obtained by increasing the efficiency of the detector. Because most CBCT units use flat panel detectors consisting of a scintillator that transfers light energy into electrical energy, detector efficiency could

**Table 3.** Future innovations of cone-beam computed tomography (CBCT)

CBCT optimization	Real-time dual-energy imaging	Optical imaging	Non-dental applications	Phase contrast
Reduction of focal spot size Optimal exposure, automatic exposure control based on scout image and dynamic automatic exposure control Alteration of beam geometric shape <ul style="list-style-type: none"> <li>– Triangular, small field of view</li> <li>– 180° rotation</li> </ul> Increased detector efficiency Increased temporal resolution Optimal image reconstruction and interpretation <ul style="list-style-type: none"> <li>– Algebraic reconstruction technique</li> <li>– Metal artifact reduction</li> <li>– Motion detection and reduction</li> <li>– Artificial intelligence</li> <li>– Graphic processing unit</li> </ul>	Energy-selective imaging Beam hardening Artifact reduction	Intraoral optical scanners merged with CBCT Facial scanning merged with CBCT	Ear and sinus infections Tumors of the skull base Upper airway dimensional analysis Orthopedic imaging to detect skeletal abnormalities	Image reconstruction based on phase nature of X-rays increases soft tissue contrast

be increased by decreasing the detector pixel size. In addition, doing this increases the temporal resolution, resulting in a shorter scan time and an improvement in image reconstruction.<sup>1,61</sup>

Several CBCT devices use pulsed exposure, resulting in a large discrepancy between scan time (the time between the first and last projection) and exposure time (the cumulative time over which an exposure is made). In contrast, some machines allow only continuous exposure, for which the total scan time and the exposure time are same. Pulsed X-ray systems have better spatial resolution than systems that rely on continuous exposure, owing to a reduced motion effect due to the movement of the gantry during each exposure in pulsed systems.<sup>3,62</sup>

Image reconstruction has been revolutionized by the use of the algebraic reconstruction technique, which requires almost half the number of projection images than that required by the Feldkamp algorithm. The algebraic reconstruction technique is most commonly combined with the metal artifact reduction algorithm, which reduces large amounts of scatter and absorption during the scan. One drawback of the algebraic reconstruction technique is its long computation time, which results in patient motion artifacts that have been reported to have a profound effect on the quality of the CBCT images. Motion artifacts can be corrected by comparing the consecutive projection images and removing those images which are non-diagnostic due to the patient’s movement during the scan.<sup>60</sup> Other recent software advancements involve artificial intelligence or machine-based learning, particularly the training and programming of machines to read radiographs and to predict the location of pathologies. Hiraiwa et al.<sup>63</sup> applied deep-learning artificial intelligence to panoramic images of the mandibular first molar in which CBCT imaging had determined the presence of extra roots in 21.4% of the distal roots imaged. The artificial intelligence system displayed a diagnostic accuracy of 86.9% in the determination of whether the distal root was single or had extra roots. In the very near future, deep learning image analysis tools aim to improve the diagnosis of and treatment plans for periodontal diseases via detection of early bone loss and changes, early intervention of peri-implantitis, and even detection of early-stage oral cancer. Furthermore, to improve reconstruction efficiency, the standard filtered back projection method has been optimized by GPUs. Noel et al.<sup>64</sup> found that computation time for 256 volumes was reduced from 25 minutes (using the standard reconstruction algorithm) to 3.2 seconds using GPU reconstruction, and GPU reconstruction time for 512 volumes was 8.5 seconds.



Another recent innovation is real-time dual-energy imaging, in which 2 sets of projections are made at 2 different energies. This allows broadening of the contrast range. Real-time dual-energy imaging has been applied in angiography due to its reduction of the superimposition of bone and blood vessels. Moreover, this technique reduces beam-hardening artifacts and provides energy-selective imaging. Although its application in dentistry still needs to be validated, it has the potential to improve contrast-based imaging, CBCT sialography, and the accurate identification of sialoliths based on their composition.<sup>61</sup>

### Optical scanners with CBCT

Recently, the diagnostic process has been enhanced by the introduction of optical scanners, and combination of these techniques with CBCT could lead to improved treatment planning. Although CBCT can provide cross-sectional 3D images of the maxilla and the mandible for implant surgery, it cannot replicate the surface details and occlusal morphology of teeth. This task is accomplished by placing a stone cast into an optical scanner and then into a CBCT machine with same settings as the patient's scan; alternatively, intraoral scanners could be used to take virtual impressions of the occlusal surfaces of the teeth, thus precluding the use of regular impression materials. These digital technologies allow the clinician to clearly visualize the patient's anatomy when planning minimally invasive surgery.<sup>65</sup> Another software advancement has merged optical facial scanning with CBCT, with the aim of evaluating the effect of orthodontic treatment or orthognathic surgery on the facial structures. However, this 3D representation of facial features should be validated by future clinical trials.<sup>62,65</sup>

### Non-odontogenic pathologies

While CBCT scans were initially used exclusively for imaging the dentomaxillofacial complex, the use of this technique has expanded to include the visualization of non-tooth-related pathologies and abnormalities in the head and neck region, mainly sinus pathologies, such as mucosal thickening, partial opacification with liquid accumulation, total opacification, and polypoidal mucosal thickening. Low-dose multidetector CT has long been used to image the sinuses, but this technique has several limitations. For instance, the resultant images are usually noisy due to metal artifacts, and they have lower spatial resolution. CBCT images provide complete diagnostic information regarding sinus pathologies with higher spatial resolution than multi-

detector computed tomography.<sup>61,66</sup>

Tumors of the skull base are better visualized with MRI than with CBCT, but CBCT does play a crucial role in the detection of calcification processes, as well as in situations requiring sinus lifting or bone augmentation procedures. In addition, CBCT is used for 3D analysis of the upper airway dimensions of patients with cleft lip and palate or obstructive sleep apnea. CBCT scanning can also be used to assess swallowing function, particularly in cases when videofluoroscopy is not available. It is now increasingly used by orthopedic surgeons to image the upper and lower extremities, as well as by ENT clinicians to analyze sinus and ear infections at a low dose of radiation.<sup>66</sup>

### Phase contrast tomography

The literature includes numerous studies investigating the X-ray absorption of the object under study in phase contrast tomography, but the phase nature of the X-rays still requires further exploration. Recently, researchers have introduced quantitative phase-contrast cone-beam tomography, in which the phase coefficient rather than the attenuation coefficient is used to reconstruct the image. This technique utilizes unfiltered radiation from a small polychromatic source, thus reducing high spatial frequency noise and contributing to high soft tissue contrast.<sup>61,67</sup>

## Discussion

CBCT has proven to be a promising advancement in imaging of the oral and maxillofacial region due to its many advantages compared with conventional CT, including lower cost, smaller radiation dose, and the need for less space. CBCT scanning is associated with a few disadvantages, including poor soft tissue contrast, image noise, and the presence of motion artifacts. However, the potential benefits of CBCT outweigh the risks. Future efforts to improve this technique should most likely be directed towards reducing the scan time; providing multimodal imaging (conventional panoramic and cephalometric, in addition to CBCT imaging); improving image fidelity, including soft tissue contrast; and incorporating task-specific protocols to minimize patient dose (for example, high-resolution, small FOV, or medium-resolution imaging for dentoalveolar imaging, or large FOV for dentofacial orthopedic imaging). The combination of CBCT with optical imaging and phase contrast tomography, as well as the extension of its application for non-dental pathologies would be revolutionary steps in the coming decades.

## References

1. White SC, Pharoah MJ. The evolution and application of dental maxillofacial imaging modalities. *Dent Clin North Am* 2008; 52: 689-705.
2. Miracle AC, Mukherji SK. Conebeam CT of the head and neck, part 1: physical principles. *AJNR Am J Neuroradiol* 2009; 30: 1088-95.
3. American Academy of Oral and Maxillofacial Radiology. Clinical recommendations regarding use of cone beam computed tomography in orthodontics. [corrected]. Position statement by the American Academy of Oral and Maxillofacial Radiology. *Oral Surg Oral Med Oral Pathol Oral Radiol* 2013; 116: 238-57.
4. Jung YH, Liang H, Benson BW, Flint DJ, Cho BH. The assessment of impacted maxillary canine position with panoramic radiography and cone beam CT. *Dentomaxillofac Radiol* 2012; 41: 356-60.
5. Akgül N, Caglayan F, Durna N, Sümbüllü MA, Akgül HM, Durna D. Evaluation of enamel pearls by cone-beam computed tomography (CBCT). *Med Oral Patol Oral Cir Bucal* 2012; 17: e218-22.
6. Villaca-Carvalho MF, Manhaes LR Jr, de Moraes ME, Lopes SL. Prevalence of bifid mandibular canals by cone beam computed tomography. *Oral Maxillofac Surg* 2016; 20: 289-94.
7. Deeb G, Antonos L, Tack S, Carrico C, Laskin D, Deeb JG. Is cone-beam computed tomography always necessary for dental implant placement? *J Oral Maxillofac Surg* 2017; 75: 285-9.
8. Lo Giudice R, Nicita F, Puleio F, Alibrandi A, Cervino G, Lizio AS, et al. Accuracy of periapical radiography and CBCT in endodontic evaluation. *Int J Dent* 2018; 2018: 2514243.
9. Shweel M, Amer MI, El-shamhory AF. A comparative study of cone-beam CT and multidetector CT in the preoperative assessment of odontogenic cysts and tumors. *Egypt J Radiol Nuclear Med* 2013; 44: 23-32.
10. Nah KS. Condylar bony changes in patients with temporomandibular disorders: a CBCT study. *Imaging Sci Dent* 2012; 42: 249-53.
11. Nunes LF, Santos KC, Junqueira JL, Oliveira JX. Prevalence of soft tissue calcifications in cone beam computed tomography images of the mandible. *Rev Odonto Ciênc* 2011; 26: 297-303.
12. Bertin H, Bonnet R, Delemazure AS, Mourrain-Langlois E, Mercier J, Corre P. Three-dimensional cone-beam CT sialography in non tumour salivary pathologies: procedure and results. *Dentomaxillofac Radiol* 2017; 46: 20150431.
13. de Moraes ME, Hollender LG, Chen CS, Moraes LC, Balducci I. Evaluating craniofacial asymmetry with digital cephalometric images and cone-beam computed tomography. *Am J Orthod Dentofacial Orthop* 2011; 139: e523-31.
14. Pinchi V, Pradella F, Buti J, Baldinotti C, Focardi M, Norelli GA. A new age estimation procedure based on the 3D CBCT study of the pulp cavity and hard tissues of the teeth for forensic purposes: a pilot study. *J Forensic Leg Med* 2015; 36: 150-7.
15. Tyndall DA, Rathore S. Cone-beam CT diagnostic applications: caries, periodontal bone assessment, and endodontic applications. *Dent Clin North Am* 2008; 52: 825-41.
16. Tu MG, Huang HL, Hsue SS, Hsu JT, Chen SY, Jou MJ, et al. Detection of permanent three-rooted mandibular first molars by cone-beam computed tomography imaging in Taiwanese individuals. *J Endod* 2009; 35: 503-7.
17. Kottoor J, Velmurugan N, Sudha R, Hemamalathi S. Maxillary first molar with seven root canals diagnosed with cone-beam computed tomography scanning: a case report. *J Endod* 2010; 36: 915-21.
18. La SH, Jung DH, Kim EC, Min KS. Identification of independent middle mesial canal in mandibular first molar using cone-beam computed tomography imaging. *J Endod* 2010; 36: 542-5.
19. Lauber R, Bornstein MM, von Arx T. Cone beam computed tomography in mandibular molars referred for apical surgery. *Schweiz Monatsschr Zahnmed* 2012; 122: 12-24.
20. Szabo BT, Pataky L, Mikusi R, Fejerdy P, Dobo-Nagy C. Comparative evaluation of cone-beam CT equipment with micro-CT in the visualization of root canal system. *Ann Ist Super Sanita* 2012; 48: 49-52.
21. Patel S. The use of cone beam computed tomography in the conservative management of dens invaginatus: a case report. *Int Endod J* 2010; 43: 707-13.
22. Young SM, Lee JT, Hodges RJ, Chang TL, Elashoff DA, White SC. A comparative study of high-resolution cone beam computed tomography and charge-coupled device sensors for detecting caries. *Dentomaxillofac Radiol* 2009; 38: 445-51.
23. Wang P, Yan XB, Lui DG, Zhang WL, Zhang Y, Ma XC. Detection of dental root fractures by using cone-beam computed tomography. *Dentomaxillofac Radiol* 2011; 40: 290-8.
24. Patel S, Dawood A, Wilson R, Horner K, Mannocci F. The detection and management of root resorption lesions using intra-oral radiography and cone beam computed tomography - an in vivo investigation. *Int Endod J* 2009; 42: 831-8.
25. Takita T, Tsurumachi T, Ogiso B. Endodontic treatment of a maxillary lateral incisor with a perforating internal resorption by using cone beam computed tomography as a diagnostic aid: a case report. *Quintessence Int* 2011; 42: 745-52.
26. Oberoi S, Chigurupati R, Gill P, Hoffman WY, Vargervik K. Volumetric assessment of secondary alveolar bone grafting using cone beam computed tomography. *Cleft Palate Craniofac J* 2009; 46: 503-11.
27. Takane M, Sato S, Suzuki K, Fukuda T, Asano Y, Honda K, et al. Clinical application of cone beam computed tomography for ideal absorbable membrane placement in interproximal bone defects. *J Oral Sci* 2010; 52: 63-9.
28. Umetsubo OS, Gaia BF, Costa FF, Cavalcanti MG. Detection of simulated incipient furcation involvement by CBCT: an in vitro study using pig mandibles. *Braz Oral Res* 2012; 26: 341-7.
29. Peterson AG, Wang M, Gonzalez S, Covell DA Jr, Katancik J, Sehgal HS. An in vivo and cone beam computed tomography investigation of the accuracy in measuring alveolar bone height and detecting dehiscence and fenestration defects. *Int J Oral Maxillofac Implants* 2018; 33: 1296-304.
30. Xu X, Xu L, Jiang JH, Wu JQ, Li XT, Jing WD. Accuracy analysis of alveolar dehiscence and fenestration of maxillary anterior teeth of angle class III by cone-beam CT. *Beijing Da Xue Xue Bao Yi Xue Ban* 2018; 50: 104-9.
31. Leung CC, Palomo L, Griffith R, Hans MG. Accuracy and reliability of cone-beam computed tomography for measuring alveolar bone height and detecting bony dehiscences and fenestrations. *Am J Orthod Dentofacial Orthop* 2010; 137 (4 Suppl):

- S109-19.
32. Angelopoulos C, Thomas SL, Hechler S, Parissis N, Hlavacek M. Comparison between digital panoramic radiography and cone-beam computed tomography for the identification of the mandibular canal as part of presurgical dental implant assessment. *J Oral Maxillofac Surg* 2008; 66: 2130-5.
  33. Ghaemnia H, Meijer GJ, Soehardi A, Borstlap WA, Mulder J, Bergé SJ. Position of the impacted third molar in relation to the mandibular canal. Diagnostic accuracy of cone beam computed tomography compared with panoramic radiography. *Int J Oral Maxillofac Surg* 2009; 38: 964-71.
  34. Lee JS, Yoon SJ, Kang BC. Mandibular canal branches supplying the mandibular third molar observed on cone beam computed tomographic images: reports of four cases. *Korean J Oral Maxillofac Radiol* 2009; 39: 209-12.
  35. Lofthag-Hansen S, Gröndahl K, Ekestubbe A. Cone-beam CT for preoperative implant planning in the posterior mandible: visibility of anatomic landmarks. *Clin Implant Dent Relat Res* 2009; 11: 246-55.
  36. Spector L. Computer-aided dental implant planning. *Dent Clin North Am* 2008; 52: 761-75.
  37. Loubele M, Maes F, Schutyser F, Marchal G, Jacobs R, Suetens P. Assessment of bone segmentation quality of cone-beam CT versus multislice spiral CT: a pilot study. *Oral Surg Oral Med Oral Pathol Oral Radiol Endod* 2006; 102: 225-34.
  38. Ferreira MC, Garib DG, Cotrim-Ferreira F. Methodology standardization for measuring buccal and lingual alveolar bone plates using cone beam computed tomography. *Dental Press J Orthod* 2010; 15: 49-52.
  39. Bornstein MM, Balsiger R, Sendi P, von Arx T. Morphology of the nasopalatine canal and dental implant surgery: a radiographic analysis of 100 consecutive patients using limited cone-beam computed tomography. *Clin Oral Implants Res* 2011; 22: 295-301.
  40. Jung J, Yim JH, Kwon YD, Al-Nawas B, Kim GT, Choi BJ, et al. A radiographic study of the position and prevalence of the maxillary arterial endosseous anastomosis using cone beam computed tomography. *Int J Oral Maxillofac Implants* 2011; 26: 1273-8.
  41. Kruse C, Spin-Neto R, Wenzel A, Kirkevang LL. Cone beam computed tomography and periapical lesions: a systematic review analysing studies on diagnostic efficacy by a hierarchical model. *Int Endod J* 2015; 48: 815-28.
  42. Kruse C, Spin-Neto R, Reibel J, Wenzel A, Kirkevang LL. Diagnostic validity of periapical radiography and CBCT for assessing periapical lesions that persist after endodontic surgery. *Dentomaxillofac Radiol* 2017; 46: 20170210.
  43. Sogur E, Baksi BG, Gröndahl HG, Lomcali G, Sen BH. Detectability of chemically induced periapical lesions by limited cone beam computed tomography, intra-oral digital and conventional film radiography. *Dentomaxillofac Radiol* 2009; 38: 458-64.
  44. Sirin Y, Guven K, Horasan S, Sencan S. Diagnostic accuracy of cone beam computed tomography and conventional multislice spiral tomography in sheep mandibular condyle fractures. *Dentomaxillofac Radiol* 2010; 39: 336-42.
  45. Yendreka VC, Fonseca GM. A "borderline" dental trauma with 12 y of evolution justifying CBCT as diagnostic method. *Biomed Res* 2018; 29: 2800-5.
  46. Ersan N, Ilguy M. Diagnosis of unusual mandibular split fracture with cone-beam computed tomography. *J Oral Maxillofac Radiol* 2015; 3: 67-9.
  47. Lewis EL, Dolwick MF, Abramowicz S, Reeder SL. Contemporary imaging of the temporomandibular joint. *Dent Clin North Am* 2008; 52: 875-90.
  48. Librizzi ZT, Tadinada AS, Valiyaparambil JV, Lurie AG, Mallya SM. Cone-beam computed tomography to detect erosions of the temporomandibular joint: effect of field of view and voxel size on diagnostic efficacy and effective dose. *Am J Orthod Dentofacial Orthop* 2011; 140: e25-30.
  49. Al-Saleh MA, Alsufyani NA, Lagravere M, Nebbe B, Lai H, Jaremko JL, et al. MRI alone versus MRI-CBCT registered images to evaluate temporomandibular joint internal derangement. *Oral Surg Oral Med Oral Pathol Oral Radiol* 2016; 122: 638-45.
  50. Januário AL, Barriviera M, Duarte WR. Soft tissue cone-beam computed tomography: a novel method for measurement of gingival tissue and the dimensions of the dentogingival unit. *J Esthet Restor Dent* 2008; 20: 366-74.
  51. Pette GA, Norkin FJ, Ganeles J, Hardigan P, Lask E, Zfaz S, et al. Incidental findings from a retrospective study of 318 cone beam computed tomography consultation reports. *Int J Oral Maxillofac Implants* 2012; 27: 595-603.
  52. Tward DJ, Siewerdsen JH, Daly MJ, Richard S, Moseley DJ, Jaffray DA, et al. Soft-tissue detectability in cone-beam CT: evaluation by 2AFC tests in relation to physical performance metrics. *Med Phys* 2007; 34: 4459-71.
  53. Kabashima H, Mizobe K, Nakamuta H, Fujiwara H, Okamura K, Unemori M, et al. The usefulness of three-dimensional imaging in the diagnosis and treatment of clinically ambiguous gingival swelling. *J Oral Sci* 2011; 53: 257-61.
  54. Drage NA, Brown JE. Cone beam computed sialography of sialoliths. *Dentomaxillofac Radiol* 2009; 38: 301-5.
  55. Jadu FM, Hill ML, Yaffe MJ, Lam EW. Optimization of exposure parameters for cone beam computed tomography sialography. *Dentomaxillofac Radiol* 2011; 40: 362-8.
  56. Hechler SL. Cone-beam CT: applications in orthodontics. *Dent Clin North Am* 2008; 52: 809-23.
  57. Merrett SJ, Drage NA, Durning P. Cone beam computed tomography: a useful tool in orthodontic diagnosis and treatment planning. *J Orthod* 2009; 36: 202-10.
  58. Yang F, Jacobs R, Willems G. Dental age estimation through volume matching of teeth imaged by cone-beam CT. *Forensic Sci Int* 2006; 159 Suppl 1: S78-83.
  59. Hwang HS, Choe SY, Hwang JS, Moon DN, Hou Y, Lee WJ, et al. Reproducibility of facial soft tissue thickness measurements using cone-beam CT images according to the measurement methods. *J Forensic Sci* 2015; 60: 957-65.
  60. von See C, Bormann KH, Schumann P, Goetz F, Gellrich NC, Rucker M. Forensic imaging of projectiles using cone-beam computed tomography. *Forensic Sci Int* 2009; 190: 38-41.
  61. Pauwels R, Jacobs R, Bosmans H, Schulze R. Future prospects for dental cone beam CT imaging. *Imaging Med* 2012; 4: 551-63.
  62. Pauwels R, Araki K, Siewerdsen JH, Thongvigitmanee SS. Technical aspects of dental CBCT; state of the art. *Dentomaxillofac Radiol* 2015; 44: 20140224.
  63. Hiraiwa T, Arijji Y, Fukuda M, Kise Y, Nakata K, Katsumata

- A, et al. A deep-learning artificial intelligence system for assessment of root morphology of the mandibular first molar on panoramic radiography. *Dentomaxillofac Radiol* 2019; 48: 20180218.
64. Noel PB, Walczak AM, Xu J, Corso J, Hoffmann KR, Schafer S. GPU-based cone beam computed tomography. *Comput Methods Programs Biomed* 2009; 98: 271-7.
65. Ma L, Xu T, Lin J. Validation of a three-dimensional facial scanning system based on structured light techniques. *Comput Methods Programs Biomed* 2009; 94: 290-8.
66. Lata S, Mohanty SK, Vinay S, Das AC, Das S, Choudhury P. Is cone beam computed tomography (CBCT) a potential imaging tool in ENT practice? A cross-sectional survey among ENT surgeons in the State of Odisha, India. *Indian J Otolaryngol Head Neck Surg* 2018; 70: 130-6.
67. Liu J, Cai W, Ning R. Evaluation of differential phase contrast cone beam CT imaging system. *J Xray Sci Technol* 2017; 25: 357-72.