

## C A S E R E P O R T

## The scapho-capitate syndrome: a case report with follow-up of three years

*Alessio Pedrazzini<sup>1</sup>, Lisiana Daci<sup>2</sup>, Nicola Bertoni<sup>1</sup>, Bianca Pedrabissi<sup>1</sup>, Henry Yerwo Simo<sup>1</sup>, Vanni Medina<sup>1</sup>, Francesco Ceccarelli<sup>2</sup>, Francesco Pogliacomì<sup>2</sup>*

<sup>1</sup> Orthopaedic Unit, Oglio Po Hospital, Vicomoscato (CR), Italy; <sup>2</sup> Orthopaedics and Traumatology Clinic. Department of Medicine and Surgery, University of Parma, Parma, Italy

**Summary.** The scapho-capitate or Fenton syndrome is characterized by an associate fracture of the scaphoid and capitate with rotation of 90° or 180° of the capitate's head. We report a case of this syndrome which occurred in a fifteen years old professional motorcyclist who came to our observation following a high-energy trauma that occurred during the track tests. Through a dorsal access the fractures of the capitate and scaphoid were reduced and stabilized with Kirschner wires. The patient was radiographically and clinically evaluated three years after surgery; complete healing of scaphoid fracture and reabsorption of the capitate's head as consequence of avascular necrosis with the onset of a midcarpal arthritis were observed. Despite this radiographic evolution, the patient achieved excellent clinical result featured by complete recovery of wrist motion and absence of pain thus allowing the return to motorcycling. ([www.actabiomedica.it](http://www.actabiomedica.it))

**Key words:** Fenton's syndrome, scapho-capitate syndrome, fracture, capitate, scaphoid, carpus, wrist

### Introduction

Fracture-dislocations of the carpus represent a spectrum of complex injuries. In fact, accurate descriptions of specific injuries are often difficult.

The scapho-capitate syndrome was precisely described by Fenton and Rosen (1, 2) as associate fractures of the scaphoid and capitate with the rotation of the head of capitate of 90° or 180°, even if the first report of this injury was by Lorie (3) and Perves (4) in 1937.

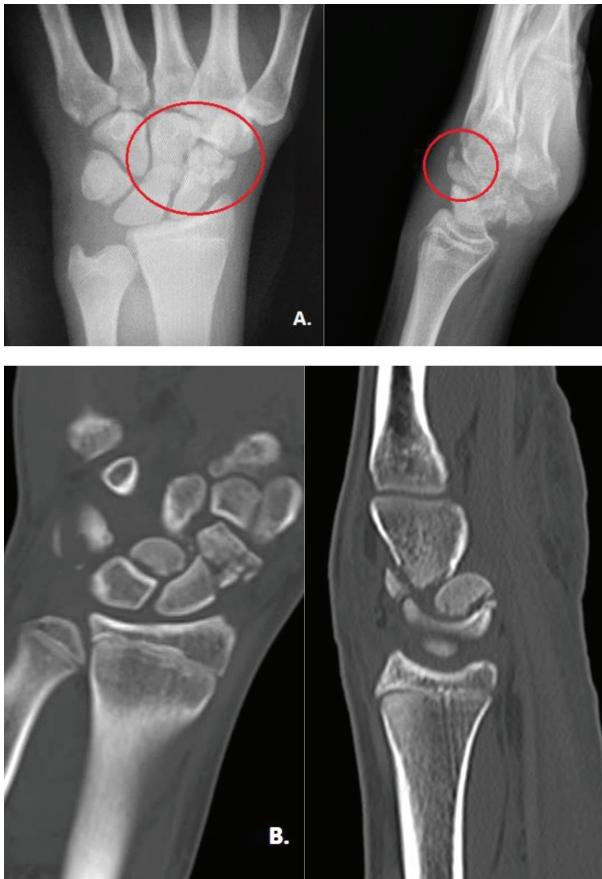
It is a very rare lesion and the diagnosis can be difficult. Few cases have been reported in the literature (5-9) and it is often associated with high-energy traumas (10). In fact, capitate bone is not normally subject to fracture because it lies in central position in the carpus at the intersection of the longitudinal and transverse carpal arches (11). It is surrounded and reinforced by the other carpal bones (2) and by strong ligaments that anchor the body of the capitate to the

trapezoid, hamate, and base of the third metacarpal, leaving the head and neck vulnerable to fractures (11).

### Case report

We report the case of a young professional motorcyclist who came to our observation following a high-energy trauma that occurred during the track tests. At the time of the trauma he was 15 years old. An initial radiographic evaluation was performed which showed the fracture of the scaphoid and of the capitate with alteration of the radiographic Gilula arches. A CT scan was then performed to better study the fractures which showed, in addition to the fracture of the capitate, a 180° rotation of its head and the multi-fragmentation of the scaphoid (Fig. 1),

A single dorsal approach was used. The fracture of the capitate was reduced (Fig. 2) and stabilized with two Kirschner wires inserted from proximal to distal

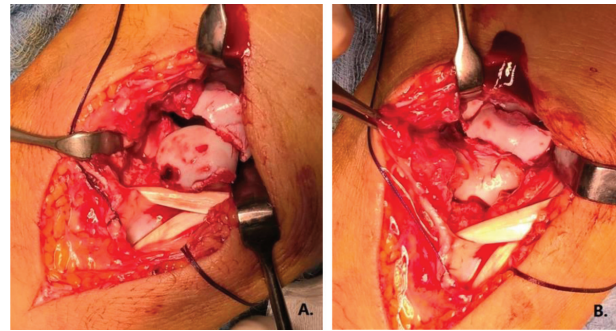


**Figure 1.** Preoperative standard radiographs (A) and CT scans (B) which show the fractures

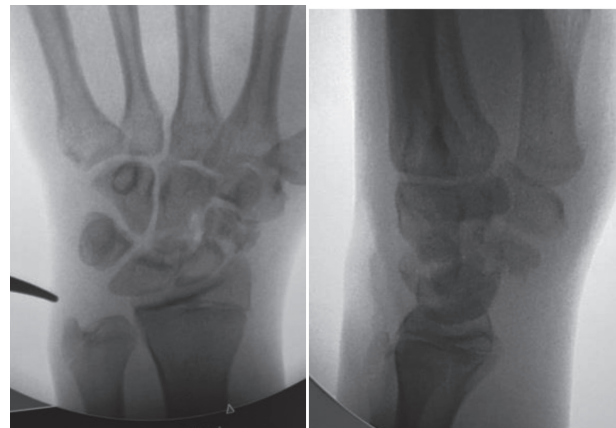
and one between capitate and hamate (Fig. 3 and 4). Since the scaphoid fracture was multifragmented, it was not possible to perform its synthesis with a Herbert-type headless screw, so the fixation was done with a Kirschner wire; a volar protective plaster cast was placed for 35 days. The patient also underwent pulsed magnetic fields in order to facilitate fractures healing.

After 35 days x-rays showed initial radiographic signs of healing of the scaphoid and initial reabsorption of the head of the capitatus without evidence of alteration of the arches of Gilula and articular collapse (Fig 5).

Kirschner wires were removed six weeks after surgery and the patient started physiotherapy for functional recovery with gradual improvement in the following weeks of wrist flexion and extension and ulnar



**Figure 2.** Intraoperative image before (A) and after reduction (B) of fracture of the capitate following a single dorsal approach

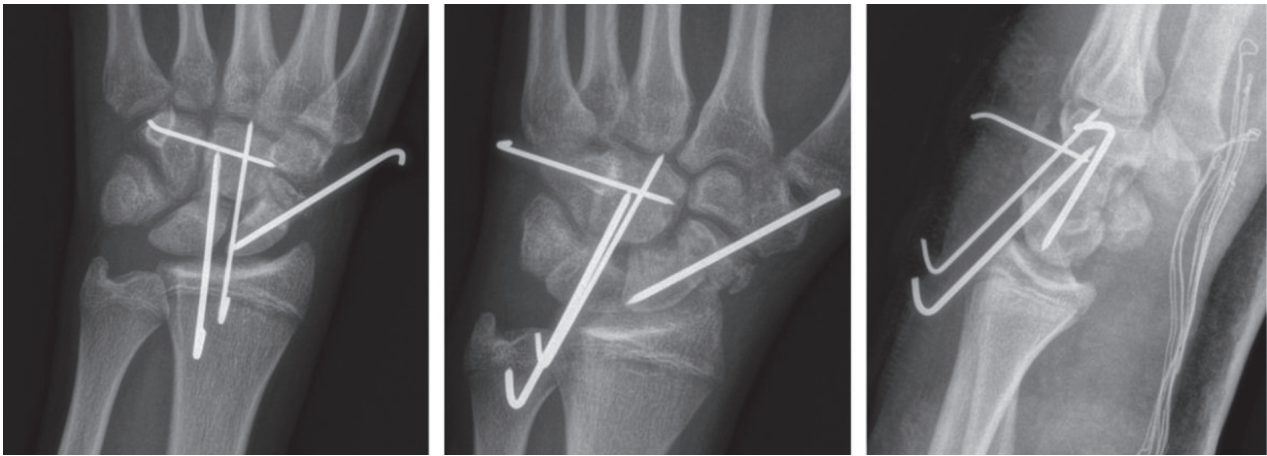


**Figure 3.** Intraoperative fluoroscopic images of fracture reduction

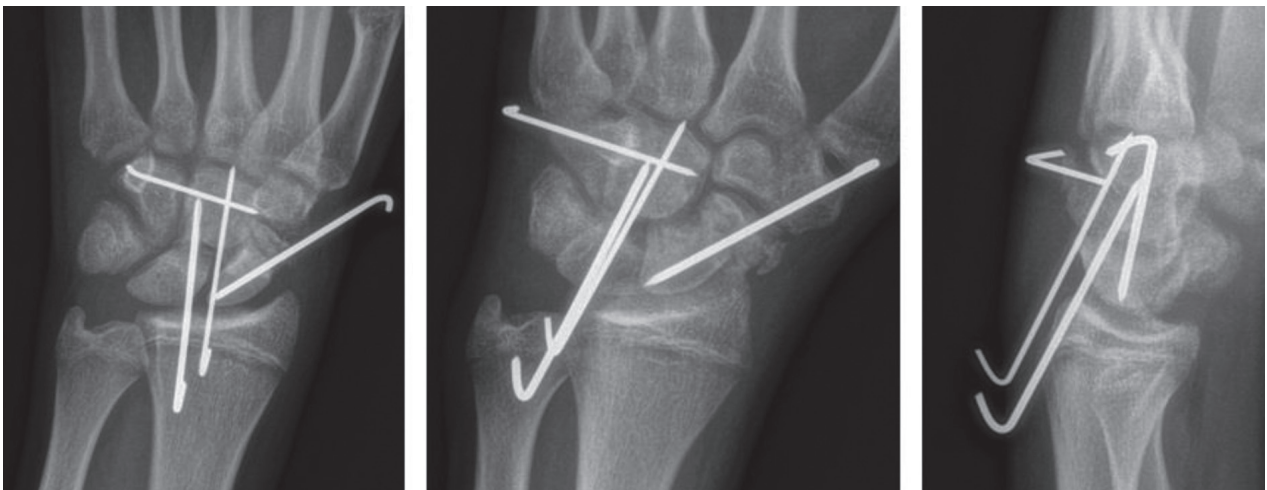
and radial deviation. After two months of rehabilitation he resumed his competitive activity.

The patient was evaluated three years later. New radiographs showed complete healing of the scaphoid fracture and a complete reabsorption of the capitate's head caused by its avascular necrosis with the onset of a midcarpal osteoarthritis despite the good reduction obtained with surgery (Fig. 6). However, radiographs showed that the Gilula arches remained substantially intact, there was no joint collapse and functionally the radiocarpal joint was good with loss of only about 20° of dorsal flexion and about 10° of flexion of the radiocarpal joint.

Clinically the patient was satisfied and he did not report pain and is still continuing his competitive sports (Fig. 7).



**Figure 4.** Postoperative x-ray views.



**Figure 5.** Radiographic images 35 days after surgery. An initial radiographic healing of the scaphoid and an initial reabsorption of the capitate's head can be noted

## Discussion

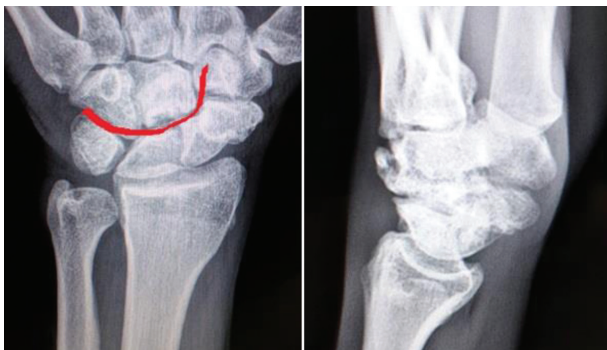The scapho-capitate syndrome is considered by many authors as a variety of trans-scaphoid, trans-capitate perilunar fracture-dislocation, and it represents the final stage of a greater arc injury which has either reduced spontaneously or by manipulation (12-14).

The mechanism of injury is not still clear. Fenton (2) first hypothesized that, during a fall, when the hand is in dorsiflexion position and radial deviation, the strength of the impact is transmitted from the radial styloid process through navicular onto the capi-

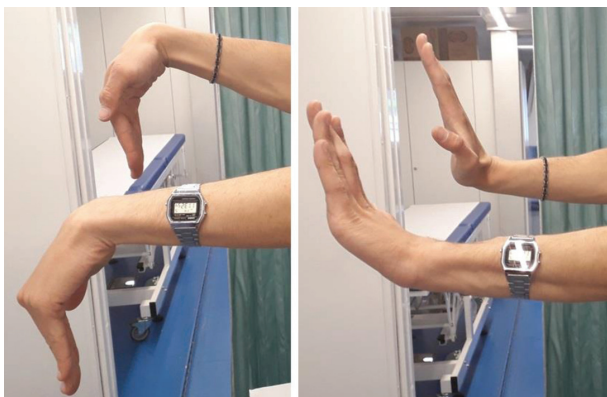
tate. In fact, the fracture lines in the two bones seem running together without interruption.

Currently, the hypothesis proposed by Stein (15) is the most accredited. For him, the trans-scaphoid, trans-capitate perilunar fracture-dislocation occurs for a forced hyperextension of the wrist during a fall on the palm of the hand. It causes the fracture of scaphoid and this fracture allows a further hyperextension of the wrist so the capitate beats on the dorsal edge of radius and breaks. The continuation of the hyperextension movement involves a rotation of 90° of the capitate. When the wrist returns to neutral position, the head





**Figure 6.** Radiographs three years after surgery with complete healing of scaphoid and reabsorption of the capitate's head; the Gilula arches remain substantially conserved, without joint collapse



**Figure 7.** Clinical evaluation 3 years after surgery; good result

of capitate rotate another  $90^\circ$ . For Sukul and Johannes (16) two type of trans-scapho-transcapitate fracture dislocation can be recognised, one in which rotation of the capitate is limited or does not occur at all, and the other in which there is  $180^\circ$  of rotation of the capitate head; this implies that a dorsal perilunate dislocation was originally present during the injury followed by a spontaneous reduction (17).

This injury is often associated with other radial or ulnar wrist lesions not always clearly detectable on X-rays such as the rupture of scaphotrapezoid ligament and lunotriquetral ligament or fracture of trapezium, trapezoid, triquetrum or hamate. Finally, the type of injury depends on two factors: the direction of the force of the injury and the severity of the injury which determines how the three columns of the wrist are interested (18).

As consequence of its rarity, the diagnosis is not simple, and the fracture pattern may not be correctly detected. It is necessary to take the correct antero-posterior and a lateral radiographic projections paying attention to any alteration of Gilula arches. A CT scan can be useful because it allows to study more precisely the reciprocal articular relationship of carpal bones and possible presence of unrecognized fractures (19).

In one of his work, Marcuzzi (20), suggests the use of Vance classification (21) in order to evaluate correctly this type of injury (Tab. 1).

In accordance with the literature, since the trauma is complex, the risk of pseudarthrosis of the scaphoid, avascular necrosis of the capitate, wrist instability and osteoarthritis is high (22-26). Authors prefer open reduction and fixation of the fracture with the more correct hardware in relation to its pattern.

It is fundamental for the therapeutic success to restore the length of the capitatus in order to prevent the articular collapse (22), the reduction and the synthesis of any associated fractures and the realignment of the carpal joints lines in case of ligaments' injuries.

Usually dorsal approach is enough but sometimes, especially if there is a suffering of the median nerve, a double access, dorsal and volar, can be used (11). The synthesis can be performed with different devices (Kirschner wires, screws, metal staples or anchors useful for the reconstruction of any associated ligaments' injuries) (17).

When it is possible, Authors prefer the Herbert-type headless screws that allow the compression of the fracture both for the scaphoid and for the capitate with the insertion for the capitate from distally to proximally in order to protect the cartilage of midcarpal articular surfaces. In cases of multi-fragmentary fractures Kirschner wires are preferable. Furthermore, rehabilitation and physical therapies plays an important role for recovering from this lesion (27).

In any case the risk of complications is high despite good reduction and fixation, as confirmed by the clinical case reported in which an excellent reduction and stabilization of both fractures of the capitate and the scaphoid were obtained.

Despite this, an avascular necrosis of the capitate and a midcarpal osteoarthritis occurred. The reason why it occurred is not clear; however, it could be hy-

**Table 1.** Vance classification

Type one	The carpus is aligned, without any dislocation of carpal bones The head of the capitate (rotated 180°) is in contact with the concavity of the lunate
Type two	The carpus is dislocated dorsally with the head of the capitate (rotated 180°) respect to the lunate which remains in place
Type three	The carpus is dislocated dorsally The head of capitate (rotated 180°) is in contact with the surface of the lunate
Type four	Only the head of capitate (rotated 180°) is dislocated dorsally
Type five	The carpus is dislocated to volar side with the head of the capitate (rotated 180°) the lunate remains in place
Type six	There is volar dislocation only of the head of the capitate (rotated 180°)

pothesised that the cartilage of the midcarpal articular complex and the vascularisation of the proximal pole of the capitate were inevitably damaged and compromised by the high-energy trauma that caused the injury. Nevertheless, the reconstruction of carpal anatomy and stabilization of articular structures avoided joint instability and collapse, thus ensuring an excellent functional result with satisfaction of the patient who resumed his competitive activity just three months after surgery.

## Conclusions

The scapho-capitate or Fenton syndrome is a rare carpal injury resulting from high-energy traumas where the fracture of the scaphoid is associated with the fracture of the proximal pole of the capitate which rotates of 90° or 180°. The treatment is surgical with different techniques and followed by intense and specific rehabilitation.

Nevertheless, it is a serious injury and the risk of complication is high despite good reduction and fixation.

**Conflict of interest:** Each author declares that he or she has no commercial associations (e.g. consultancies, stock ownership, equity interest, patent/licensing arrangement etc.) that might pose a conflict of interest in connection with the submitted article

## References

1. Fenton RL, Rosen H. Fracture of the capitate bone-report of two cases. *Bulletin of the Hospital for Joint Diseases Orthopaedic Institute* 1950; 11: 134-9.
2. Fenton RL. The naviculo-capitate fracture syndrome. *J Bone Joint Surg Am* 1956; 38-A(3): 681-4.
3. Lorie JP. Un case de fractura del escafidides carpiano y del hueso grande. *Chirurgia Ortopédica y Traumatologia Habana* 1937; 5: 125-30.
4. Pervés I, Rigaud A, Bedelon L. Fracture par décapitation du grand ps avec déplacement dorsal du corps de l'os simulant une dislocation carpienne. *Revue d'Orthop Mie* 1937; 24: 3: 251-3.
5. Dailiana ZH, Papatheodorou LK, Malizos KN. Scaphocapitate fracture: two cases with follow-up over 5 years. *J Wrist Surg* 2015 Aug; 4(3): 174-8.
6. Hamdi MF. The scaphocapitate fracture syndrome: report of a case and a review of the literature. *Musculoskelet Surg* 2012; 96(3): 223-6.
7. Kim YS, Lee HM, Kim JP. The scaphocapitate fracture syndrome: a case report and literature analysis. *Eur J Orthop Surg Traumatol* 2013; 23(suppl 2): S207-12.
8. Kumar A, Thomas AP. Scapho-capitate fracture syndrome. A case report. *Acta Orthop Belg* 2001; 67(2): 185-9.
9. Milliez PY, Dallaserra M, Thomine JM. An unusual variety of scapho-capitate syndrome. *J Hand Surg Br* 1993; 18(1): 53-7.
10. Pedrazzini A, Tocco S, Vaienti E, Ceccarelli F, Pogliacomini F. A rare case of bilateral complex wrist injury in a professional motocross rider. *Acta Biomed* 2016 Apr 15; 87 Suppl 1: 131-5.

11. Alan E, Freeland MD, Tracy A, Pesut MD. Oblique Capitate Fracture of the Wrist. *Orthopedics* 2004 Mar; 27(3): 287-90.
12. Johnson RP. The acutely injured wrist and its residuals. *Clinical Orthopaedics and Related Research* 1980; 149: 33-44.
13. Mazur K, Stevanovic M, Schnall SB, Hannani K, Zions LE (). Scaphocapitate syndrome in a child associated with a distal radius and ulna fracture. *Journal of Orthopaedic Trauma* 1997; 11: 230-2.
14. Pandit R. Proximal and palmar dislocation of the lunate and proximal scaphoid as a unit in a case of Scaphocapitate syndrome. A 32-month follow-up. *J Hand Surg Br* 1998 Apr; 23(2): 266-8.
15. Stein F, Siegel MW. Naviculocapitate fracture syndrome: A case report: New thoughts on the mechanism of injury. *J Bone Joint Surg* 1969; 51A: 391-5.
16. Kaulesar Sukul DM, Johannes EJ. Transscapho-transcapitate fracture dislocation of the carpus. *J Hand Surg Am* 1992 Mar; 17(2): 348-53.
17. Jones GB. An unusual fracture-dislocation of the carpus. *J Bone Joint Surg* 1955; 37B: 146-7.
18. Aspergis E, Darmanis S, Kastanis G, Papanikolaou A. Does the term scaphopapitate syndrome need to be revised? A report of 6 cases. *J Hand Surg Br* 2001 Oct; 26(5): 441-5.
19. De Filippo M, Pogliacomì F, Bertellini A, Araoz PA, Avèrna R, Sverzellati N, Ingegnoli A, Corradi M, Costantino C, Zompatori M. MDCT arthrography of the wrist: diagnostic accuracy and indications. *Eur J Radiol* 2010 Apr; 74(1): 221-5.
20. Marcuzzi A, Chirila L, Landi A. Transscaphoid-transcapitate perilunate fracture dislocations of the wrist: Fenton's syndrome. *GIOT* 2008; 34: 205-10.
21. Vance RM, Gelbermann RH, Evans EF. Scaphocapitate fractures: Patterns of dislocation, mechanisms of injury, and preliminary results of treatment. *J Bone Joint Surg* 1980; 62A: 271-6.
22. Rand JA, Linscheid RL, Dobyns JH. Capitate fractures: a long term follow-up. *Clin Orthop* 1982; 165: 209-16.
23. Adler JB, Shaftan GW. Fractures of the capitate. *Am J Surg* 1962; 44: 1537-47.
24. Vander Grend RV, Dell PC, Glowczewskie F, Leslie B, Ruby LK. Intraosseous blood supply of the capitate and its correlation with avascular necrosis. *J Hand Surg Am* 1984; 9: 677-83.
25. Boisgard S, Bremont JL, Guyonnet G, Chatenet T, Levai JP. Scapho-capitate fracture. Apropos of a case, review of the literature. *Ann Chir Main Memb Super* 1996; 15(3): 181-8.
26. Pogliacomì F, Marenghi L, Corradi M, Pedrazzini A, Caccarelli F. Proximal row carpectomy in the third millenium: is it still a valid indication? *Acta Biomed* 2014 Dec 17; 85(3): 243-51.
27. Costantino C, Pogliacomì F, Passera F, Concari G. Treatment of wrist and hand fractures with natural magnets: preliminary report. *Acta Biomed* 2007 Dec; 78(3): 198-203.

Received: 1 October 2019

Accepted: 3 November 2019

Correspondence:

Alessio Pedrazzini

Orthopaedic Unit, Oglio Po Hospital,

Via Staffolo 51 - 26041 Vicomoscato (CR), Italy

Tel. 00393478685689

E-mail: alessiopedrazzini@hotmail.com