

Laparoscopic Resection of Antenatally Identified Duodenal Duplication Cyst

Umashankar K. Ballehaninna, MD, MS, Tin Nguyen, MS-IV,
Sathyaprasad C. Burjonrappa, MD, MS, FRCS (Ed)

ABSTRACT

We report the first case of complete laparoscopic resection of a duodenal duplication cyst (DDC) in an 8-mo-old patient. The cyst was diagnosed by routine antenatal ultrasound performed at 3 mo of gestational age. Although the baby was born asymptomatic without any congenital abnormalities, the cyst had continued to increase on serial sonographic examinations. Previous reports have described treatment of DDC by surgical resection (laparotomy) or endoscopic marsupialization; we describe here, the first report of laparoscopic approach to resect DDC in a pediatric patient with a favorable outcome.

Key Words: Duodenal duplication cyst, Enterogenous cysts, Laparoscopy, Antenatal diagnosis, Laparoscopic resection, Surgical treatment.

INTRODUCTION

We report the first case of complete laparoscopic resection of a duodenal duplication cyst (DDC) in an 8-mo-old patient. The cyst was diagnosed by routine antenatal ultrasound performed at 3 mo of gestation. Although the baby was born asymptomatic without any congenital abnormalities, the cyst had continued to increase as shown on serial sonographic examinations. Previous reports have described treatment of DDC by surgical resection (laparotomy) or endoscopic marsupialization; we describe here, the first report of a laparoscopic approach to resect DDC in a pediatric patient with a favorable outcome.

Antenatally detected duodenal duplication cysts (DDC) represent an extremely rare variant of enterogenous duplication cysts (EDC) with only approximately 10 reported cases in literature.¹⁻⁴ By definition, a duplication cysts possesses a characteristic well-developed muscularis layer and a variable epithelial lining, and often has a communication with the intestinal lumen. DDC most often presents in the first decade of life with symptoms such as abdominal pain, nausea, or vomiting. Several authors have also described a plethora of different presentations and as such a curative resection is advocated to prevent future complications.^{1,5-10} A DDC can be treated by several approaches; a bulging intraluminal DDC can be amenable to endoscopic marsupialization with or without stent placement; extraluminal DDCs are traditionally treated by open exploration and resection, often leaving behind the common wall separating the cyst with adjacent bowel.¹¹⁻¹³ A laparoscopic or laparoscopic-assisted resection has been successfully used to treat certain EDCs, such as thoraco-abdominal, gastric and ileal duplication cysts especially in older children or adult patients.¹³⁻¹⁵ To our knowledge, this is the first report of total laparoscopic resection of a DDC in a pediatric patient with an excellent outcome.

CASE REPORT

A 26-y-old Chinese-speaking, gravida 1, para 1, woman presented for a routine ultrasound examination at 3 mo of gestation. A cystic mass with a well-defined wall measur-

Department of Pediatric Surgery, Maimonides Medical Center, Brooklyn, NY, USA (all authors).

Address correspondence to: Sathyaprasad C. Burjonrappa MD, MS, FACS, FRCS (Ed), Attending Pediatric Surgeon, Maimonides Medical Center, 4802, 10th Avenue, Brooklyn, NY 11219, USA. Telephone: (718) 283-7384, Fax: (718) 635-8641, E-mail: sathyabc@yahoo.com

DOI: 10.4293/108680813X13693422521151

© 2013 by JSLS, *Journal of the Society of Laparoendoscopic Surgeons*. Published by the Society of Laparoendoscopic Surgeons, Inc.

ing 1.2cm x 1.0cm was noted in the fetus on the right side of the abdomen, and there were no associated fetal anomalies. A well-developed 3,800-g male was born at full-term by spontaneous vaginal delivery. The infant was asymptomatic with a normal physical examination. Postnatal ultrasound performed during the eighth day of life suggested a 1.4cm x 1.3cm, thick-walled cyst abutting the medial aspect of the kidney (**Figure 1**). Magnetic resonance imaging (MRI) of the abdomen revealed 1.7cm x 1.2cm x 1.3cm duplication cysts possibly arising from the duodenum (**Figure 2**). The probable differential diagnosis included choledochal cyst, bowel duplication cyst, adrenal mass, and omental cyst. All laboratory tests were normal, and there were no associated anomalies. An expectant management protocol with serial sonographic evaluation was planned. Repeat sonograms obtained at 2 mo and at 6 mo showed an increase in cyst size to 2.2cm x 1.7cm, and 3.0cm x 3.0cm, respectively, of a thick-walled cyst in the region of the porta hepatis consistent with a DDC. A CT scan was obtained and confirmed a thin-walled cystic structure within the right upper quadrant lateral to the duodenum c-loop, anterior to the right kidney and renal vein, inferior to the gallbladder and liver, and posterior to the hepatic flexure of the colon. The intra- and extrahepatic biliary tree and pancreatic duct were normal (**Figure 3**).

With the patient under general anesthesia, laparoscopic resection of the DDC was performed using the standard 3-port technique with one 5-mm umbilical port for 30-degree laparoscope, and two 2-mm to 3-mm right upper and lower quadrant ports were used for instrumentation. A 2-mm stab wound was made in the epigastrium near the midline to introduce a blunt grasper that was used for liver retraction. There were many adhesions between the gallbladder and the cyst that were taken down with the Harmonic scalpel. The hepatic flexure was mobilized and reflected downwards. Adhesions between the transverse colon mesentery and the anterior cyst wall were gently separated as the colon was reflected inferiorly. A Kocher maneuver was performed to identify the medial margin of the cyst. Once the cyst margins had been completely delineated, its posterior wall was dissected off the right kidney and renal vein using the hook cautery in a lateral to medial fashion. It was attached to the medial aspect of the second portion of the duodenum by a long stalk that crossed the anterior surface of the duodenum before entering into it at the level of the pancreatic head. The stalk of the cyst, which also contained its feeding vessels, was transfixed using 4-0 silk at the level of the pancreatic head and divided. The cyst was extracted using a laparo-

scopic endo-pouch. Total operative duration was approximately 1.30 h. There were no intraoperative complications, and blood loss was < 5 mL. The patient had an uneventful postoperative course and was started on a clear liquid diet on day 1 following surgery and advanced to regular infant feeds. The patient had normal postoperative serum amylase, lipase, and bilirubin levels, and was discharged home on day 2. Pathology examination revealed an ovoid tan-grey cystic structure measuring 2.9cm x 2.2cm x 1.5cm filled with mucoid fluid (**Figure 4A**). Microscopic examination was suggestive of a duodenal duplication cyst lined with gastric mucosa and had a complete muscularis propria layer (**Figure 4B**).

RESULTS

Duodenal duplication cysts (DDC) are rare and account for 2% to 12% of gastrointestinal duplications with an incidence of < 1 per 100,000 live births.¹ DDC is usually located on the postero-medial border of the first and second part of the duodenum and sometimes may be associated with other abnormalities, such as complete colonic duplication, gastric diverticulum, and neurenteric cysts. Gastric mucosa is the most common heterotopic cell type lining the DDC, accounting for 50% of cases followed by intestinal, pancreatic, or respiratory epithelium.⁸⁻¹⁰ As we observed and noted in our patient, DDCs usually have a communication with either duodenal lumen or pancreatic/biliary ducts. In a recent meta-analysis, Chen et al.¹ reported that 29% (15 of 46 patients) have DDCs that connected to the pancreato-biliary ducts, while 2 cysts have communication with aberrant ducts in the pancreatic head, whereas 4 cysts communicated with duodenum and 1 cyst as such connected to the stomach.¹

The clinical presentation of DDC depends on location, size, and the type of underlying mucosa such as the presence of gastric mucosa. Most common symptoms at presentation include recurrent abdominal pain associated with nausea and vomiting.¹ Several authors^{1,4-9} describe a wide variety of presentations that include gastric outlet obstruction, pancreatitis, obstructive jaundice, and intussusception with DDC acting as a lead point, recurrent gastritis, gastrointestinal bleeding, and failure to thrive or weight loss. However, not all duplications give rise to symptoms, especially when diagnosed antenatally; only 67% of patients present with symptoms within the first year of life but by 2 y of age, 87% of patients are symptomatic.

Diagnosis of a DDC can be challenging, especially in the antenatal period, because it is difficult to distinguish these

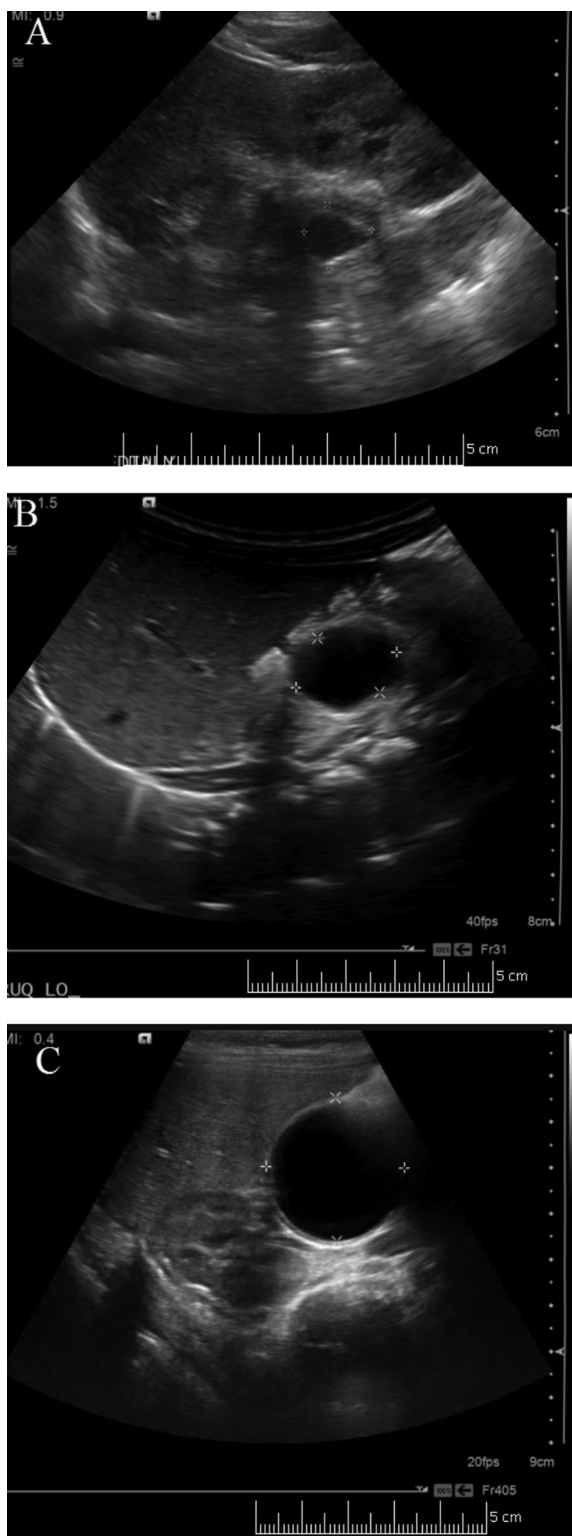


Figure 1. Serial abdominal ultrasound examination revealed a RUQ cyst with an echogenic wall that demonstrated increase in size over 6 mo.

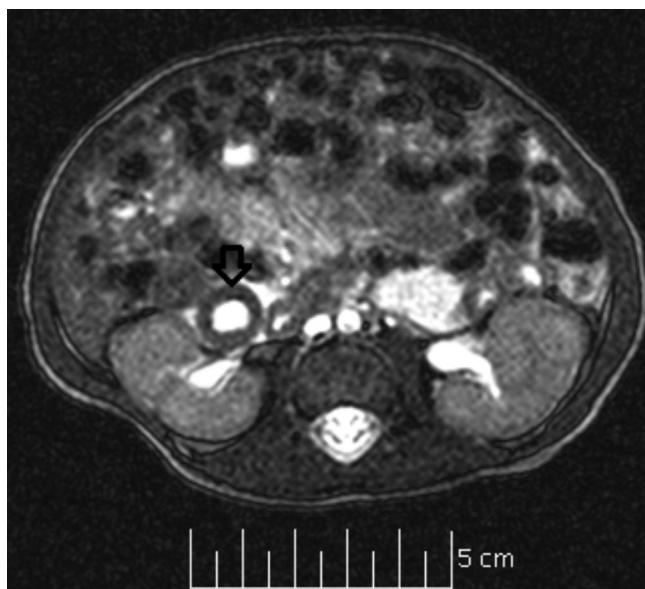


Figure 2. Magnetic resonance imaging of abdomen revealed a 1.7cm x 1.2cm x 1.3cm fluid-containing structure with a uniform 3-mm wall (arrow) adjacent to the duodenal.

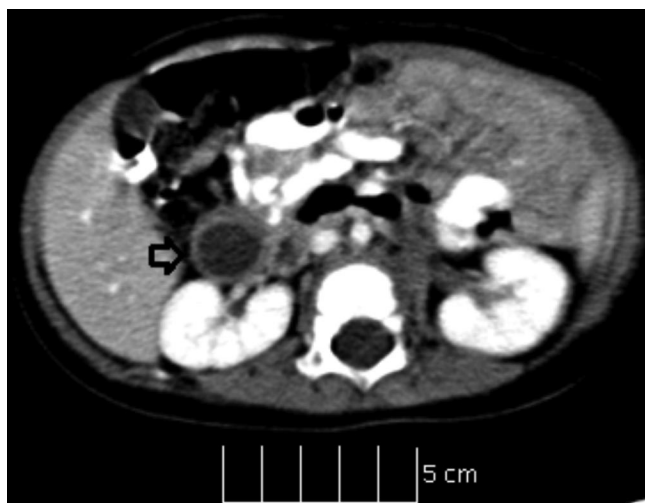

Figure 3. Computerized tomography (CT Scan) of the abdomen revealed a 1.9cm x 1.2cm diameter thin-walled cystic structure (arrow).

lesions from other intraabdominal cystic masses, such as choledochal or mesenteric cysts or adrenal tumors, and as such only a handful of case reports (<10 cases) have described the rare entity of antenatally diagnosed DDCs.¹⁻⁴ The 2 ultrasound features that are highly suggestive of enteric duplication include the “double-wall” sign (consists of an inner hyperechoic rim correlating to the mucosa-submucosa and an outer surrounding hypoechoic layer

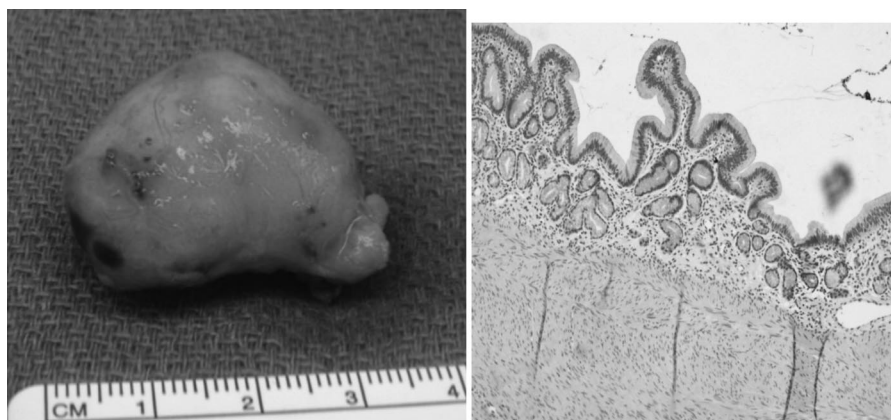


Figure 4. (A) Gross specimen measures 2.9cm x 2.2cm x 1.5cm. (B) Enteric duplication cyst lined by gastric type mucosa.

reflecting muscularis propria) and the presence of peristalsis. The most frequent initial screening test for diagnosis is often the abdominal ultrasound, and currently pre-natal diagnosis of DDC can be made as early as 12 wk as in our patient.⁴ Other imaging studies are often required to delineate the number, size, and anatomic relationship of the duplication cyst, establish any cyst communications with biliary/pancreatic ducts as well as to rule out the presence of associated congenital abnormalities or cyst-related complications.¹

The management of DDC is often determined by the anatomic characteristics of the DDC as well as associated complications. In a recent meta-analysis of 37 articles describing 46 cases of duodenal duplication cysts in the English-speaking literature, Chen et al.¹ report that overall 33 patients underwent surgical treatment of DDCs, which include 25 patients with surgical resection, 6 patients with surgical marsupializations, and 2 patients who underwent pancreatico-duodenectomies. In the same report, 13 patients had endoscopic drainage (marsupialization) and/or snare resection of intraluminal DDC, often without a stent placement, whereas one patient received medical therapy alone. Thus, surgical resection is accepted as the treatment modality, especially in patients with extraluminal DDC or when associated with complications, such as perforation, bleeding, lesser sac abscess, or presence of malignancy.^{1,4-9} Complete excision is possible in most cases. However, subtotal excision with resection of the cyst wall, stripping of the mucosal layer, and leaving behind the common wall between the cyst and vital structures is required in some cases because of the close proximity to the biliary and pancreatic duct systems.^{1,11,12} Literature review suggests that all of the reported cases of surgical resection of DDCs involve either laparotomy or a

transumbilical mini-laparotomy.¹ We report here the first case of complete resection of DDC using a total laparoscopic approach with excellent results. While safety and efficacy of laparoscopic surgery is being increasingly reported in infants to treat a variety of pathologies, we affirm that this approach is specifically useful to delineate the relationship of the DDC with surrounding structures. Our patient was discharged on hospital day 2 without any complications, which contrasts favorably to open, endoscopic, or combined approaches where the average length of hospital stay varied from 5 d to 7 d with significant reports of morbidity (20% to 30%) and mortality (2 patients).¹ This report demonstrates the safety and feasibility of the laparoscopic approach in the surgical treatment of extraluminal duodenal duplication cysts.

CONCLUSION

Antenatally diagnosed duodenal duplication cysts constitute a rare variant of enterogenous duplication cysts. Treatment of DDC should be tailored based on size, location, and the presence of associated symptoms or complications. A laparoscopic approach offers a safe alternative to open resection and is associated with improved patient outcomes.

References:

1. Chen JJ, Lee HC, Yeung CY, et al. Meta-analysis: the clinical features of the duodenal duplication cyst. *J Pediatr Surg.* 2010; 45(8):1598–1606.
2. Laje P, Flake AW, Adzick NS. Prenatal diagnosis and postnatal resection of intraabdominal enteric duplications. *J Pediatr Surg.* 2010;45(7):1554–1558.

3. Foley PT, Sithasanan N, McEwing R, et al. Enteric duplications presenting as antenatally detected abdominal cysts: is delayed resection appropriate? *J Pediatr Surg*. 2003;38(12):1810–1813.
4. Richards DS, Langham MR, Anderson CD. The prenatal sonographic appearance of enteric duplication cysts. *Ultrasound Obstet Gynecol*. 1996;7(1):17–20.
5. Yamauchi Y, Hoshino S, Yamashita Y, et al. Successful resection of an infected duodenal duplication cyst after percutaneous cyst drainage: report of a case. *Surg Today*. 2005;35:586–589.
6. Ozel A, Uysal E, Tufaner O, et al. Duodenal duplication cyst: a rare cause of acute pancreatitis in children. *J Clin Ultrasound*. 2008;36:584–586.
7. Cauchi JA, Buick RG. Duodenal duplication cyst: beware of the lesser sac collection. *Pediatr Surg Int*. 2006;22:456–458.
8. Hata H, Hiraoka N, Ojima H, et al. Carcinoid tumor arising in a duplication cyst of the duodenum. *Patol Int*. 2006;56:272–278.
9. Sand J, Matikainen M, Harmoinen A, et al. Haemorrhage into a duodenal cyst with ectopic gastric epithelium, a rare cause of gastric outlet obstruction in an adult. *Ann Chir Gynaecol*. 1997;86(1):76–78.
10. Zamir G, Gross E, Shmushkevich A, et al. Duodenal duplication cyst manifested by duodeno-jejunal intussusception and hyperbilirubinemia. *J Pediatr Surg*. 1999;34(8):1297–1299.
11. Antaki F, Tringali A, Deprez P, et al. A case series of symptomatic intraluminal duodenal duplication cysts: presentation, endoscopic therapy, and long-term outcome (with video). *Gastrointest Endosc*. 2008;67(1):163–168.
12. Wada S, Higashizawa T, Tamada K, et al. Endoscopic partial resection of a duodenal duplication cyst. *Endoscopy*. 2001;33(9):808–810.
13. Jiménez M, Cadière GB, Dapri G, et al. Duodenal duplication cyst in an adult: first simultaneous laparoscopic and endoscopic surgery. *J Laparoendosc Adv Surg Tech A*. 2009;19(2):207–210.
14. Martinez-Ferro M, Laje P, Piaggio L. Combined thoracoscopic laparoscopy for trans-diaphragmatic thoraco-abdominal enteric duplications. *J Pediatr Surg*. 2005;40(9):e37–40.
15. Zheng E, Burjonrappa S. Pancreatitis because of foregut duplication cyst of the pancreas treated by laparoscopic resection. *J Pediatr Surg*. 2010;45(12):e1–3.