

Clinical and Experimental Evidence of Supernormal Excitability and Conduction

Marcelo V. Elizari*¹, Jorge Schmidberg², Augusto Atenza², Diego V. Paredes² and Pablo A. Chiale³

¹Division of Cardiology, Ramos Mejía Hospital, Buenos Aires, Argentina; ²Centro de Arritmias Cardíacas del Gobierno de la Ciudad de Buenos Aires, Division of Cardiology, Ramos Mejía Hospital, Buenos Aires, Argentina; ³Centro de Arritmias Cardíacas del Gobierno de la Ciudad de Buenos Aires, Division of Cardiology, Ramos Mejía Hospital, Buenos Aires, Argentina

Abstract: True supernormality of excitability and conduction has been demonstrated in normal Purkinje fibers in *in vitro* studies. In the clinical setting, supernormality of conduction is manifested better than expected. This phenomenon is much more common than previously thought, particularly in the presence of certain clinical conditions. If a careful scanning of the cardiac cycle is performed on all patients with intermittent bundle branch block and second degree or advanced infra-nodal AV block, accessory pathways and malfunctioning pacemakers, it is anticipated that a much larger amount of supernormal excitability and conduction will be unmasked.

Keywords: Arrhythmias, AV block, intermittent bundle branch block, Mobitz type II AV block, supernormality, ventricular pre-excitation.

INTRODUCTION

Although excellent experimental and clinical studies have proved the existence of supernormality of excitability and conduction in some cardiac tissues, the application of these concepts for a better interpretation of cardiac arrhythmias has not been accepted unanimously by electrophysiologists and arrhythmologists. This standpoint is supported by the lack of enough hard facts and evidence to elucidate the intimate underlying physiopathologic mechanisms. What is more, the interpretation is still more disturbing for the general cardiologist who must be updated with information that sometimes is scarce and controversial.

For the above mentioned reasons, it is our belief that supernormality of excitability and conduction should be revisited.

SUPERNORMALITY IN NORMAL CARDIAC TISSUES

Adrian and Lucas [1] and Hoff and Nahum [2] described a supernormal phase of excitability in nerve and heart muscle respectively excited by electrodes placed on the surface. Later, various studies emphasized the complexity of surface stimulation for the study of myocardial excitability. Thus, pure depolarizing current delivered to a cell through intracellular microelectrodes were done to provide more accurate information. By means of this technique, Weidman [3] first demonstrated a period of supernormal excitability in sheep Purkinje fibers and Childers *et al.* [4] also showed the same phenomenon in the Bachmann's bundle in canine hearts.

Using intracellular stimulation and recording electrodes in different tissues of the heart, supernormal excitability can only be demonstrated in specific fibers [5]. As a representative

example, Fig. (1) illustrates the excitability curve measured in Purkinje and ventricular fibers using intracellular depolarizing current. The time course of the action potential voltage (top) and the excitability curve (bottom) are displayed in both cells. The scale at the bottom of the action potential indicates the time after the phase 0. The ordinate shows the minimum depolarizing current necessary to evoke a response according to the times disclosed in the abscissa. During the period of supernormal excitability the current necessary to depolarize the Purkinje fibers falls to its minimum value since the threshold is lower and excitation can be obtained successfully by stimuli which are ineffective before and after this particular period. Therefore, during the last part of the phase 3, the threshold potential is closer to the membrane potential and a smaller degree of depolarization with less stimulating current is necessary to bring the tissue to a firing level. Spear and Moore also demonstrated that changes in input resistance occurring late in phase 3 contribute to a lesser extent to supernormal excitability [5]. The supernormal period is always strictly related to the total refractory period and hence, to the duration of the action potential. Accordingly, supernormal excitability will occur earlier within the cardiac cycle with abbreviation of the refractory period at fast rates and later, at slow rates of stimulation. Conversely, supernormal excitability is not present in the ventricular working muscle using intracellular depolarizing current. Merideth *et al.* [6] measured the threshold values in single fibers of atrial and ventricular muscle, AV node, His bundle, and peripheral Purkinje fibers of the rabbit heart using intracellular stimulation (Fig. 2). Among the explored cells, the Purkinje fibers were the only ones whose threshold was lower at the very end of repolarization than later during diastole. It should be stressed that supernormality does not occur in atrial and ventricular fibers or in the AV node, where refractoriness outlasts repolarization.

Fig. (3) exhibits the response to stimulation of a Purkinje fiber and of a ventricular cell at different times of the repolarization process. In the Purkinje fiber, the earliest

*Address correspondence to this author at the Division of Cardiology, Ramos Mejía Hospital, Urquiza 609, 1221 Buenos Aires, Argentina; Tel/Fax: 0054 11 4.956.2102; E-mail: elizarimv@gmail.com.ar

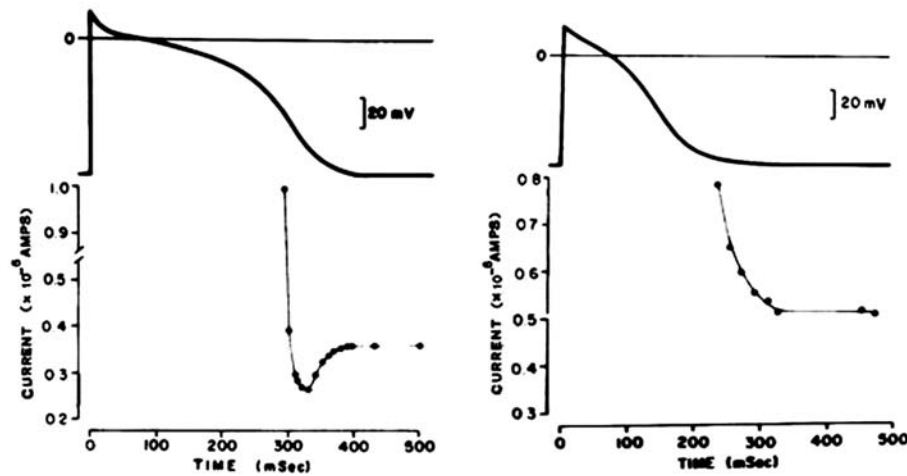


Fig. (1). Intracellular depolarizing currents necessary to trigger a response at the various times during repolarization from single canine Purkinje (left) and ordinary ventricular muscle (right). The abscissas indicate the times after the upstrokes of the action potential and the ordinates, the minimal depolarizing currents. A supernormal phase is observed only in the Purkinje fiber (see text for further description).

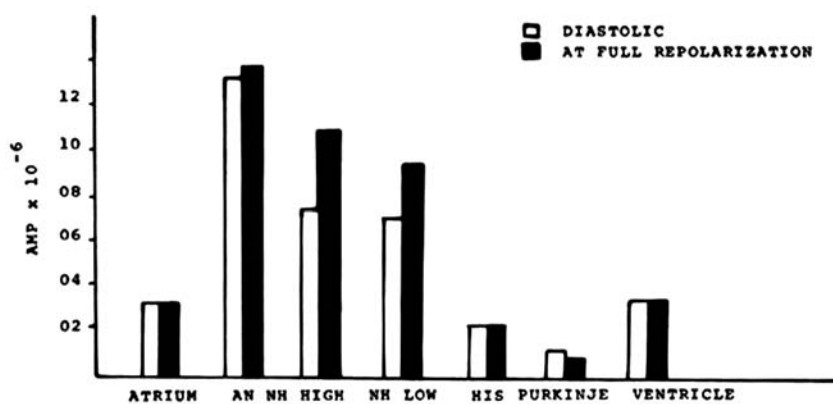


Fig. (2). Intracellular stimulation in different cardiac fibers of the rabbit heart to explore the excitability thresholds at the moment of full repolarization (white bars) of the previous action potential and late in diastole (black bars). The diastolic threshold at full repolarization is the lowest only in Purkinje fibers, during the supernormal phase (see text for further comments).

zation process. In the Purkinje fiber, the earliest propagated response can be obtained at a more positive membrane potential than in a ventricular fiber. This implies a relatively earlier recovery from inactivation of the sodium current, which is probably related as the mechanism underlying the existence of a supernormal phase in the specialized fibers. To be mentioned, stimulation of Purkinje fibers at the membrane potential where the supernormal phase occurs shows an excess of overshoot which might also contribute to greater stimulating efficacy (Fig. 3, left). Conversely, the myocardial cell (Fig. 3, right) does not exhibit the same pattern. It looks like recovery is completely and abruptly reassumed after the refractory period, without the presence of “slow responses”, denoting the absence of a significant relative refractory period. The virtual absence of a relative refractory period in ventricular fibers determine the excellent quality of the earliest response in terms of rate of rise of the phase 0 and dv/dt max, a characteristic that precludes slow conduction of premature stimuli. As a result, the ventricular mass becomes less vulnerable and ventricular fibrillation is unlikely or improbable to occur in the normal heart during physiological electrical stimulation.

In conclusion, it is assumed that the presence of a rather long relative refractory period of specialized fibers would facilitate the existence of a well developed supernormal phase

and eventually supernormal conduction. In fact, supernormal excitability implies that conduction of the cardiac impulse may improve during such period. In accordance with the local circuit theory, reduced current requirements for excitation at the end of repolarization in homogeneous conducting tissues (i.e. the Purkinje cells, in the bundle branches and intraventricular fascicles), the membrane potential could be brought to threshold potential faster and the downstream propagation will show more rapid conduction velocity.

The relationship between supernormal excitability and conduction was proven by Spear and Moore [5]. In *in vitro* studies performed in isolated Purkinje fibers with stimulating intracellular microelectrode, they showed the temporal coincidence of the two phenomena (Fig. 4A). Likewise, in another *in vivo* study in the open chest anesthetized dog using plunge bipolar electrodes to record the electrograms of the bundle of His and of the right bundle branch (RBB) near the right anterior papillary muscle and during a full diastolic scan of premature beats, the same investigators demonstrated an acceleration of conduction of 12.4% in the supernormal period as compared to normal conduction times later in diastole [5] (Fig. 4B). The maximum increment in the conduction time occurred at a H1-H2 interval of 195 ms.

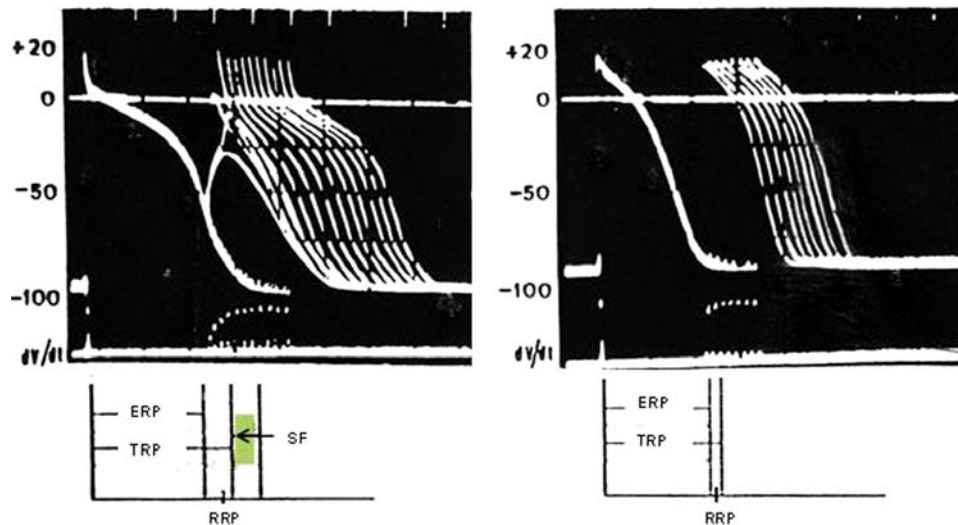


Fig. (3). Response to stimulation of a Purkinje fiber (left) and a ventricular fiber (right) at different times during and after the repolarization process. In each panel, the top tracing is the time scale (100 ms intervals), the second one is the response to stimulation of the action potentials and the lower tracing shows the dv/dt corresponding to each response (note the different scales. The first action potential in each panel is the last of a series of eight at a cycle length of 800 ms. The successive action potentials were evoked at progressively increasing S1S2 intervals. The earliest responses occur at a more negative membrane potential in the ventricular fiber with an almost normal rate of rise of the upstroke. The diagram at the bottom of A and B indicates the different periods of refractoriness and the supernormal phase of excitability (SF). ERP: effective refractory period; RRP: relative refractory period; TRP: total refractory period. See text for further comments.

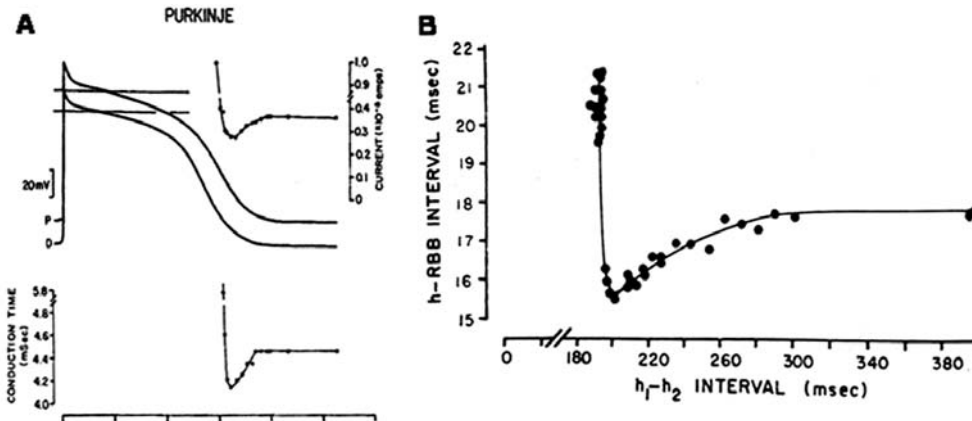


Fig. (4). Relationship between supernormal excitability and true physiologic supernormal conduction. **A:** Above: the action potentials were recorded in isolated Purkinje fiber 4 mm apart. P corresponds to the action potential recorded near the stimulating intracellular microelectrode and D indicates the distal action potential. The graph at the top indicates the minimal depolarizing currents with the excitability curve. Bottom: the graph plotted on the same time course as the action potentials show the conduction times between P and D recording sites. All data are plotted on the common time axis below. **B:** supernormal conduction in the His-Purkinje system of the intact canine heart. The ordinate indicates the conduction times between the electrograms from the His bundle and the distal RBB. The premature beats (h_1-h_2 intervals) are plotted on the abscissa. The supernormal phase with the increase in conduction of 2,2 ms (12,4%) occurred at h_1-h_2 intervals between 195 and 290 ms.

A clinical counterpart of the *in vitro* and *in vivo* experimental studies may occur in normal human hearts during the conduction of premature supraventricular beats. An impulse reaching the right or left bundle branch during the supernormal phase may be supernormally accelerated, a phenomenon that would be indiscernible and practically immeasurable in clinical settings. At most, it can be speculated that a premature impulse supernormally conducted in the RBB and normally conducted in the left bundle branch (LBB) will hardly change the normal sequence of the septal activation resulting in very small degrees of incomplete left bundle branch block (LBBB) without discernible changes in the HV interval.

SUPERNORMAL EXCITABILITY IN NORMAL MYOCARDIUM. CLINICAL AND EXPERIMENTAL EVIDENCE

The possibility of supernormal excitability in ventricular muscle has long been a matter of discussion. *In vitro* studies of ventricular endocardium failed to uncover a period of supernormal excitability [5]. It should be stressed that this was observed in studies exploring excitability by using intracellular depolarizing currents. However, extracellular stimulation was able to disclose a supernormal phase in atrial and ventricular muscle as well [7, 8] (see later).

Under clinical conditions this phenomenon may account for cases of failing or malfunctioning chronically epicardial

implanted pacemakers [9-14]. In these cases, the subthreshold impulses of a failing pacemaker induce ventricular responses only when they fall during a confined interval after the spontaneous escape beats as shown in (Fig. 5). The possibility that the subthreshold impulses may really stimulate Purkinje fibers across the ventricular wall is not admissible when the electrodes are placed at the base of the ventricles (where the wall is thick and Purkinje fibers are scarce or absent), or in the coronary sinus.

In *in vivo* experiments in the dog heart we showed that subthreshold extracellular stimuli, either of bipolar or monopolar cathodal mode, unveiled a narrow supernormal period in any part of the epicardium (Fig. 6) [15]. Beyond this point, during the diastole, the stimulating current has to be increased gradually until reaching a steady level. This response to extracellular subthreshold stimulation contrasts with previous knowledge on strength interval curves obtained by intracellular stimulation of single ventricular fibers. Accordingly, this must be interpreted as evidence of supernormal excitability, a phenomenon that does not necessarily imply supernormal conduction although both phenomena are positively related.

On the basis of the biphasic restitution of action potential amplitude in epicardium, Antzelevitch and Litovsky [16] considered the possibility that the characteristics of the recovery of the source (tissue already activated) rather than the characteristics of recovery of the excitability of the sink (tissue to be activated) may be responsible for supernormal excitability and conduction in the epicardium. The authors postulated that under conditions of impaired conduction, supernormality may occur in epicardium because of the much greater local current provided by the source in early versus late diastole. In fact, they demonstrate the phenomenon in epicardial strips of myocardium mounted in the sucrose gap. The supernormal phase of conduction occurred within a 50 to 200 ms window which varied as a function of the basic stimulation rate and tissue resistance (see Figure 42-4 in cite 16).

SUPERNORMAL CONDUCTION IN ABNORMAL CARDIAC TISSUES

As already presented, there are excellent experimental studies that have demonstrated the mechanisms of super-

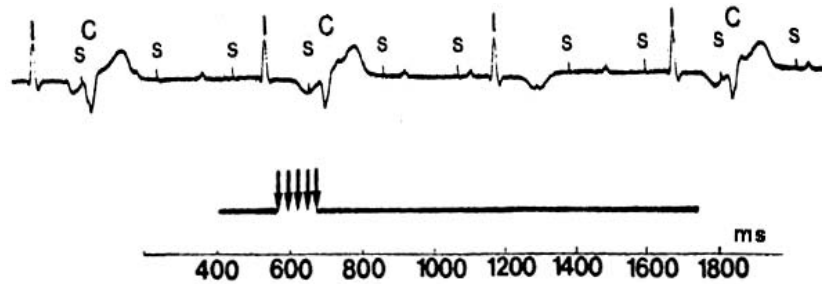

Fig. (5). Impulses of a failing pacemaker (S) evoke ventricular captures (C) only during a restricted interval after the idioventricular beats (I) uncovering a supernormal phase of excitability. The bottom diagram indicates the I-S intervals at which S was probably subthreshold and ineffective (solid line) and the I-S intervals inducing a ventricular response (arrows) between 540 and 680 ms of the preceding beat. The fact that the patient had a prolonged QT interval explains the late position of the supernormal phase. The pacemaker impulses falling in the earliest part of the supernormal period show a variable latency (second and third captures).

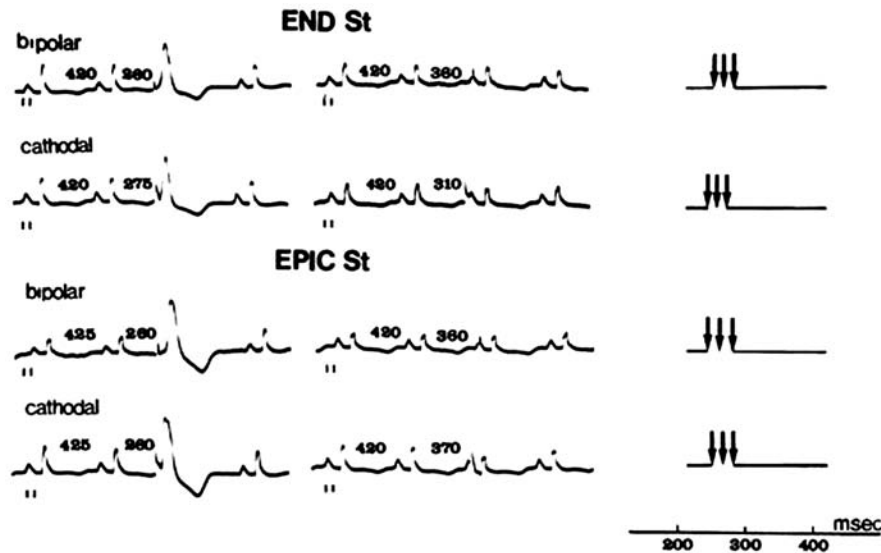


Fig. (6). The diastolic interval was fully scanned by subthreshold stimuli in an anesthetized dog using bipolar and cathodal (unipolar) stimulation delivered to the right ventricular endocardium in the apex (END.St) and to the epicardial surface close to the base (EPIC.St). The ECG strips to the left show ventricular responses evoked only during a short interval suggesting a supernormal phase of excitability while the ECG strips to the right show ineffective stimuli at different time intervals during diastole. Diagrams on the right summarize the results of the full diastolic scanning for each type of stimulation. The arrows indicate the periods of supernormal excitability.

normal excitability and conduction in normal cardiac tissues. However, the role of supernormality in clinical electrocardiography under abnormal conditions has been considered modest and even controversial [17].

According to various authors, supernormal conduction has been defined in different forms, but they all express a similar concept. Some examples are pertinent: “supernormal conduction is said to occur when impulse conduction is better than expected” [18]; “conduction may be called supernormal when it is better than anticipated under certain circumstances, or where propagation succeeds early in diastole and fails at all other times” [19]; “supernormal phase designates a short, early and limited period of the cardiac cycle during which a stimulus elicits either a totally unexpected response or one that is less abnormal than expected considering the state of recovery from the preceding impulse” [20]; “not truly supernormal but represents a brief period when impulse conduction is successful under conditions when it would be expected to fail” [21]; “the supernormal phase of conduction” is a short period of paradoxical improved conduction which may occur during an early phase [22]. None of all the above mentioned definitions is entirely appropriate because the words “better than anticipated or expected”, common in all the definitions, may correspond to other different causes listed in Table 1, which may be designated as “pseudo” supernormal conduction. The term “true” supernormal conduction will be reserved to conditions under which conduction improves and occurs in relation to a true supernormal phase of excitability in a sick tissue.

Table 1 summarizes a list including most causes of pseudo supernormal conduction due to conduction troubles at different levels of AV conduction.

To be mentioned, most of the studies on both “true” and “pseudo” supernormal conduction were performed in patients with AV block or related to troubles of nodal AV transmission [17, 18, 28]. This has been confusing since it is at the level of the AV junction where pseudo supernormal conduction can be interpreted as a true supernormal phenomenon. For didactic purposes and the sake of better comprehension, conduction and block in the intraventricular conducting fascicles is a preferable model to understand supernormal excitability and conduction.

SUPERNORMAL CONDUCTION IN PATIENTS WITH INTERMITTENT BUNDLE BRANCH BLOCK

Supernormal conduction was described in isolated cases of intermittent bundle branch block under different circumstances [22, 28-35], but Tavazzi *et al.* [34] were who performed a systematic study using programmed atrial stimulation in 15 cases of phase 3 bundle branch block (tachycardia-dependent block) uncovering a supernormal phase of conduction in 4 cases (25.6%). Later on, the same phenomenon was demonstrated when we analyzed cases of phase 3 bundle branch block [35]. In 12 of them, the supernormal phase of conduction was unveiled during a full scan of the diastolic interval with programmed atrial stimulation including His bundle recording as illustrated in (Fig. 7A). Other 8 cases were regarded as possible examples since the supernormal phase was outlined during spontaneous premature beats without His bundle recordings (Fig. 7B).

As an illustrative example, (Fig. 8) shows a series of His bundle recordings in a 45-year-old woman with intermittent right bundle branch block (RBBB) related to Chagas' cardiomyopathy. Premature atrial depolarization delivered after

Table 1. Causes of pseudo supernormal conduction.

1. In the AV node
a. Gap phenomenon [17, 18, 23, 24]
b. Peeling [17]
c. Manifest or concealed nodal reentry during Wenckebach periodicity [18, 23]
d. Longitudinal dissociation of the AV node [17]
e. Pulsatile changes in vagal discharge [17]
f. Facilitation of conduction by ectopic beats [18]
2. In the intraventricular His Purkinje system
a. Gap phenomena [23, 25]
b. His Purkinje delay resulting in normalization of aberrant conduction [18, 25]
c. AV nodal delay of premature atrial beats allowing normalization of aberrant intraventricular conduction [17, 18]
d. Wenckebach phenomenon in the bundle branches permitting normalization of aberrant intraventricular conduction [18]
e. Bilateral bundle branch block [19]
f. Ventriculophasic arrhythmia [17, 19]
g. Bradycardia dependent or phase 4 block [18, 19, 26]
h. Longitudinal dissociation in the RBB [27]

a fixed train shows normal conduction with H1-H2 interval of 820 ms (Fig. 8, Panel A). Increasing prematurity delivered at 10 ms steps revealed that the effective refractory period is about 800 ms. Progressively earlier stimuli identified a phase during which conduction through the RBB is as normal as during late diastole (Fig. 8, Panel B). Normalization of conduction occurred at an H1-H2 interval of 595 ms while small degrees of incomplete RBBB were observed at 540 and 610 ms which are the limits of the beginning and end of a supernormal phase of about 70 ms. Still earlier premature beats resulted again in RBBB (Fig. 8, Panel C). Normalization of conduction is preceded and followed by impaired conduction in the RBB indicating that the supernormal phase is immersed in the recovery curve of the affected fascicle without changes in His-Purkinje conduction times (H-V). His bundle recording was an essential requirement for the recognition of

a supernormal phase of conduction in order to exclude other confusing explanations (i.e. His-Purkinje and AV nodal gaps) as well as the possibility to determine the duration of the total refractory period. Nonetheless, supernormal conduction can be recognized in the setting of intermittent bundle branch block and is manifest by an unexpected normalization of conduction in the diseased fascicle with foreshortening of the R-R intervals. Panel D illustrates the position of the supernormal phase of conduction (white bar to the left) within the prolonged refractory period (black bar). The white bar on the right discloses the period of normal conduction up to cycle lengths of 1,400 ms.

An example of an apparently typical case of supernormal conduction is illustrated in Figure 9 in a case of intermittent LBBB in which the refractory period was estimated to last about 1,120 ms. A very long tracing showed that the super-

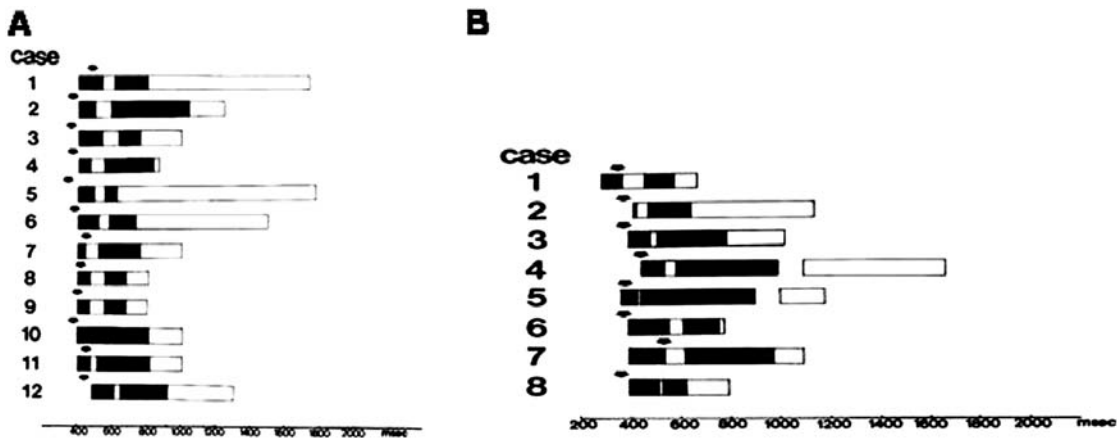


Fig. (7). **A:** Position of the supernormal phase of conduction in 12 cases (short-white bar to the left) in relation to the total duration of refractoriness (black bar) and to the end of the T wave (black arrows). In each case supernormality was demonstrated during a full scan of induced premature atrial beats during the diastolic interval including a His bundle recording. The supernormal phase is thus given in H1-H2 intervals. **B:** a similar illustration of 8 cases of intermittent bundle branch block uncovered by spontaneously occurring atrial premature beats and induced changes of cardiac rate by carotid sinus massage. Since His bundle recording was not done, the supernormal phase is given in R.R intervals. The position of the supernormal phase is similar to the cases shown in A. White bars to the right indicate normal conduction after the end of refractoriness achieved in some cases by carotid sinus massage.

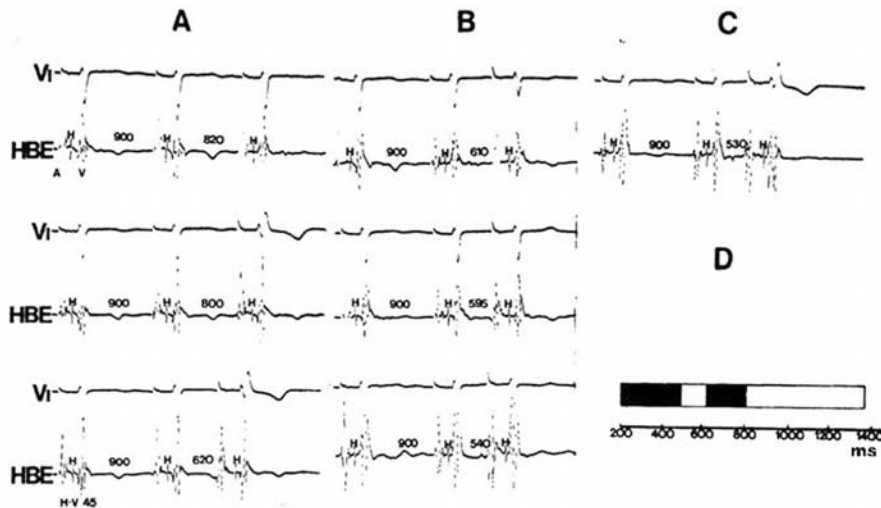


Fig. (8). Supernormal conduction in a patient with intermittent RBBB. Simultaneous recording of lead V1 and His bundle electrogram during programmed premature atrial stimulation at a basic cycle length of 800 ms. Panels A to C are described in the text. Panel D depicts the position of the supernormal phase of conduction (white bar to the left) within the prolonged refractory period (black bar). The white bar on the right represents normal conduction up to cycle lengths of 1,400 ms.

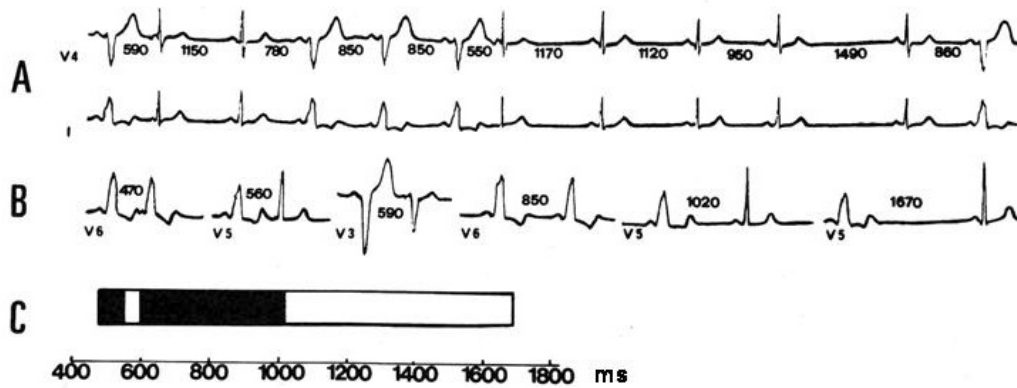


Fig. (9). Supernormal conduction in a case of intermittent LBBB. Atrial premature beats disclose a supernormal phase of conduction during a short period of the cardiac cycle. The heart rate was changed by carotid sinus massage. **A:** simultaneous recording of leads V4 and I. High degree of LBBB occurred in beats closing RR intervals between 780 and 860 ms and normal intraventricular conduction during the supernormal phase at R-R of 590 and 550 ms (2nd and 7th beats), respectively. **B:** Discontinuous recording of lead V6. Normal intraventricular conduction of beats falling after the end of the total refractory period occurred at RR intervals between 1,120 and 1,670 ms. The total refractory period was estimated to last about 1,020 ms. Premature atrial beats falling between 540 and 590 ms were normally conducted or show a small degree of LBBB suggesting the existence of a supernormal phase. **C:** The diagram at the bottom illustrates the ranges of block (black bars) and conduction during the supernormal phase (white bar to the left) and beyond the end of the total refractory period (to the right).

normal phase occurred between 540 and 590 ms of the cardiac cycle and began about 430 ms before the end of the total refractory period. Eight cases were analyzed on conventional electrocardiograms in which the findings were similar to those already illustrated (Fig. 7B).

Altogether, 20 cases of intermittent bundle branch block were analyzed and the main findings were:

1. All patients showed a tachycardia dependent block (phase 3 bundle branch block) and the duration of the refractory period ranged between 600 and 1,020 ms. The presence of a prolonged refractory period appears as an essential requirement for the occurrence of a supernormal phase of intraventricular conduction. To be mentioned, the supernormal phase became apparent in cases in which prolongation of the refractory period was induced by small doses of conduction depressing drugs [34, 35].
2. The supernormal phase followed the end of the T wave by an interval ranging from 0 to 185 ms (mean 84 ms) and was a rate-dependent phenomenon being shifted to the left at fast rates and to the right at slow rates. The duration of the supernormal phase extended from 10 to 90 ms and its position in the cardiac cycle was relatively constant (Figs. 7-9).
3. The relatively constant position of the supernormal phase was independent of the total duration of refractoriness. In fact, the interval between the end of the supernormal phase and the end of the total duration of refractoriness ranged between 70 to 460 ms (mean 243 ms) and was found within the refractory period in a rather constant position regardless its duration.

The fact that the refractory period was always followed by normal conduction, ruled out the presence of phase 4 block (bradycardia dependent block) [26].

4. The QRS intervals of the supernormally conducted beats are usually identical to those occurring after the

long pauses (beyond refractoriness). However, in some cases, different degrees of incomplete bundle branch block may be seen during the supernormal phase, thus suggesting that it is indeed a dip with gentle descending and ascending slopes within an abnormally prolonged refractory period.

5. Since the supernormal phase is imbedded within the prolonged refractory period, and should the heart rate be increased, a point is expected to be reached where every impulse should be 1:1 supernormally conducted. This phenomenon was seen to occur in the anomalous pathways during atrial tachycardia, atrial flutter and atrial fibrillation or in cases with advanced AV block in which conduction to the ventricles takes place through a single fascicle (see later). Interestingly, this type of conduction is exceptional in patients with intermittent bundle branch block. It was observed that when the cycle length reached the R-R interval of the supernormal phase, only every other beats were supernormally conducted with a 2:1 pattern. In the presence of bundle branch block, 1:1 supernormal conduction does not occur because once a first beat is normally conducted during the supernormal phase, such normalization shifts the supernormal phase to the left in such a way that the next beat, at the same rate, falls beyond the supernormal period and bundle branch block is elicited again. Bundle branch block re-shifts the supernormal phase to the right creating an alternation in its position accounting for the 2:1 supernormal conduction which may remain stable and persistent if the heart rate continues being constant as illustrated in (Fig. 10). In order to maintain the 2:1 pattern of conduction it has to be admitted that during each aberrant beat the affected branch is activated in a retrograde and concealed fashion. The preservation of retrograde conduction may explain this particular condition and others that will be discussed later.

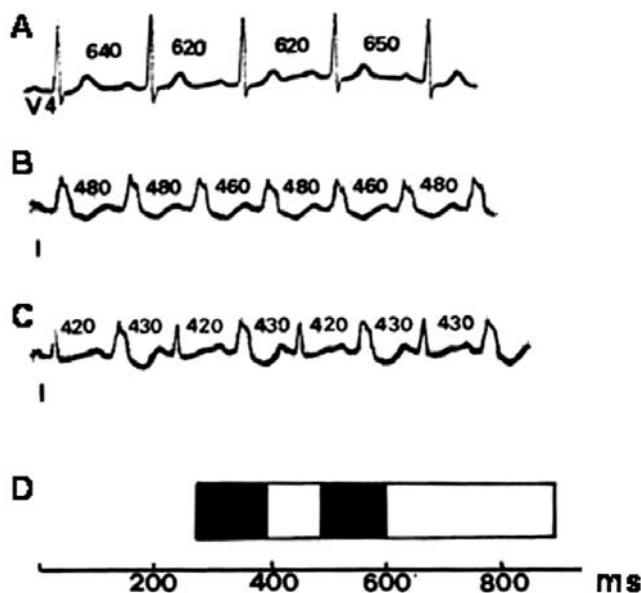


Fig. (10). An example of 2:1 supernormal conduction in the left bundle branch. **A:** normal conduction is observed at a cycle length of 620-640 ms, while persistent LBBB occurred when the cycle length is shortened to 460-480 ms (panel **B**) after the administration of atropine. **A** further shortening of the cycle length to 420-430 ms (panel **C**) resulted in 2:1 LBBB in the presence of a supernormal phase. Panel **D** discloses the position of the supernormal phase and the total duration of refractoriness in the LBB (refer to text for further comments).

6. The effect of conduction depressing drugs was explored in patients with intermittent or transient intermittent BBB [35]. In cases in which the existence of supernormality is demonstrated, a small to moderate dose of conduction depressing drugs causes a prolongation of the refractory period with disappearance of the supernormal phase [35]. The opposite effect was caused by weaker doses of the same drug favoring the occurrence of a supernormal phase of conduction. This phenomenon was demonstrated in 4 patients that were known to have had intermittent bundle branch block in previous tracings, but at the time of the study, conduction was normal at rates up to 150/min [35]. The administration of conducting depressing drugs resulted in the reappearance of the intermittent bundle branch block and the prolongation of refractoriness was accompanied with supernormal conduction in all of them. In turn, an increase of the dose of the drug provoked disappearance of the supernormal phase. Obviously, these observations confirm that for a supernormal phase to become apparent, it is mandatory to have a prolonged refractory period. Of course, a greater depression of conduction will prolong or eliminate any possible form of conduction.

SUPERNORMAL CONDUCTION IN PATIENTS WITH ADVANCED AV BLOCK

Patients with advanced infranodal AV block and variable periods of AV dissociation may exhibit late and early captures illustrated in Fig. (11), panels A and B. Late captures are commonly observed when an atrial impulse falls beyond a long critical interval following a preceding beat. The refractory period of the bundle branch responsible for AV conduction is usually longer than that described in the cases of intermittent bundle branch block denoting a greater compromise of the diseased fascicle. When looked for, iso-

lated early captures are also observed immersed inside the prolonged refractory period and these only occur when a P wave falls within a restricted, usually short, interval after a preceding idioventricular beat. Both, early and late captures, show the same QRS pattern with the same PR interval. Late captures occur after the end of the refractory period while the early captures can only happen if the existence of a supernormal phase of conduction is operative [20, 35]. Fig. (12) is also a demonstrative clinical example to illustrate the occurrence of early ventricular captures during the supernormal conduction period, mimicking ventricular extrasystoles, in a patient with advanced AV block.

A remarkable finding in cases of advanced AV block is the presence of retrograde conduction, which occurs whenever it is not interfered by atrial beats falling close or within the idioventricular beats. The fact that AV block is unidirectional allows retrograde activation at the site of block of the diseased conducting tissue which may be manifest or concealed. This is of paramount importance since supernormal AV conduction can only occur if retrograde activation of the damaged area is present [28, 35]. Cases showing a similar behavior have previously been reported by several investigators [20, 28, 33, 35, 36].

In conclusion, cases of advanced AV block with early and late captures with the opposite or similar QRS pattern of the basic idioventricular rhythm and manifest or concealed retrograde conduction are paradigmatic examples of typical supernormality to account for the occurrence of early ventricular captures.

THE RELATIONSHIP BETWEEN MOBITZ TYPE II AV BLOCK WITH THE SUPERNORMAL PHASE OF EXCITABILITY AND CONDUCTION

Katz and Pick [37] suggested that Mobitz type II block occurs as a consequence of prolongation of the absolute re-

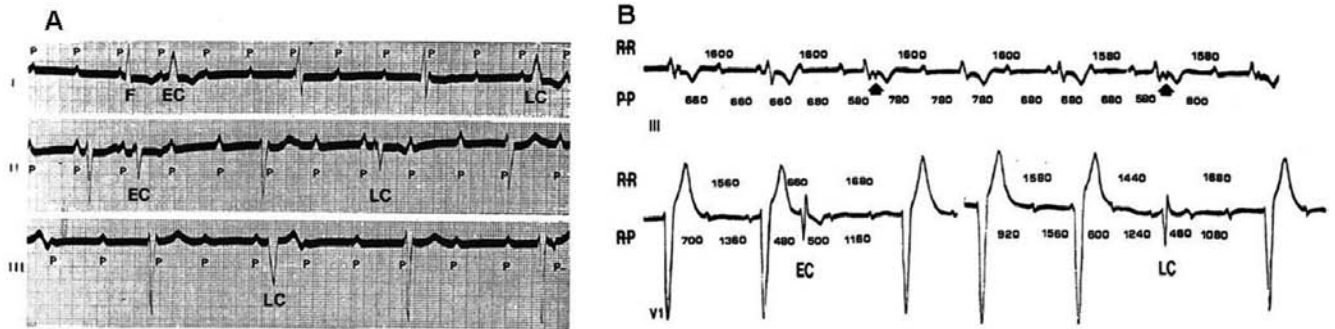


Fig. (11). Examples of early (EC) and late (LC) captures in cases of advanced AV block. **A:** leads I, II and III are discontinuous. The idioventricular rhythm shows a pattern of RBBB with left anterior hemiblock, while early and late captures exhibit LBBB pattern preceded by a similar PR interval. AV conduction via the RBB only occurs when the RP intervals are about 560 ms (EC) or 1,600 ms or more (LC). The last negative P wave in the third strip (lead III) indicates retrograde conduction to the atria. **B:** another example of true supernormal AV conduction in the presence of advanced AV block. Leads III and V1 are discontinuous. The idioventricular rhythm shows a LBBB pattern whereas both, early (EC) and late (LC) captures exhibit RBBB pattern. This implies that the RBB is totally interrupted and the one exhibiting a long refractory period and a supernormal phase is the LBB. The arrows in the top strip (lead III) show retrograde conduction to the atria (negative P waves after beats 3 and 6).

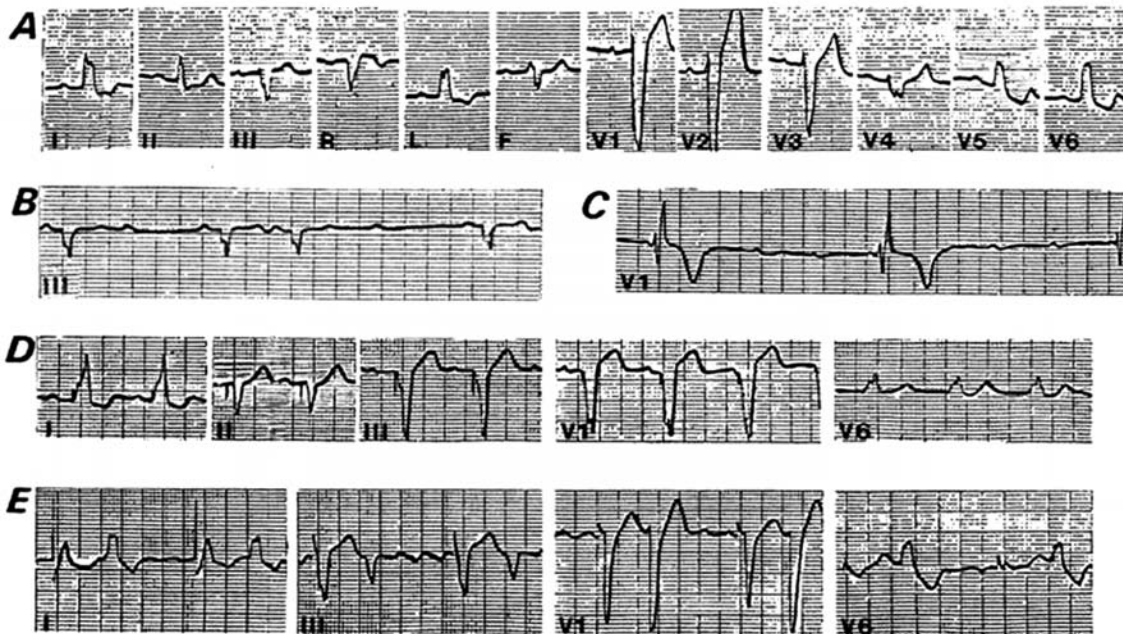


Fig. (12). Supernormal AV conduction in a patient with advanced AV block after the implant of a permanent pacemaker. Tracings from A to D were obtained at different dates during successive controls of the patient. **A:** normal sinus rhythm with LBBB; **B:** 3:2 Mobitz II AV block; **C:** complete AV block; **D:** a permanent pace marker was implanted; **E:** the patient developed atrial flutter. The first QRS complex in each lead corresponds to a paced beat and the second one to an early ventricular capture during the supernormal phase. The rapid atrial rate of the flutter allows AV conduction whenever the atrial impulse hits the supernormal period. Interestingly, this early captures were erroneously interpreted as ventricular premature beats and treated as such with an antiarrhythmic drug.

refractory period without a concomitant prolongation of the relative refractory period. Likewise, Pick and Langendorf [36] postulated that the relative refractory period should even be shorter than normal.

Halpern *et al.* [38] studied 47 cases of Mobitz II block in which 3:2 AV conduction was present. Tachycardia and bradycardia-inducing maneuvers were performed in all cases in order to obtain different AV conduction patterns (1:1; 2:1; 3:2; 4:2, etc.). In 16 out of the 47 patients, atrial pacing and His bundle recordings were performed and it was possible to obtain the transitions from 1:1 to 2:1 and 3:2 AV conduction. The effective refractory period was determined as the short-

est R-P interval that was followed by a successful conduction to the ventricles as well as the AV intervals, which were also measured.

Halpern *et al.* [38] also proposed that 3:2 periodicity is a common presentation of Mobitz type II block and sets itself as a model to postulate the occurrence of a supernormal phase of conduction which plays a fundamental role on the occurrence of this pattern. Fig. (13) illustrates the main features of a typical case of Mobitz type II AV block showing 3:2 periodicities. Fig. (14) depicts the electrophysiologic study of a patient that had shown 3:2 Mobitz II AV block in a previous control. At a time when 1:1 conduction was prevalent, a full scan of the

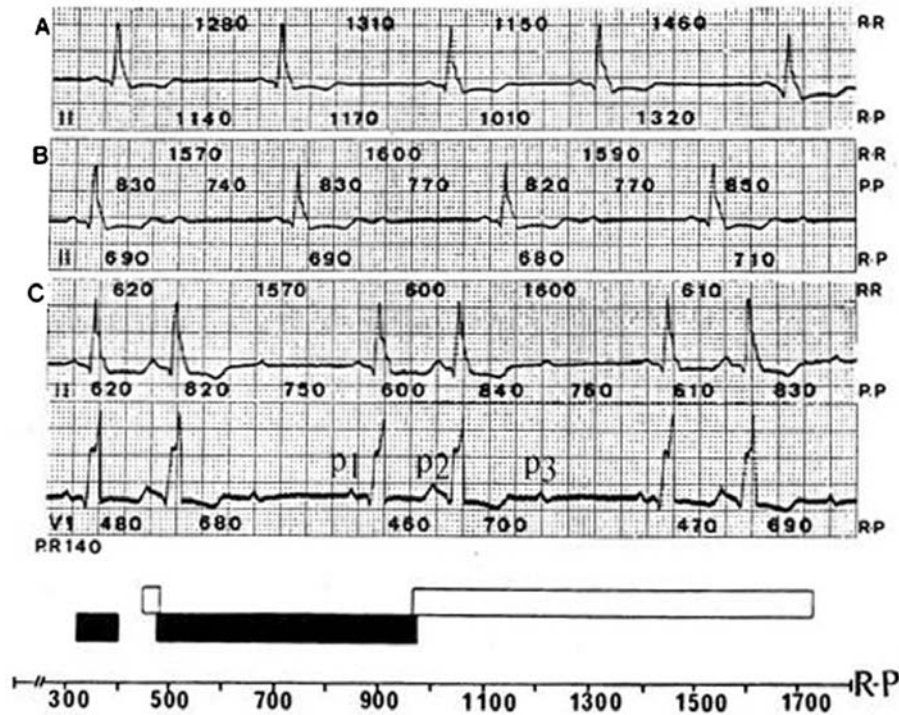


Fig. (13). Mobitz II type block showing the development of a 3:2 periodicity. The R-R, R-P and P-P intervals are indicated in ms. **A:** 1:1 AV conduction with R-R intervals between 1,150 and 1,460 ms. **B:** increasing the sinus rate a 2:1 AV conduction was obtained with P-P intervals between 740 and 850 ms; **C:** with a further increase of the sinus rate a 3:2 periodicity occurs in the presence of a clear-cut constant ventriculo-phasic arrhythmia. The diagram at the bottom represents the total duration of refractoriness (black bar) during which P waves are blocked. P waves are normally conducted early during the supernormal phase (small white bars on the left) or late after the end of refractoriness (long white bar). All figures are in milliseconds. See text for further comments.

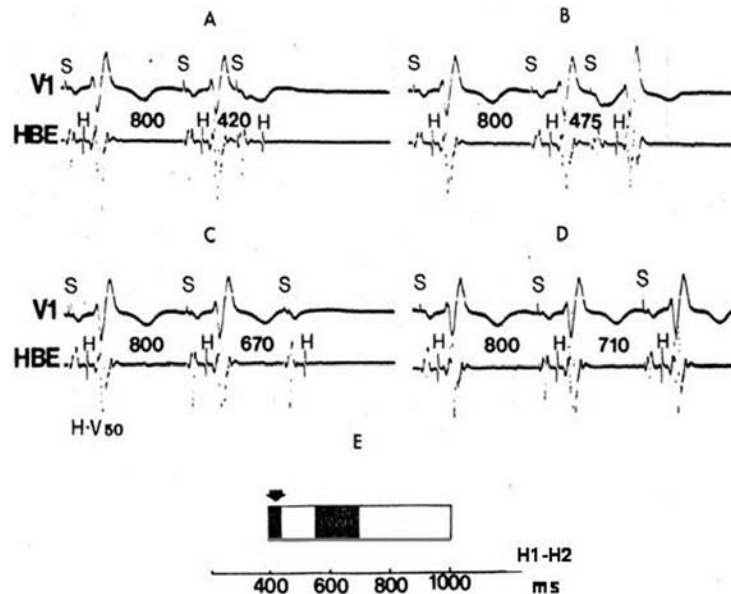


Fig. (14). Electrophysiological study from a patient that had shown Mobitz II AV block, at a time when 1: 1 AV conduction was prevalent. A full scan of the cardiac cycle disclosed a typical supernormal phase of AV conduction as illustrated in the bottom diagram (white bar to the left). See text for a detailed description.

cardiac cycle was performed. In each panel, the first two beats are the last of a series of eight at a fixed cycle length of 800 ms. At H-H intervals of 440 ms or shorter, AV conduction failed (Panel A). H-H intervals between 440 and 560 ms show AV conduction with the same HV interval (Panel B). Conduction failed again at H-H intervals between 560 and 700 ms

(Panel C). AV conduction is regained at H-H intervals of 710 ms or longer (Panel D). The diagram at the bottom discloses the results of the full scan with the occurrence of a supernormal period (short white bar to the left). The refractory period lasts 700 ms (black bar). The arrow points at the end of the T wave.

The main electrocardiographic findings obtained by applying this methodology were:

1. The P-R interval was normal in 38 (80.8%) of the 47 cases;
 2. The HV interval was normal in 8 of the 16 cases in whom a His bundle recording was obtained and ranged between 70 to 155 ms (mean 97 ms) in the other 8;
 3. The QRS interval was narrow in 3 cases in which the AV block was probably located in the His bundle. In the remaining cases, there was a wide QRS with LBBB or RBBB pattern. In 34 cases (77.3%), RBBB was the intraventricular conduction disturbance and many of them also exhibited left anterior or left posterior hemiblock.
- Bilateral or trifascicular AV block are commonly observed, thus supporting that AV block was infranodal in most or all of the cases. In fact, in the 15 cases in whom the His bundle electrogram was recorded; the site of AV block was below this His bundle. In every case there was a total interruption in one or two main fascicles with critical conduction occurring in the remaining diseased but still viable fascicle;
4. The duration of refractoriness in the fascicle responsible for AV conduction or block was always greatly prolonged ranging between 460 and 980 ms (mean $613.9 \text{ ms} \pm 34.2 \text{ ms}$). This prolonged refractoriness was the consequence of a long absolute refractory period with a short or even absent relative refractory period (Fig. 15).
 5. As already mentioned many different AV conduction ratios or periodicities can be observed and 2:1 or

3:2 were the most common, whereas 3:1 or 4:1 were rare. The most remarkable finding was the occurrence of supernormal conduction in 45 (96%) of the 47 cases. The existence of supernormal conduction was supported by the detailed interpretation of the 3:2 pattern of AV conduction.

The 3:2 Periodicity and Supernormal AV Conduction

The mechanism of AV 3:2 periodicity can be explained by the occurrence of 4 physiopathologic paradoxes that are well illustrated in the example of Fig. (13).

Paradox 1 is demonstrated by the fact that in each 3:2 periodicity, P2 is normally conducted although it falls early after the preceding QRS (RP intervals between 460 and 480 ms), whereas P3 is blocked following a much longer interval (680 to 700 ms); **paradox 2** consists on the fact that P2 is normally conducted after previous long cardiac cycle, when refractoriness is expected to be prolonged; **paradox 3** corresponds to the fact that P3 is blocked following a much shorter cardiac cycle, when refractoriness is expected to be shortened and **paradox 4** refers to the fact that the increase in sinus rate first depresses the conduction ratio but a further rise in rate improves the conduction ratio. In conclusion, the 3:2 periodicity occurs because P2 falls in the supernormal phase of conduction, P3 is blocked because it falls on the refractory period and P1 is normally conducted because it falls after refractoriness has finished.

A phenomenon that allows the 3:2 periodicity and the manifestation of the supernormal phase of conduction is the presence of ventriculophasic arrhythmia [39]. In fact, It plays an essential role in paradox 1 and favors the maintenance of the 3:2 periodicity because the P1-P2 interval containing the first QRS of each pair is the shortest,

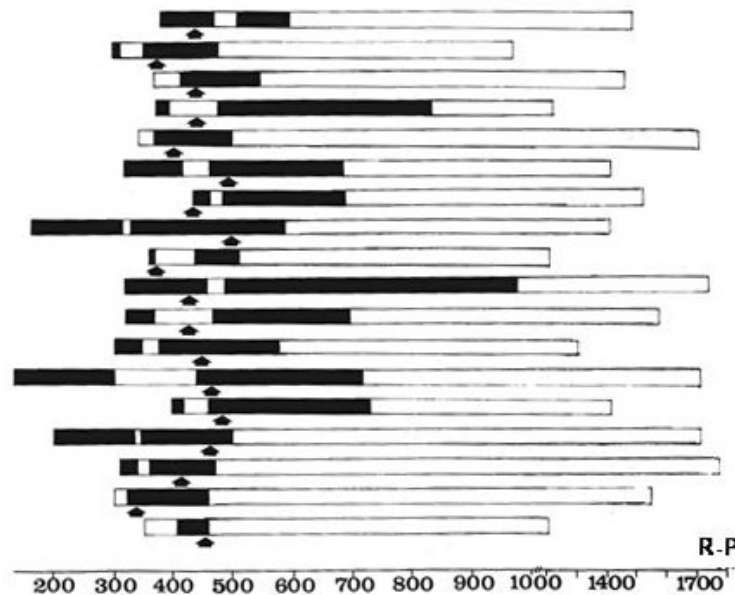


Fig. (15). Position of the supernormal phase (white bar to the left) within the cardiac cycle in 18 cases of Mobitz II AV block. The arrows indicate the relationship of the supernormal period with the end of the T wave. The black bar to the right represents the total duration of refractoriness. The white bars to the right indicate the RR intervals during which P waves are conducted to the ventricles with a PR interval similar to the one observed during the supernormal phase. Normal AV conduction after longer pauses ruled out the presence of phase 4 blocks.

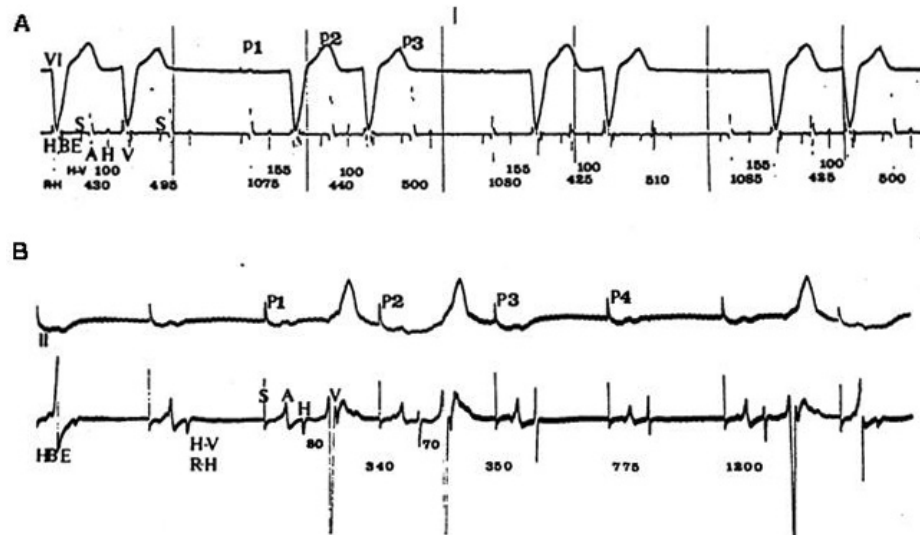


Fig. (16). Mobitz II block with 3:2 periodicities at a constant rate of stimulation showing shortening of the H-V interval. **A:** lead VI and His bundle electrogram were simultaneously recorded. The second HV (and P-R) interval of each 3:2 period shortens 55 ms. **B:** simultaneous recording of lead II and His bundle electrogram. Like in the example in A, the second HV interval shortens 10 ms. The HV and RH intervals in A and B are in milliseconds. These examples demonstrate that 3:2 Mobitz II AV block may occur in the absence of ventriculophasic arrhythmia.

allowing P2 to fall on the supernormal phase while the P2-P3 interval containing the second QRS is the longest, causing P3 to fall beyond the supernormal phase on the refractory period. Thus, the P3-P1 interval (not containing a QRS) is longer than P1-P2. The presence of a regular ventriculophasic arrhythmia is an important contributing component to maintain the 3:2 periodicity related to ventriculophasic periodicity. Nonetheless, it should be mentioned that the ventriculophasic arrhythmia is not an absolutely necessary condition since supernormal induced 3:2 periodicity may occur with constant or almost constant PP intervals as in the examples illustrated in Fig. (16). When 3:2 periodicity occurs during constant atrial rate either spontaneously or when the atria are paced, supernormality may be also operative in the absence of a ventriculophasic arrhythmia. Under such conditions, P2 falls on a supernormal phase because it occurs following a long pause, whereas P3 falls beyond the supernormal period that has been shifted to the left due to the preceding shorter diastolic interval. Consequently, an underlying supernormal phase may explain the occurrence of 3:2 periodicities in the presence of a constant RP or RH interval. Given these circumstances, what varies is the position of the supernormal phase in accordance with the alternance of the changes of the ventricular cycle length induced by the blocked atrial beats. If supernormality is truly responsible for the second conducted beat (during the 3:2 pattern), the second PR interval may be expected to be, in some cases, shorter than the first due to the occurrence of the supernormal mechanism. This might be attributed to the phasic variations of the vagal tone acting on the AV or to a true shortening of the HV interval due to acceleration of conduction during the supernormal period [38], as shown in Fig. (16). This phenomenon occurring in 4 out of 47 cases can be considered another paradox of the 3:2 periodicity which can only be demonstrated recording the His-bundle electrogram [38].

The position of the supernormal phase and the duration of refractoriness in cases of Mobitz II AV block are similar to those observed in the cases of phase 3 intermittent bundle branch block as showed in Figs. (7 and 15). This similarity reflects that Mobitz II second degree AV block is also the manifestation of phase 3 block in the intraventricular conducting tissue while conduction is interrupted in the remaining fascicles.

The relationship between Mobitz II block and supernormality is also illustrated in Fig. (17) from a patient with RBBB and left posterior hemiblock with paroxysmal phase 3 AV block, Mobitz II AV block and 1:1 supernormal AV conduction. The first part of the top strip shows 1:1 conduction with a constant PP interval of 640 ms from P1 to P6. P wave 7 falling 40 to 50 ms later shows AV block followed by other two blocked P waves. It is assumed that 1:1 conduction is possible (P1 to P6) because each impulse hits precisely the supernormal phase of each preceding cycle. P7 falls at the end of the supernormal period but it is still conducted in a concealed fashion inducing block of P8, which in turn, elicit concealed conduction to P9. Since concealed conduction is a self limited phenomenon P10 resumes conduction with a typical 3:2 Mobitz II period followed by other episode of paroxysmal AV block. The bottom strip also shows 1:1 supernormal AV conduction and repetitive AV block. The relationship between concealed conduction and supernormality has been admirably discussed by Pick and co-workers [20].

It might be concluded that supernormal conduction is actually a frequent component of the electrophysiologic picture of Mobitz II block. Furthermore, the estimation of refractoriness and the position of the supernormal phase are quite similar when evaluated from the electrophysiologic studies or from the conventional electrocardiographic recordings, which support the information presented in Figs. (13-17).

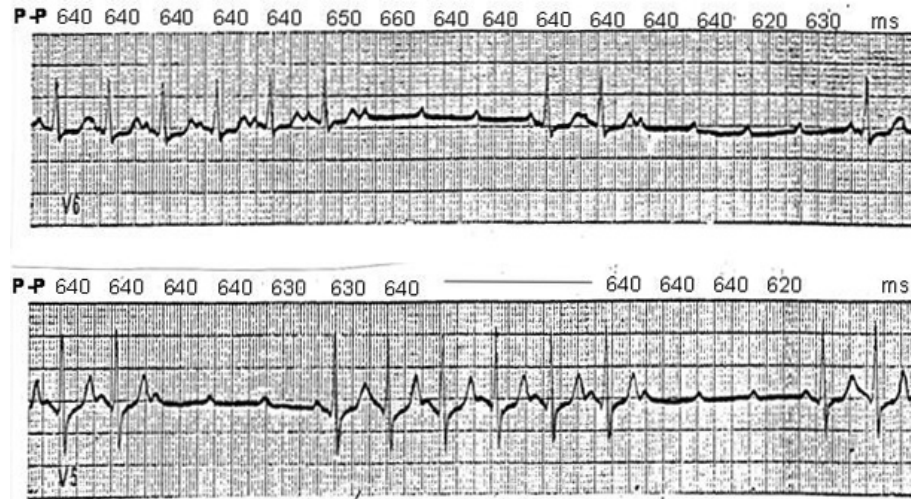


Fig. (17). Relationship between supernormal conduction, paroxysmal phase 3 block (tachycardia dependent block) and concealed conduction in a patient with permanent RBBB and left posterior hemiblock and intermittent conduction in the anterior division of the LBB. PP intervals are in milliseconds (see text for further description).

SUPERNORMAL CONDUCTION IN THE ACCESSORY PATHWAYS

We have shown that a phase of supernormal conduction in abnormal tissues can be uncovered in some patients with intermittent bundle branch block, advanced AV block and Mobitz type II second degree AV block and in each instance; the phenomenon was associated with a prolonged refractory period in the abnormal segment of the His-Purkinje system. The occurrence of supernormal conduction in the accessory pathway was first reported by Mc Henry *et al.* [40] followed by few articles describing the same phenomenon [41-47]. The occurrence of supernormal conduction in patients with ventricular pre-excitation was systematically investigated by Przybylski *et al.* whenever the refractory period of the anomalous pathway was clearly prolonged [41]. This study included 21 patients with a history of intermittent ventricular pre-excitation, a fact that obviously implied a prolonged anterograde refractory period in the accessory pathway. In 4 out of the 21 patients with a relatively short refractory period (300 to 420 ms), refractoriness was intentionally prolonged with ajmaline to unmask the supernormal phase. Programmed atrial stimulation unveiled a supernormal phase of conduction in 16 of 21 cases during premature atrial stimulation [41]. The refractory period of the anomalous bundle was scanned with premature impulses introduced at progressively shorter intervals by 10 ms steps after eight sinus or paced beats at a cycle length slightly shorter than the sinus cycle length. The scanning was performed until the atrial refractory period was reached, whether or not a supernormal phase was uncovered. A supernormal phase of conduction was defined as a range of A1-A2 or P1-P2 intervals showing conduction through the accessory pathway always occurring inside its refractory period. Supernormal conduction occurred in 7 patients whose refractory period ranged from 480 to 980 ms which was shorter than or similar to the spontaneous sinus cycle length and ventricular pre-excitation became apparent with a slight slowing of the heart rate. Conversely, in 10 patients whose refractory period ranged between 1000 to more than 4000 ms, ventricular pre-excitation was not spontaneously manifest. In 6 out of these 10 patients, a su-

pernormal phase of conduction in the accessory pathway was demonstrated during induced premature atrial beats.

The fact that supernormal conduction over the accessory pathway may be the only manifestation of the apparent existence of total block in the anomalous bundle in patients that were known to have ventricular pre-excitation that disappeared from the ECG during follow-up is a meaningful clinical finding (see later). Fig. (18) illustrates this condition in a patient in whom ventricular pre-excitation failed to occur even after pauses longer than 4,000 ms. In each panel, the second beat is the last of a series of eight sinus beats at a cycle length of 910 to 1,060 ms showing normal intraventricular conduction. The third beat corresponds to induced atrial premature beats at progressively shorter intervals. At an A1-A2 interval of 660 ms (or longer) and 490 ms (or shorter) ventricular activation was normal. However, ventricular pre-excitation was unmasked at A1-A2 intervals between 500 and 650 ms. It is remarkable how the supernormal conduction over the anomalous bundle was the only evidence by which anterograde conduction could be restored.

Fig. (19) illustrates a representative example of a patient with a relatively short refractory period in the accessory pathway. In each panel, the first beat is the last of a series of eight sinus beats with a cycle length of 880 to 900 ms and shows ventricular pre-excitation with a QRS configuration suggesting a fusion beat, whereas the second beat is the result of the premature atrial stimulation at progressively shorter intervals. At an A1-A2 interval of 490 ms, the premature response conducted over the anomalous bundle exhibits a greater degree of ventricular pre-excitation because of the normal slowing of conduction in the AV node reflected in a prolonged A2-H2 interval. At an A1-A2 interval of 480 ms, anterograde conduction is blocked in the accessory pathway and ventricular activation proceeds only through the normal pathway indicating that this is the limit of the anterograde refractory period in the accessory bundle. Shortening of the A1-A2 intervals shows that when an interval of 430 ms is reached, this resulted in conduction over the accessory pathway with an even greater degree of pre-excitation and the H2 deflection is not longer seen because it is concealed within

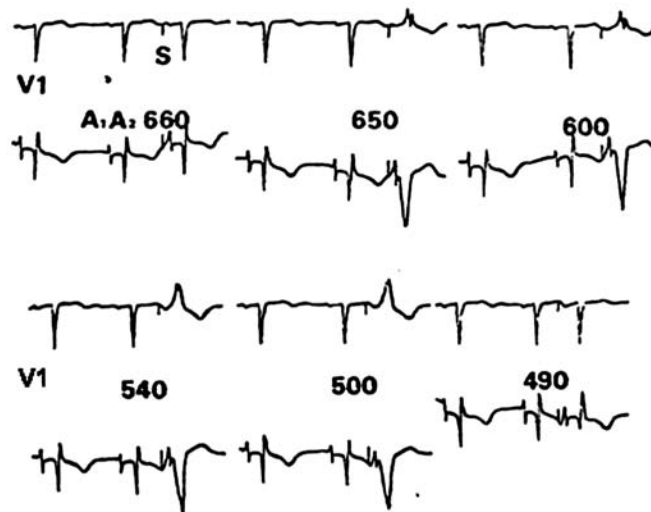


Fig. (18). Supernormal conduction in the absence of manifest ventricular pre-excitation. The second beat in each panel is the last of a series of eight sinus beats and the third beat results of atrial stimulation at progressively shorter intervals. Supernormal conduction is the only means by which anterograde conduction over the accessory pathway could be demonstrated (see text for further details).

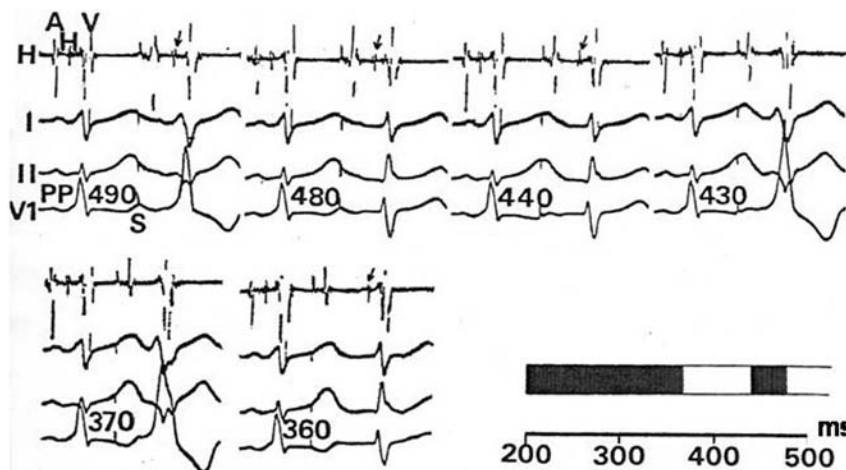


Fig. (19). Supernormal conduction over the accessory pathway during premature atrial stimulation. Simultaneous recordings of His bundle electrogram, leads I, II and V1 at A1-A2 intervals between 360 and 490ms. In each panel the first beat is the last of a series of eight spontaneous sinus beats at a cycle length of 800 to 900 ms showing a small degree of pre-excitation (fusion beats between pre-excited and normally excited ventricle). PP intervals are in milliseconds. The diagram (bottom right) depicts the total duration of refractoriness in the accessory bundle (black bar) and the white bar (to the left), the supernormal phase of conduction (see text for a more detailed description).

the ventricular electrogram (V). This is interpreted as due to supernormal conduction in the anomalous bundle which is observed up to an A1-A2 interval of 370 ms, with block again at 360 ms. Thus, the supernormal period lasts 60 ms (from 370 to 430 ms), while the total refractory period measures 480 ms.

Supernormal conduction in the anomalous bundle shows striking similarities to those observed in the His-Purkinje system. The main common facts are: **1.** An abnormally prolonged refractory period; **2.** The supernormal phase shows a relatively constant position close to the end of the T wave of the surface electrocardiogram; **3.** The supernormal phase shifts to the right at slow rates and to the left at fast rates; **4.** Due to the presence of concealed retrograde activation of the depressed accessory bundle the supernormal phase shifts to the right after a blocked impulse and concealed retrograde activation of the accessory pathway must occur during the basic rhythm in order to trigger a phase of supernormal con-

duction; **5.** Two to one supernormal conduction (observed in 4 patients) can readily be induced at appropriately rapid rates and the underlying electrophysiologic mechanism is similar to the one observed in His-Purkinje system; **6.** The duration of the supernormal phase discloses a similar range; **7.** The QRS complex is of similar morphology either during the supernormal conduction or late in diastole after the end of the effective refractory period; **8.** In some patients the supernormal phase can be unmasked by the effect of conduction depressing drugs which prolong refractoriness in the anomalous bundle.

Remarkably, supernormal conduction is much more frequent in cases of ventricular pre-excitation than in the His-Purkinje system. The main explanation for this finding occurring either spontaneously or provoked intentionally, is that the premature atrial impulses delivered to unmask the supernormal phase have a direct excitation impact to the accessory pathway while in the diseased His-Purkinje sys-

tem, the premature impulses are more prone to suffer conduction delay in the AV node or in the proximal His-Purkinje system preventing the direct hitting in the target lesion of the diseased conducting tissue as early as needed to uncover the supernormal phase.

The demonstration of supernormal excitability and conduction in the accessory pathways is of clinical relevance. In some cases, it may prove the presence of concealed ventricular pre-excitation whenever the normal sinus beats or any supraventricular rhythm are blocked because they fall during the refractory period. As already shown, there are cases in which supernormal conduction is the only manifestation of pre-excitation.

SUPERNORMAL CONDUCTION IN THE ANOMALOUS BUNDLE DURING ATRIAL TACHYARRHYTHMIAS

It has been pointed out that the duration of the refractory period of the accessory pathways is the main factor determining the ventricular response and the risk of ventricular fibrillation and sudden cardiac death in patients with pre-excitation during atrial fibrillation [41-47]. However, the existence of a supernormal phase of conduction in patients with anomalous pathways and a marked prolongation of the refractory period may be clinically relevant whenever sustained rapid propagation through the supernormal period of the pathway may cause extremely fast ventricular responses during atrial tachycardia, atrial flutter or atrial fibrillation. Propagation of the atrial impulses may follow a 1:1 relationship when the atrial cycle length equals that of the supernormal phase of conduction, as exemplified in Figs. (18 and 19).

The presence of supernormal conduction through the anomalous pathways during any form of atrial tachyarrhythmia, particularly in atrial fibrillation, implies a risk of ventricular fibrillation or severe hemodynamic compromise. This may be disregarded by the cardiologist in patients with a prolonged refractory period disclosed by the fact that they exhibit intermittent pre-excitation or a concealed form of anomalous pathway with complete absence of pre-excitation in the ECG. Fig. (20) shows the tracing of a 54-year-old man with recurrent syncopal episodes that had no evidence of pre-excitation during sinus rhythm or premature atrial stimulation during the electrophysiologic study. The baseline ECG did not show ventricular pre-excitation, either after pauses of 1,200 ms by carotid sinus massage or during premature atrial stimulation. Interestingly, ventricular stimulation disclosed retrograde conduction to the atria over an anterolateral left-sided anomalous bundle. During intravenous infusion of isoproterenol, early and late ventricular pre-excitation was observed (not shown). A full scan of the cardiac cycle, disclosed the existence of supernormal conduction in the accessory pathway. Fast atrial pacing caused bursts of very rapid ventricular rates conducted during the supernormal phase (up to 300 beats/min accompanied by hemodynamic instability). It may be assumed that if atrial flutter or atrial fibrillation occurs during a physical or emotional stress, conduction through the anomalous bundle during the supernormal phase may evoke extreme high ventricular rates and risk of ventricular fibrillation. Fig. (21) illustrates another example of 1:1 supernormal conduction over an accessory pathway. A 26-year-old man underwent radiofrequency ablation (apparently successful) of a right-sided anomalous bundle. After the procedure, ventricular pre-excitation was absent

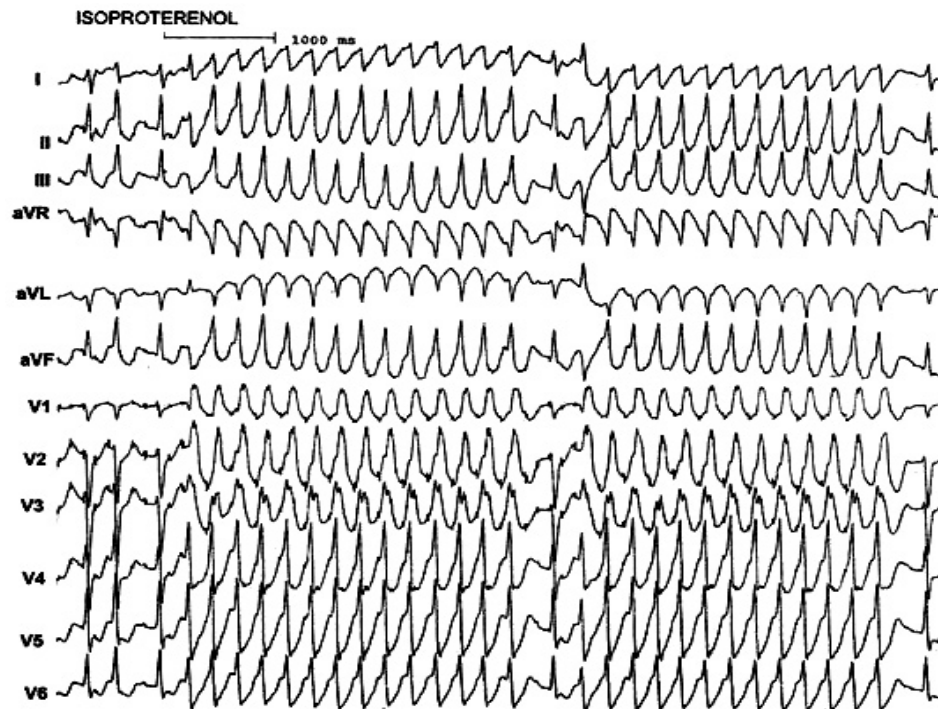


Fig. (20). Anterograde supernormal conduction through the accessory pathway of a patient with recurrent syncopal attacks. Twelve leads simultaneously recorded during the IV isoproterenol infusion from a patient with absence of ventricular pre-excitation on the ECG at baseline. In the electrophysiologic study, rapid atrial stimulation caused a very fast ventricular response (300 beats/min) during the supernormal phase of excitability and conduction of the accessory pathway (see text for more details).

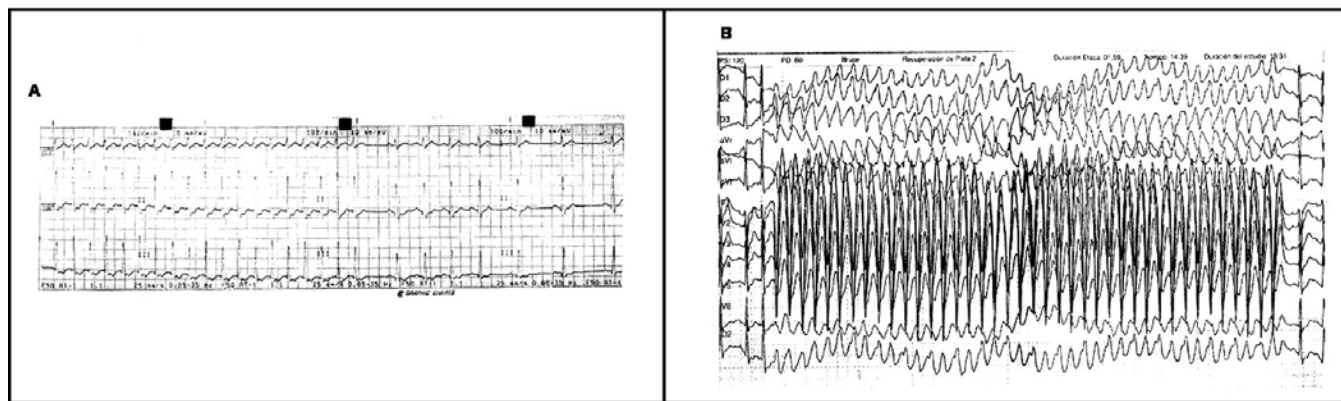


Fig. (21). A and B. Supernormal conduction through the accessory pathway as the only manifestation of pre-excitation (see full description in the text).

either during normal sinus rhythm or during atrial premature beats. After the procedure the patient experienced almost incessant palpitations during physical or emotional stress. The ECG in Fig. (21), panel A shows a continuous strip of leads I, II and III recorded in an episode of orthodromic atrioventricular reentrant tachycardia at 190 beats/min spontaneously interrupted by an atrial premature beat and followed by sinus rhythm that slowed down to 60 beats/min without ventricular pre-excitation. Thus, the refractory period of the anomalous bundle is at least of 1,000 ms. The P waves that resulted from retrograde conduction over the accessory pathway during tachycardia are readily seen as inverted deflections in the ST segment of leads II and III indicating that retrograde conduction through the anomalous bundle was still preserved. Fig. (21), panel B was recorded during a 12-lead stress test. When sinus tachycardia is about 135 beats/min, an atrial premature beat triggers an episode of fast supraventricular tachycardia (flutter? fibrillation?) with conduction through the accessory pathway at a heart rate of 290 beats/min. The arrhythmia terminates spontaneously. The first 3 beats (the third one is an atrial premature beat) and the last one are conducted to the ventricles without pre-excitation. The pre-excited beats during the paroxysm show the same QRS pattern as that of the ECGs before the first attempt of radiofrequency ablation. A second electrophysiologic study demonstrated the presence of supernormal conduction during a full scan of the diastolic interval with the same coupling interval observed during the salvos. Ablation of the anomalous pathway resulted in complete abolition of the arrhythmia and symptoms during follow-up.

Fig. (22) is an exceptional case showing retrograde supernormal conduction unmasked by right ventricular pacing. The patient consulted because of multiple episodes of reentrant atrioventricular tachycardia without any evidence of ventricular pre-excitation in the ECG. During programmed right ventricular pacing the retrograde refractory period of the accessory pathway measured 420 ms. Retrograde supernormal conduction to the atria occurred at S1-S2 intervals between 350 and 300 ms. A further shortening of the S1-S2 interval to 290 ms shows again retrogradely blocked to the atria. The diagram at the bottom depicts the position of the retrograde supernormal phase (left white bar) within the refractory period (black bar).

VENTRICULAR PREMATURE BEATS AND SUPERNORMAL EXCITABILITY AND CONDUCTION

Ventricular arrhythmias may be related either to abnormalities of impulse formation or abnormalities of impulse propagation [48]. However, their exact underlying mechanism is not only sometimes misinterpreted but also difficult to assess. The classical reentry model postulated by Schmitt and Erlanger [49] requires the existence of a micro reentry loop in which two branches of Purkinje tissue arising from a common bundle are connected by ventricular muscle. Excitability and conduction are assumed to be normal in one of the Purkinje limbs and in the ventricular muscle, while the other Purkinje limb discloses abnormal anterograde conduction due to prolonged refractoriness, whereas retrograde conduction is preserved. If retrograde conduction through the depressed segment occurs with sufficient delay, the impulse reaches the proximal tissue when it has already recovered eliciting its re-excitation and provoking a ventricular premature beat. This reentry may repeat itself as a circus movement causing a ventricular tachycardia.

The main requisite for the occurrence of a reentry in this scheme is that the anterograde refractory period of the abnormal segment of the circuit must be longer than the sinus cycle length (or any other basic rhythm). The abnormal segment of the reentry circle may show different degrees or types of block (unidirectional block, Mobitz I or Mobitz II blocks) related to changes in heart rate (tachycardia-dependent block) as it has been described in the His Purkinje system. As in intermittent bundle branch block, anterograde conduction will be normal when the impulse falls beyond the refractory period and will be blocked when it occurs before recovery is completed. Moreover, it is possible to postulate the existence of a supernormal phase of excitability and conduction within the refractory period of the diseased limb of the reentry circuit. Thus, the ventricular premature beat may not be present when the sinus impulse reaches the supernormal phase of excitability of conduction or when it occurs after the end of the refractory period of the abnormal limb of the circuit due to the occurrence of anterograde conduction, which stops the reentry mechanism. Nahum and Hoff [50] and others [51-52] advanced this hypothesis to explain the occurrence of ventricular extrasystoles from a combination of experimental and clinical data. The relationship between

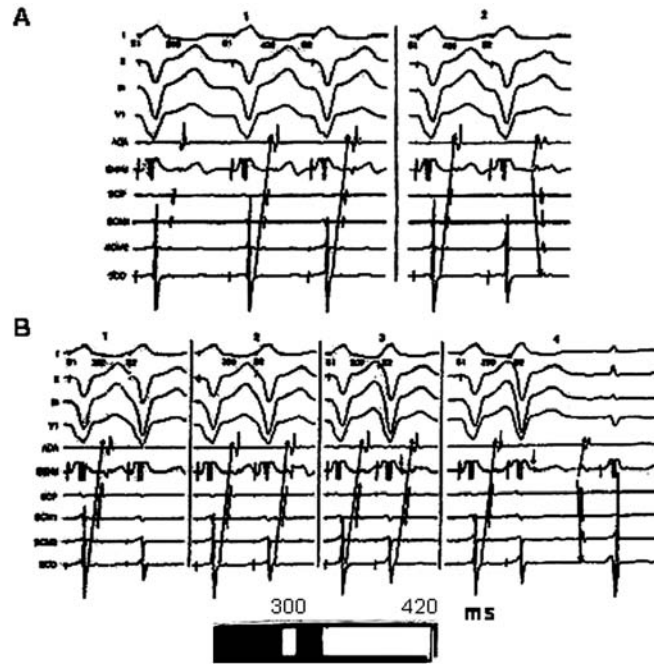


Fig. (22). Retrograde supernormal conduction uncovered by programmed right ventricle pacing. The diagram at the bottom discloses the total refractory period (black bar) and the supernormal phase of conduction (white bar to the left). See text for a more detailed description.

the timing of ventricular extrasystoles during the cardiac cycle and the heart rate was also extensively described by Nau *et al.* [53] and although the participation of supernormal excitability was not considered in their paper, they stated that slowing of the heart rate suppressed the ectopic activity in all patients with coupled ventricular extrasystoles. Moreover, they describe some zones of silent ectopic activity at both ends of the range of cardiac rates. This might be explained by the presence of supernormal excitability.

THE GAP PHENOMENON MAY IMITATE SUPER-NORMAL AV CONDUCTION

The “gap in AV conduction” was first described by Moe and associates [54] in experiments performed in the canine

heart designed to evaluate the characteristics of AV conduction. During atrial premature beats evoked progressively earlier in the cardiac cycle, it was noted that conduction to the ventricles occurred first with prolonged PR intervals. Decreasing prematurity induced AV block. However, as the atrial beats were even more premature conduction resumed. The use of His bundle recordings disclosed the electrophysiologic mechanism of this phenomenon. According to the site of initial block in the His-Purkinje system or in the A-V node and the site of proximal delay which allows recovery of the distal and initial site of block, six types of gap have been described for anterograde conduction and two for retrograde conduction [17, 18, 23, 24, 55]. Table 2 summarizes the different types of anterograde and retrograde gaps.

Table 2. Gap phenomena during AV conduction.

Type	Site of Initial Block	Site of Proximal Delay
1	HPS	AV node
2	HPS (distal)	HPS proximal
3	HPS	bundle of His
4	HPS or AV node	atrium
5	distal AV node	proximal AV node
6	HPS	none (supernormality)
Gap phenomena during VA conduction		
Type	Site of Initial Block	Site of Proximal Delay
1	AV node	HPS
2	HPS	HPS

HPS: His-Purkinje system - From Damato A *et al.* [55].

As an example, only one of the different forms of AV gaps is shown in Fig. (23).

The demonstration of type I gap requires that the effective refractory period of the His-Purkinje system exceed the effective refractory period of both the atrium and the functional refractory period of the AV node. These requirements also apply to types 2 and 3 gap phenomena.

PATHOPHYSIOLOGIC MECHANISM OF SUPERNORMAL EXCITABILITY AND CONDUCTION

All along this review we have shown that supernormal excitability and conduction may occur in normal and abnormal cardiac tissues. The mechanisms operating in normal specialized conducting fibers and in ordinary muscle have been extensively discussed and explained based on experimental and clinical evidence. However, why supernormal excitability and conduction occur when conduction is clearly abnormal is still unclear and a matter of dispute. What is clear, however, taking into account the analysis of clinical cases, is that two conditions are mandatory for the occurrence of supernormal conduction in abnormal cardiac tissues: 1. an abnormally prolonged refractory period and 2. a dip of supernormal excitability buried within the refractory period. Levi *et al.* [35] hypothesized that there are two possible ways in which a dip of supernormality may occur: cathodal and anodal supernormality.

Cathodal supernormality refers to a supernormal dip uncovered by a depolarizing current occurring in normal cardiac tissues as already described in this article. However, cathodal supernormality is unlikely to account for the findings of supernormal conduction in abnormal cardiac tissues either. The most important objections are: 1. the supernormal conduction period always occurs long before the end of the total refractory period regardless its duration. Cathodal supernormality has always been shown to occur at the end of the relative refractory period (end of phase 3 of the action potential) [5, 56]; 2. Supernormal conduction can be induced by weak doses of conducting-depressing drugs but it is difficult to account for the appearance of supernormal excitability when a selective depression of excitability is induced.

The fact that *anodal supernormality* is more closely related to the end of recovery in ventricular muscle than to the end of recovery of the damaged fascicle (either intraventricular conducting tissue or accessory pathways) suggests that anodal supernormality induced by ventricular repolarization may be at play. In order to have anodal stimulation, the density of the repolarizing current provided by the adjacent myocardium must be strong enough to induce a significant change in the affected fascicle. For this to happen, repolarization of the ventricular mass should be shorter than in the critically damaged fascicle. The classical experimental study by Kölliker and Mueller [57] showed that ventricular repolarization may excite a nervous trunk

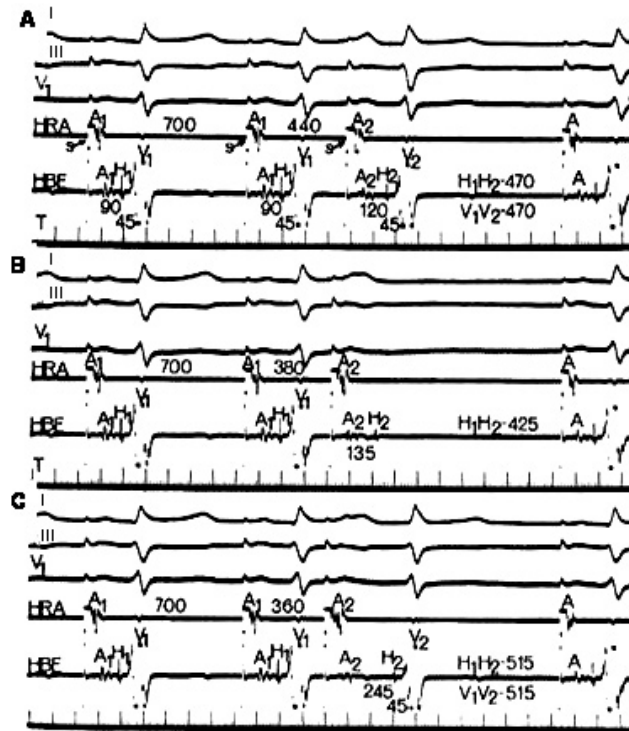


Fig. (23). Type I gap in AV conduction. In each panel, recordings from top to bottom are leads I, III and V1, high right atrium (HRA), His bundle electrogram (HBE) and time lines at 10 and 100 ms. A1, H1, V1 are the electrograms of the basic drive beats, while A2, H2 and V2 correspond to the premature beats delivered progressively earlier from 440 to 360 ms; S: stimulus artifact. **A:** the basic drive rate A1-H1 is 700 ms. A premature atrial impulse (A2) is delivered at A1-A2 of 440 ms; **B:** A2 blocks within the His-Purkinje system. The effective refractory period (ERP) of the His-Purkinje system (HPS) is encountered at an H1-H2 interval of 380 ms. In **C**, AV conduction resumes at a shorter A1-A2 interval (360 ms). Note the increase in AV nodal delay (135 to 245 ms). The resulting H1-H2 interval increases from 425 to 515 ms and is now outside the ERP of the HPS. During resumption of AV conduction, the QRS complexes may be normal or may show intraventricular aberrant conduction (modified from Damato A *et al.* [56]).

and thus, it may well be the case acting upon a conducted fascicle. Brooks *et al.* [7] demonstrated that anodal excitation does not occur at the make but at the break. Likewise, an electrotonus (stimulating with sub-threshold intensity) initially causes a depression of excitability followed by an enhancement at the break [7]. The initial depression of excitability is due to hyperpolarization while the threshold remains constant. However, since hyperpolarization causes a removal of inactivation, the threshold falls and break re-excitation may occur. It has also been shown that weak anodal stimulation may cause local or graded responses [56]. The same investigators demonstrated that the excitability threshold is lower for cathodal current during diastole but lower for anodal current during recovery and that the recovery curve of excitability during anodal stimulation exhibits a major dip of true anodal supernormality.

In conclusion, both cathodal and anodal supernormality may explain most of the facts for the occurrence of a supernormal phase of conduction in the intraventricular conducting tissues both in normal or abnormal circumstances; and also in accessory pathways.

CONCLUSION

The present review shows that supernormal conduction may be much more common than previously thought, particularly when the clinical conditions are present and the phenomenon is systematically searched in patients with advanced AV block or intermittent conduction in the His-Purkinje system or in the case of accessory pathways. One of the main still unresolved problems will be to elucidate the exact mechanism of this almost forgotten electrophysiologic curiosity, which, occasionally, plays a relevant role in dangerous arrhythmias.

CONFLICT OF INTEREST

The authors confirm that this article content has no conflict of interest.

ACKNOWLEDGEMENTS

The authors wish to thank the secretarial skill of Mrs Cecilia Mc Keon.

DISCLOSURE

This work was supported in part by the Fundación de Investigaciones Cardiológicas Einthoven.

REFERENCES

- Adrian ED, Lucas K. On the summation of propagate disturbances in nerve and muscle. *J Physiol* 1912; 44: 68-124.
- Hoff HE, Nahum LM. The supernormal period in the mammalian ventricle. *Am J Physiol* 1938; 124: 591-5.
- Weidman S. Effects of calcium ions and local anesthetics on electrical properties of Purkinje fibers. *J Physiol* 1955; 129: 568-82.
- Childers RW, Merideth J, Moe GJ. Supernormality in Bachmann's bundle. An *in vivo* and *in vitro* study. *Circ Res* 1968; 22: 363-70.
- Spear JF, Moore EN. Supernormal excitability and conduction in the His-Purkinje system of the dog. *Circ Res* 1974; 35: 782-92.
- Merideth J, Méndez C, Mueller WJ *et al.* Electrical excitability of atrioventricular nodal cells. *Circ Res* 1968; 23: 69-85.
- Brooks Ch McC, Hoffman BT, Suckling EE *et al.* (eds). *Excitability of the Heart*. New York, Grune & Stratton, 1955, p 74.
- Cranefield PF, Hoffman BF, Siebens A. Anodal excitation of cardiac muscle. *Am J Physiol* 1957; 190: 383-90.
- Hernández Pieretti O, Morales Rocha J, Barceló JE. Supernormal phase of conduction in human heart demonstrated by subthreshold pacemaker stimulation. *Br Heart J* 1969; 31: 553-8.
- Burchell HB. Analogy of electronic pacemaker and ventricular parasystole with observations on refractory period, supernormal phase and synchronization. *Circulation* 1963; 27: 878-9.
- Mc Henry PL, Knoebel SB. Supernormal excitation of the human heart. *Indiana State Med Assoc* 1965; 58: 125-8.
- Zimenthal AJ, Zoll PM. Quantitative studies of ventricular refractory periods in man. *Trans Assoc Ann Phys* 1962; 75: 285-92.
- Solof LA, Fewel JW. The supernormal phase of ventricular excitation in man. Its bearing on the genesis of ventricular premature systoles and a note on atrioventricular conduction. *Am Heart J* 1960; 59: 869-74.
- Fisch Ch (ed). *Electrocardiography of Arrhythmias*. Philadelphia, Lea & Febiger, 1990 p 246.
- Rosenbaum MB, Levi RJ, Elizari MV, Vetulli HM, Sánchez RA. Supernormal excitability and conduction. *Cardiology Clinic* 1983; 1: 75-92.
- Antzelevitch C, Litovsky SH. Epicardium versus Endocardium. *Electrophysiology and Pharmacology*. In: Zipes DJ, Jalife J (eds) *Cardiac Electrophysiology*, Philadelphia, 1990 pp 386.
- Moe GK, Childers RW, Merideth J. An appraisal of "supernormal" AV conduction. *Circulation* 1968; 38: 5-28.
- Gallagher JJ, Damato AN, Varghese PJ, Caracta AR. Alternative mechanisms of apparent supernormal atrioventricular conduction. *Am J Cardiol* 1973; 3: 362-71.
- Childers RW. Supernormality. In: Ed Fisch Ch, Brest AN. *Complex Electrocardiography*. Philadelphia: Davis FA, 1978, pp136-58.
- Pick A, Langendorf R, Katz LN. Supernormal phase of atrioventricular conduction. I. Fundamental Mechanisms. *Circulation* 1962; 26: 388-404.
- Lipman BS, Massie E, Kleiger RE. *Clinical Scalar Electrocardiography*. 6th Edition, Chicago Year Book. Medical Publishers Inc. 1972, p 462.
- Schamroth L. The supernormal phase of intraventricular conduction. *Brit Heart J* 1969; 31: 337-42.
- Damato An, Wit AL, Lau SH. Observations on the mechanism of one type of so-called supernormal AV conduction. *Am Heart J* 1971; 82: 725-30.
- Wu D, Denes P, Dhingra R, Rosen K. Nature of gap phenomenon in man. *Circ Res* 1974; 34: 682-92.
- Agha AS, Castellanos A, Wells D, Ross MD, Befeler B, Myerburg RJ. Type I, Type II and Type III gaps in bundle branch conduction. *Circulation* 1973; 47: 325-30.
- Rosenbaum MB, Elizari MV, Levi RJ, Nau GJ. Paroxysmal atrioventricular block related to hypopolarization and spontaneous diastolic depolarization. *Chest* 1973; 63: 678-88.
- Wellens HJJ. Unusual occurrence of non aberrant conduction in patients with atrial fibrillation and aberrant conduction. *Am Heart J* 1969; 77: 158-66.
- Katz LN, Pick A. *Clinical Electrocardiography*. Part I. The Arrhythmias. Philadelphia, Lea & Febiger, 1956, p. 640.
- Segers M. Les blocks intraventriculaires inconstants. *Acta Cardiol* 1951; 6: 272-92.
- Control S, Magri G, Natali G. Premature beats overcoming impaired intraventricular conduction. Supernormal phase of intraventricular conduction. *Am Heart J* 1956; 51: 378-86.
- Mihalic MJ, Fisch Ch. Supernormal conduction of the right bundle branch. *Chest* 1970; 57: 395-7.
- Di Cruz IA. Supernormal intraventricular conduction. *J Electrocardiol* 1971; 4: 240-8.
- Masumi RA, Amsterdam EA, Mason DT. Phenomenon of supernormality in the human heart. *Circulation* 1972; 41: 264-275.
- Tavazzi L, Salerno JA, Bobba P. Intraventricular conduction and supernormal phase in intermittent bundle branch block (Abstract). *Circulation* 1975; 51: Suppl II: II-248.
- Levi RJ, Salerno JA, Nau GJ, Elizari MV, Rosenbaum MB. A Reappraisal of Supernormal Conduction. In: Rosenbaum MB, Elizari MV (eds). *Frontiers of Cardiac Electrophysiology*. The Hague, Martinus Nijhoff Publishers, 1983 p 427.
- Pick A, Langendorf R. Interpretation of Complex Arrhythmias. Philadelphia, Lea & Febiger, 1979, p 276 and 330.

- [37] Katz KL, Pick A. Clinical Electrocardiography. Part I. The Arrhythmias. Philadelphia, Lea & Febiger, 1956 p. 529.
- [38] Halpern MS, Nau GJ, Chiale PA, Elizari MV, Rosenbaum MB. Mechanism of Mobitz II Periodicity. In: Rosenbaum MB, Elizari MV (eds). Frontiers of Cardiac Electrophysiology, The Hague, Martinus Nijhoff Publishers, 1983, p. 465.
- [39] Rosenbaum MB, Lepschkin E. The effect of ventricular systole on auricular rhythm in auriculoventricular block. *Circulation* 1955; 11: 240-61.
- [40] Mc Henry PL, Knoebel S, Fisch Ch. The Wolff-Parkinson-White syndrome with supernormal conduction through the anomalous bypass. *Circulation* 1966; 34: 734-9.
- [41] Przybylski J, Chiale PA, Sánchez RA, Pastori JD, Francos HG, Elizari MV *et al*. Supernormal conduction in the accessory pathway of patients with overt or concealed ventricular pre-excitation. *J Am Coll Cardiol* 1987; 9:1269-78.
- [42] Chang MS, Miles WM, Prystowsky EN. Supernormal conduction in accessory atrioventricular connections. *Am J Cardiol* 1987; 59: 852-6.
- [43] Chen PS, Prystowsky E. Role of concealed and supernormal conduction during atrial fibrillation in the pre-excitation syndrome. *Am J Cardiol* 1991; 68: 1329-34.
- [44] Wellens HJJ, Durrer D. Wolf-Parkinson-White syndrome and atrial fibrillation: relation between refractory period of accessory pathway and ventricular rate during atrial fibrillation. *Am J Cardiol* 1974; 34: 777-82.
- [45] Chiale PA, Albino E, Garro HA *et al*. Supernormal conduction in the anomalous bundles of the Wolff-Parkinson-White syndrome. An overlooked electrophysiologic property with potential clinical implications. *J Cardiovasc Pharmacol Ther* 2007; 12: 181-91.
- [46] Klein GJ, Bashore TM, Sellers TD, Pritchett EL, Smith WM, Gallagher JJ. Ventricular fibrillation in the Wolff-Parkinson-White syndrome. *N Engl J Med* 1979; 301: 1080-85.
- [47] Wellens HJJ. El Síndrome de Wolff-Parkinson-White en Individuos Asintomáticos. In: Elizari MV, Chiale PA (eds). *Arritmias Cardíacas, Fundamentos Celulares y Moleculares, Diagnóstico y Tratamiento*. Buenos Aires, Editorial Médica Panamericana, 2003, p. 511.
- [48] Hoffman BF, Cranefield PF. The physiological basis of cardiac arrhythmias. *Am J Med* 1964; 37: 670-84.
- [49] Schmitt FO, Erlanger J. Directional differences in the conduction of the impulse through heart muscle and their possible relation to extrasystolic and fibrillary contractions. *Am J Physiol* 1928; 87: 326-47.
- [50] Nahum LH, Hoff HE. The interpretation of the U wave of the electrocardiogram *Am Heart J* 1939; 17: 585-98.
- [51] Scherf D, Schott A. The supernormal phase of recovery in man. *Am Heart J* 1939; 17: 357-67.
- [52] Antzelevitch Ch, Jalife J, Moe GK. Characteristics of reflection as a mechanism of reentrant arrhythmias and its relationship to parasystole. *Circulation* 1980; 61: 182-91.
- [53] Nau GJ, Aldariz A, Acunzo RS, Elizari MV, Rosenbaum MB. Clinical Studies on the Mechanism of Ventricular Arrhythmia. In: *Frontiers of Cardiac Electrophysiology*. Martinus Nijhoff Publishers, The Hague 1983, p 239.
- [54] Moe GK, Méndez C, Han J. Aberrant AV impulse propagation in the dog heart. A study of functional bundle branch block *Circ Res* 1965; 16: 261-86.
- [55] Damato AN, Akhtar M, Ruskin J, Caracta A, Lan SH. Gap Phenomena: Anterograde and Retrograde. In: *The Conduction System of the Heart. Structure, Function and Clinical Implications*. Wellens HJJ, Lie KI, Janse MH I(eds). HE Stenfert Kroese, BV Leiden, 1979, pp 404-528.
- [56] Hoffman BF, Cranefield PF. *Electrophysiology of the Heart*. New York, Mc Grow-Hill, 1960, p 217.
- [57] Kölliker A, Mueller H. Nachweis der negativen Schwankung des Muskelstrom and natürlich sich contrahirten Muskel. *Verh Phylo Med Ges* 1956; 6: 528-33.