

# Computed tomographic findings of chest injuries following cardiopulmonary resuscitation

## More complications for prolonged chest compressions?

Seo Jin Jang, MD<sup>a</sup>, Yoon Ki Cha, MD<sup>a,\*</sup>, Jeung Sook Kim, MD, PhD<sup>a</sup>, Han Ho Do, MD, PhD<sup>b</sup>, So Hyeon Bak, MD<sup>c</sup>, Won Gun Kwack, MD<sup>d</sup>

### Abstract

Chest injuries are common and inevitable complications of chest compressions during cardiopulmonary resuscitation (CPR). This study aimed to investigate lung parenchymal and thoracic skeletal injuries after CPR by using computed tomography (CT) and to analyze the correlation between the duration of CPR and related complications.

We examined 43 non-traumatic cardiac arrest patients who were successfully resuscitated after CPR and had chest CT scans within 24 hours of CPR. Lung parenchymal injuries were assessed by quantifying the lung contusion score (LCS) on the CT images, and each skeletal injury was investigated by classifying the location and the distribution. Other CPR-related chest injuries were also described, such as pleural effusion/hemothorax, pneumothorax, and retrosternal hematoma. Statistical analysis was conducted to determine whether the duration of CPR was correlated with each complication.

Lung contusions were found in all of the patients (mean LCS: 22, range: 5–47). The distribution of lung contusions were predominantly in the bilateral dependent portions of the lungs (41 patients). All of the rib fractures occurred in the anterior arc (43 patients), and the sternal fractures occurred predominantly in the mid-sternal body (31 patients). In patients younger than 70 years old, the number of rib fractures significantly increased among those who underwent CPR for more than 25 minutes compared to those who received CPR for less than 25 minutes (median 4.5 vs 9; mean 8.3 vs 5.6 per person, respectively;  $P = .035$ ). The risk of sternal fracture tended to be higher for patients who received CPR for more than 10 minutes compared to those who received CPR for less than 10 minutes (odds ratio: 3.60; 95% confidence interval: 0.86–15.06;  $P = .079$ ). However, there was no statistically significant correlation between the duration of CPR and LCS or other CPR-related chest injuries.

The duration of CPR was associated with the number of rib fractures and the occurrence of sternal fractures, but it did not affect the extent of CPR-related lung contusions or other CPR-related chest injuries. All of the rib fractures occurred in the anterior arc, while the sternal fractures occurred predominantly in the mid-sternal body. However, since this study was conducted in a single institution, the number of patients included was relatively small, thus limiting the statistical analysis.

**Abbreviations:** AHA = American Heart Association, ALC = area of the lung contusion, ARDS = acute respiratory distress syndrome, CPR = cardiopulmonary resuscitation, CT = computed tomography, ECC = emergency cardiovascular care, EMR = electronic medical records, IQR = interquartile range, LCS = lung contusion score, OR = odds ratio, PaO<sub>2</sub>/FiO<sub>2</sub> = partial pressure of arterial oxygen/fraction of inspired oxygen.

**Keywords:** cardiac arrest, cardiopulmonary resuscitation, chest injury, emergencies, lung injury, multidetector computed tomography

Editor: Abdelouahab Bellou.

This study was supported by the Dongkook Life Science. Co., Ltd., Republic of Korea.

The authors report no conflicts of interest.

The datasets generated during and/or analyzed during the current study are available from the corresponding author on reasonable request.

<sup>a</sup> Department of Radiology, Dongguk University Ilsan Hospital, Dongguk University School of Medicine, <sup>b</sup> Department of Emergency Medicine, Dongguk University Ilsan Hospital, Dongguk University School of Medicine, Goyang, <sup>c</sup> Department of Radiology, Kangwon National University Hospital, Kangwon National University School of Medicine, Chuncheon, <sup>d</sup> Division of Pulmonary, Allergy and Critical Care Medicine, Department of Internal Medicine, Kyung Hee University Hospital, Seoul, South Korea.

\* Correspondence: Yoon Ki Cha, Department of Radiology, Dongguk University Ilsan Hospital, 27, Dongguk-ro, Ilsandong-gu, Goyang-si, Gyeonggi-do 10326, South Korea (e-mail: [sublime256@naver.com](mailto:sublime256@naver.com)).

Copyright © 2020 the Author(s). Published by Wolters Kluwer Health, Inc.

This is an open access article distributed under the terms of the Creative Commons Attribution-Non Commercial License 4.0 (CCBY-NC), where it is permissible to download, share, remix, transform, and buildup the work provided it is properly cited. The work cannot be used commercially without permission from the journal.

How to cite this article: Jang SJ, Cha YK, Kim JS, Do HH, Bak SH, Kwack WG. Computed tomographic findings of chest injuries following cardiopulmonary resuscitation: more complications for prolonged chest compressions?. *Medicine* 2020;99:33(e21685).

Received: 28 January 2020 / Received in final form: 6 July 2020 / Accepted: 9 July 2020

<http://dx.doi.org/10.1097/MD.00000000000021685>

## 1. Introduction

Cardiopulmonary resuscitation (CPR), first reported by Friedrich in 1891, has served as a crucial method for reviving patients suffering from cardiac arrest from various causes.<sup>[1]</sup> Chest compression creates blood flow by increasing the intrathoracic pressure and directly compressing the heart, which in turn generates blood flow and oxygen delivery to the myocardium and brain.<sup>[2]</sup> The American Heart Association (AHA) periodically publishes Guidelines Update for CPR and Emergency Cardiovascular Care (ECC). The newest guidelines emphasized the importance of more forceful and faster chest compressions. The 2015 AHA Guidelines Update for CPR and ECC recommended that rescuers perform chest compressions to a depth of at least two inches or five cm for an average adult, and at a rate of 100 to 120 beats per minute.<sup>[3]</sup>

CPR can exert excessive physical force on the chest of the patient, as it involves artificially circulating the blood through repeated sternal compression to rescue the patient from cardiac arrest. Thus, chest injury is an inevitable complication of chest compressions during CPR.<sup>[4]</sup> Previous studies have reported that CPR-related chest injuries range from non-complicated skeletal injuries to life-threatening injuries, such as mediastinal hemorrhage or large pneumothorax.<sup>[2,5–7]</sup>

Prompt radiologic diagnosis of CPR-related injuries can help properly diagnose and manage resuscitated patients. This study assessed the relationship between the duration of CPR and CPR-related chest injuries, including skeletal, lung parenchymal, and additional chest injuries. We also conducted a quantitative analysis of lung contusions from chest CTs.

## 2. Methods

### 2.1. Patients and CT examinations

This retrospective study was approved by the Institutional Review Board of our hospital (IRB No. 2019-04-024). Between December 2009 and February 2019, a total of 52 patients who were resuscitated by CPR underwent chest CTs at the institution within 24 hours after CPR to investigate the cause of the sudden cardiac arrest and the complications from CPR.

Patients were excluded from the study if they had traumatic cardiac arrest ( $n=6$ ), preexisting parenchymal pulmonary disease ( $n=2$ ), or preexisting pulmonary thromboembolism ( $n=1$ ). One patient was included despite having a stable tuberculosis lesion in the right upper lobe because the extent of the lesion was small. Ultimately, 43 patients who underwent chest CTs after CPR were included in the study.

Two multi-detector CTs were used for the emergency patients: the Somatom Sensation 64 scanner (64 slices; Siemens Medical Solutions, Germany), which has been used since 2005, and the Somatom Definition AS+ (128 slices; Siemens Medical Solutions, Germany), which has been used since 2011.

### 2.2. Data collection

The patients' electronic medical records (EMR) were retrospectively reviewed to evaluate the cause of the cardiac arrest, any underlying disease, the duration of CPR, the CPR provider, the presence of acute respiratory distress syndrome (ARDS) 48 hours after CPR, and the outcome of each patient. The cause of the cardiac arrest was determined based on a combination of the clinical, imaging, and laboratory findings, and it was classified

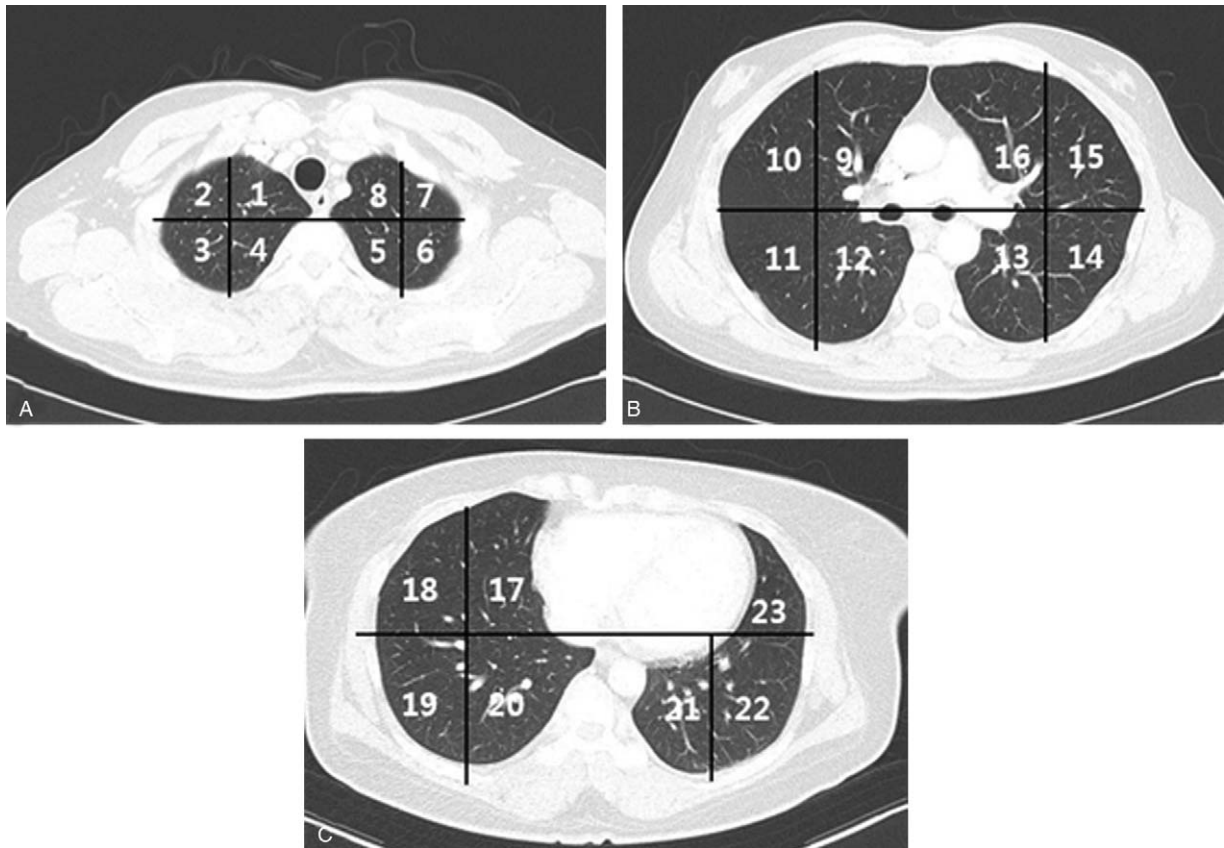
into cardiac, respiratory, cerebral, metabolic, septic, drug overdose, and undetermined groups<sup>[8]</sup>: cardiac causes included myocardial infarction and heart failure; respiratory causes included pneumonia and asphyxia; cerebral causes included hypoxic brain injury, intracranial hemorrhage, and acute infarction; metabolic causes included multi-organ failure due to metastasis as well as acute and chronic renal failure; and septic causes included bowel perforation as well as multiple osteomyelitis and septic shock with unknown causes.

The CPR providers were classified as bystanders or healthcare providers. ARDS was defined by the updated Berlin definition: acute onset respiratory failure with bilateral opacities on chest radiograph or CT that cannot be explained by pleural effusion, atelectasis, or nodules, and decreased oxygenation ( $\text{PaO}_2/\text{FiO}_2$  (partial pressure of arterial oxygen/fraction of inspired oxygen) ratio decreased to less than 300 mmHg with a positive end-expiratory pressure value of at least 5 cmH<sub>2</sub>O), which could not be explained by cardiac failure or fluid overload during the first 48 hours after resuscitation.<sup>[9]</sup>

### 2.3. Image analysis

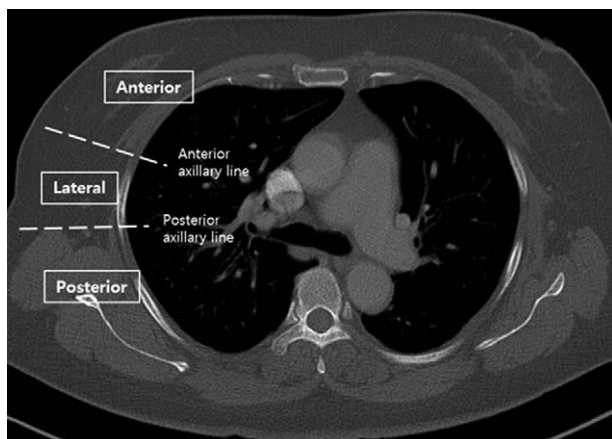
A subspecialty-trained chest radiologist retrospectively reviewed the radiography and chest CT images. Lung contusions on chest CT were defined by nonsegmental patchy consolidation or ground-glass opacities in the lung window setting on chest CT (width 1500 H.U.; level -700 H.U.). Subpleural sparing was considered to be a clue pointing toward lung contusion.<sup>[10]</sup> The pattern, distribution, and allocation of the segments of the lung contusion were investigated as well: The patterns of lung contusion were classified as consolidation only, ground-glass opacity only, or both. The distribution of lung contusions was classified among dependent, peribronchovascular, or diffuse types, and they were also determined to be either unilateral or bilateral. The allocation of the lung contusion segments was done according to a previous study by Cha et al.<sup>[11]</sup> The thorax was divided into three regions (upper, middle, and lower), and each region was subdivided into four segments (anteromedial, anterolateral, posteromedial, and posterolateral) except for the lower region of the left lung, which was subdivided into three segments (anterolateral, posteromedial, and posterolateral) because the heart shares its volume. Thus, both lungs were divided into 23 segments, among which the area of the lung contusion (ALC) was labeled, and the severity score was measured in each ALC (Fig. 1). A severity score of 1 was assigned to an ALC taking up less than one-third of a segment, a score of 2 was assigned to an ALC taking up equal to or greater than one-third of a segment and less than two-thirds of a segment, and a score of 3 was assigned to an ALC taking up greater than or equal to two-thirds of a segment. Finally, the sum of the scores for all ALCs was calculated, and this was defined as the lung contusion score (LCS). An LCS greater than 23 was defined as a severe lung contusion, indicating a lung contusion that was observed in more than one-third of both lungs.

Rib fractures were assessed by classifying their location and number. The location of each rib fracture was assigned according to the method outlined by Caragounis et al.<sup>[12]</sup> The rib cage was divided into three sections (anterior, lateral, and posterior) by two axillary lines (anterior and posterior). The anterior axillary line indicated the lateral border of the pectoralis major muscle and the posterior axillary line indicated the anterior border of the latissimus dorsi muscle at the level of the fourth rib on the axial



**Figure 1.** Allocation of the segments of the lung contusion on chest CT: A, upper; B, middle; and C, lower.

CT images (Fig. 2). The location of each sternal fracture was classified into four segments longitudinally: the manubrium sterni and the sternal body, consisting of parts 1, 2, and 3 (Fig. 3).<sup>[13]</sup> Additional chest injuries, such as pleural effusion or hemothorax, pneumothorax, and retrosternal hematoma, were also described.



**Figure 2.** Division of the location of the rib fracture into 3 parts. The rib cage is divided into three sections (anterior, lateral, and posterior) by 2 axillary lines (anterior and posterior). The anterior axillary line indicates the lateral border of the pectoralis major muscle and the posterior axillary line indicates the anterior border of the latissimus dorsi muscle at the level of the fourth rib on the CT images.

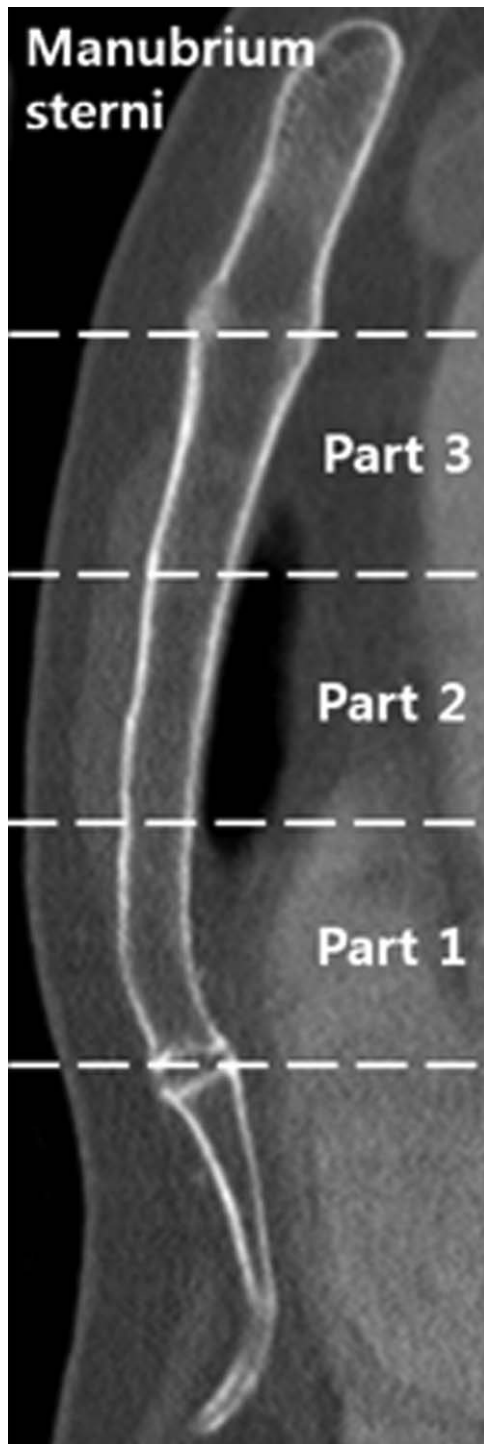
**2.4. Statistical analysis**

The results are presented as the median and interquartile range (IQR) for the continuous variables because the results are not normally distributed. The number (n) and the percentage (%) are used for the categorical variables. The correlation between LCS and the duration of CPR and age were analyzed by the nonparametric Spearman’s rank correlation test. A 2-tailed t-test was used to identify whether the duration of CPR was associated with the number of rib fractures or additional thoracic injuries. Odds ratios (ORs) were calculated to identify the relationship between sternal fractures and the duration of CPR. A P value of <.05 indicated a significant difference. All statistical analyses were performed using statistical software (SPSS for Windows, version 18.0; IBM Corp., Armonk, NY).

**3. Results**

**3.1. Demographics**

In total, 43 patients who underwent chest CTs after CPR were included in this study. The mean age of the patients was 72.3 (range: 2–98) years. Of the 43 patients, 27 (62.8%) were males and 16 (37.2%) were females. The causes of the cardiac arrest experienced by the patients included in the study were cardiac (10 patients, 23.3%), cerebral (5 patients, 11.6%), renal (3 patients, 7.0%), sepsis (5 patients, 11.6%), unknown causes (1 patient, 2.3%), and other causes (15 patients, 34.9%), including asphyxia (12 patients, 27.9%), anaphylaxis (1 patient, 2.3%), multi-organ



**Figure 3.** Topographic division of the sternum in four parts: the manubrium sterni and sternal body including parts 1, 2, and 3.

failure due to metastasis (1 patient, 2.3%), and drug intoxication in a suicide attempt (1 patient, 2.3%).

Successful resuscitation was achieved after CPR for less than 10 minutes in 14 patients (32.6%), after 10 to 25 minutes in 13 patients (30.2%), and after 25 minutes or more in 16 patients (37.2%). According to the EMR, all patients underwent manual CPR, as there were no records of the use of mechanical chest

**Table 1**

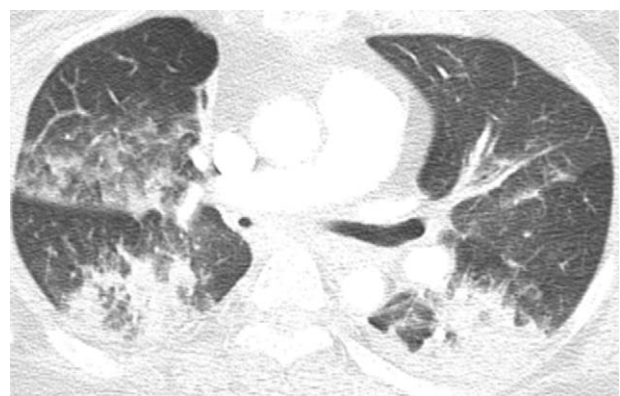
**Age distribution and clinical findings in 43 patients.**

Age distribution, n (%)	
<10 year	1 (2.3)
41~50	1 (2.3)
51~60	6 (14.0)
61~70	9 (20.9)
71~80	12 (27.9)
81~90	9 (20.9)
91~100	5 (11.6)
Cause of cardiac arrest, n (%)	
Cardiac	10 (23.3)
Noncardiac	33 (76.7)
Respiratory	19 (44.2)
Cerebral	5 (11.6)
Metabolic	4 (9.3)
Sepsis	3 (7.0)
Drug overdose	1 (2.3)
Undetermined	1 (2.3)
Final outcomes, n (%)	
Survival	20 (46.5)
Expire	22 (51.2)
undetermined	1 (2.3)

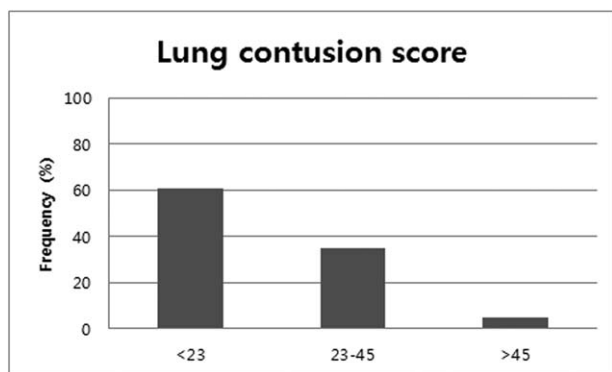
compressions. CPR was provided by bystanders to 11 patients (25.6%), by healthcare providers to 21 patients (28.8%), and by both to 11 patients (25.6%). ARDS occurred 48 hours after CPR in 8 patients (18.6%), did not occur in 24 patients (55.8%), and was unknown in 11 patients (25.6%). Ten patients expired within 24 hours after CPR and one patient was transferred to another institution. Ultimately, 20 patients (46.5%) survived to discharge and 22 (51.2%) expired during hospitalization. The detailed demographic variables are listed in Table 1.

**3.2. Overall CT features**

All patients included in the study developed lung contusions with bilateral opacity on the chest CT scans. The pattern of lung contusion was categorized into consolidation only (one patient, 2.3%), ground-glass opacity (GGO) only (2 patients, 4.7%), and both types (40 patients, 93%) (Fig. 4). The distribution of lung contusions was most commonly of the dependent type (41



**Figure 4.** CT finding of a 52-year-old woman who was successfully resuscitated after 30 minutes of CPR. On the chest CT images with lung setting, the consolidation and the ground-glass opacity are seen predominantly in the dependent portions of the lungs.



**Figure 5.** Distribution of the lung contusion scores in the patients with lung contusion.

patients, 95.3%), followed by the peribronchovascular type (two patients, 4.7%). The mean LCS was 22 and it ranged from 5 to 47. The proportions of the LCSs are shown in detail in Figure 5. There was no statistically significant correlation between the duration of CPR and LCS or between the age of patients and LCS by Spearman’s rank correlation coefficient ( $\rho = .039$  and  $-0.130$ ,  $P = .803$ , and  $.407$ , respectively).

Rib fractures were present in all patients included in this study. In total, 360 rib fractures were recorded. The number of rib fractures ranged from 2 to 13 per patient, with a mean of 8.4 fractures per patient. All patients showed anterior arc fractures, and one had both anterior and lateral arc fractures. No patients had posterior arc fractures. The number of rib fractures was less than three in 2 patients (4.7%) and equal to or greater than three in 41 patients (95.3%).

In the group of patients under 70 years old, the number of rib fractures was significantly increased among patients with CPR durations longer than 25 minutes compared to those who received CPR for less than 25 minutes (median 4.5 vs 9; mean 8.3 vs 5.6 per person, respectively;  $P = .035$ ) (Table 2).

Sternal fractures were diagnosed in 31 patients (72.1%), all of which occurred in the sternal body and none of which occurred in the manubrium sterni. In detail, fractures occurred in part 1 of the sternal body in 2 patients (4.7%), in parts 1 and 2 in 2 patients (4.7%), in part 2 in 25 patients (58.1%), and in part 3 in 3 patients (7.0%). The risk of sternal fracture tended to increase in the group of patients who underwent CPR for 10 minutes or more compared to those who received CPR for less than 10 minutes with an OR of 3.60 (95% CI: 0.86, 15.06;  $P = .079$ ). Other reported CPR-related thoracic injuries, such as pleural effusion/hemothorax (28 patients, 65.1%), pneumothorax (4 patients, 9.3%), and retrosternal hematoma (19 patients,

**Table 2**  
**Association between the number of rib fracture and the duration of cardio pulmonary resuscitation according to the age.**

	Duration of cardio pulmonary resuscitation	
	≤25 min (n=29)	> 25 min (n=14)
Number of rib fracture, median (interquartile range)		
All	10 (5–10)	9 (7–10)
Age <70 yr	4.5 (3–7.75)	9 (7.5–9)
Age ≥70 yr	10 (7.5–11.5)	10 (6.5–12)

**Table 3**  
**Association between the duration of cardio pulmonary resuscitation and other chest injuries.**

Duration of cardio pulmonary resuscitation (min)	Pleural effusion/hemothorax	Yes	Median (interquartile range)
			21 (6.5–29)
	Pneumothorax	No	20 (6–30)
		Yes	26 (18.5–29.25)
	Retrosternal hematoma	No	20 (6–29.5)
		Yes	23.5 (9.25–29)
		No	20 (3–20)

44.2%), were not associated with the duration of CPR ( $P = .890$ ,  $.711$ , and  $.222$ , respectively) (Table 3). There were no abdominal injuries in the scanned areas. Table 4 lists all detected injuries.

**4. Discussion**

The latest CPR guidelines recommend high-quality chest compressions of at least 5 cm in depth and at a rate of 100 to 120 beats per minute.<sup>[3,14]</sup> Deeper and faster chest compressions enhance the survival rate, but also inevitably increase the risk of CPR-related chest injuries.<sup>[15,16]</sup>

**Table 4**  
**Imaging findings of the cardio pulmonary resuscitation-related chest injuries.**

Pattern, n (%)	
Consolidation only	1 (2.3)
Ground-glass opacity only	2 (4.7)
Both	40 (93.0)
Distribution, n (%)	
Unilateral/bilateral	0 (0)/43 (100)
Dependent area	41 (95.3)
Peribronchovascular	2 (4.7)
Diffuse	0 (0)
Lung contusion score, mean (range)	22 (5~47)
Additional thoracic injury, n (%)	
Rib fracture	43 (100)
Rib fracture (location)	
Anterior arc	42 (97.7)
Anterior & lateral arc	1 (2.3)
Lateral arc	0 (0)
Posterior arc	0 (0)
Rib fracture (number)	
≥ 3	41 (95.3)
<3	2 (4.7)
Sternal fracture	31 (72.1)
Sternal fracture (location)	
Manubrium sterni	0 (0)
Sternal body	32 (74.4)
Part 1	2 (4.7)
Part 1&2	2 (4.7)
Part 2	25 (58.1)
Part 3	3 (7.0)
Pleural effusion/hemothorax	28 (65.1)
Pneumothorax	4 (9.3)
Retrosternal hematoma	19 (44.2)
None	0 (0)

In the past, autopsy or simple radiography was used to investigate CPR-related chest injury,<sup>[17,18]</sup> but recently, multi-detector CT has seen increasing usage in patients with cardiopulmonary arrest due to its rapid examination and multifaceted reconstitution capacity, along with the thinner image slices it obtains. It is particularly useful for patients in emergency conditions due to the fact that it takes less effort and a shorter amount of time.

Rib and sternal fractures are known to be the most common CPR-related chest injuries. Previous studies based on post-resuscitation CT<sup>[6,15,19,20]</sup> have reported the incidence of rib fractures to range from 26.8% to 70% and that of sternal fractures from 4.2% to 30%. According to a previous prospective cross-sectional study,<sup>[19]</sup> the incidence of rib fracture shows wide variability from hospital to hospital (0%–83.3%); the reason for this variability is not well-known and is likely multifactorial.

The number of rib fractures after CPR obtained in the present study was similar to those reported in previous studies, which have ranged from 0 to 14 per patient (mean 8.5 fractures per patient)<sup>[2]</sup> and from 2 to 14 per patient (mean 7 fractures per patients).<sup>[21]</sup> Choi et al<sup>[21]</sup> reported that the location of rib fracture was mainly (90%) in the anterior part of the ribs and that the location of sternal fracture was predominantly (63.2%) in the middle-third of the sternal body, and these results were consistent with those of the present study. This result, of course, is believed to be due to the standard position of hands for chest compression specified in the current CPR guideline: the lower half of the sternum.

A few studies have identified the relationship between the duration of CPR and CPR-related thoracic skeletal injuries. Krischer et al<sup>[17]</sup> conducted an autopsy study and found that prolonged CPR leads to a higher frequency of rib fractures. Cho et al,<sup>[22]</sup> Milling et al,<sup>[23]</sup> Ondruschka et al,<sup>[24]</sup> and Kashiwagi et al<sup>[6]</sup> also reported that patients with thoracic skeletal injuries underwent CPR for significantly longer durations. However, other studies reported no significant associations between the duration of CPR and chest injuries.<sup>[19,25]</sup> In theory, as the stiffness of ischemic tissue weakens, prolonged CPR may increase the incidence of rib fracture.<sup>[19]</sup> To the best of our knowledge, no study has investigated the relationship between the duration of CPR and CPR-related pleural effusion/hemothorax, pneumothorax, or retrosternal hematoma, all of which showed no significant correlation in the present study.

Smekal et al<sup>[26]</sup> reported that the incidence of rib or sternal fractures was significantly higher in patients with signs of osteoporosis than those without any such signs. However, in the present study, there was a lack of data on the patient's signs of osteoporosis, because the patients were admitted to the emergency room for cardiac arrest. Statistical analysis showed no association between the incidence of skeletal injuries and gender in this study, which is consistent with several previous studies,<sup>[26–28]</sup> but conflicts with the results of other studies.<sup>[15,19]</sup> Unlike thoracic skeletal injuries, little is known about lung parenchymal injuries after CPR.<sup>[4,11,29]</sup> Lung parenchymal injuries affect oxygen supply and ventilation during postcardiac arrest care. The present study quantified the severity of lung contusion using a previously announced method<sup>[11]</sup> and analyzed whether the duration of CPR is a contributable factor of lung contusion.

In the prior literature, the incidence of CPR-related lung contusion ranged from 41% to 100% and bilateral lung contusions were reported in 54.3% to 95% of cases.<sup>[4,11,29]</sup> In

a previous study by Cha et al,<sup>[11]</sup> the LCS after CPR ranged from 1 to 58 with a median of 17, which was less than that in our study. The LCS did not correlate with CPR duration ( $r=0.285$ ;  $P=.097$ ), which was also the case in our study. In another study by Cho et al,<sup>[29]</sup> patients with lung injuries had a tendency to have a longer duration of CPR than those who did not have lung injuries, although this trend was not statistically significant ( $P=.173$ ).

Three mechanisms have been suggested as the mechanism for lung contusion after chest compression. First, disruption of the alveolocapillary membrane after repetitive chest compression results in pulmonary hemorrhage and edema. The leakage of blood and proteins accumulate into the alveolar spaces and interstitium, often as a result of a direct inward force of the injured chest wall to the adjacent or contrecoup lung.<sup>[30]</sup> Second, it can present as pulmonary reperfusion injury after cardiac arrest, which aggravates alveolocapillary membrane function due to oxidative stress of lipid or protein oxidation. Local inflammatory reactions are believed to contribute to reperfusion injury, such as the release of cytokines, the upregulation of cell adhesion molecule expression, and the subsequent induction of leukocyte accumulation.<sup>[31]</sup> Third, concurrent aspiration of gastric juice or oropharyngeal secretion can exacerbate lung injuries by increasing the permeability of lung tissue and its associated inflammation. Patients who have received CPR often experience aspiration due to difficulty in swallowing associated with mental changes.<sup>[32]</sup>

It may be assumed that there is no significant correlation between LCS and the duration of CPR due to the characteristics of lung compliance, that is, the ability of the lung to stretch and expand. Unlike the stiffness of bony structure, the lungs experience distensibility after being damaged by the repetitive and uniform pressure of chest compressions. In particular, since this study included patients with no underlying lung disease and with normal compliance, it could be considered as a reflection of this characteristic.

Previous studies have reported the common pattern and the distribution of lung contusion after CPR was ground-glass opacity and consolidation in the dependent area of both lungs,<sup>[4,11,29]</sup> as was the case in our study. The predominance in the dependent area could be explained by the fact that an increase in the intrathoracic pressure produced by chest compression exerts high hydrostatic pressure on the dependent area of the lung; this pressure is further increased due to the patient's supine position during CPR.<sup>[11]</sup>

Although CPR-related abdominal visceral injuries, such as laceration of the liver and the spleen, and perforation of the gastrointestinal tract, have been reported,<sup>[2,33–36]</sup> no abdominal complications were observed in the present study.

#### 4.1. Limitations

We acknowledge several limitations of the present study. First, due to the retrospective study design, unexpected confounders might have been included. Second, since this study was conducted in a single institution, the number of patients included was small, thus limiting the statistical analysis. Third, this study did not evaluate or adjust potential contributing factors, such as age, presence of osteoporosis, or CPR providers (bystanders vs. health care providers), which may have induced selection bias. Fourth, this study did not evaluate the prognosis of the patients or the clinical significance of a longer duration of CPR or higher LCS,

such as mortality or hospitalization. Further randomized prospective studies are required to evaluate the prognosis of each factor in resuscitated patients.

## 5. Conclusions

Chest injuries are common complications in patients who have undergone CPR. Rib and sternal fractures typically occur in specific locations: the anterior arc of the ribs and two-thirds of the sternal body. Lung contusions commonly occur in the bilateral dependent portion. Despite the limitation that the number of patients was relatively small, there were a few statistically significant correlations. The number of rib fractures was higher with prolonged CPR at the age under 70. Sternal fractures tend to occur more often with prolonged CPR. However, there was no association between the duration of CPR and lung contusion or other CPR-related chest injuries, such as pleural effusion/hemothorax, pneumothorax, and retrosternal hematoma.

## Author contributions

**Conceptualization:** Seo Jin Jang, Yoon Ki Cha, Jeung Sook Kim, Han Ho Do, So Hyeon Bak, Won Gun Kwack.

**Data curation:** Seo Jin Jang, Yoon Ki Cha, So Hyeon Bak, Han Ho Do.

**Formal analysis:** Seo Jin Jang, Yoon Ki Cha, So Hyeon Bak.

**Supervision:** Yoon Ki Cha.

**Writing – original draft:** Seo Jin Jang.

## References

- [1] Taw RL. Dr. Friedrich Maass: 100th anniversary of “new” CPR. *Clin Cardiol* 1991;14:1000–2.
- [2] Dunham GM, Perez-Girbes A, Bolster F, et al. Use of whole body CT to detect patterns of CPR-related injuries after sudden cardiac arrest. *Eur Radiol* 2018;28:4122–7.
- [3] Kleinman ME, Brennan EE, Goldberger ZD, et al. Part 5: adult basic life support and cardiopulmonary resuscitation quality: 2015 American heart association guidelines update for cardiopulmonary resuscitation and emergency cardiovascular care. *Circulation* 2015;132(18 Suppl 2):S414–35.
- [4] Ryu HM, Yoo JY, Kim SJ. Computed tomographic features of lung parenchyma over time after cardiopulmonary resuscitation. *J Kor Soc Radiol* 2019;80:740–9.
- [5] Boland LL, Satterlee PA, Hokanson JS, et al. Chest compression injuries detected via routine post-arrest care in patients who survive to admission after out-of-hospital cardiac arrest. *Prehosp Emerg Care* 2015;19:23–30.
- [6] Kashiwagi Y, Sasakawa T, Tampo A, et al. Computed tomography findings of complications resulting from cardiopulmonary resuscitation. *Resuscitation* 2015;88:86–91.
- [7] Olds K, Byard RW, Langlois NE. Injuries associated with resuscitation - An overview. *J Forensic Leg Med* 2015;33:39–43.
- [8] Kurkciyan I, Meron G, Behringer W, et al. Accuracy and impact of presumed cause in patients with cardiac arrest. *Circulation* 1998;98:766–71.
- [9] Fanelli V, Vlachou A, Ghannadian S, et al. Acute respiratory distress syndrome: new definition, current and future therapeutic options. *J Thorac Dis* 5 2013;326–34.
- [10] Kaewlai R, Avery LL, Asrani AV, et al. Multidetector CT of blunt thoracic trauma. *RadioGraphics* 2008;28:1555–70.
- [11] Cha KC, Kim YW, Kim HI, et al. Parenchymal lung injuries related to standard cardiopulmonary resuscitation. *Am J Emerg Med* 2017;35:117–21.
- [12] Caragounis EC, Xiao Y, Granhed H. Mechanism of injury, injury patterns and associated injuries in patients operated for chest wall trauma. *Eur J Trauma Emerg Surg* 2019;1–0.
- [13] Scheyerer MJ, Zimmermann SM, Bouaicha S, et al. Location of sternal fractures as a possible marker for associated injuries. *Emerg Med Int* 2013;2013:407589.
- [14] Perkins GD, Handley AJ, Koster RW, et al. European Resuscitation Council Guidelines for Resuscitation 2015: Section 2. Adult basic life support and automated external defibrillation. *Resuscitation* 2015;95:81–99.
- [15] Hellevuo H, Sainio M, Nevalainen R, et al. Deeper chest compression - more complications for cardiac arrest patients? *Resuscitation* 2013;84:760–5.
- [16] Beom JH, You JS, Kim MJ, et al. Investigation of complications secondary to chest compressions before and after the 2010 cardiopulmonary resuscitation guideline changes by using multi-detector computed tomography: a retrospective study. *Scand J Trauma Resusc Emerg Med* 2017;25:8.
- [17] Krischer JP, Fine EG, Davis JH, et al. Complications of cardiac resuscitation. *Chest* 1987;92:287–91.
- [18] Himmelhoch SR, Dekker A, Gazzaniga LAB, et al. Closed-chest cardiac resuscitation. *N Engl J Med* 1964;270:118–22.
- [19] Kim MJ, Park YS, Kim SW, et al. Chest injury following cardiopulmonary resuscitation: a prospective computed tomography evaluation. *Resuscitation* 2013;84:361–4.
- [20] Kim EY, Yang HJ, Sung YM, et al. Multidetector CT findings of skeletal chest injuries secondary to cardiopulmonary resuscitation. *Resuscitation* 2011;82:1285–8.
- [21] Choi SJ, Kim HS, Kim EY, et al. Thoraco-abdominal CT examinations for evaluating cause of cardiac arrest and complications of chest compression in resuscitated patients. *Emerg Radiol* 2014;21:485–90.
- [22] Cho JC, Seo YW, Kim G, et al. Factors associated with skeletal chest injuries secondary to cardiopulmonary resuscitation of in-hospital cardiac arrest patients. *J Kor Soc Emerg Med* 2015;26:409–16.
- [23] Milling L, Astrup BS, Mikkelsen S, et al. Prehospital cardiopulmonary resuscitation with manual or mechanical chest compression: a study of compression-induced injuries. *Acta Anaesthesiol Scand* 2019;63:789–95.
- [24] Ondruschka B, Baier C, Bayer R, et al. Chest compression-associated injuries in cardiac arrest patients treated with manual chest compressions versus automated chest compression devices (LUCAS II) - a forensic autopsy-based comparison. *Forensic Sci Med Pathol* 2018;14:515–25.
- [25] Foo NP, Chang JH, Lin HJ, et al. Rescuer fatigue and cardiopulmonary resuscitation positions: a randomized controlled crossover trial. *Resuscitation* 2010;81:579–84.
- [26] Smekal D, Lindgren E, Sandler H, et al. CPR-related injuries after manual or mechanical chest compressions with the LUCAS™ device: a multicentre study of victims after unsuccessful resuscitation. *Resuscitation* 2014;85:1708–12.
- [27] Deliliga A, Chatzinikolaou F, Koutsoukis D, et al. Cardiopulmonary resuscitation (CPR) complications encountered in forensic autopsy cases. *BMC Emerg Med* 2019;19:23.
- [28] Black CJ, Busuttill A, Robertson C. Chest wall injuries following cardiopulmonary resuscitation. *Resuscitation* 2004;63:339–43.
- [29] Cho SH, Kim EY, Choi SJ, et al. Multidetector CT and radiographic findings of lung injuries secondary to cardiopulmonary resuscitation. *Injury* 2013;44:1204–7.
- [30] Wicky S, Wintermark M, Schnyder P, et al. Imaging of blunt chest trauma. *Eur Radiol* 2000;10:1524–38.
- [31] Basu S, Nozari A, Liu XL, et al. Development of a novel biomarker of free radical damage in reperfusion injury after cardiac arrest. *FEBS Lett* 2000;470:1–6.
- [32] Lomoschitz FM, Eisenhuber E, Linnau KF, et al. Imaging of chest trauma: radiological patterns of injury and diagnostic algorithms. *Eur J Radiol* 2003;48:61–70.
- [33] Camden JR, Carucci LR. Liver injury diagnosed on computed tomography after use of an automated cardiopulmonary resuscitation device. *Emerg Radiol* 2011;18:429–31.
- [34] Engelken FJ, Bosse G, Diederichs G. A complication of cardiopulmonary resuscitation. *Emerg Med J* 2011;28:173.
- [35] Fitchet A, Neal R, Bannister P. Splenic trauma complicating cardiopulmonary resuscitation. *BMJ* 2001;322:480–1.
- [36] Offerman SR, Holmes JF, Wisner DH. Gastric rupture and massive pneumoperitoneum after bystander cardiopulmonary resuscitation. *J Emerg Med* 2001;21:137–9.