



Association of CNS demyelination and COVID-19 infection: an updated systematic review

Ismail Ibrahim Ismail¹ · Sara Salama²

Received: 11 July 2021 / Revised: 5 August 2021 / Accepted: 5 August 2021 / Published online: 12 August 2021
© Springer-Verlag GmbH Germany, part of Springer Nature 2021

Abstract

Background Since the declaration of COVID-19 pandemic, several case reports of demyelination of both peripheral and central nervous systems have been published. The association between CNS demyelination and viral infection has long been documented, and this link was recently reported following SARS-CoV-2 infection as well.

Objectives In this systematic review, we aim to investigate the existing literature on CNS demyelination associated with SARS-CoV-2, and the proposed pathophysiological mechanisms.

Methods We conducted a systematic review of articles in PubMed, SCOPUS, EMBASE, Cochrane, Google Scholar and Ovid databases, from 1 January 2020 until June 15, 2021. The following keywords were used: “COVID-19”, “SARS-CoV-2”, “demyelination”, “demyelinating disease”, “multiple sclerosis”, “neuromyelitis optica”, and “transverse myelitis”.

Results A total of 60 articles were included in the final analysis of this systematic review and included 102 patients: 52 (51%) men and 50 (49%) women, with a median age of 46.5 years. The demyelination mimicked a variety of conditions with a picture of encephalitis/encephalomyelitis being the most common. At the same time other patterns were less frequently reported such as MS, NMOSD and even MOGAD. Longitudinally extensive transverse myelitis (LETM) was the most frequently reported pattern of spinal cord involvement.

Conclusion A growing body of literature has shown an association between SARS-CoV-2 infection and the development of different types of CNS demyelination. Although causality cannot readily be inferred, this review may suggest a probable causal relationship, through a para-infectious or post-infectious immune-mediated etiology in COVID-19 patients. This relationship needs to be clarified in future research.

Keywords COVID-19 · SARS-CoV-2 · Demyelinating disease · Multiple sclerosis

Introduction

Severe acute respiratory syndrome coronavirus 2 (SARS-CoV-2) emerged in Wuhan, China, in December 2019, and coronavirus disease 2019 (COVID-19) was declared a pandemic on March 11, 2020. Since then, several neurological manifestations have been reported, including both

peripheral and central nervous systems (CNS) demyelinating diseases [1, 2]. Several articles reported the occurrence of acute demyelinating encephalomyelitis (ADEM), transverse myelitis (TM), multiple sclerosis (MS), and even neuromyelitis optica spectrum disorder (NMOSD), in association with COVID-19 infection [3–5].

There is an ongoing debate whether this association is merely related to the neurotropic features of SARS-CoV-2, or secondary to an acute or delayed immune-mediated response [6]. Coronavirus family showed clear evidence of neurotropic properties, as CNS demyelination has been reported with Middle East respiratory syndrome coronavirus (MERS-COV) and SARS-COV-1 [7–9].

When it comes to SARS-CoV-2, data are still limited in terms of cases of para-infectious and post-infectious CNS demyelinating/inflammatory diseases. Recent evidence has shown that SARS-CoV-2 can cross the blood–brain barrier

Ismail Ibrahim Ismail and Sara Salama contributed equally to this work.

✉ Ismail Ibrahim Ismail
dr.ismail.ibrahim2012@gmail.com

¹ Department of Neurology, Ibn Sina Hospital, Gamal Abdel Nasser Street, Sabah Medical Area, Safat, Kuwait

² Department of Neurology and Psychiatry, University of Alexandria, Alexandria, Egypt

and induce acute or delayed CNS demyelination [10]. Various mechanisms have been suggested including virus-induced hypercoagulable or proinflammatory states, direct viral invasion of the CNS, and post-infectious immune-mediated processes [11].

In this systematic review, we aim to investigate the available evidence regarding the different types of CNS demyelination in association with SARS-CoV-2 infection, and the proposed pathophysiological mechanisms in these cases.

Methods

Design

This systematic review collected data from PubMed, SCOPUS, EMBASE, Cochrane library, Google Scholar and Ovid databases, in accordance with Preferred Reporting Items for Systematic Reviews and Meta-analysis (PRISMA) guidelines. We aimed to identify relevant articles that discussed CNS demyelination in association with SARS-CoV-2 infection from 1 January 2020 until June 15, 2021.

Search strategy

A pre-specified searching strategy consisted of a variation of keywords of relevant medical subject headings (MeSH) and keywords, including: “COVID-19”, “SARS-CoV-2”, “demyelination”, “demyelinating disease”, “multiple sclerosis”, “neuromyelitis optica”, and “transverse myelitis”. Furthermore, we hand-searched additional relevant COVID-19 articles that were referenced in the selected studies.

Inclusion criteria

We included all peer-reviewed publications that reported any form of CNS demyelination in association with COVID-19 infection, including but not limited to case reports and case series that met the following criteria: (i) studies reporting early or delayed acute CNS demyelination after COVID-19 infection; (ii) studies reporting possible association of cases fulfilling the diagnostic criteria of multiple sclerosis (MS), transverse myelitis (TM), neuromyelitis optica spectrum disorder (NMOSD), or myelin oligodendrocyte glycoprotein antibody disease (MOGAD), and COVID-19 infection; and (iii) studies published in English.

Exclusion criteria

The review was restricted to studies published in English. Publications that were not peer-reviewed were excluded from this study. We also excluded review papers, viewpoints, commentaries, unless reporting a case of demyelination, and

studies where demyelination affected peripheral rather than central nervous systems. We also excluded cases not supported by positive imaging findings, laboratory or clinical evidence of COVID-19 infection.

Data extraction

Titles and abstracts of all identified studies were independently screened for relevance by the two reviewers, followed by full-text screening of the deemed eligible papers. The same reviewers then extracted data on the following parameters: article title, authors, publication year, age and gender of the patients, COVID-19-related information, onset of neurological symptoms, findings of neurological examination, MRI findings, laboratory work-up, CSF analysis, treatment and clinical outcome. Severity of COVID-19 infection was categorized into mild; asymptomatic infections or infections with mild symptoms not requiring hospitalization, moderate; requiring hospitalization but not ICU admission, and severe; requiring ICU admission and mechanical ventilation.

Statistical analysis

Qualitative data were described in percentages and numbers. Quantitative data were described using range (minimum and maximum), mean, standard deviation, and median. Significance of the obtained results was judged at the 5% level, but it could not be calculated due to insufficient data. A meta-analysis was planned to evaluate the association of the demographic findings, clinical, radiological and laboratory findings and outcomes, but it could not be performed due to lack of sufficient data.

Results

As illustrated in Fig. 1, our systematic search resulted in an initial number of 1,399 of potentially relevant articles, of which 966 were screened by title and abstract, following duplicates removal. Applying the inclusion/exclusion criteria to the full-text documents, 83 articles were deemed eligible, of which, 60 studies with a total of 102 patients, were included in the systematic review.

Brain demyelination

We identified 78 cases of brain demyelination from 38 articles. There were 40 males and 38 females. The median age of patients was 45.5 (0.17–77) years. The most common presenting neurological symptoms were lethargy, altered sensorium with or without seizures. In some cases, the symptoms followed COVID-19 infection by few weeks, while in others, they started at initial presentation and overlapped with

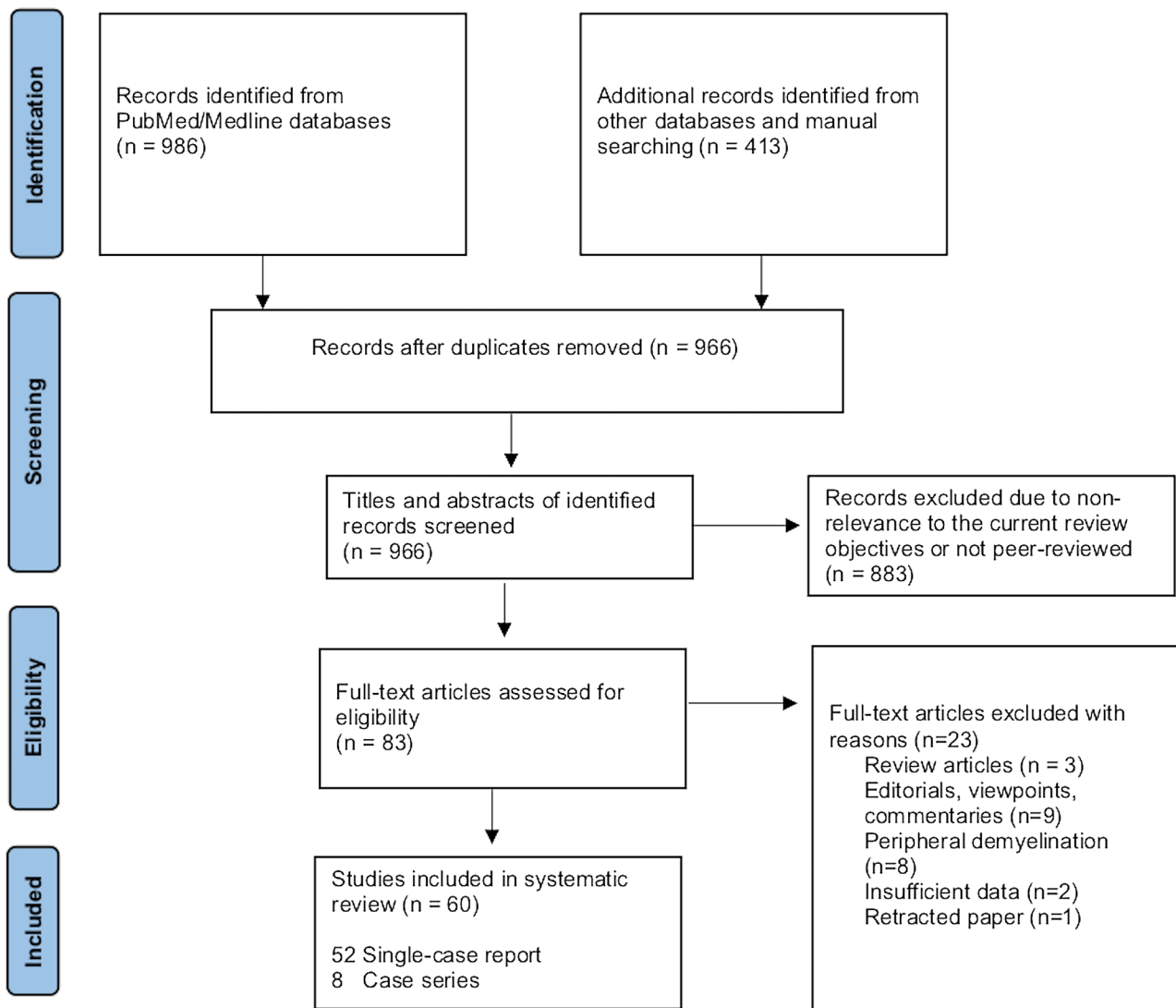


Fig. 1 Preferred reporting items for systematic reviews and meta-analyses (PRISMA) study selection flow diagram

COVID-19 symptoms. The demyelination mimicked a variety of conditions with the picture of encephalitis/encephalomyelitis being the most common (91%). At the same time, other patterns were less frequently reported such as MS, NMOSD and even MOGAD (10%).

It still remains an unanswered question whether demyelination represents a manifestation of direct viral invasion to the CNS, or it is an immune-mediated process triggering other well-known conditions, or in some cases a mere sequel for hypoxia affecting the CNS as a direct result of respiratory affection.

We summarized the results based on the most likely clinical diagnosis, in view of symptoms, laboratory and imaging findings in Tables 1 and 2.

Encephalitis/encephalomyelitis-like

A total of 71/78 patients (90%) presented by an encephalopathic clinical picture, lethargy, loss of consciousness and/or seizures which was supported by imaging findings. The median age of patients was 47 years. Hemorrhage and/or necrosis were reported in 26/71 (36.6%) of those patients. Of whom, 21/26 suffered severe COVID-19 infection which required mechanical ventilation. This observation raises the concern of a hypoxic ischemic theory and the need for anticoagulation in severely ill cases. A summary of the clinical characteristics is presented in Table 1.

Table 1 Characteristics of cases presenting with COVID-19 related encephalitis/encephalomyelitis

Author	Age (years)	Gender	Comorbidities	Time relation between SARS-COV-2 infection and NP	Presenting COVID-19 symptoms	Presenting neurological symptoms	Neurological diagnosis	Other NS manifestations	Treatment	Response to treatment	PCR testing for SARS-COV 2	Severity of COVID-19 infection	Other laboratory investigations	MRI data
1. Zoghi et al. [14]	21	Male	None	2–3 weeks	Fever, chills, cough	Weakness and paresthesia of the lower limbs and upper limbs, urinary retention, vomiting, drowsiness and lethargy	ADEM vs NMOSD	None	PLEX for 5 days with antibiotics and antivirals	Partial improvement	Negative in nasopharynx and in CSF (Positive chest and IgG)	Mild	Negative OCBs	Brain: bilateral corticospinal tracts, cerebral peduncle and pons, marbled hyperintensity in the splenium of corpus callosum Cervical spine: LETM
2. Zamin et al. [32]	54	Female	NA	At initial presentation	Anosmia and ageusia	Loss of consciousness and seizures	HIE vs viral encephalitis, myelitis	None	High-dose steroid treatment (dexamethasone 20 mg/day for 10 days and 10 mg/day for 10 days)	Marked improvement of pulmonary condition Neurological improvement: not mentioned	Positive in nasopharynx, negative in CSF	Severe	NA	Brain: hyperintensities PV, bulbo-medullary junction Cervicodorsal spine: patchy hyperintensities
3. Brun et al. [33]	54	Female	HTN	8 days	Fever, fatigue, respiratory distress	Hemiplegia and altered sensorium	HIE vs ADEM	None	Steroids	Partial improvement	Positive in nasopharynx, negative in CSF	Severe	NA	Brain: bilateral tumefactive demyelination, bilateral globus pallidi, DWM and corpus callosum, avid post-contrast enhancement
4. Alqwaify et al. [34]	14	Female	None	2 weeks	Fever	Unsteadiness, left-sided facial weakness	ADEM	None	IVMP 1 g for 5 days	Partial improvement	Positive in nasopharynx, negative in CSF	Mild	Negative OCBs	Brain: well-defined middle cerebellar peduncle lesion, faint post-contrast enhancement

Table 1 (continued)

Author	Age (years)	Gender	Comorbidi- ties	Time rela- tion between SARS- COV-2 infection and NP	Presenting COVID-19 symptoms	Presenting neurological symptoms	Neuro- logical diagnosis	Other NS manifesta- tions	Treatment	Response to treatment	PCR test- ing for SARS- COV 2	Severity of COVID-19 infection	Other laboratory investiga- tions	MRI data
5. Paterson et al. [3]	52	Male	Asthma	22 days	Fever, cough, dyspnea	Delayed recovery of consciousness after weaning from ventila- tion	ADEM	None	Supportive	Partial improvement	Positive in naso- phar- ynx, nega- tive in CSF	Severe	Negative OCBs	Brain: multiple lesions in DWM. Cyst-like areas of varied sizes, some with hemorrhagic foci and peripheral rims of restricted diffusion
6. Paterson et al. [3]	60	Male	DM, HTN	27 days	Fever, myalgia, fatigue, dyspnea	Altered con- sciousness	ADEM	None	IVMP 1 g for 3 days	Partial improvement	Negative PCR in CSF	Severe	Negative OCBs	Brain: multifocal and confluent areas of signal change in the cerebral DWM with extensive microhe- morrhages in the subcortical regions
7. Paterson et al. [3]	66	Female	HTN, hypothy- roidism, hyster- ectomy, osteoar- thritis, degenera- tive spine disease	1 day	Fever	Confusion and seizures	Autoim- mune/ limbic encepha- litis	None	IVMP 1 g for 3 days, then oral predni- sone taper, IVIG	Partial improvement	Nega- tive in naso- phar- ynx	Mild	Negative OCBs	Brain: T2-hyperintense signals in upper pons, limbic lobes, medial thalami and subcorti- cal cerebral white matter
8. Paterson et al. [3]	59	Female	Aplastic anemia, MGUS, breast cancer, fatty liver, hyper- cholester- olemia	10 days	Cough, chills, lethargy, myalgia	GTCs and low conscious level	ADEM	None	Intubation, ventila- tion; leveti- racetam, acyclovir and cef- triaxone, dexametha- sone	No response, died	Nega- tive in CSF	Mild	NA	Brain: extensive confluent, largely symmetrical areas in brainstem, limbic, and insular lobes, superficial subcortical white matter and deep grey matter, clusters of microhemorrhages, restricted diffusion and peripheral rim enhancement

Table 1 (continued)

Author	Age (years)	Gender	Comorbidi- ties	Time rela- tion between SARS- COV-2 infection and NP	Presenting COVID-19 symptoms	Presenting neurological symptoms	Neuro- logical diagnosis	Other NS manifesta- tions	Treatment	Response to treatment	PCR test- ing for SARS- COV 2	Severity of COVID-19 infection	Other laboratory investiga- tions	MRI data
9. Paterson et al. [3]	52	Male	None	At presenta- tion	Fever, res- piratory distress	History of GBS 3 days before CNS symptoms. Increased weakness, dysphagia, ophthal- moplegia and altered sensorium	ADEM	AIDP	Intubation and venti- lation, IVMP 1 g for 5 days, IVIG	Partial improvement	Positive in naso- phar- ynx, nega- tive in CSF	Severe	NA	Brain: multifocal confluent lesions in internal and external capsules, splenium and DWI of cerebral hemispheres. Over 5 days, lesions increased in size and showed multiple microhemorrhages and extensive promi- nent medullary veins. Spine: components of brachial and lumbosa- cral plexus showed increased signal and enhancement
10. Paterson et al. [3]	47	Female	Asthma	8 days	Cough, fever, shortness of breath	Headache, left- hand numb- ness, left sided facial weakness, left upper limb weakness and mild left leg weakness, reduced con- scious level	ADEM	None	Intubation, hemi- cranec- tomy, IVMP 1 g for 5 days, oral pred- nisolone, IVIG	Partial improvement	Negative PCR in brain tissue	Severe	NA	Brain: severe right hemispheric vaso- genic oedema with a leading edge on contrast imaging. Smaller areas of T2-hyperintense changes in the left hemisphere. Marked mass-effect
11. Paterson et al. [3]	54	Female	HTN, PCOS	14 days	Cough, fever, dysgeu- sia, rash	Unsteadiness, left sided weakness, slurred speech, fatigue and falls	ADEM	None	IVMP 1 g for 3 days, then oral predniso- lone	Partial improvement	NA	Mild	Negative OCBs	Brain: multiple large lesions with periph- eral rim restriction in periventricular white matter of both cer- ebral hemispheres

Table 1 (continued)

Author	Age (years)	Gender	Comorbidi- ties	Time rela- tion between SARS- COV-2 infection and NP	Presenting COVID-19 symptoms	Presenting neurological symptoms	Neuro- logical diagnosis	Other NS manifesta- tions	Treatment	Response to treatment	PCR test- ing for SARS- COV 2	Severity of COVID-19 infection	Other laboratory investiga- tions	MRI data
12. Paterson et al. [3]	60	Female	DM, HTN	18 days	Fever, cough, dyspnea, diarrhea	Delayed recov- ery in ICU	ADEM	None	IVMP 1 g for 3 days, then oral predni- solone taper. Intuba- tion and ventila- tion; renal replace- ment	Partial improvement	Nega- tive in CSF	Severe	Negative OCBs	Brain: multifocal lesions with diffusion changes in PV white matter and corpus callosum
13. Paterson et al. [3]	33	Female	None	2 days	Fever	Headache, confusion, reduced con- scious level	ADEM, LETM	None	Intubation, ICP bolt; lumbar drain; IVMP 1 g for 3 days then oral predniso- lone	Partial improvement	Nega- tive in CSF	Mild	Negative OCBs, MOG, AQP4 antibod- ies	Brain: multifocal lesions in lower brainstem, medial temporal lobes and DWM, some of which showed restricted diffusion. 3 days later, the brainstem lesions coa- lesced and extensive inframedullary lesions Spine: oedema involv- ing grey and white matter of the spinal cord appeared
14. Paterson et al. [3]	27	Female	None	8 days	Fever, cough, anosmia, dysgeu- sia	Sensory symptoms in feet and right hand; difficulty with balance and walking	ADEM, TM	None	None	Complete recovery	NA	Mild	NA	Brain: diffuse ill-defined confluent T2-hyperin- tensity involving the white matter of the cerebral hemispheres, largely along the corticospinal tracts. Small focal area of diffusion changes in the left motor cortex Spine: ill-defined inframedullary lesion without swelling in the conus medullaris

Table 1 (continued)

Author	Age (years)	Gender	Comorbidi- ties	Time rela- tion between SARS- COV-2 infection and NP	Presenting COVID-19 symptoms	Presenting neurological symptoms	Neuro- logical diagnosis	Other NS manifesta- tions	Treatment	Response to treatment	PCR test- ing for SARS- COV 2	Severity of COVID-19 infection	Other laboratory investiga- tions	MRI data
15. Poyadji et al. [35]	58	Female	None	At initial presenta- tion	Fever, cough	Altered senso- ritum	ADEM	None	IVIG	NA	Positive in naso- phar- ynx	NA	NA	Brain: hemorrhagic rim-enhancing lesions within the bilateral thalami, medial temporal lobes, and subinsular regions Brain: T2-hyperintense white matter lesions in bilateral frontal, parietal lobes, left thalamus, left cerebral peduncle, and medulla. Internal areas of diffusion restriction and irregu- lar patchy areas of rim enhancement were noted within most of the lesions. Left pari- etal PV white matter lesion was reaching the ventricular atrium with subjacent faint subependymal enhancement. Few microbleeds were seen
16. Varadan [36]	46	Male	Alcoholic liver disease	5 weeks	Fever, dyspnea	Headache, left hemiplegia, left facial and altered mental status	AHLE	None	IVMP 1 g for 5 days	Deteriorated and died	Positive in naso- phar- ynx	Moderate	NA	Brain: multifocal sub- cortical white matter lesions in bilateral cerebral hemispheres with associated petechial hemorrhages and vasogenic edema. Bilateral thalamic and cerebellar involvement present. Incomplete ring-like enhancement sur- rounded the thalamic lesions
17. Yong MH et al. [37]	61	Male	DM, HTN, hyperlipi- demia	20 days	Fever, cough, anosmia, res- piratory failure	Encephalopathy	AHL vs ANE	None	Remdesivir, enoxa- parin, mannitol, PLEX, IVIG	Tetra paretic and dyspha- sic at time of writing	Positive in naso- phar- ynx	Severe	NA	

Table 1 (continued)

Author	Age (years)	Gender	Comorbidi- ties	Time rela- tion between SARS- COV-2 infection and NP	Presenting COVID-19 symptoms	Presenting neurological symptoms	Neuro- logical diagnosis	Other NS manifesta- tions	Treatment	Response to treatment	PCR test- ing for SARS- COV 2	Severity of COVID-19 infection	Other laboratory investiga- tions	MRI data
18. Alan Chalil et al. [38]	48	Female	None	2 weeks	Myalgia, dry cough, dyspnea, fever	Altered con- sciousness	AHLE	None	Vasopres- sor and steroids	Partial improvement	Positive in naso- phar- ynx, nega- tive in CSF	Severe	NA	Brain: extensive bilateral parietal and occipital intraparen- chymal hemorrhage, with surrounding edema with intraven- tricular extension and acute hydrocephalus, cortical enhancement Brain: bilateral subacute hemorrhagic lesions in the basal ganglia with perilesional edema and hemor- rhage. Insular, temporal and frontal lobe white matter involvement with concentric demyelina- tion pattern
19. Karapa- nyiotides T et al. [39]	57	Male	None	3 days	Fever, cough	Altered senso- rium	AHLE	None	Azithro- mycin, hydroxy- chloro- quine and lopinavir/ ritonavir, anakinra	Partial improvement	Positive in naso- phar- ynx, nega- tive in CSF	Severe	NA	Brain and spine: bilateral frontoparietal and subcortical hyper- intensities affecting splenial, medullary and cervical cord involvement with petechial hemorrhage and splenial diffusion restriction Brain: limited MR images showing left frontoparietal and right parietal white matter lesions with hemorrhage and edema
20. Handa R et al. [40]	33	Male	CKD, HTN	At initial presenta- tion	Fever	Progressive weakness of upper and lower limbs and altered sensorium, seizures	AHLE, myelitis	None	IVMP 1 g	Partial improvement then death due to respiratory failure	Positive in naso- phar- ynx	Severe	NA	
21. Ghosh et al. [41]	44	Female	None	2 days after fever reso- lution	High-grade fever, myalgia dry cough, hypo- geusia, hypos- mia	Confusion, disorientation, GTCs, loss of sphincter control and loss of con- sciousness	AHNE	None	IVMP 1 g for 5 days	Died	Positive in naso- phar- ynx	Mild	Elevated IgG index	

Table 1 (continued)

Author	Age (years)	Gender	Comorbidities	Time relation between SARS-COV-2 infection and NP	Presenting COVID-19 symptoms	Presenting neurological symptoms	Neurological diagnosis	Other NS manifestations	Treatment	Response to treatment	PCR testing for SARS-COV 2	Severity of COVID-19 infection	Other laboratory investigations	MRI data
22. Hacıqi et al. [42]	56	Male	HTN, CKD, hypercholesterolemia, asthma	7 days	Flu-like symptoms	Altered sensorium	AHLE	None	Supportive	No improvement	Positive in nasopharynx, negative in CSF	Severe	Positive OCBs	Brain: symmetrical signal with hemosiderin staining. Cystic hemorrhagic areas with fluid levels. Areas of restricted diffusion. Slight partial resolution of findings in repeat MRI
23. Mullaguri et al. [43]	77	Female	Parkinson's disease, cognitive impairment, and HTN	At initial presentation	Fever, fatigue, disorientation, shortness of breath	Disturbed sensorium	AHNE	None	Supportive	No improvement, died	Positive in nasopharynx	Severe	NA	Brain: tiny foci of restricted diffusion involving bilateral centrum semiovale and inferior left cerebellar hemisphere. SWI revealed innumerable areas of microhemorrhages in the bilateral cerebral hemispheres involving the corona radiata, centrum semiovale, internal capsule, globus pallidus, the gray–white junction of all lobes, pons, bilateral middle cerebellar peduncles, and cerebellar hemispheres
24. Mullaguri et al. [43]	68	Female	CLL, HTN	At initial presentation	Malaise, nausea, diarrhea, progressive dyspnea, high-grade fever	Encephalopathy	AHNE	None	Supportive	No improvement, died	Positive in nasopharynx	Severe	NA	Brain: T2/FLAIR hyperintense PV lesions with diffusion restriction involving the bilateral centrum semiovale, right internal capsule, left parietal cortex, and bilateral cerebellum. SWI demonstrated multiple areas of microhemorrhages in the bilateral cerebral cortex, basal ganglia, and cerebellar hemispheres

Table 1 (continued)

Author	Age (years)	Gender	Comorbidi- ties	Time rela- tion between SARS- COV-2 infection and NP	Presenting COVID-19 symptoms	Presenting neurological symptoms	Neuro- logical diagnosis	Other NS manifesta- tions	Treatment	Response to treatment	PCR test- ing for SARS- COV 2	Severity of COVID-19 infection	Other laboratory investiga- tions	MRI data
25. Rad- manesh et al. [44]	11 patients mean age, 53 years; age range, 38–64 years	9 males, 2 females	NA	NA	NA	Altered mental status	ANE	NA	NA	No improve- ment, died	NA	Severe	NA	Brain: diffuse leukoen- cephalopathy; sym- metrical, confluent T2-hyperintensities with mild restricted diffusion, and involved bilateral deep and subcortical white matter. Infratentorial parenchyma tended to be less affected; only four patients had mild involvement of middle cerebellar peduncles and medial cerebellar hemispheres
26. Sachs et al. [45]	59	Male	Asthma	NA	Fever, upper res- piratory symp- toms	NA	Hemor- rhagic leukoen- cephalopathy	None	NA	NA	Positive in naso- phar- ynx	Severe	NA	Brain: diffuse, confluent T2/FLAIR hyperin- tensities in posterior predominant white matter with scattered microhemorrhages predominantly in the corpus callosum, and apparent posterior circulation without diffusion restriction or abnormal enhance- ment
27. McLendon et al. [46]	1.4	Female	None	13 days	Fever	Progressive fatigue, decreased communi- cation, difficulty feeding and walking, without sup- port. Parental complaint of irritability, weakness of upper extrem- ities, and gait disturbance, seizures	ADEM	None	IVIG 2 g/ kg for four days, IVMP (30 mg/ kg/day) for 5 days	Complete recovery after 2 months	Positive in naso- phar- ynx and posi- tive IgG anti- anti- bodies	Mild	Negative OCBs, normal IgG index	Brain: multifocal hyper- intense T2/FLAIR signals in bilateral subcortical and PV white matter without contrast enhancement

Table 1 (continued)

Author	Age (years)	Gender	Comorbidi- ties	Time rela- tion between SARS- COV-2 infection and NP	Presenting COVID-19 symptoms	Presenting neurological symptoms	Neuro- logical diagnosis	Other NS manifesta- tions	Treatment	Response to treatment	PCR test- ing for SARS- COV 2	Severity of COVID-19 infection	Other laboratory investiga- tions	MRI data
28. Scullen et al. [47]	63	Female	HTN, obesity	6 days	Fever, cough, shortness of breath, chest pain	Encephalopathy	HIE	None	Glucocorti- coids	NA	Positive in naso- phar- ynx	Severe	NA	Brain: FLAIR changes and diffusion restric- tion in bilateral globus pallidi and bilateral centrum semiovale. Gradient echo showed subtle changes in bilateral globus pallidi
29. Scullen et al. [47]	43	Female	HTN, DM	2 weeks	Cough, dyspnea	Encephalopathy	ANE	None	PLEX	No improve- ment	Positive in naso- phar- ynx	Severe	NA	Brain: FLAIR changes in bilateral mesial temporal structures, lenticular nuclei, crus cerebri, and centrum semiovale with dif- fusion- restriction of those areas together with the splenium, body, and genu of the corpus callosum. SWI sequences showed hemorrhagic conversion in the left cerebral peduncle and bilateral basal ganglia
30. Virham- mar et al. [48]	55	Female	None	7 days	Fever, myalgia	Lethargy and disturbed sensorium, multifocal myoclonus	ANE	None	IVIG and acyclovir, PLEX	Partial improvement	Positive in naso- phar- ynx, ini- tially nega- tive in CSF, later posi- tive in 3rd sam- sam- ple	Mild	NA	Brain: symmetri- cal pathological signal pattern in all sequences. Partial regression in follow- up

Table 1 (continued)

Author	Age (years)	Gender	Comorbidi- ties	Time rela- tion between SARS- COV-2 infection and NP	Presenting COVID-19 symptoms	Presenting neurological symptoms	Neuro- logical diagnosis	Other NS manifesta- tions	Treatment	Response to treatment	PCR test- ing for SARS- COV 2	Severity of COVID-19 infection	Other laboratory investiga- tions	MRI data
31. Dixon et al. [49]	59	Female	Aplastic anemia	10 days	Fever, cough and head- ache, myalgia, dyspnea	Seizure and altered senso- rium	ANE	None	Acyclovir, sup- portive treatment, high-dose dexa- metha- sone	No improve- ment, died	Positive in naso- phar- ynx, nega- tive in CSF	Mild	NA	Brain: extensive, relatively symmetrical changes throughout the supratentorial and infratentorial areas with diffuse swelling and hemorrhage in the brain stem and amygdalae. Extensive abnormal signal and microhemorrhage within thalamic nuclei, subinsular regions, splenium of corpus callosum, cin- gulate gyri, and sub- cortical perirolandic regions with restricted diffusion with periph- eral enhancement, tonsillar herniation
32. Montes- Ramirez [50]	27	Female	None	17 days	Fever, dyspnea	Aphasia and quadripareisis	Diffuse leukoen- cephal- opathy a with micro- bleeds	None	IVMP	Complete recovery	Positive in naso- phar- ynx	Severe	NA	Brain: ependymal enhancement, leukoencephalopathy, and microbleeds
33. McCuddy et al. [51]	37	Female	DM, HTN, obesity	22 days	Fever, cough, chest pain, dyspnea	Diffuse weak- ness post- extubation	ADEM	None	Decadron 20 mg IV for 5 days, 10 mg IV for 5 days	Marked partial improvement	Negative CSF, posi- tive in serum	Severe	Negative OCBs	Brain: T2-hyperinten- sity with restricted diffusion in corpus callosum, bilateral cerebral WM, pons, bilateral ventral medulla, with some enhancement
34. McCuddy et al. [51]	56	Male	DM, HTN, CKD, asthma	20 days	Fever, cough, chest pain and dyspnea	Encephalopathy	ADEM	None	Solumedrol 1 g for 5 days, IVIG	Mild partial improvement	Nega- tive in CSF, posi- tive in serum	Severe	Negative OCBs	Brain: diffuse hyperin- tensities in cerebral WM and cerebellum, with restricted dif- fusion

Table 1 (continued)

Author	Age (years)	Gender	Comorbidi- ties	Time rela- tion between SARS- COV-2 infection and NP	Presenting COVID-19 symptoms	Presenting neurological symptoms	Neuro- logical diagnosis	Other NS manifesta- tions	Treatment	Response to treatment	PCR test- ing for SARS- COV 2	Severity of COVID-19 infection	Other laboratory investiga- tions	MRI data
35. McCuddy et al. [51]	70	Female	DM, HTN, CKD, obesity	16 days	Fever, cough, chest pain, dyspnea	Encephalopathy	ADEM	None	Solumedrol 1 g for 5 days, IVIG	Mild partial improvement	Nega- tive in CSF, posi- tive in serum	Severe	Negative OCBs	Brain: T2-hyperintensi- ties in cerebral WM, corpus callosum, brachium pontis with some restricted diffusion Brain: an unusual DWI pattern with nodular and ring-shaped lesions involving the PV and DWM
36. Assuncao et al. [52]	49	Male	None	30 days	Respiratory symp- toms	Altered senso- rium	ADEM	None	NA	NA	Positive in naso- phar- ynx, nega- tive in CSF	Severe	NA	Brain: unusual DWI pat- tern with nodular and ring-shaped lesions involving the PV and DWM
37. Assuncao et al. [52]	9	Male	None	37 days	None	Difficulty walking and speaking, right hemiparesis, and impaired ocular motor function	ADEM	None	NA	NA	Positive serol- ogy	Mild	NA	Brain: unusual DWI pat- tern with nodular and ring-shaped lesions involving the PV and DWM
38. Parsons et al. [53]	51	Female	NA	At initial presenta- tion	Fever, dyspnea, vomiting	Altered senso- rium	ADEM	None	IVMP 1 g for 5 days, IVIG for 5 days	Partial improvement	Positive in naso- phar- ynx, nega- tive in CSF	Severe	Negative OCBs, AQP4 antibod- ies	Brain: scattered hyperintense lesions on FLAIR imaging in DWM and juxta- cortical areas, left frontal juxta-cortical white matter showed mild enhancement with a small amount of intraventricular hemorrhage in the occipital horns of both lateral ventricles. No parenchymal hemorrhage

Table 1 (continued)

Author	Age (years)	Gender	Comorbidi- ties	Time rela- tion between SARS- COV-2 infection and NP	Presenting COVID-19 symptoms	Presenting neurological symptoms	Neuro- logical diagnosis	Other NS manifesta- tions	Treatment	Response to treatment	PCR test- ing for SARS- COV 2	Severity of COVID-19 infection	Other laboratory investiga- tions	MRI data
39. Langley et al. [54]	53	Male	NA	8 days	Fever, cough, shortness of breath, myalgia, malaise	Altered senso- ritum	ADEM	None	IVMP 1 g for 3 days followed by two 500 mg doses	Partial improvement	Positive naso- phar- ynx	Severe	Positive OCBs	Brain: multiple hyperintense lesions within the subcortical and DWI of the frontoparietal lobes bilaterally with restricted diffusion centrally. No leptome- ningeal enhancement was seen. Small intraventricular hem- orrhage within the occipital horns of the lateral ventricles. SWI showed microhemor- rhages in parietal gyri, bilateral superior frontal lobes and occipital lobe
40. Wong et al. [55]	40	Male	None	13 days	Fever, dyspnea on exer- tion	Unsteady gait, diplopia, oscillopsia, limb ataxia, altered sensa- tion in right arm, hiccups and dysphagia	Inflam- matory brain stem encepha- litis, LETM	None	Supportive	Partial improvement	Positive in naso- phar- ynx	Moderate	NA	Brain: hyperintensi- ties in right inferior cerebellar peduncle, extending to involve a small portion of cervi- cal cord with associ- ated microhemorrhage The supratentorial region of the brain was normal Spine: LETM measur- ing 28 mm in longitu- dinal extent
41. Novi et al. [56]	64	Female	Vitiligo, HTN, MGUS	2 weeks	Influenza- like symp- toms, anosmia, ageusia	Irritability and bilateral vision impairment associated with sensory deficit on her right leg	ADEM, TM	None	IVMP 1 g for 5 days tapered with oral pred- nisone 75 mg/d) associ- ated with IVIG (2 g/kg in 5 days)	Marked but partial improvement	Nega- tive in naso- phar- ynx, posi- tive in CSF	Mild	Negative OCBs	Brain: evidence of multiple T1 post-Gd enhancing lesions of the brain Spine: single spinal cord lesion at the T8 level Orbit: bilateral optic nerve enhancement

Table 1 (continued)

Author	Age (years)	Gender	Comorbidi- ties	Time rela- tion between SARS- COV-2 infection and NP	Presenting COVID-19 symptoms	Presenting neurological symptoms	Neuro- logical diagnosis	Other NS manifesta- tions	Treatment	Response to treatment	PCR test- ing for SARS- COV 2	Severity of COVID-19 infection	Other laboratory investiga- tions	MRI data
42. Otluoğlu et al. [57]	48	Male	None	At initial presenta- tion	Progressive headache and persistent cough, fatigue, myalgia, anosmia	Headache, anosmia	Viral encepha- litis, TM	None	IVMP 1 g for 5 days, IV acy- clovir for 21 days	NA	Nega- tive in naso- phar- ynx, posi- tive in CSF	Mild	NA	Brain: hyperintense lesions both in the posterior medial cortical surface of the temporal lobe consistent with viral encephalitis Spine: hyperintense lesions confined to the upper cervical spinal cord
43. Utkuri et al. [58]	44	Male	None	At initial presenta- tion	None	Urinary retention for 2 days, bilateral lower limbs weakness and numbness, inability to walk, lethargy, dysarthria and upper limb ataxia	ADEM, LETM	None	IVMP 1 g, IVIg	Partial improvement	Positive in naso- phar- ynx, nega- tive in CSF	Mild	Negative OCBs, normal IgG index	Brain: PV and juxta- cortical lesions with homogeneous brisk enhancement in the left parietal lobe juxta-cortical/cortical lesions Spine: non-enhancing T2 hyperintense lesions throughout cervical and thoracic. Slight expansion of the conus medullaris with mild T2 hyper- intensity and minimal foci of enhancement
44. Lopes et al. [59]	59	Female	HTN	3 days	Fever, cough, res- piratory failure	Disturbed level of conscious- ness	ADEM	None	Non- specific	Died	Positive in naso- phar- ynx, nega- tive in CSF	Severe	Negative OCBs	Brain: multiple bilateral focal areas of signal abnormalities in the cerebral and cerebellar white mat- ter, including corpus callosum, cerebellar and globus pallidus
45. Lopes et al. [59]	41	Male	DM, HTN, obesity	6 days	Fever, rhi- norhea, progres- sive dyspnea, res- piratory failure	Disturbed level of conscious- ness	ADEM	Sensori- motor poly- neu- ropathy	NA	Marked improvement	Positive in naso- phar- ynx, nega- tive in CSF	Severe	Negative OCBs	Brain: focal lesions located in the centrum semiovale, bilaterally, right thalamus, globus pallidus bilaterally, and anterior limb of internal capsule

Table 1 (continued)

Author	Age (years)	Gender	Comorbidi- ties	Time rela- tion between SARS- COV-2 infection and NP	Presenting COVID-19 symptoms	Presenting neurological symptoms	Neuro- logical diagnosis	Other NS manifesta- tions	Treatment	Response to treatment	PCR test- ing for SARS- COV 2	Severity of COVID-19 infection	Other laboratory investiga- tions	MRI data
46. Lindan et al. [29]	0.17	Male	None	1 day	Fever, cough	Seizures	ADEM	None	Supportive measures in ICU, AEDs	Marked improvement	Positive in naso- phar- ynx	Severe	NA	Brain: multifocal T2 hyperintensity throughout bilateral thalami
47. Lindan et al. [29]	1.17	Female	None	2 days	Fever	Encephalopa- thy, dystonic posturing, seizures	ADEM	None	Intubated, sup- portive measures in ICU, AEDs	Marked improvement	Positive in naso- phar- ynx	Severe	NA	Brain: confluent areas of T2 hyperintensity and restricted diffusion in the central gray, pons, and subcortical white matter. Splenic lesion
48. Lindan et al. [29]	9	Male	Asthma	5 days	Fever, cough, headache	Encephalopathy, photophobia, phonophobia, seizures	ADEM	None	Intubated, sup- portive measures in ICU, IVIG	Marked improvement	Positive in naso- phar- ynx	Severe	NA	Brain: diffuse lepto- meningeal enhancement, patchy T2 hyperin- tensity of cerebral white matter and cerebellum. Cortical, thalamic and splenic signal abnormalities. Follow-up 2.5 weeks: extension to optic chiasm and bilateral pyramidal tracts
49. Lindan et al. [29]	13	Male	None	1 day	Fever, headache	Lower limb weakness	ADEM, LETM	None	IVMP	Marked improvement	Positive in naso- phar- ynx	Mild	NA	Brain: extensive patchy white matter and basal ganglia T2 hyperin- tensities, associated mass effect and mild enhancement of right frontal lobe Spine: long segment mildly expansive central cord T2 hyperintensity. No post-contrast imaging of spine
50. Lindan et al. [29]	0.25	Male	None	12 days	Cough without fever,	Lower > upper limb spastic- ity and brisk DTR's, reduced weight bear- ing	ADEM, LETM	None	IVIG	Partial improvement	Positive in naso- phar- ynx	Mild	NA	Brain: T2 hyperintensity brainstem Spine: long segment cord T2 hyperinten- sity with central gray matter predominance. No post-contrast imaging

Table 1 (continued)

Author	Age (years)	Gender	Comorbidi- ties	Time rela- tion between SARS- COV-2 infection and NP	Presenting COVID-19 symptoms	Presenting neurological symptoms	Neuro- logical diagnosis	Other NS manifesta- tions	Treatment	Response to treatment	PCR test- ing for SARS- COV 2	Severity of COVID-19 infection	Other laboratory investiga- tions	MRI data
51. Lindan et al. [29]	1.58	Female	None	3 days	Irritability	Gait impair- ment, consti- pation	ADEM, LETM	Neuritis: cauda equina	High-dose steroids	Complete improvement	Positive in naso- phar- ynx	Mild	NA	Brain: punctate and linear T2 hyperintense foci and enhancement in subcortical white matter Spine: long segment T2 hyperintensity with central gray matter predominance and patchy enhancement. Enhancement of cauda equina
52. Lindan et al. [29]	14	Female	None	2 days	Fever	Encephalopa- thy, seizures, respiratory failure	ADEM	Anti- NMDAR autoim- mune encepha- litis	Intubated, sup- portive measures in ICU	No improve- ment	Positive in naso- phar- ynx	Severe	NA	Brain: initial normal, follow-up 4 weeks: patchy T2 hyperin- tensity white matter and basal ganglia, brainstem, cerebel- lar peduncles. No restricted diffusion or enhancement
53. Lindan et al. [29]	5	Female	None	1 day	MIS-C syn- drome, fever, abdomi- nal pain, diarrhea	Encephalopathy	ADEM	None	Supportive measures in ICU	Complete improvement	Positive in naso- phar- ynx	Severe	NA	Brain: T2 hyperintensity cerebral white WM. Focal CC and splenial lesions of corpus callosum, T2 hyperin- tensity and restricted diffusion
54. Lindan et al. [29]	9	Male	None	11 days	MIS-C syn- drome	Encephalopathy, gait impair- ment	ADEM	Myositis	Supportive measures in ICU	Complete improvement	Positive in naso- phar- ynx	Severe	NA	Brain: T2 hyperintensity cerebral white WM
55. Lindan et al. [29]	9	Male	None	2 days	MIS-C syn- drome, fever, head- ache, neck pain	Encephalopathy, cerebellar signs, weak- ness	ADEM	Myositis	Supportive measures in ICU	Partial improvement	Positive in naso- phar- ynx	Severe	NA	Brain: T2 hyperinten- sity cerebral WM. Splenial lesion T2 hyperintensity and restricted diffusion
56. Lindan et al. [29]	13.25	Female	None	1 day	MIS-C syn- drome, fever	Headache encepha- lopathy, facial paralysis	ADEM	Neuritis	Supportive measures in ICU	Partial improvement	Positive in naso- phar- ynx	Severe	NA	Brain: T2 hyperintensity hypothalamus. Blat- eral neuritis CN VII

Table 1 (continued)

Author	Age (years)	Gender	Comorbidities	Time relation between SARS-COV-2 infection and NP	Presenting COVID-19 symptoms	Presenting neurological symptoms	Neurological diagnosis	Other NS manifestations	Treatment	Response to treatment	PCR testing for SARS-COV 2	Severity of COVID-19 infection	Other laboratory investigations	MRI data
57. Lindan et al. [29]	13.83	Female	Asthma	6 days	MIS-C syndrome with cardiac dysfunction,	Stupor, pyramidal signs	ADEM, TM	None	Supportive measures in ICU	Complete improvement	Positive in nasopharynx	Severe	NA	Brain: T2 hyperintensity hypothalamus Spine: focal T2 hyperintensity in thoracic cord with central predominance
58. Lindan et al. [29]	14.5	Male	None	8 days	MIS-C syndrome, fever, diarrhea, rash, hypotension	Encephalopathy,	ADEM	None	Supportive measures in ICU	Complete improvement	Positive in nasopharynx	Severe	NA	Brain: T2 hyperintensity cerebral WM. Splenic lesion T2 hyperintensity and restricted diffusion
59. Lindan et al. [29]	15	Female	Obese	18 days	MIS-C syndrome, fever, cough, dyspnea	Encephalopathy, myalgias, leg swelling	ADEM	Vasculitis/thrombosis	Supportive measures in ICU	Complete improvement	Positive in nasopharynx	Severe	NA	Brain: T2 hyperintensity cerebral WM. Splenic lesion T2 hyperintensity and restricted diffusion Innumerable microthrombi cerebrum, brainstem, cerebellum
60. Lindan et al. [29]	0.83	Male	None	1 week	Fever	Right ptosis, hypotonia, encephalopathy	ADEM, LETM	Neuritis	Supportive measures, high-dose steroids	Partial improvement. Relapse at 3 months after weaning steroids	Negative PCR in nasopharynx, serology positive	Severe	NA	Brain: T2 hyperintensities in cerebral WM, thalami, brainstem and cerebellum. Associated foci of enhancement and restricted diffusion Spine: long segment predominance and without enhancement
61. Lindan et al. [29]	4.17	Male	None	NA	Skin rash	Seizures, facial palsy, four limb dysfunctions	ADEM	None	High-dose steroids	Marked improvement	Negative PCR in nasopharynx,	Mild	Anti-MOG positive	Brain: T2 hyperintense lesions in cerebral cortex and thalamus. No enhancement

ADEM acute disseminated encephalomyelitis, *TM* transverse myelitis, *NMOSD* neuromyelitis optica spectrum disorders, *HIE* hypoxic ischemic encephalopathy, *LETM* longitudinally extensive myelitis, *AHLE* acute hemorrhagic necrotizing encephalitis, *ANE* acute necrotizing encephalitis, *AHNE* acute hemorrhagic necrotizing encephalitis, *OCS* oligoclonal bands, *CSF* cerebrospinal fluid, *DM* diabetes mellitus, *HTN* hypertension, *IVMP* intravenous methylprednisolone, *GTCs* generalized tonic-clonic convulsions, *CNS* central nervous system, *GBS* Guillain-Barré syndrome, *AIDP* acute inflammatory demyelinating polyneuropathy, *MOG* myelin oligodendrocyte glycoprotein, *AQP4* Aquaporin4, *PCR* polymerase chain reaction, *CLL* chronic lymphocytic leukemia, *IgG* immunoglobulin G, *PLEX* plasma exchange, *CKD* chronic kidney disease, *WM* white matter, *CC* corpus callosum, *MGUS* monoclonal gammopathy with unknown significance, *PCOS* polycystic ovarian syndrome, *PV* periventricular, *DWM* deep white matter, *SWI* susceptibility-weighted imaging, *FLAIR* fluid-attenuated inversion recovery, *ICU* intensive-care unit, *AEDs* anti-epileptic drugs, *NMDAR-N-methyl-D-aspartate* receptor, *MIS-C* multisystem inflammatory syndrome in children

MS-like demyelination

Three cases of MS-like demyelination: two females and one male have been reported. Their ages were 24, 28 and 29 years. The presentation was localizing to brain stem in two of them. On the other hand, unilateral optic neuritis was the main complaint in the third case.

In all cases the COVID-19 symptoms preceded the neurological symptoms by 2–4 weeks and the infection was mild in severity.

Oligoclonal bands were positive in two patients and not tested in the third.

Although the patient reported by Moore et al. fulfilled the 2017 McDonald criteria [12], we believe the MRI lesions were quite atypical being round in shape and larger than typical MS plaques. Follow-up is mandatory to securely establish the diagnosis.

The same atypical pattern of demyelination applies to the patient reported by Yavari et al. [5], where the lesions were large and located mainly in deep white matter and subcortical areas.

Despite the fact that the third case presented with optic neuritis, the associated field defect rendered the presentation atypical. Moreover, only two supratentorial lesions were detected in addition to the optic nerve lesion which does not fulfill the 2017 McDonald criteria.

That raises the question of whether these cases represent true MS or just a post-viral demyelinating syndrome. Findings of clinical characteristics are summarized in Table 2.

NMOSD and MOGAD-like demyelination

Longitudinally extensive transverse myelitis (LETM) and symptomatic cerebral syndrome are two of the well-known core features of NMOSD. In addition, ADEM could herald the first presentation of the disorder [13]. The patient reported by Zhogi et al. [14] was a 21-year-old male who presented with lethargy, vomiting, weakness of both lower limbs and urine retention, few weeks after suspicious COVID-19 symptoms.

Brain MRI revealed affection of bilateral corticospinal tracts up to cerebral peduncle and pons, marbled hyperintensity in the splenium of corpus callosum. Moreover, LETM was reported on his spinal MRI and testing for AQP4 antibody was positive. This patient received a probable diagnosis of COVID-19 based on his previous symptoms, chest imaging and positive antibody testing.

Additionally, Correa et al. [4] reported another female patient with LETM and brain hyperintensities in the fornix and subfornical area. The serology was positive for AQP4 after receiving a definite diagnosis of COVID-19 few weeks earlier.

MOGAD was reported in three post-COVID-19 patients based on positive antibody testing; the first was a 15-year-old patient who suffered subacute bilateral optic neuritis. COVID-19 infection was suspected based on his previous symptoms and two family members developing the infection a few weeks later. It was confirmed with positive nasopharyngeal PCR testing.

The second case was a 47-year-old male who presented with bilateral optic neuritis following asymptomatic infection, and was suspected based on his contact with positive cases. The infection was never confirmed though. Findings of clinical characteristics are shown in Table 2

The third case was a 4-year-old child presenting with ADEM. He had a mild infection with marked improvement after high-dose steroid treatment (Table 1).

Transverse myelitis

A total of 40 cases of TM have been reported in relation to SARS-CoV-2, of whom, 24 were isolated TM (Table 3), and 16 as a part of diffuse demyelinating process (Tables 1, 2). The cases included 19 females and 21 males.

LETM was the most frequently reported pattern of spinal involvement reported in 72.5% of cases of myelitis (19/24 of cases of isolated TM and 10/16 of cases of diffuse demyelination). Conus medullaris involvement was reported in 3 cases (3/40).

There are many mechanisms by which SARS-CoV-2 can induce myelitis: acute viral myelitis, post-COVID-19 immune-mediated myelitis, ischemic myelitis, part of an inflammatory demyelinating syndrome triggered by COVID-19 infection (ADEM, MS, NMOSD, and MOGAD). Table 3 summarizes the reported cases of isolated myelitis with COVID-19 infection.

Demyelination in special populations (children, pregnancy and puerperium)

Twenty pediatric, one pregnant and one postpartum cases of COVID-19-related brain demyelination have been reported. Although the pregnant and postpartum females had severe COVID-19 infection that required mechanical ventilation, they recovered almost completely with high doses of steroids. The presentation was of typical ADEM in one and diffuse leukoencephalitis with microbleeds in the other.

Among the pediatric cohort, there were 12 males and 8 females, with a median age of 9 years. Of them, 60% (12/20) suffered from severe COVID-19 infection. All patients presented with a picture of ADEM with (5/20) or without associated myelitis. In the five patients with myelitis, four showed LETM. The outcome was favorable (marked to complete recovery) in 13/20 patients. COVID-19-related isolated TM was reported in five pediatric patients (Table 3). Their

Table 2 Characteristics of cases presenting with other COVID-19 related demyelinating syndromes

Author	Age	Gender	Comorbidities	Time relation between SARS-COV2 infection and NP	Presenting COVID symptoms	Presenting neurological symptoms	Neurological diagnosis	Other NS manifestations	Treatment	Response to treatment	Testing for SARS-COV 2	Severity of COVID infection	Antibody and OCBs testing	MRI data
1. Moore et al. [12]	28	Male	Glaucoma and right retinal hole treated with laser ablation	2 weeks	Fever, myalgia, anosmia, sore throat, headache and cough	Diplopia, vertigo, right oral numbness	MS	None	3 days pulse steroids with oral taper	Partial improvement	Positive nasopharyngeal PCR	Mild	Positive OCBs	Brain MRI: juxtacortical, PV and infratentorial lesions
2. Palao et al. [60]	29	Female	Asthma Rhino conjunctivitis	2–3 weeks	Anosmia and dysgeusia asthenia and proximal myalgia in her limbs	Right optic neuritis	MS	None	3 days pulse steroids with oral taper	Partial improvement	Negative PCR in nasopharynx and CSF Positive IgM and IgG	Mild	Positive OCBs	Orbital MRI: right optic nerve lesion with contrast enhancement Brain MRI: sparse supratentorial PV demyelinating lesions
3. Yavari et al. [5]	24	Female	None	1 month after onset Overlapped symptoms	Sore throat, low-grade fever, myalgia, anosmia	Blurred vision, diplopia, left lower motor neuron facial palsy, paresis of fingertips of both arms	MS-like	None	4 days pulse steroids INF-beta 1a: 3 times weekly	Partial improvement	Positive PCR in nasopharynx	Mild	NA	Brain MRI: atypical patches in the subcortical and DWM
4. de Ruijter [61]	15	Male	None	Few weeks	Fever, nausea and cough	Bilateral optic neuritis	MOGAD (bilateral ON)	None	Pulse steroids	Almost complete recovery in 2 weeks	NA	Mild	Negative OCBs Negative AQP4 Positive MOG antibody	Orbital MRI: bilateral extensive optic neuritis

Table 2 (continued)

Author	Age	Gender	Comorbidi- ties	Time relation between SARS- COV2 infection and NP	Presenting COVID symptoms	Presenting neurologi- cal symp- toms	Neurological diagnosis	Other NS manifesta- tions	Treatment	Response to treat- ment	Testing for SARS- COV 2	Sever- ity of COVID infec- tion	Antibody and OCBs testing	MRI data
5. Zoghi et al. [14]	21	Male	None	2–3 weeks from onset of COVID symp- toms	Fever, chills, non-pro- ductive cough	Weak- ness and parese- thesia of the lower limbs and upper limbs, urinary retention, vomit- ing and drowsi- ness and lethargy	ADEM vs NMOSD	None	PLEX for 5 days with antibiot- ics and antivirals	Partial improve- ment	Negative PCR in naso- pharynx and in CSF (positive chest and IgG)	Mild	Negative OCBs Negative AQP4 antibody Negative MOG antibody	Brain MRI: bilateral corti- cospinal tracts up to cerebral peduncle and pons, marbled hyperintensity in the splenium of corpus callosum Cervical spine MRI: LETM
6. Correa et al. [4]	51	Female	None	2 weeks	Fever, cough myalgia, headache, anosmia, ageusia	Dyses- thesia, abdomi- nal band (T6–10) associ- ated with lower extremity numbness and dys- esthesias, proprio- ceptive deficits, urinary retention, and left lower extremity weakness	NMOSD	Radiculitis	5-day course of methyl- predniso- lone (1 g/ day) fol- lowed by plasma exchange For long- term attack preven- tion, she is using aza- thioprine 3 mg/kg per day	Remark- able neu- rological improve- ment	Positive PCR in naso- pharynx Negative PCR in CSF	Mild	Serum and CSF cell- based assay for anti- AQP4 antibod- ies were positive Positive IgG index	Brain MRI: a hyperintense lesion on T2WI and FLAIR in the anterior fornix and in the subformal organ, with con- trast enhance- ment Spinal MRI: (LETM) with a ring enhance- ment pattern and radiculitis

Table 2 (continued)

Author	Age	Gender	Comorbidi- ties	Time relation between SARS- COV2 infection and NP	Presenting COVID symptoms	Presenting neurologi- cal symp- toms	Neurological diagnosis	Other NS manifesta- tions	Treatment	Response to treat- ment	Testing for SARS- COV 2	Sever- ity of COVID infec- tion	Antibody and OCBs testing	MRI data
7. Zhou et al. [62]	26	Male	None	Few days	Dry cough	Eye pain, visual loss, lower limb numbness	MOGAD (bilateral ON + mye- litis)	None	Intravenous methyl- predniso- lone for 5 days, followed by an oral pred- nisone taper	Visual acuity Improved	Positive nasal and oro- pharyn- geal PCR	Mild	Positive OCBs Positive (MOG) IgG Negative AQP4 antibody	Spinal MRI: patchy T2 hyper- intensities in the lower cervical and upper tho- racic spinal cord associated with mild central thickening and GAD enhance- ment Brain and orbits MRI: avid, uniform enhancement and thickening of both optic nerves extending from the globe to their intra- cranial, pre-chias- mal segments, without overt involvement of the chiasm One small non- enhancing, nonspecific periventricular T2 hyperinten- sity was present, adjacent to the occipital horn of the right lateral ventricle

Table 2 (continued)

Author	Age	Gender	Comorbidi- tites	Time relation between SARS- CoV2 infection and NP	Presenting COVID symptoms	Presenting neurologi- cal symp- toms	Neurological diagnosis	Other NS manifesta- tions	Treatment	Response to treat- ment	Testing for SARS- COV 2	Sever- ity of COVID infec- tion	Antibody and OCBs testing	MRI data
8. Kogure et al. [63]	47	Male	Right adrenal resection. Recurrent paranasal sinuses	2 days	Asymp- tomatic (close contact of a positive case)	Left eye pain and upper visual field defect	MOGAD	None	Methyl- predniso- lone 1 g/ day for a total of 3 days, followed by an oral predniso- lone taper	Partial	Negative PCR in naso- pharynx Negative PCR in CSF	Mild	Positive MOG antibody	Orbit MRI: post-contrast T1-weighted fat-suppressed MRI revealed the bilateral (but left-dom- inant) uniform enhancement along with optic nerve sheaths

NP neurological presentation, NS nervous system, MS multiple sclerosis, MOGAD MOG antibody disease, ADEM acute disseminated encephalomyelitis, NMOSD neuromyelitis optica spectrum disorder, ON optic neuritis, CSF cerebrospinal fluid, IgM immunoglobulin M, IgG immunoglobulin G, AQP4 Aquaporin 4, LETM longitudinally extensive transverse myelitis, PLEX plasma exchange, MOG myelin oligodendrocyte glycoprotein, PCR polymerase chain reaction

median age was 11 years. LETM was the presenting imaging feature in all of them. Unfortunately, the outcome ranged between no to partial improvement.

Discussion

Several recent studies have evaluated the possible mechanisms of COVID-19-associated demyelination. Viral infection has demonstrated the ability to induce an inflammatory response, activating myelin-specific T cells, which can accelerate the development of early or delayed virus-induced demyelination [15]. Historically, SARS-CoV-1 and MERS-CoV, which are genetically similar to SARS-CoV-2, has been associated with central demyelination in literature [7].

Several experimental studies [16] revealed that murine coronavirus infection of susceptible mice has led to an inflammatory demyelination similar to MS, with coronavirus RNA sequences and its antigen detected in the demyelinating lesions. Furthermore, in one study [17], HCoV-229E viral RNA and HCoV-myelin cross-reactive T cell lines were predominantly detectable in the CNS of 36% of patients with MS, compared to none in patients with other neurological diseases and normal controls.

Although the exact mechanism of virus spread in the CNS has not been established, the two possible explanations are either hematogenous spread from systemic circulation to CNS or trans-neuronal spread through the olfactory pathway. In addition, the CNS can be potentially compromised through an ischemic–hypoxic insult resulting from severe respiratory affection or by latent immune-mediated mechanisms.

SARS-CoV-2 exhibits neurotropic and neuro-invasive properties and can cause direct neurological damage, through binding to angiotensin-converting enzyme-2 (ACE-2) receptors, whose expression is ubiquitous, including the CNS, or via blood circulation through Virchow Robin spaces [11]. Moreover, delayed CNS damage appears to be mediated by an undesired immune reaction following acute infection, leading to CNS demyelination [18].

Accumulated evidence showed that SARS-CoV-2 and several proinflammatory cytokines, including IL-1 β , IL-2, IL-4, IL-6, IL-8, IL-10, TNF- α , and IFN- γ , can cross the blood–brain barrier, affecting macrophages, microglia, and astrocytes, which are the principal cells that mediate innate immunity in the CNS, thus creating a perfect cytokine storm for a proinflammatory state [10, 19]. IL-6 is an important proinflammatory mediator that can induce an immune response in the nervous system, and plays a crucial role in regulating the immune response in MS. In experimental autoimmune encephalomyelitis (EAE) model of MS, IL-6 aggravates clinical manifestations, neuroinflammation, and demyelination, principally by promoting pathogenic T helper

Table 3 Characteristics of cases presenting with COVID-19 related isolated myelitis

Author	Age	Gender	Comorbidities	Time relation between infection and NP	Presenting COVID-19 symptoms	Presenting neurological symptoms	Neurological diagnosis	Other NS manifestations	Treatment	Response to treatment	Testing for SARS-COV-2	Severity of COVID-19 infection	Antibody and OCBs testing	MRI data
1. Valiuddin [64]	61	Female	None	A week	Rhinorrhoea, chills and generalized weakness	Numbness and tingling in hands and feet, weakness in both lower limbs and upper limbs, constipation and urine retention	Acute COVID myelitis (LETM)	Acute Motor Axonal Neuropathy (AMAN)	IVMP for 5 days, 5 sessions PLEX	No improvement Mild improvement	Positive PCR in nasopharynx, negative in CSF	Mild	NA	Cervico-thoraco-lumbar spine; LETM without pathological contrast enhancement
2. Moreno-Escobar [65]	41	Male	None	A week	Headache, nausea and low-grade fever, fatigue and myalgia	Paresthesia of bilateral upper and lower extremities along with urinary and fecal retention Weakness of both lower limbs	Post COVID-19 myelitis vs NMOISD (LETM)	Dysautonomia	IVMP for 5 days with oral taper	Partial	Positive PCR in nasopharynx	Mild	Negative OCBs, AQP4 and MOG antibodies	Cervical and thoracic spinal: LETM without any abnormal enhancement
3. Munz et al. [66]	60	Male	HTN, fatty liver, ureterolithiasis	3 days	Respiratory symptoms	Bladder dysfunction and progressive weakness of the lower limbs	Post-COVID myelitis	None	IV Acyclovir and ceftriaxone, IVMP 100 mg/day	Marked but partial	Positive PCR in nasopharynx, negative in CSF	Moderate	Negative OCBs	Thoracic spinal: T2 signal hyperintensity of the thoracic spinal cord at Th9 level suggestive of acute transverse myelitis rather than multiple sclerosis FUP after 6 days: a patchy hyper-intensity of the thoracic cord at Th9-10 and at Th3-5 level, suggestive of transverse myelitis

Table 3 (continued)

Author	Age	Gender	Comorbidities	Time relation between infection and NP	Presenting COVID-19 symptoms	Presenting neurological symptoms	Neurological diagnosis	Other NS manifestations	Treatment	Response to treatment	Testing for SARS-COV-2	Severity of COVID-19 infection	Antibody and OCBs testing	MRI data
4. Sarma et al. [67]	28	Female	Hypothyroidism	At initial presentation	Productive cough, fever, myalgia, rhinorrhea	Low back pain, parasthesia in both lower limbs, urine retention, nausea and vomiting	Immune mediated COVID-myelitis (LETM)	None	Prednisolone and received two PLEX treatments	Partial	Positive PCR in nasopharynx	Mild	NA	Spine: widespread elongated signal changes throughout the spinal cord to the conus medullaris and involving the medulla (LETM)
5. Sotoca et al. [68]	69	Female	None	8 days	Fever and cough	Irradiated cervical pain, imbalance, and motor weakness and numbness in the left hand	Acute necrotizing myelitis (ANM) (LETM)	None	IVMP for 5 days, PLEX and another course of IVMP for 5 days with oral taper	Partial then deteriorated and new attack	Positive PCR in nasopharynx, negative in CSF	Mild	Negative OCBs, MOG and AQP4 antibodies	Spinal: LETM extending from the medulla oblongata to C7, involving most of the cord with diffuse patchy enhancing lesions A new spinal MRI after deterioration: transversally and caudally progression until T6 level with similar enhancement and a new area of central necrosis at the T1 level with peripheral enhancement FUP MRI after PLEX: substantial decrease in myelitis extension and enhancement, but central necrosis at the C7-T1 level remained unchanged

Table 3 (continued)

Author	Age	Gender	Comorbidities	Time relation between infection and NP	Presenting COVID-19 symptoms	Presenting neurological symptoms	Neurological diagnosis	Other NS manifestations	Treatment	Response to treatment	Testing for SARS-COV-2	Severity of COVID-19 infection	Antibody and OCBs testing	MRI data
6. Domingues et al. [69]	42	Female	None	3 weeks Symptoms overlapped	Coryza, nasal obstruction	Recurrent pareshesia of the left upper limb, later progressing to left hemithorax, and hemiface (these symptoms occurred 3 years ago)	Spinal CIS vs viral myelitis	None	No treatment received	Full spontaneous recovery after 3 weeks	Positive PCR in CSF, negative in nasopharynx	Definite	NA	Cervical: small lateral demyelinating patch that explains the symptoms
7. Alketbi et al. [70]	32	Male	None	2 days	High-grade fever and flu-like symptoms	Sudden onset of bilateral lower limb weakness, difficulty in sitting up, and in passing urine	Post-COVID-19 myelitis (LETM)	None	IVMP for 5 days	Marked partial	Positive PCR in nasopharynx	Mild	NA	Spinal: LETM
8. Durrani et al. [71]	24	Male	None	12 days	Fever, chills, nausea and vomiting	Bilateral lower extremity weakness in addition to developing overflow urinary incontinence	Post COVID-19 myelitis vs COVID-19 myelitis (LETM)	None	IVMP	Marked	Positive PCR in nasopharynx	Moderate	Negative OCBs	Spinal: LETM

Table 3 (continued)

Author	Age	Gender	Comorbidities	Time relation between infection and NP	Presenting COVID-19 symptoms	Presenting neurological symptoms	Neurological diagnosis	Other NS manifestations	Treatment	Response to treatment	Testing for SARS-COV-2	Severity of COVID-19 infection	Antibody and OCBs testing	MRI data
9. Abdelhady et al. [71]	52	Male	DM, G6PD deficiency	At initial presentation	Fever	Lower abdominal pain and inability to pass urine for the past 3 days, associated with fever and lower limb weakness	COVID-19 myelitis (LETM)	None	Steroids and acyclovir	Died	Positive PCR in nasopharynx, negative in CSF	Mild	NA	Thoracic spinal: LETM
10. Chow et al. [72]	60	Male	HTN, Hypercholesterolemia, ex smoker	18 days	Fever, cough, loss of taste and smell	Bilateral lower limb weakness, urinary retention and constipation	ATM (LETM)	None	IVMP for 3 days, physiotherapy	Complete neurological and radiological improvement	Positive PCR in nasopharynx	Mild	Negative serum anti-MOG, anti-MAG, and AQP4 antibodies	Whole spine: LETM Normal MRI brain and orbit Follow-up MRI whole spine after 10 days showed almost complete resolution
11. Kaur et al. [73]	3	Female	None	At initial presentation	Asymptomatic	Flaccid quadripareisis, neurogenic respiratory failure requiring intubation	ATM (LETM)	None	IVMP for 5 days (30 mg/kg/day) and IVIG (2 g/kg total dose), then seven sessions of PLEX, then Rituximab	No improvement	Positive PCR in nasopharynx	Mild	Negative serum AQP4 and MOG autoantibodies	Spine: LETM of cervical spinal cord extending from the lower medulla to the mid-thoracic level with no enhancement Brain and orbits: were normal Follow-up MRI: reduced edema, early cervical myelomalacia

Table 3 (continued)

Author	Age	Gender	Comorbidities	Time relation between infection and NP	Presenting COVID-19 symptoms	Presenting neurological symptoms	Neurological diagnosis	Other NS manifestations	Treatment	Response to treatment	Testing for SARS-COV-2	Severity of COVID-19 infection	Antibody and OCBs testing	MRI data
12. Masucio et al. [74]	70	Female	HTN, obesity	15 days	Fever, anosmia and generalized myalgia	Severe quadriparesis, decreased tactile and pain sensation in the lower limbs accompanied with urinary retention	ATM	Acute motor axonal neuropathy (AMAN)	PLEX followed by one course of IVIG	No improvement	Negative PCR in nasopharynx	Mild	Anti-GDIb IgM positive	Spine: hyperintensity in posterior portion of the spinal cord from vertebral levels (C7–D1), no gadolinium enhancement
13. Shahali et al. [75]	63	Male	DM, CRF, IHD	4 days	Fever, fatigue, sore throat, and runny nose	Severe paraplegia, constipation, and urinary retention	ATM (LETM)	None	IVMP for 3 days and then tapered to 1 mg/kg/day, followed by IVIG (2.5 g daily for 3 days)	Complete resolution of neurologic manifestations	Positive PCR in nasopharynx	Moderate	IgG index = elevated (>0.91)	Spine: LETM with linear enhancement within the mid and lower thoracic cord
14. Chakraborty et al. [76]	59	Female	None	4 days	Fever	Acute, severe progressive ascending flaccid paraplegia with retention of urine and constipation	ATM	None	IVMP at a dose of 1 g/day	Cardiac arrest, and death	Positive PCR in nasopharynx	Severe	NA	Thoracic spine: hyperintensity in the spinal cord at T6–T7 vertebral level, suggestive of myelitis
15. Baghbani et al. [77]	53	Female	DM, HTN, IHD	14 days	Fever, respiratory symptoms	Paraplegia, low back pain and urinary incontinence	ATM (LETM)	None	PLEX	Partial recovery	Positive PCR in nasopharynx	Mild	Negative CSF OCBs and the IgG index was in the upper limit of normal AQP4 and MOG antibodies were negative	Spine: LETM in the T8–T10 cord segments Brain: normal

Table 3 (continued)

Author	Age	Gender	Comorbidities	Time relation between infection and NP	Presenting COVID-19 symptoms	Presenting neurological symptoms	Neurological diagnosis	Other NS manifestations	Treatment	Response to treatment	Testing for SARS-COV-2	Severity of COVID-19 infection	Antibody and OCBs testing	MRI data
16. Guler et al. [78]	14	Female	None	At initial presentation	Asymptomatic	Right hemiplegia	ATM (LETM)	None	IVIG was administered at 400 mg/kg/day for 5 days. Followed by IVMP was given at 30 mg/kg/day for 7 days	Partial improvement	Positive PCR in nasopharynx	Mild	Serum AQP4 IgG was negative CSF OCBs were negative	Spine: showed a contrast-enhancing lesion causing expansion at the C2–C5 level
17. Fumery et al. [79]	38	Female	None	14 days	Dry cough, myalgia, fatigue and shortness of breath	Paraplegia, hypoaesthesia and bladder dysfunction	ATM (LETM)	None	IVMP (1 g daily for 8 consecutive days)	Significant clinical improvement	Positive PCR in nasopharynx	Mild	Negative for OCBs and CSF SARS-CoV-2 PCR Negative MOG and AQP4 antibodies	Spine: LETM with no gadolinium enhancement Brain: normal
18. Nejad Bilgari et al. [80]	11	Female	None	3 days	Fever	Flaccid paraplegia, urinary and fecal retention, epigastric pain	ATM (LETM)	None	IVIG (0.4 g/kg/day) for 5 days, IVMP (30 mg/kg) for 3 days, and seven sessions of PLEX	Slight improvement	Positive PCR in nasopharynx	Mild	NA	Spinal: LETM Brain: normal
19. Ali et al. [81]	56	Male	DM, G6PD deficiency	3 days	Fever, fatigue, dyspnea	Flaccid paraplegia, urinary incontinence	ATM (LETM)	None	IV pulse steroids and acyclovir	No improvement, cardiac arrest, death	Positive PCR in nasopharynx	Moderate	NA	Thoracic spine: LETM with no post-contrast enhancement Brain: normal

Table 3 (continued)

Author	Age	Gender	Comorbidities	Time relation between infection and NP	Presenting COVID-19 symptoms	Presenting neurological symptoms	Neurological diagnosis	Other NS manifestations	Treatment	Response to treatment	Testing for SARS-COV-2	Severity of COVID-19 infection	Antibody and OCBs testing	MRI data
20. Román et al. [82]	72	Male	HTN	None	Asymptomatic Contact of a positive case	Urine retention Dyesthesias in arms and legs and weakness of all four limbs	ATM	None	IVMP (1 g/day) for 5 days, enoxaparin 40 mg daily, followed by IVIG (30 g/day) for five days. Oral prednisone was prescribed for the next 30 days	Partial improvement	Positive serology	Mild	Positive OCBs	Brain: normal Cervicothoracic spinal: hyperintensities at C ₄ –C ₅ and Th ₃ –Th ₄ were observed without contrast enhancement
21. Paterson et al. [3]	48	Male	DM, HTN	19 days	Cough, dyspnea and fever	Numbness of hands and feet; band of itching sensation at level of the umbilicus and ataxia	Post-infectious myelitis (LETM)	None	IVMP for 3 days	Partial improvement	NA	Mild	Negative OCBs	Brain: normal Thoracic spine: LETM down to the conus with no enhancement with contrast
22. Saberi et al. [83]	60	Male	DM, HTN, hyperlipidemia	2 weeks	Fever, nausea and vomiting	Progressive weakness of lower limbs accompanied by urinary incontinence and constipation	Post-infectious myelitis (LETM)	None	IVIG (30 g/day) was initiated for 5 days PLEX for 5 days	Improved initially then worsened again No improvement	Negative PCR in nasopharynx	Mild	Negative AQP4 antibodies	Cervical spine: LETM In the second cervical MRI, the previous hyperintense lesion was smaller and shrunken

Table 3 (continued)

Author	Age	Gender	Comorbidities	Time relation between infection and NP	Presenting COVID-19 symptoms	Presenting neurological symptoms	Neurological diagnosis	Other NS manifestations	Treatment	Response to treatment	Testing for SARS-COV-2	Severity of COVID-19 infection	Antibody and OCBs testing	MRI data
23. Lindan et al. [29]	3	Female	None	1 day	Fever, diarrhea, urinary retention, hyperreflexia	Upper and lower extremity weakness, acute respiratory failures, confusion	Myelitis (LETM)	None	Supportive measures in ICU	No improvement	Positive PCR in nasopharynx	Severe	NA	Brain: normal Spine: expansible T2-hyperintense signal from obex to mid-thoracic cord with mild enhancement Follow-up 4 days: worsening cord edema with extensive restricted diffusion, hemorrhage and enhancement Follow-up 3 weeks: interval myelomalacia with persistent restricted diffusion
24. Lindan et al. [29]	12	Male	None	3 days	Fever, diarrhea	Urinary retention, hyperreflexia	Myelitis (LETM)	None	High-dose steroids	Partial improvement	Positive PCR in nasopharynx	NA	NA	Spine: long segment T2-hyperintensity from the obex through the mid-thoracic cord, with central predominance. No post-contrast imaging

NP neurological presentation, NS nervous system, LETM longitudinally extensive transverse myelitis, PLEX plasma exchange, IVP intravenous methyl prednisolone, IIG intravenous immunoglobulin, OCBs oligoclonal bands, AQP4 Aquaporin4, MOG myelin oligodendrocyte glycoprotein, FUP follow-up, ANM acute necrotizing myelitis, CIS clinically isolated syndrome, PCR polymerase chain reaction, TM transverse myelitis, HTN hypertension, ATM acute transverse myelitis, DM diabetes mellitus, CRF chronic renal failure, IHD ischemic heart disease, G6PD glucose 6-phosphate dehydrogenase deficiency

(Th) 17 cell generation in the peripheral lymphoid organs [20, 21]. The levels of IL-6 were found to be correlated with the severity of COVID-19 symptoms, and this dysregulation can affect both innate and acquired immunity [1]. Furthermore, most COVID-19 patients exhibit increased circulating levels of IL-17 [22], which has a documented role in MS pathogenesis, mainly based on the data obtained from EAE model [23].

Moreover, autopsy data showed activation of astrocytes and microglia with infiltration of cytotoxic T cells, particularly in the brainstem, in COVID-19 patients [24]. In addition, Toll-like receptors (TLR), the main pattern recognition receptors expressed by CNS cells, have played a significant role in the pathogenesis of MS, and EAE model [25]. TLR are also believed to play a significant role in the pathogenesis of COVID-19, mainly through recognition of viral particles, activation of the innate immune system, and secretion of pro-inflammatory cytokines [26].

Another possible explanation could be the production of antibodies against myelin triggered by the virus. This para-infectious or post-infectious etiology is reported in several cases of post-SARS-CoV-2 Guillain–Barre syndrome. SARS-CoV-2 may play a role in triggering MS, similar to the documented role of Epstein–Barr virus [27]. These key aspects represent a maladaptive immune response to SARS-CoV-2 characterized by hyperactivity of innate immunity followed by immune dysregulation.

In view of this data, the reported cases in this review support a demyelinating aspect to SARS-CoV-2 infection. In the majority of cases, COVID-19 infection was confirmed by RT-PCR testing and in the remaining by adequate clinical, radiological and serological testing. Although causality cannot be adequately established, there is enough evidence to warrant further large-scale studies.

Brain demyelination was reported in a good number of cases; 78 patients, with encephalitis/encephalomyelitis presentation being the most common. The development of hemorrhage is potentially related to the severity of the respiratory involvement. Hypoxia as a result of such severe infection is a very likely contributing mechanism.

Although MS and other demyelinating diseases were reported, caution is a must when interpreting these findings, as in some cases the clinical presentation and MRI lesions are atypical. Further supporting laboratory investigations such as OCBs, VEP and spinal cord imaging will be needed to support the diagnosis. Despite the presence of MOG antibodies in some cases, MOGAD diagnosis should be made with caution, as acute bilateral optic neuritis and ADEM could be triggered by COVID-19 infection. A close follow-up is recommended to establish a solid diagnosis.

The fact the cytokines are involved to a great extent in COVID-19 pathogenesis could explain the trigger of MS and other common demyelinating disorders as they share

the same pathogenic mechanisms. This might also explain the beneficial effects of steroids, plasma exchange (PLEX) and intravenous immunoglobulins (IVIg) in many of the reported cases.

It is noteworthy to mention the high frequency of LETM in the cases presenting with myelitis. Although it is shared by many diseases like NMOSD, idiopathic TM, and ADEM, SARS-CoV-2 myelitis should be added to the list of differential diagnosis of LETM.

With regard to the pediatric age group, and contrary to adult population, CNS demyelination appears to be less common, and usually associated with the development of multisystem inflammatory syndrome (MIS-C) [28]. Demyelinating disease etiologies can be difficult to stratify in children, as many of the initial presentations overlap among disease and syndromes; however, the most frequent type was post-infectious, immune-mediated ADEM-like presentation, followed by TM, and isolated splenic lesions [29]. Furthermore, the time of presentation, and the constantly negative PCR in CSF samples from affected patients, strongly suggests a post-infectious mechanism for the pathogenesis of CNS demyelination [30]. However, rare cases of acute, rather than post-infectious cerebellar ataxia have been recently reported in children with COVID-19 [31].

There are some limitations to the current systematic review. The main limitation is that it was based on small number of case reports and case series, despite extensive search of available literature, which hindered the ability to perform a meta-analysis. Moreover, although the selected reports provided relevant information, there was great heterogeneity regarding several aspects of the collected data. Furthermore, in few cases, nasopharyngeal RT-PCR testing was not performed, and in the majority of cases, CSF-PCR was negative, probably due to delayed presentation. Despite these shortcomings, the current review provides preliminary data on SARS-CoV-2-associated demyelinating diseases that can guide neurologists in dealing with such cases, and help future research.

Conclusion

This systematic review has shown an association between SARS-CoV-2 infection and the development of different types of CNS demyelination in literature, although causality cannot be made with absolute certainty. A probable para-infectious or post-infectious immune-mediated etiology might be implicated in patients with COVID-19. We are currently facing a dilemma of diagnosing common neurological disorders in the setting of this viral infection, raising the question of whether there is causality in this association, or just coincidence. The long-term prognosis of such cases is not clear, which may have implications regarding the use

of disease-modifying therapies, or symptomatic treatments, in these patients. This relationship needs to be clarified in future research.

Author contributions III: conceptualization (equal); data curation (equal); investigation (equal); methodology (equal); project administration (equal); validation (equal); supervision (equal); writing—original draft (equal); writing—review and editing (equal). SS: conceptualization (equal); data curation (equal); investigation (equal); methodology (equal); project administration (equal); validation (equal); supervision (equal); writing—original draft (equal); writing—review and editing (equal).

Funding No funding received.

Declarations

Conflicts of interest The authors declare that the research was conducted in the absence of any commercial or financial relationships that could be construed as a potential conflict of interest.

References

- Andalib S, Biller J, Di Napoli M, Moghimi N, McCullough LD, Rubinos CA et al (2021) Peripheral nervous system manifestations associated with COVID-19. *Curr Neurol Neurosci Rep* 21(3):9
- Montalvan V, Lee J, Bueso T, De Toledo J, Rivas K (2020) Neurological manifestations of COVID-19 and other coronavirus infections: a systematic review. *Clin Neurol Neurosurg* 194:105921
- Paterson RW, Brown RL, Benjamin L, Nortley R, Wiethoff S, Bharucha T et al (2020) The emerging spectrum of COVID-19 neurology: clinical, radiological and laboratory findings. *Brain* 143(10):3104–3120
- Corrêa DG, de Souza Lima FC, da Cruz Bezerra D, Coutinho AC, Hygino da Cruz LC (2021) COVID-19 associated with encephalomyelorradiculitis and positive anti-aquaporin-4 antibodies: cause or coincidence? *Mult Scler* 27(6):973–976
- Yavari F, Raji S, Moradi F, Saeidi M (2020) Demyelinating changes alike to multiple sclerosis: a case report of rare manifestations of COVID-19. In: Banerjee TK (ed) *Case reports in neurological medicine*. Hindawi, London, pp 1–4
- Mahalakshmi AM, Ray B, Tuladhar S, Bhat A, Paneyala S, Patteswari D et al (2021) Does COVID-19 contribute to development of neurological disease? *Immun Inflamm Dis* 9(1):48–58
- Gu J, Gong E, Zhang B, Zheng J, Gao Z, Zhong Y et al (2005) Multiple organ infection and the pathogenesis of SARS. *J Exp Med* 202(3):415–424
- Ann Yeh E, Collins A, Cohen ME, Duffner PK, Faden H (2004) Detection of coronavirus in the central nervous system of a child with acute disseminated encephalomyelitis. *Pediatrics* 113(1):e73–e76
- Verstrepen K, Baisier L, De Cauwer H (2020) Neurological manifestations of COVID-19, SARS and MERS. *Acta Neurol Belg* 120(5):1051–1060
- Desforges M, Le Coupanec A, Dubeau P, Bourgoign A, Lajoie L, Dubé M et al (2019) Human coronaviruses and other respiratory viruses: underestimated opportunistic pathogens of the central nervous system? *Viruses* 12(1):14
- Wu Y, Xu X, Chen Z, Duan J, Hashimoto K, Yang L et al (2020) Nervous system involvement after infection with COVID-19 and other coronaviruses. *Brain Behav Immun* 87:18–22
- Moore L, Ghannam M, Manousakis G (2021) A first presentation of multiple sclerosis with concurrent COVID-19 infection. *eNeurologicalSci* 22:100299
- Wingerchuk DM, Banwell B, Bennett JL, Cabre P, Carroll W, Chitnis T et al (2015) International consensus diagnostic criteria for neuromyelitis optica spectrum disorders. *Neurology* 85(2):177–189
- Zoghi A, Ramezani M, Roozbeh M, Darazam IA, Sahraian MA (2020) A case of possible atypical demyelinating event of the central nervous system following COVID-19. *Mult Scler Relat Disord*. 44:102324
- Perlman S, Zhao J (2017) Roles of regulatory T cells and IL-10 in virus-induced demyelination. *J Neuroimmunol* 15(308):6–11
- Murray RS, Cai GY, Hoel K, Zhang JY, Soike KF, Cabirac GF (1992) Coronavirus infects and causes demyelination in primate central nervous system. *Virology* 188(1):274–284
- Talbot PJ, Boucher A, Duquette P, Gruslin E (2005) Coronaviruses and neuroantigens: myelin proteins, myelin genes. In: Lavi E, Constantinescu CS (eds) *Experimental models of multiple sclerosis* [Internet]. Springer US, Boston [cited 2021 Jul 1], pp 781–791. https://doi.org/10.1007/0-387-25518-4_43
- Lima M, Siokas V, Aloizou A-M, Liampas I, Mentis A-FA, Tsouris Z et al (2020) Unraveling the possible routes of SARS-CoV-2 invasion into the central nervous system. *Curr Treat Options Neurol* 22(11):37
- Han H, Ma Q, Li C, Liu R, Zhao L, Wang W et al (2020) Profiling serum cytokines in COVID-19 patients reveals IL-6 and IL-10 are disease severity predictors. *Emerg Microbes Infect* 9(1):1123–1130
- Petkovic F, Castellano B (2016) The role of interleukin-6 in central nervous system demyelination. *Neural Regen Res* 11(12):1922
- Janssens K, Slaets H, Hellings N (2015) Immunomodulatory properties of the IL-6 cytokine family in multiple sclerosis. *Ann N Y Acad Sci* 1351:52–60
- Cao X (2020) COVID-19: immunopathology and its implications for therapy. *Nat Rev Immunol* 20(5):269–270
- Kostic M, Dzopalic T, Zivanovic S, Zivkovic N, Cvetanovic A, Stojanovic I et al (2014) IL-17 and glutamate excitotoxicity in the pathogenesis of multiple sclerosis. *Scand J Immunol* 79(3):181–186
- Matschke J, Lütgehetmann M, Hagel C, Spherhake JP, Schröder AS, Edler C et al (2020) Neuropathology of patients with COVID-19 in Germany: a post-mortem case series. *Lancet Neurol* 19(11):919–929
- Racke MK, Drew PD (2009) Toll-like receptors in multiple sclerosis. In: Kielian T (ed) *Toll-like receptors: roles in infection and neuropathology* [Internet]. Springer, Berlin [cited 2021 Jul 1], pp 155–168 (Current Topics in Microbiology and Immunology; vol 336). https://doi.org/10.1007/978-3-642-00549-7_9
- Khanmohammadi S, Rezaei N (2021) Role of Toll-like receptors in the pathogenesis of COVID-19. *J Med Virol* 93(5):2735–2739
- Kamel WA, Ibrahim Ismail I, Al-Hashel JY (2021) Guillain–Barré syndrome following COVID-19 infection: first case report from Kuwait and review of the literature. *Dubai Med J* 18:1–5
- Feldstein LR, Rose EB, Horwitz SM, Collins JP, Newhams MM, Son MBF et al (2020) Multisystem inflammatory syndrome in U.S. children and adolescents. *N Engl J Med* 383(4):334–346
- Lindan CE, Mankad K, Ram D, Kociolek LK, Silvera VM, Boddaert N et al (2021) Neuroimaging manifestations in children with SARS-CoV-2 infection: a multinational, multicentre collaborative study. *Lancet Child Adolesc Health* 5(3):167–177
- Stafstrom CE, Jantzie LL (2020) COVID-19: neurological considerations in neonates and children. *Children (Basel)* 7(9):E133
- Sotgiu S, Uzzau S, Pippia A, Carta A, Antonucci R (2021) Expanding the spectrum of acute cerebellitis due to SARS-Cov-2. *Pediatr Neurol* 121:1–2

32. Zanin L, Saraceno G, Panciani PP, Renisi G, Signorini L, Migliorati K et al (2020) SARS-CoV-2 can induce brain and spine demyelinating lesions. *Acta Neurochir* 162(7):1491–1494
33. Brun G, Hak J-F, Coze S, Kaphan E, Carvelli J, Girard N et al (2020) COVID-19—white matter and globus pallidum lesions: demyelination or small-vessel vasculitis? *Neurol Neuroimmunol Neuroinflamm* 7(4):e777
34. Alqwaifiy M (2020) Demyelinating solitary lesion of the central nervous system associated with COVID-19: a case report and literature review. *Int J Adv Med* 7(12):1884
35. Poyiadji N, Shahin G, Noujaim D, Stone M, Patel S, Griffith B (2020) COVID-19-associated acute hemorrhagic necrotizing encephalopathy: imaging features. *Radiology* 296(2):E119–E120
36. Varadan B, Shankar A, Rajakumar A, Subramanian S, Sathya AC, Hakeem AR et al (2021) Acute hemorrhagic leukoencephalitis in a COVID-19 patient—a case report with literature review. *Neuroradiology* 63(5):653–661
37. Yong MH, Chan YFZ, Liu J, Sanamandra SK, Kheok SW, Lim KC et al (2020) A rare case of acute hemorrhagic leukoencephalitis in a COVID-19 patient. *J Neurol Sci* 416:117035
38. Chalil A, Baker CS, Johnston RB, Just C, Debicki DB, Mayich MS et al (2021) Acute hemorrhagic encephalitis related to COVID-19. *Neurol Clin Pract* 11(2):e147–e151
39. Karapanayiotides T, Geka E, Prassopoulos P, Koutroulou I, Kollaras P, Kiourtzieva E et al (2020) Concentric demyelination pattern in COVID-19-associated acute haemorrhagic leukoencephalitis: a lurking catastrophe? *Brain* 143(12):e100
40. Handa R, Nanda S, Prasad A, Anand R, Zutshi D, Dass SK et al (2020) Covid-19-associated acute haemorrhagic leukoencephalomyelitis. *Neurol Sci* 41(11):3023–3026
41. Ghosh R, Dubey S, Finsterer J, Chatterjee S, Ray BK (2020) SARS-CoV-2-associated acute hemorrhagic, necrotizing encephalitis (AHNE) presenting with cognitive impairment in a 44-year-old woman without comorbidities: a case report. *Am J Case Rep [Internet]* [cited 2021 Jun 30]. <https://www.amjcaserep.com/abstract/index/idArt/925641>
42. Haqiqi A, Samuels TL, Lamb FJ, Moharrum T, Myers AE (2021) Acute haemorrhagic leukoencephalitis (Hurst disease) in severe COVID-19 infection. *Brain Behav Immun Health*. 12:100208
43. Mullaguri N, Sivakumar S, Battineni A, Anand S, Vanderwerf J (2021) COVID-19 related acute hemorrhagic necrotizing encephalitis: a report of two cases and literature review. *Cureus [Internet]* [cited 2021 Jun 30]. <https://www.cureus.com/articles/50440-covid-19-related-acute-hemorrhagic-necrotizing-encephalitis-a-report-of-two-cases-and-literature-review>
44. Radmanesh A, Derman A, Lui YW, Raz E, Loh JP, Hagiwara M et al (2020) COVID-19-associated diffuse leukoencephalopathy and microhemorrhages. *Radiology* 297(1):E223–E227
45. Sachs JR, Gibbs KW, Swor DE, Sweeney AP, Williams DW, Burdette JH et al (2020) COVID-19-associated leukoencephalopathy. *Radiology* 296(3):E184–E185
46. McLendon LA, Rao CK, Da Hora CC, Islamovic F, Galan FN (2021) Post-COVID-19 acute disseminated encephalomyelitis in a 17-month-old. *Pediatrics* 147(6):e2020049678
47. Scullen T, Keen J, Mathkour M, Dumont AS, Kahn L (2020) Coronavirus 2019 (COVID-19)-associated encephalopathies and cerebrovascular disease: the New Orleans Experience. *World Neurosurg* 141:e437–e446
48. Virhammar J, Kumlien E, Fällmar D, Frithiof R, Jackmann S, Sköld MK et al (2020) Acute necrotizing encephalopathy with SARS-CoV-2 RNA confirmed in cerebrospinal fluid. *Neurology* 95(10):445–449
49. Dixon L, Varley J, Gontsarova A, Mallon D, Tona F, Muir D et al (2020) COVID-19-related acute necrotizing encephalopathy with brain stem involvement in a patient with aplastic anemia. *Neurol Neuroimmunol Neuroinflamm* 7(5):e789
50. Montes-Ramirez J, Aquino-Lopez E (2020) COVID-19-associated diffuse leukoencephalopathy and cerebral microbleeds during puerperium. *Int J Gynecol Obstet* 151(3):466–467
51. McCuddy M, Kelkar P, Zhao Y, Wicklund D (2020) Acute demyelinating encephalomyelitis (ADEM) in COVID-19 infection: a case series. *Neurol India* 68(5):1192–1195
52. Assunção FB, Fragoso DC, Donoso Scopetta TLP, Martins Maia AC (2021) COVID-19-associated acute disseminated encephalomyelitis-like disease. *AJNR Am J Neuroradiol* 42(4):E21–E23
53. Parsons T, Banks S, Bae C, Gelber J, Alahmadi H, Tichauer M (2020) COVID-19-associated acute disseminated encephalomyelitis (ADEM). *J Neurol* 267(10):2799–2802
54. Langley L, Zeicu C, Whitton L, Pauls M (2020) Acute disseminated encephalomyelitis (ADEM) associated with COVID-19. *BMJ Case Rep* 13(12):e239597
55. Wong PF, Craik S, Newman P, Makan A, Srinivasan K, Crawford E et al (2020) Lessons of the month 1: a case of rhombencephalitis as a rare complication of acute COVID-19 infection. *Clin Med* 20(3):293–294
56. Novi G, Rossi T, Pedemonte E, Saitta L, Rolla C, Roccatagliata L et al (2020) Acute disseminated encephalomyelitis after SARS-CoV-2 infection. *Neurol Neuroimmunol Neuroinflamm* 7(5):e797
57. Demirci Otluglu G, Yener U, Demir MK, Yilmaz B (2020) Encephalomyelitis associated with Covid-19 infection: case report. *Br J Neurosurg* 7:1–3
58. Utukuri PS, Bautista A, Lignelli A, Moonis G (2020) Possible acute disseminated encephalomyelitis related to severe acute respiratory syndrome coronavirus 2 infection. *AJNR Am J Neuroradiol* 41:E82–E83
59. Lopes CCB, Brucki SMD, Passos Neto CEB, Corazza LA, Baima JPS, Fiorentino MD et al (2020) Acute disseminated encephalomyelitis in COVID-19: presentation of two cases and review of the literature. *Arq Neuro-Psiquiatr* 78(12):805–810
60. Kim HJ, Paul F, Lana-Peixoto MA, Tenenbaum S, Asgari N, Palace J et al (2015) MRI characteristics of neuromyelitis optica spectrum disorder: an international update. *Neurology* 84(11):1165–1173
61. de Ruijter NS, Kramer G, Gons RAR, Hengstman GJD (2020) Neuromyelitis optica spectrum disorder after presumed coronavirus (COVID-19) infection: a case report. *Mult Scler Relat Disord* 46:102474
62. Zhou S, Jones-Lopez EC, Soneji DJ, Azevedo CJ, Patel VR (2020) Myelin oligodendrocyte glycoprotein antibody-associated optic neuritis and myelitis in COVID-19. *J Neuroophthalmol* 40(3):398–402
63. Kogure C, Kikushima W, Fukuda Y, Hasebe Y, Takahashi T, Shibuya T et al (2021) Myelin oligodendrocyte glycoprotein antibody-associated optic neuritis in a COVID-19 patient: a case report. *Medicine* 100(19):e25865
64. Valiuddin H, Skwirsk B, Paz-Arabo P (2020) Acute transverse myelitis associated with SARS-CoV-2: a case-report. *Brain Behav Immun Health* 5:100091
65. Moreno-Escobar MC, Kataria S, Khan E, Subedi R, Tandon M, Peshwe K et al (2021) Acute transverse myelitis with dysautonomia following SARS-CoV-2 infection: a case report and review of literature. *J Neuroimmunol* 353:577523
66. Munz M, Wessendorf S, Koretsis G, Tewald F, Baegi R, Krämer S et al (2020) Acute transverse myelitis after COVID-19 pneumonia. *J Neurol* 267(8):2196–2197
67. Sarma D, Bilello L (2020) A case report of acute transverse myelitis following novel coronavirus infection. *Clin Pract Cases Emerg Med* 4(3):321–323
68. Sotoca J, Rodríguez-Álvarez Y (2020) COVID-19-associated acute necrotizing myelitis. *Neurol Neuroimmunol Neuroinflamm* 7(5):e803

69. Domingues RB, Mendes-Correa MC, de Moura Leite FBV, Sabino EC, Salarini DZ, Claro I et al (2020) First case of SARS-CoV-2 sequencing in cerebrospinal fluid of a patient with suspected demyelinating disease. *J Neurol* 267(11):3154–3156
70. AlKetbi R, AlNuaimi D, AlMulla M, AlTalal N, Samir M, Kumar N et al (2020) Acute myelitis as a neurological complication of Covid-19: a case report and MRI findings. *Radiol Case Rep* 15(9):1591–1595
71. Durrani M, Kucharski K, Smith Z, Fien S (2020) Acute transverse myelitis secondary to severe acute respiratory syndrome coronavirus 2 (SARS-CoV-2): a case report. *Clin Pract Cases Emerg Med* 4(3):344–348
72. Chow CCN, Magnussen J, Ip J, Su Y (2020) Acute transverse myelitis in COVID-19 infection. *BMJ Case Rep* 13(8):e236720
73. Kaur H, Mason JA, Bajracharya M, McGee J, Gunderson MD, Hart BL et al (2020) Transverse myelitis in a child with COVID-19. *Pediatr Neurol* 112:5–6
74. Masuccio FG, Barra M, Claudio G, Claudio S (2021) A rare case of acute motor axonal neuropathy and myelitis related to SARS-CoV-2 infection. *J Neurol* 268(7):2327–2330
75. Shahali H, Ghasemi A, Farahani RH, Nezami Asl A, Hazrati E (2021) Acute transverse myelitis after SARS-CoV-2 infection: a rare complicated case of rapid onset paraplegia. *J Neurovirol* 27(2):354–358
76. Chakraborty U, Chandra A, Ray AK, Biswas P (2020) COVID-19-associated acute transverse myelitis: a rare entity. *BMJ Case Rep* 13(8):e238668
77. Baghbanian SM, Namazi F (2020) Post COVID-19 longitudinally extensive transverse myelitis (LETM)—a case report. *Acta Neurol Belg* [Internet] [cited 2021 Jul 1]. <https://doi.org/10.1007/s13760-020-01497-x>
78. Guler MA, Keskin F, Tan H (2020) Acute myelitis secondary to COVID-19 in an adolescent: causality or coincidence? *New Trend Med Sci* 1(2):132–136
79. Fumery T, Baudar C, Ossemann M, London F (2021) Longitudinally extensive transverse myelitis following acute COVID-19 infection. *Mult Scler Relat Disord* 48:102723
80. Nejad Biglari H, Sinaei R, Pezeshki S, Khajeh HF (2021) Acute transverse myelitis of childhood due to novel coronavirus disease 2019: The first pediatric case report and review of literature. *Iran J Child Neurol* 15(1):107–112
81. Ali L, Khan A, Elalamy O, Canibano B, Al hatou M, Adeli G, Ahmed I, Iqar A, Abdussalam A, Ibrahim AS, Sardar S (2020) A rare presentation of acute flaccid myelitis in COVID-19 patient: a case report. *Pak J Neurol Sci (PJNS)* 15(3), Article 5
82. Román GC, Gracia F, Torres A, Palacios A, Gracia K, Harris D (2021) Acute transverse myelitis (ATM): clinical review of 43 patients with COVID-19-associated ATM and 3 post-vaccination ATM serious adverse events with the ChAdOx1 nCoV-19 vaccine (AZD1222). *Front Immunol* 12:653786
83. Saberi A, Ghayeghran A, Hatamian H et al (2020) COVID-19-associated myelitis, para/post infectious or infectious myelitis: a case report from the north of Iran. *Caspian J Neurol Sci.* 6(2):132–138