

## IBD LIVE Case Series—Case 2: Previous Cancer in a Patient with Crohn's Disease: Is It Appropriate to Use Biologics and Immunosuppressants for IBD Treatment?

Peter N. Le, MD,\* Julia B. Greer, MD, MPH,<sup>†</sup> Ioannis Oikonomou, MD,<sup>‡</sup> Wolfgang H. Schraut, MD,<sup>§</sup> Corey A. Siegel, MD,<sup>||</sup> Raymond K. Cross, MD, MS,<sup>¶</sup> Stefan D. Holubar, MD, MS,<sup>\*\*</sup> Andrew Tinsley, MD,<sup>††</sup> Walter A. Koltun, MD,<sup>‡‡</sup> David G. Binion, MD,<sup>†</sup> and Miguel D. Regueiro, MD<sup>†</sup>

### PRESENTATION

Dr. Peter N. Le: Clinical Fellow, III, 2013 to 2014, Yale University School of Medicine, Section of Digestive Diseases.

The patient is a 58-year-old woman with a 33-year history of Crohn's disease and 2 prior cancers who presents to Yale University for management of her inflammatory bowel disease (IBD).

She was diagnosed with Crohn's disease in 1980 after undergoing a small bowel follow-through. Her family history of IBD was negative. Her medical and surgical histories are remarkable for stage I infiltrating lobular breast carcinoma diagnosed in 2004 for which she underwent bilateral mastectomy and breast reconstruction. Her tumor was estrogen and progesterone receptor-positive, and she received adjuvant hormonal therapy.

For her Crohn's ileocolitis, she has been treated intermittently with short courses of systemic steroids, antibiotics, and

mesalamine. In 2006, she underwent a colonoscopy that demonstrated a proximal colonic stricture that was described as being "pinhole opening" with ulcerations. Random biopsies taken at the stricture site and throughout the colon were negative for dysplasia but revealed chronic active colitis with noncaseating granulomas.

In 2007, imaging suggested a subclinical small bowel obstruction. The patient was referred to a surgeon but decided against stricturoplasty or resection. Between 2008 and 2009, she developed refractory anemia and was referred to the Hematology/Oncology service where she underwent a comprehensive workup that was unremarkable for a hematologic malignancy. Repeat esophagogastroduodenoscopy and colonoscopy in 2009 again demonstrated a smooth-walled stricture at the proximal colon similar in appearance to the pinhole narrowing noted in 2006. Her upper gastrointestinal (GI) tract was negative for Crohn's disease, dysplasia, or an active bleed.

Between 2009 and 2010, the patient describes having more frequent and severe postprandial epigastric pain, nausea, bloating, and nonbloody loose bowel movements. A small bowel series demonstrated that she had 2 jejunal strictures and a 16 to 20 cm long stricture of the ileum. The patient was referred to colorectal surgery and, in June of 2010, she underwent resection of 2 jejunal strictures and an ileocecectomy. At surgery, a large mass was seen at the proximal jejunum that had bulky adenopathy that reached to the base of the mesentery. The tumor was lobulated and circumferential with serosal umbilication causing stricture at the proximal jejunum. The surgeon noted enlarged lymph nodes extending to the aorta and to the perisuperior mesenteric artery chain; some of these lymph nodes could not be resected. Pathology of the mass indicated that it was invasive adenocarcinoma measuring 7.0 × 5.5 × 1.3 cm. Initially, the tumor was staged as IIIB but was upstaged to stage IV after a chest computed tomography (CT) was positive for thoracic lymph nodes.

The patient was referred to the Yale University Oncology Service where it was recommended that she be treated with 12 cycles of FOLFOX (Folinic Acid Fluorouracil Oxaliplatin). After treatment, her serum tumor markers normalized. From April 2011 until today, serial positron emission tomography (PET)/CT scans have not demonstrated any signs of cancer recurrence.

Now, she presents to the Yale University Digestive Disease service. She has never been treated with immunomodulators or biologics. She complains of progressively worse postprandial

Received for publication February 2, 2015; Accepted March 10, 2015.

From the \*South Denver Gastroenterology, Lone Tree, Colorado; <sup>†</sup>Division of Gastroenterology, Hepatology and Nutrition, Department of Medicine, University of Pittsburgh School of Medicine, Pittsburgh, Pennsylvania; <sup>‡</sup>Section of Digestive Diseases, Department of Internal Medicine, Yale School of Medicine, New Haven, Connecticut; <sup>§</sup>Division of Surgical Oncology, Department of Surgery, University of Pittsburgh School of Medicine, Pittsburgh, Pennsylvania; <sup>||</sup>Section of Gastroenterology and Hepatology, Department of Medicine, Dartmouth-Hitchcock Medical Center, Lebanon, New Hampshire; <sup>¶</sup>Department of Medicine, Division of Gastroenterology and Hepatology, University of Maryland Medical Center, Baltimore, Maryland; <sup>\*\*</sup>Division of Colon and Rectal Surgery, Department of Surgery, Dartmouth-Hitchcock Medical Center, Lebanon, New Hampshire; <sup>††</sup>Division of Gastroenterology and Hepatology, Department of Medicine, Penn State Milton S. Hershey Medical Center, Hershey, Pennsylvania; and <sup>‡‡</sup>Division of Colon and Rectal Surgery, Department of Surgery, Penn State Milton S. Hershey Medical Center, Hershey, Pennsylvania.

J. B. Greer currently holds a grant with Abbvie. I. Oikonomou has past research grants with Janssen Pharmaceutica, Pfizer, and Celgene. C. A. Siegel currently consults for Janssen Pharmaceutica, Abbvie, and UCB, and has ongoing research grants with Janssen Pharmaceutica, Abbvie, and UCB. R. K. Cross consults, participates in advisory boards, and has research grant support with Abbvie and Janssen Pharmaceutica; Dr. Cross also participates in Takeda's advisory board. A. Tinsley has previously consulted for Janssen Pharmaceutica and is involved in ongoing consulting and lecturing for Abbvie. D. G. Binion has an ongoing grant with Janssen Pharmaceutica and has previously consulted for Abbvie, Janssen Pharmaceutica, Cubist Pharmaceuticals, Salix Pharmaceuticals, and Takeda. M. D. Regueiro has previously consulted for UCB, Takeda, Shire Plc, Abbvie, and Janssen Pharmaceutica.

Reprints: Julia B. Greer, MD, MPH, Division of Gastroenterology, Hepatology and Nutrition, Department of Medicine, University of Pittsburgh School of Medicine, Medical Arts Building, 3708 5th Avenue, Office 401.3, Pittsburgh, PA 15213 (e-mail: greerjb@upmc.edu).

Copyright © 2015 Crohn's & Colitis Foundation of America, Inc.

DOI 10.1097/MIB.0000000000000435

Published online 4 May 2015.

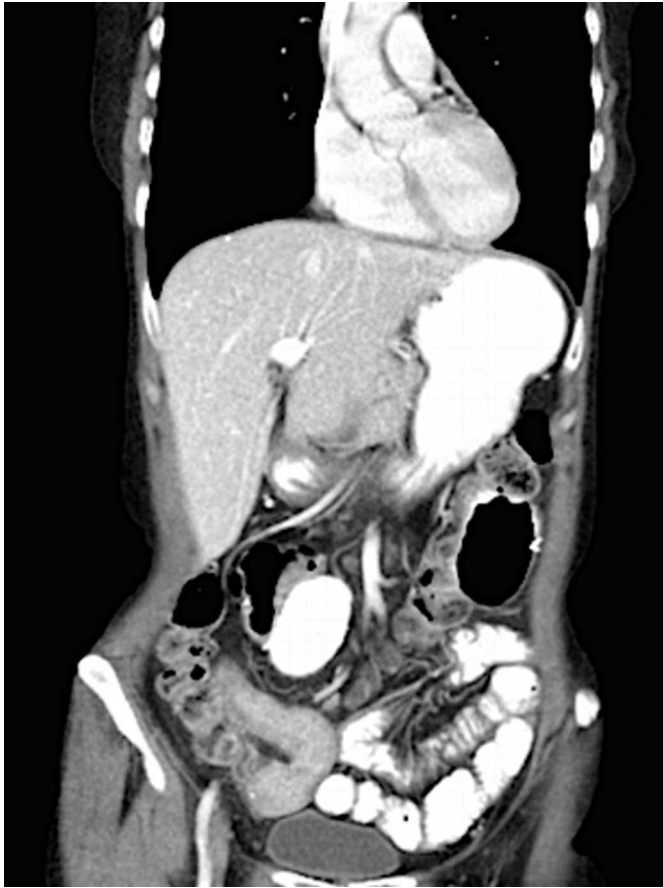

FIGURE 1. A representative photograph of a recent contrast-enhanced CT of the abdomen and pelvis. The distal small bowel demonstrates a significant amount of stricturing and some intestinal thickening.

epigastric discomfort, bloating, weight loss, and intermittent nausea but denies any vomiting. Her most recent CT scan in September of 2013 demonstrates a new distal ileum stricture with neoterminal ileum thickening and adjacent fat stranding (Fig. 1). A colonoscopy shows active Crohn's disease with stenosis in the distal ileum (Fig. 2).

In summary, this is a 58-year-old woman with a history of breast cancer in 2004, status after bilateral mastectomy and adjuvant antiestrogen therapy, with long-standing enterocolonic Crohn's disease complicated by small bowel strictures. In 2010, she underwent stricture resection with the discovery of stage IV jejunal adenocarcinoma that is currently in remission after treatment with adjuvant chemotherapy. She currently has evidence of an ileal stricture and active inflammation.

## CASE DISCUSSION

### Dr. Miguel D. Regueiro

This case is quite challenging. Her breast cancer was an early stage tumor that was treated and currently is in remission. We should assume that the jejunal adenocarcinoma was a primary adenocarcinoma of the small bowel secondary to Crohn's disease rather than

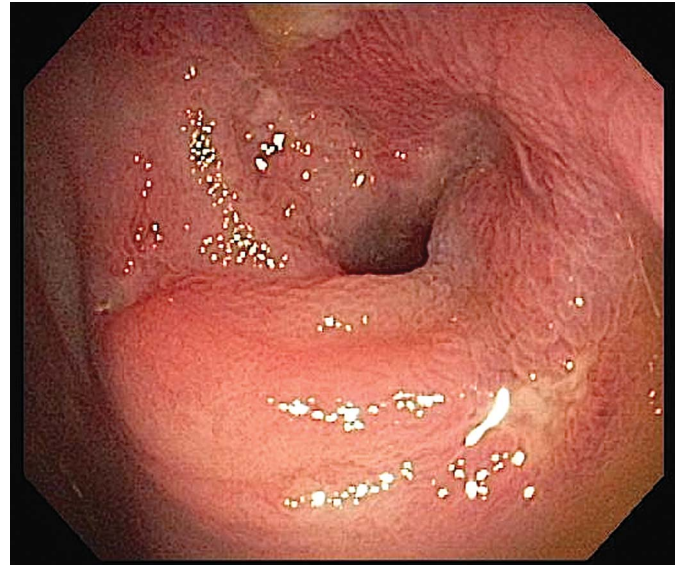


FIGURE 2. Photograph of distal ileum with narrow lumen from colonoscopy performed in October of 2013. Pathology taken from this area was negative for malignancy or dysplasia but was positive for chronic active inflammation.

breast cancer metastasis. She's never received immunosuppressive therapy, and she now has a Crohn's recurrence and stenosis at the ileocolonic anastomosis. Her symptoms are consistent with a partial small bowel obstruction. The important questions are (1) can we treat, and potentially reverse, this process with medication or is surgery required? and (2) if we choose medication, is anyone concerned about using immunosuppressive treatment given her cancer history? I'd like to ask our surgeon for his opinion. Dr. Wolfgang Schraut, looking at the CT scan, what do you think? Is this patient destined to have another surgery or could we try medication first?

### Dr. Wolfgang H. Schraut

Given this woman's history and what I can see on that recent CT scan, I certainly don't think that we should wait another 9 years to do an operation. I would proceed with resection. However, I would not discount the possibility that she has metastatic disease at the current time, perhaps even in a different area than her original adenocarcinoma. Given her high risk of recurrence, she will not respond to anything else but a resection, realizing that she will have another segment of intestine removed.

### Dr. Miguel D. Regueiro

Ah, spoken like a true surgeon, Dr. Schraut is recommending that the patient has a surgical resection and not even consider medication. Let's turn to our gastroenterology colleagues. How safe are IBD meds, specifically anti-tumor necrosis factor alpha agents (anti-TNFs) and immunosuppressants, in a patient with a history of cancer? Corey, you've done considerable research in the area of malignancy risk with IBD medications. What are your thoughts on treatment in this specific case as well as treatment of IBD in the setting of an active or prior cancer?

## Dr. Corey A. Siegel

This case represents an unfortunate situation that we often experience. Sometimes our patients get cancer and, when they have completed treatment, we have to determine how we should best manage their IBD. Let me give a quick summary on my thoughts about using our immunosuppressant drugs in the setting of a history of cancer or a recurrence of cancer, which might be true for this case. Then, I'll make a comment on what I would do in her case specifically.

To date, there is no compelling evidence that anti-TNF monotherapy plays a role in solid tumor development. Our group evaluated this relationship in a study that was recently published in the journal *Inflammatory Bowel Diseases*. We looked across all disease states and all indications for anti-TNFs and immune modulators, and we did not find any indication that anti-TNF monotherapy is associated with the development or the occurrence or recurrence of solid tumors. There was a similar type of study conducted by the CESAME national French cohort, which looked at recurrent types of cancer that patients with IBD developed after being treated for an initial cancer. The interesting thing in the CESAME study was that some patients did get cancers after treatment for their bowel disease, but they often got a different type of cancer from their original tumor, which is similar to the woman whom we are discussing today who may be predisposed to cancer. In this recent CESAME study, the risk of getting new or recurrent cancer was not found to be linked to treatment with immunosuppressants.

I don't know if anything we do for this patient is either going to prevent her cancer or stimulate it further. I'm not at all convinced that she's cured of this cancer. However, we need to deal with her GI disease because, just as it may be inevitable that her cancer is going to come back, it's also inevitable that her Crohn's will be a problem for her. Although I agree that her distal ileal stricture will not be "fixed" by medication therapy, the patient has had diffuse aggressive small bowel Crohn's disease and she will need treatment. Assuming that she survives long enough from her cancer, which we certainly hope that she does, she is going to experience a huge quality of life problem if she undergoes 1 or more surgery to resect her small bowel. The ambiguity here is that we don't know what is going to happen with her cancer. But whether her long-term survival is less than 5 years or much longer, we have to do something to treat her Crohn's or things are only going to get worse in regards to her bowel disease.

In a recent study, Osterman et al evaluated cancer risk across all adalimumab Crohn's disease trials. They looked at the rates of cancer development across all of the studies in patients with Crohn's disease treated with single agent adalimumab, and they compared them with cancer rates in patients with Crohn's disease treated with a combination of adalimumab and an immunomodulator. For the first time, an increased risk of solid tumors was noted among patients on combination therapy. However, their analysis was based on solid tumors as an aggregate, meaning that they did not examine the risk of adenocarcinoma of the thyroid, breast, or colon separately. Their results showed that

adalimumab monotherapy did not increase the risk of solid tumors but there was a concerning signal that patients who received treatment with combination therapy did have a higher rate of developing a solid tumor compared with patients who were treated only with adalimumab.

Based on all of this, for this patient, I would use anti-TNF monotherapy. Anti-TNF monotherapy will help her to maintain a good quality of life while she deals with these other issues going forward. Now I'd like to see if one of our colorectal surgeons, Stefan Holubar, wants to share any additional comments that he may have on this topic.

## Dr. Stefan D. Holubar

First off, I feel that it's imperative to know about the status of her adenocarcinoma. When exactly was the most recent PET/CT done and which tumor markers were followed? Given the overall poor prognosis of small bowel adenocarcinoma, I'd want to know whether she is truly in a remission. Clearly, she needs an operation for her symptomatic stricture, perhaps in the setting of a diagnostic laparoscopy to assess for cancer recurrence. However, there are almost always alternatives worth considering, and it's our ethical obligation to examine alternatives to surgery. The literature on small bowel stenting is limited, but a colleague from residency, Dr. Rebecca Levine, reported a small case series at the Ferguson Clinic of Crohn's patients with strictures who were managed with endoluminal stenting with self-expanding metal stents and had a good long-term success rate. Subsequent case series have suggested similar results. This patient had advanced small bowel adenocarcinoma with metastases to the para-aortic lymph nodes, so she most likely will not have great long-term survival. Perhaps palliating any symptoms, she may have with a self-extending metal stent or any other biodegradable stent might be an alternative treatment. The main risk of the stent is perforation that, if the patient were on a palliative pathway, would be a life-shortening event. However, I would only consider this option if her current circumstances dictate that her priority is palliative care.

## Dr. Wolfgang H. Schraut

The longest stent is 15 cm long. I'm concerned that it would not be long enough.

## Dr. Stefan D. Holubar

I certainly think that they could put in multiple stents and bridge this 15 cm stricture. Additionally, there are new stents coming on line from Korea that may offer improvements over our current options. I'm not suggesting that this is the ultimate therapy for her but I do believe that it's an alternative that should be considered by her team if she is already metastatic. Otherwise, I agree that surgical exploration is the next step. The other major alternative to consider is a stricturoplasty but, given her prior cancers, I would be reticent to leave the 15 cm long segment in situ indefinitely over concern for a metachronous small bowel cancer.

## Dr. Miguel D. Regueiro

Dr. Ray Cross, how would you or another colleague at Maryland manage this case?

### Dr. Raymond K. Cross

I agree with what Corey said but there are some additional things that I would consider. Some of the symptoms of post-surgical patients may be from small intestinal bacterial overgrowth or choleric diarrhea. I'm sure that her pain and obstructive symptoms are not due to those entities but there may be other mechanisms at play contributing to her GI symptoms. Given her overall poor prognosis, if she responds to budesonide, I would consider continuing the budesonide to keep her well; I might even give it at higher doses. Although it was called a long stricture on imaging, endoscopically, it looked like the ileocolonic stricture was fairly short. We talked about dilation and stents but perhaps we could do periodic stricture dilations; you can dilate more than 1 stricture at a time, especially if they're segmental. I realize that this method would not offer a durable solution, but performing repeated endoscopies to dilate these strictures is a reasonable way to help alleviate some of her symptoms. I agree with Corey that although there is no association between anti-TNF monotherapy and solid tumors, you would prefer to try to get this patient out farther from her malignancy before starting anti-TNF therapy. Having said that, I think she's going to need to escalate therapy in the near future. I would have no problem using an anti-TNF agent. However, if you have reservations about anti-TNFs, you might consider using methotrexate because it is less immunosuppressive and is one of the safest drugs that we have. She's not childbearing age so methotrexate would be a reasonable start.

### Dr. Miguel D. Regueiro

Peter and Yanni, please correct me if I'm wrong. To Ray's point about dilating this stricture, you probably saw the tip of the stricture, meaning that you got to the area of the anastomosis. Were you able to traverse it?

### Dr. Ioannis (Yanni) Oikonomou

We were not able to traverse it. In addition, on the CT scan, there was a long segment of thickening and inflammation above the area of the stricture. Overall, it seems to me that there is a short segment of stricture and proximal to that is a long segment of neoterminal ileal inflammation.

### Dr. Miguel D. Regueiro

From a medical and surgical standpoint, I'd like to ask our clinicians at Hershey Medical Center what they might do for this patient.

### Dr. Andrew Tinsley

A lot of good points have been raised. When we see these patients, we like to know what type of cancer the patient has, its stage, and if it has been adequately controlled. These types of small bowel cancers in the setting of long-standing Crohn's disease, as was mentioned, have a very poor prognosis—stage for stage, they're considerably worse than colon cancer. It's great that she's 2 years out but there's a high chance that the cancer is going to

come back and that ultimately she will succumb to it. Therefore, I'd like to buy her more time. She may end up needing surgery but I think budesonide is reasonable. I also like the idea of using methotrexate. Although the data is somewhat reassuring that there is not a clear risk, I'm hesitant to introduce an anti-TNF in the setting of what might still be an active cancer. I would like to give her the best chance of avoiding a recurrence, and I'm not completely comfortable with having her initiate a biologic anti-TNF.

The only other thought that I have is that we could consider using vedolizumab. Although we do not have long-term data about vedolizumab, this agent might be reasonable. Given its specific mechanism of action, I would not expect it to be associated with increased cancer risk.

### Dr. Walter A. Koltun

I agree with Dr. Schraut but I have a question. Has a PET/CT scan been performed recently to stage possible recurrence of her small bowel adenocarcinoma?

### Dr. Peter N. Le

A PET/CT scan has been done, and there has been no sign of recurrence. Her most recent scan was in the September of the last year, approximately 4 months ago.

### Dr. Walter A. Koltun

Thank you. I still agree with Dr. Schraut that the most effective treatment for this patient would be surgical resection.

### Dr. David G. Binion

This patient has had a 3 decade experience with Crohn's disease and a mid small bowel lesion, which was left behind for quite some time. We don't normally think that the most likely diagnosis of small bowel Crohn's disease with obstructive symptoms as being a small bowel adenocarcinoma. However, this is the exact scenario in which it presents, which is in the rare person with small bowel disease that does not get resected fairly early in his or her disease course. There are some relevant articles in the literature including a recently published French study that characterized small bowel adenocarcinoma in Crohn's disease and found it to occur in a clinical setting just like what we're discussing for today's patient. So, historically, patients go to the operating room due to obstructive complications for Crohn's, which probably provides them an additional long-term benefit of removing areas of damage that would be at risk for developing dysplasia and cancer. When we talk to patients about surgery, we should tell them that removing a damaged segment that may have been inflamed for 2 or 3 decades may help to prevent a more serious complication from developing. Doing a primary stricturoplasty is probably not the right answer for patients with long-standing areas of damage. In terms of what this patient is experiencing, I'm highly suspicious that carcinomatosis is contributing to her symptoms. There clearly is inflammation on the imaging but I am more concerned that what she is suffering from is actually metastatic complications of her previous stage IV adenocarcinoma in the small bowel.

## Dr. Miguel D. Regueiro

Peter and Gianni, you have just heard completely different viewpoints and opinions about this case. Although I don't know if there is necessarily a single correct answer for how to manage your patient, I'll take the chair prerogative and end with my thoughts. Looking at the CT scan, I agree with both surgeons that I'm not sure if that area will recover. I'm of similar opinion with the other points that were made about possible residual cancer even in the face of negative PET/CTs. The way that I look at it is that if her obstructive symptoms are significant, I would talk to her about surgery. Undergoing surgery could also simultaneously confirm that she does not have carcinomatosis, which would impact all of her future treatment decisions. If her obstructive symptoms were mild or minimal, I would probably bite the bullet and give her 6 months of fairly aggressive treatment with a very frank discussion about the fact that she may have an adenocarcinoma right now. To that end, I would probably give an anti-TNF with methotrexate. I know that some of the previous studies have examined thiopurines but I would probably use methotrexate at a lower dose in combination with an anti-TNF agent. I would give her 6 months on this regimen, restage her, and at that point decide which direction to take. The downside to that is that if you're missing an adenocarcinoma, could it potentially worsen? Yes. At the same time, I think that her Crohn's, like Corey said, is going to be aggressive for the remainder of her life. So, I think it depends on the degree of obstruction whether you go to surgery first or whether you go to combination therapy first. If you go to surgery first, I would use aggressive treatment postoperatively if she does not have a cancer. To my point, I would use an anti-TNF, and if you were worried about immunogenicity, I'd give her methotrexate.

## DISCUSSION

Constituting fewer than 2 percent of all the malignant tumors of the GI tract, small intestinal adenocarcinoma (SBA) is a very rare form of neoplasia.<sup>1</sup> According to the American Joint Committee on Cancer Manual of 2010 (Seventh Edition), the 5-year survival rate of SBA is 5%.<sup>2</sup>

Although the cancer most frequently encountered in patients with IBD is colon cancer, recent work has noted standardized incidence or mortality ratios of SBA in patients with Crohn's disease to be as much as 40- to 46-fold higher than expected.<sup>3,4</sup> Case reports and small series of Crohn's patients have noted that SBA can develop within a stricture or stricturoplasty site, especially when the patient has long-standing disease and has been treated with medical therapy rather than surgery.<sup>5-8</sup> Additional factors that have been associated with SBA among patients with Crohn's disease include prolonged treatment with salicylates, longer duration of disease, fistulas, surgically excluded loops of small bowel (after jejunal or ileal bypass), and the use of immunosuppressive medications.<sup>3,9-16</sup> A study published almost 40 years ago in *Archives of Surgery* compared SBA in Crohn's disease with SBA not associated with Crohn's disease and noted that those associated with Crohn's (1)

occurred more frequently, (2) were discovered at a younger mean age (46 versus 64 yr), (3) were more likely to occur in the ileum, and (4) were less successfully diagnosed and cured.<sup>17</sup>

Symptoms of SBA include anemia, nausea, cramping abdominal pain, weight loss, and blood in the stool. Because many of these presenting features mimic a flare of active or obstructing Crohn's disease, a delay in diagnosis and treatment may occur, which may partly explain their later stage at diagnosis compared with other individuals who develop this malignancy.<sup>9,18,19</sup>

Patient risks and benefits must be evaluated when choosing treatment for IBD. It is well known that the use of immunosuppressants after organ transplant is associated with elevated rates of malignancy.<sup>20</sup> In addition to their direct oncogenic effects, immunosuppressant medications decrease immunosurveillance of both oncogenic viruses and emerging cancers.<sup>20,21</sup> Anti-TNFs and immunomodulators have been associated with some forms of skin cancer and lymphoma, especially when both agents are used synchronously.<sup>21-23</sup> Three recent European studies also observed that thiopurine use in IBD might be associated with an increased overall risk of malignancy.<sup>24-26</sup> In addition to experiencing a cancer recurrence, individuals with a history of cancer have a slightly elevated risk of developing a second cancer.<sup>27</sup> Although the overall cancer risk associated with immunosuppressant medications is very low, an individual who has been diagnosed and treated for cancer has often been through a traumatic life-altering experience. Fears of developing a recurrence or a second cancer may interfere with selecting the most disease-effective treatment whether it's surgery or a highly therapeutic IBD medication.

Combination therapy with an anti-TNF agent and an immunomodulator has been shown to be superior to treatment with either agent alone in achieving corticosteroid-free clinical remission; additionally, induction therapy with an anti-TNF is more effective when a thiopurine is added to the regimen.<sup>21,28,29</sup> Among the 17,047 patients of the French Cancers Et Surrisque Associé aux Maladies Inflammatoires Intestinales En France (CESAME) prospective observational cohort study, 405 individuals were diagnosed with cancer before study inception and 23 cases of incident cancer occurred during the 2.25- to 3.5-year study duration. One Crohn's patient who was diagnosed with small bowel cancer older than 21 years before study entry developed another small bowel cancer during the short study. This patient was not receiving immunosuppressants before or during the study. In sum, neither new nor recurrent cancers were associated with the use of immunosuppressants in this large-scale study.<sup>30</sup>

In reference to the patient who was just presented, a previous experience with breast cancer and a possible gynecologic malignancy may have caused her to be overly cautious when selecting medication and made her reluctant to undergo surgery. Early in her disease course, strictures were noted in her small bowel but they were not surgically removed. Recent work has shown that strictures that appear to be more active on imaging demonstrate prominent signs of inflammation on histology that contributes to their potential for dysplastic transformation.<sup>31</sup>

## EDITOR'S COMMENTS

Management options for this patient are not mutually exclusive. Surgery to remove the strictured and inflamed segment of distal small bowel would be the most aggressive option and would simultaneously evaluate recurrent cancer. However, more surgery is not without risk, and this patient could develop short gut syndrome. In patients with active IBD and a history of solid tumors, such as adenocarcinoma, consultation with the oncologist is advised. Generally, patients who have been cancer-free for at least 1 year may be considered for biologic and/or immunomodulator treatment.<sup>32</sup> There is a paucity of data in this area, and each case is individualized, but the risk of cancer recurrence is probably low. Most gastroenterologists do not stent Crohn's disease strictures. However, dilation using biodegradable or self-expanding metal stents has been shown to be effective for controlling obstructive symptoms in patients with CD with strictures of the colon and the ileocolonic anastomosis. Stent migration and complications requiring surgery can occur.<sup>33–35</sup> A recent single institution review of all patients with Crohn's disease undergoing endoluminal stenting for anastomotic strictures between 2001 and 2010 achieved 100% technical and 80% clinical success with a mean long-term luminal patency of 34.8 months and only 1 complication requiring surgery.<sup>36</sup> In conclusion, IBD medications may be given to patients with prior cancer. This decision should be made as part of a multidisciplinary discussion between the patient, gastroenterologist, surgeon, and oncologist.

## REFERENCES

1. *What Are the Risk Factors for Small Intestine Cancer? Small Intestine Cancer. Causes, Risk Factors, and Prevention Topics.* American Cancer Society. Available at: <http://www.cancer.org/cancer/smallintestinecancer/detailedguide/small-intestine-2cancer-risk-factors>. Accessed May 8, 2014.
2. Small intestine. In: Edge SB, Byrd DR, Compton CC, et al, eds. *AJCC Cancer Staging Manual (7th Ed)*. New York, NY: Springer; 2010:127–132.
3. Elriz K, Carrat F, Carbone F, et al; Cesame Study Group. Incidence, presentation, and prognosis of small bowel adenocarcinoma in patients with small bowel Crohn's disease: a prospective observational study. *Inflamm Bowel Dis*. 2013;19:1823–1826.
4. Jess T, Loftus EV Jr, Harmsen WS, et al. Survival and cause specific mortality in patients with inflammatory bowel disease: a long term outcome study in Olmsted County, Minnesota, 1940–2004. *Gut*. 2006;55:1248–1254.
5. Ellamushi HE, Smith IS. Small bowel adenocarcinoma complicating Crohn's disease. *Scott Med J*. 1992;37:54–55.
6. Beaugerie L, Svrcek M, Seksik P, et al. Risk of colorectal high-grade dysplasia and cancer in a prospective observational cohort of patients with inflammatory bowel disease. *Gastroenterology*. 2013;145:166–175.e8.
7. Partridge SK, et al; Partridge SK, Hodin RA. Small bowel adenocarcinoma at a strictureplasty site in a patient with Crohn's disease: report of a case. *Dis Colon Rectum*. 2004;47:778–781.
8. Balaji V, Thompson MR, Marley NJ, et al. Occult small bowel adenocarcinoma in a Crohn's stricture. *J R Soc Med*. 1997;90:45.
9. Solem CA, Harmsen WS, Zinsmeister AR, et al. Small intestinal adenocarcinoma in Crohn's disease: a case-control study. *Inflamm Bowel Dis*. 2004;10:32–35.
10. Piton G, Cosnes J, Monnet E, et al. Risk factors associated with small bowel adenocarcinoma in Crohn's disease: a case-control study. *Am J Gastroenterol*. 2008;103:1730–1736.
11. Ribeiro MB, Greenstein AJ, Heimann TM, et al. Adenocarcinoma of the small intestine in Crohn's disease. *Surg Gynecol Obstet*. 1991;173:343–349.
12. Michelassi F, Testa G, Pomidor WJ, et al. Adenocarcinoma complicating Crohn's disease. *Dis Colon Rectum*. 1993;36:654–661.
13. Lashner BA. Risk factor for small bowel cancer in Crohn's disease. *Dig Dis Sci*. 1992;37:1179–1184.
14. Greenstein AJ, Sachar D, Pucillo A, et al. Cancer in Crohn's disease after diversionary surgery. A report of seven carcinomas occurring in excluded bowel. *Am J Surg*. 1978;135:86–90.
15. Valdes-Dapena A, Rudolph I, Hidayat A, et al. Adenocarcinoma of the small bowel in association with regional enteritis. Four new cases. *Cancer*. 1976;37:2938–2947.
16. Lightdale CJ, Sternberg SS, Posner G, et al. Carcinoma complicating Crohn's disease. Report of seven cases and review of the literature. *Am J Med*. 1975;59:262–268.
17. Hoffman JP, Taft DA, Wheelis RF, et al. Adenocarcinoma in regional enteritis of the small intestine. *Arch Surg*. 1977;112:606–611.
18. Feldstein RC, Sood S, Katz S. Small bowel adenocarcinoma in Crohn's disease. *Inflamm Bowel Dis*. 2008;14:1154–1157.
19. Fresko D, Lazarus SS, Dotan J, et al. Early presentation of carcinoma of the small bowel in Crohn's disease ("Crohn's carcinoma"). Case reports and review of the literature. *Gastroenterology*. 1982;82:783–789.
20. Gutierrez-Dalmau A, Campistol JM. Immunosuppressive therapy and malignancy in organ transplant recipients: a systematic review. *Drugs*. 2007;67:1167–1198.
21. Mason M, Siegel CA. Do inflammatory bowel disease therapies cause cancer? *Inflamm Bowel Dis*. 2013;19:1306–1321.
22. Peyrin-Biroulet L, Khosrotehrani K, Carrat F, et al. Increased risk for nonmelanoma skin cancers in patients who receive thiopurines for inflammatory bowel disease. *Gastroenterology*. 2011;141:1621–1628.e1–e5.
23. Biancone L, Calabrese E, Petruzzello C, et al. Treatment with biologic therapies and the risk of cancer in patients with IBD. *Nat Clin Pract Gastroenterol Hepatol*. 2007;4:78–91.
24. Beaugerie L, Brousse N, Bouvier AM, et al. Lymphoproliferative disorders in patients receiving thiopurines for inflammatory bowel disease: a prospective observational cohort study. *Lancet*. 2009;374:1617–1625.
25. Camus M, Seksik P, Bourrier A, et al. Long-term outcome of patients with Crohn's disease who respond to azathioprine. *Clin Gastro Hepatol*. 2013;11:389–394.
26. Pasternak B, Svanstrom H, Schmiegelow K, et al. Use of azathioprine and the risk of cancer in inflammatory bowel disease. *Am J Epidemiol*. 2013;177:1296–1305.
27. Curtis RE, Freedman M, Ron E, et al. *New Malignancies Among Cancer Survivors: SEER Cancer Registries, 1993–2000*. Bethesda, MD: National Cancer Institute, NIH Publ. No. 05-5302; 2006.
28. Bressler B, Siegel CA. Beware of the swinging pendulum: anti-tumor necrosis factor monotherapy vs combination therapy for inflammatory bowel disease. *Gastroenterology*. 2014;146:884–887.
29. Panaccione R, Ghosh S, Middleton S, et al. Combination therapy with infliximab and azathioprine is superior to monotherapy with either agent in ulcerative colitis. *Gastroenterology*. 2014;146:392–400.e3.
30. Beaugerie L, Carrat F, Colombel J-F, et al. Risk of new or recurrent cancer under immunosuppressive therapy in patients with IBD and previous cancer. *Gut*. 2014;63:1416–1423.
31. Adler J, Punglia DR, Dillman JR, et al. Computed tomography enterography findings correlate with tissue inflammation, not fibrosis in resected small bowel Crohn's disease. *Inflamm Bowel Dis*. 2013;18:849–856.
32. Swoger JM, Regueiro M. Stopping, continuing, or restarting immunomodulators and biologics when an infection or malignancy develops. *Inflamm Bowel Dis*. 2014;20:926–935.
33. Branche J, Attar A, Vernier-Massouille G, et al. Extractible self-expandable metal stent in the treatment of Crohn's disease anastomotic strictures. *Endoscopy*. 2012;44(suppl 2 UCTN):E325–E326.
34. Saritas U, Ustundag Y. Biodegradable stents: another big step in the field of non-surgical therapy for fibrostenotic Crohn's disease. *Endoscopy*. 2012;44:435; author reply 6.
35. Attar A, Maunoury V, Vahedi K, et al. Safety and efficacy of extractible self-expandable metal stents in the treatment of Crohn's disease intestinal strictures: a prospective pilot study. *Inflamm Bowel Dis*. 2012;18:1849–1854.
36. Levine RA, Wasvary H, Kadro O. Endoprosthetic management of refractory ileocolonic anastomotic strictures after resection for Crohn's disease: report of nine-year follow-up and review of the literature. *Inflamm Bowel Dis*. 2012;18:506–512.