



# Shoulder arthroplasty in patients with glenohumeral osteoarthritis, glenoid bone loss and an intact rotator cuff: an algorithmic approach and review of the literature

Andrew B. Harris<sup>1</sup>^, Filippo Familiari<sup>2</sup>, Raffaella Russo<sup>2</sup>, Piotr Lukasiewicz<sup>1</sup>, Edward G. McFarland<sup>1</sup>

<sup>1</sup>Department of Orthopaedic Surgery, The Johns Hopkins University, Baltimore, MD, USA; <sup>2</sup>Department of Orthopaedic and Trauma Surgery, Magna Graecia University of Catanzaro, Catanzaro, Italy

**Contributions:** (I) Conception and design: All authors; (II) Administrative support: AB Harris, F Familiari, P Lukasiewicz, EG McFarland; (III) Provision of study materials or patients: AB Harris, EG McFarland; (IV) Collection and assembly of data: AB Harris, F Familiari, P Lukasiewicz, EG McFarland; (V) Data analysis and interpretation: AB Harris, P Lukasiewicz, EG McFarland; (VI) Manuscript writing: All authors; (VII) Final approval of manuscript: All authors.

**Correspondence to:** Edward McFarland, MD. Department of Orthopaedic Surgery, The Johns Hopkins University, 2360 West Joppa Road, Suite 306, Lutherville, MD 21093, USA. Email: emcfarl1@jhmi.edu.

**Abstract:** In patients with severe glenohumeral osteoarthritis (OA) and preserved rotator cuff function who have failed nonoperative treatment, anatomic total shoulder arthroplasty (TSA) has historically been the preferred surgical treatment. Shoulder arthroplasty in the setting of glenoid bone loss setting is technically demanding. Many techniques have been described to deal with glenoid bone loss including eccentric reaming, bone grafting, augmented glenoid baseplates, and patient-specific implants. Still, the decision to perform anatomic TSA or reverse total shoulder arthroplasty (RTSA) is often unclear, especially as the use of RTSA increases and evolves, making historical studies less useful when considering modern implant designs. RTSA has been advocated as a solution for patients with severe glenoid bone loss with intact rotator cuff function. Moreover, in appropriately selected patients, good outcomes can be achieved without the use of bone grafting or augmented baseplates. In cases of severe glenoid bone loss, RTSA can be performed with reaming the glenoid flat such that the baseplate rests on native glenoid bone. We have previously reported excellent prosthetic survival with this technique at 5-year follow-up. The purpose of this article is to highlight our suggested treatment algorithm for glenohumeral OA with glenoid bone loss and intact rotator cuff. Specifically, we focus on situations where RTSA may be preferred as opposed to anatomic TSA, and our suggested approach to managing bone loss intraoperatively in this complex patient population.

**Keywords:** Shoulder arthroplasty; glenoid bone loss; intact rotator cuff; algorithm

Received: 06 December 2022; Accepted: 22 March 2023; Published online: 11 April 2023.

doi: 10.21037/aoj-22-53

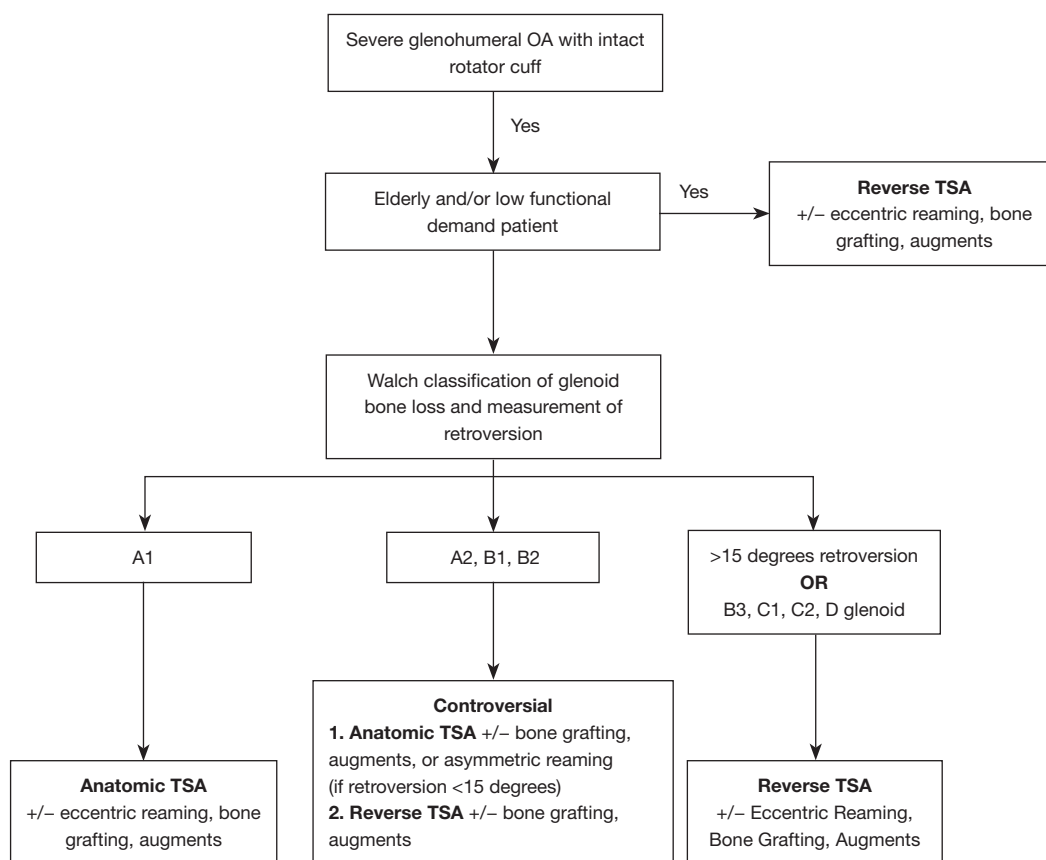
**View this article at:** <https://dx.doi.org/10.21037/aoj-22-53>

## Introduction

In patients with severe glenohumeral osteoarthritis (OA) and preserved rotator cuff function who have failed nonoperative treatment, anatomic total shoulder arthroplasty (TSA) has historically been the preferred

surgical treatment (1-3). Excessive glenohumeral retroversion and wear can be seen due to long standing glenohumeral arthritis, but also can be found in congenital glenoid dysplasia, genetic joint dysplasias, dislocation dysplasia, post-traumatic arthritis, and avascular necrosis (2,4-7). Shoulder arthroplasty in the setting of glenoid bone

<sup>^</sup> ORCID: 0000-0002-8158-4364.



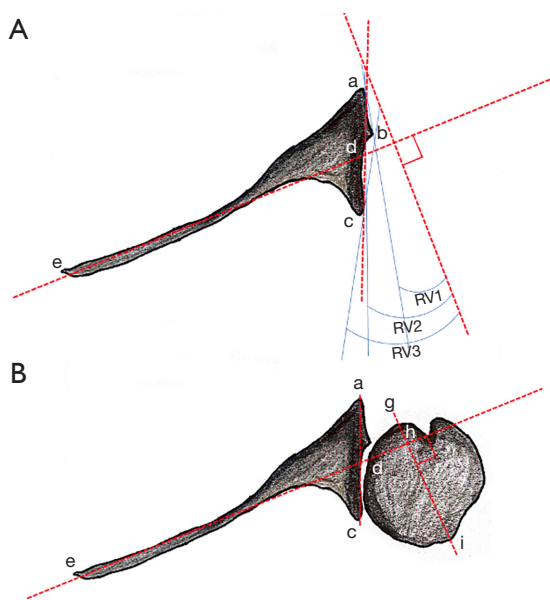
**Figure 1** Suggested treatment algorithm for patients with severe glenohumeral osteoarthritis and an intact rotator cuff. OA, osteoarthritis; TSA, total shoulder arthroplasty.

loss setting is technically demanding and associated with an increased risk of postoperative complications and revision surgery (8). Many techniques have been described to deal with glenoid bone loss including eccentric reaming, bone grafting, augmented glenoid baseplates, and patient-specific implants (1,2,7,9,10). However, some of the difficulties with glenoid fixation seen with anatomical TSA have been obviated with the advent of reverse total shoulder arthroplasty (RTSA).

RTSA was developed in 1985 by Paul Grammont to allow for improved biomechanical advantage of the deltoid to achieve full shoulder range of motion in patients with glenohumeral OA with a massive irreparable rotator cuff tears (11). With further design improvements, in addition to rotator cuff tear arthropathy, RTSA has also been shown to be effective for indications including proximal humerus fractures, revision TSA, and treating patients with severe glenoid bone loss (12). Given the enhanced stability of RTSA and robust fixation of the glenosphere compared to

anatomic TSA, RTSA has been advocated as a solution for patients with severe glenoid bone loss with intact rotator cuff function (3,6,13,14). Moreover, in appropriately selected patients, good outcomes can be achieved without the use of bone grafting or augmented baseplates (15). In cases of severe glenoid bone loss, RTSA can be performed with reaming the glenoid flat such that the baseplate rests on native glenoid bone. We have previously reported excellent prosthetic survival with this technique at 5-year follow-up (16). When this technique is performed, we recommend a goal of  $10^\circ$  of inferior inclination in the sagittal plane,  $0-9^\circ$  of posterior tilt, and positioning the baseplate to occupy the inferior portion of the glenoid (15).

The purpose of this article is to highlight our suggested treatment algorithm for glenohumeral OA with glenoid bone loss and intact rotator cuff (*Figure 1*). Specifically, we focus on situations where RTSA may be preferred as opposed to anatomic TSA, and our suggested approach to managing bone loss intraoperatively in this complex patient population.



**Figure 2** Illustration of measurements that can be assessed on preoperative shoulder CT. On a mid-axial cross-section of the glenoid (A), point e represents the medial scapula border and point d represents the midportion of the glenoid. Point a is the anterior border and point c is the posterior border of the glenoid on this cross-section. Point b is the point at which the glenoid becomes biconcave (if bone loss is severe enough). Line ed is first drawn which is the transscapular axis, or Friedman line. Line ab is then drawn which is in-line with the native glenoid, while line ac denotes the intermediate glenoid. This results in two angles, shown as angle RV2 (retroversion of the intermediate glenoid), and RV3 (neoglenoid retroversion). As seen in (B), humeral head subluxation can also be assessed using the same cross-section, which is calculated as  $hi/gi$ .

### Preoperative radiographic evaluation of glenoid bone loss in patients with intact rotator cuff

Several morphological characteristics should be closely examined in patients who present with glenoid bone loss prior to TSA. The classification system by Walch *et al.* is widely utilized and originally categorized glenoid erosion patterns as A1, A2, B1, B2 and C (5), however, the classification was later modified by Bercik *et al.* to include a B3 and D classification as well (17). In patients with type A glenoid morphology, bone loss is in the central glenoid with the humeral head centered. Type A glenoid morphology is subcategorized into A1 (minor erosion) and A2 (marked erosion). Type B glenoid morphology is defined by the humeral head subluxating posteriorly with

subsequent posterior glenoid wear. Type B is subcategorized into B1 (mild asymmetric narrowing), B2 (more extensive posterior wear resulting in a biconcave appearance), and B3 (posterior subluxation without significant retroversion). Type C glenoid morphology is defined by greater than 25 degrees of glenoid retroversion which is representative of severe glenoid bone loss. Type D glenoid morphology is defined as any level of glenoid anteversion or with humeral head subluxation of less than 40% (5,17). In addition to classification of bone loss, measurement of retroversion and humeral head subluxation can also be achieved based on preoperative CT measurements (Figure 2).

### Surgical techniques for dealing with glenoid bone loss

#### Eccentric reaming

Eccentric reaming is a technique which may be used to correct glenoid retroversion in the setting of glenoid bone loss, however, one should keep in mind that excessive reaming into subchondral bone of the glenoid may translate to decreased bony contact for supporting the glenoid baseplate, and a medialized joint line (18). While eccentric reaming may be performed for patients with mild glenoid retroversion, it has been demonstrated that attempting to correct glenoid retroversion  $>15^\circ$  may result in inadequate bony support. In a cadaveric study by Gillespie *et al.*, it was determined that correcting  $15^\circ$  of retroversion or more may result in penetration of the glenoid implant peg and/or inadequate bony support due to decreased anterior/posterior glenoid diameter (4). Similarly, Clavert *et al.* demonstrated in cadaveric specimens that eccentric reaming for  $>15^\circ$  retroversion resulted in central peg perforation in each of the five cadaveric specimens studied (19). In addition, a study by Formaini *et al.*, using polyethylene trabecular bone surrogates, found that support of the glenoid tray was adequate for baseplate stability until up to 25% of coverage was lost from the glenoid which resulted in significantly greater micromotion above their threshold of 150- $\mu$ m over 10,000 cycles (8).

There are suggestions in the literature that eccentric reaming for RTSA can be tolerated in cases with over 25 degrees of retroversion. McFarland *et al.* previously reported upon the 5-year follow-up of 29 patients who underwent RTSA with eccentric glenoid reaming alone as a treatment for glenoid bone loss without bone grafting (16). In this patient cohort, the cumulative incidence of baseplate failure

requiring revision was 2.4% at 2 years and 5.2% at 5 years. Scapular notching occurred in 19% of shoulders included in this study. However, the notching was all low grade and there were no signs of baseplate loosening due to scapular notching. Overall, clinical outcome scores were significantly improved at 5 years compared to preoperatively (16). When performing this technique, it was recommended using an unthreaded Steinmann pin placed with 10 degrees of inferior tilt and reaming the glenoid until the smallest reamer produces a flat surface to optimize bony contact between the glenoid and baseplate. Ideally, four peripheral locking screws are inserted given that each screw is able to achieve adequate bony fixation. In their cohort of 29 patients with glenoid bone loss, it was found that 22% of patients lacked adequate bone stock for 4 screws (15). In these cases, 33 (78%) of the patients had 4 screws, 7 (17%) had 3 screws, and 2 (5%) had 2 screws. One of the advantages of this technique is that special reaming such as needed for augmented implants is not necessary. Similarly eccentric reaming it obviates the need for glenohumeral bone grafting which is technically difficult and can result in failure of the glenoid-baseplate interface.

### **Bone grafting**

When glenoid bone loss is too severe for eccentric reaming techniques, bone grafting is another option for achieving stable fixation of the glenoid baseplate. Although many studies have been performed which analyze the use of bone grafting for anatomic and RTSA, outcomes of these studies are mixed and often report high rates of glenoid component failure, graft-related complications, and eventual prosthetic instability (2,6,10,18). Klika *et al.*, demonstrated outcomes of patients who received bone grafting and anatomic TSA in a series of 25 patients with 8.7-year follow-up. In their cohort, 12 patients had a Neer II metal-backed component, 7 had a Cofield II all-polyethylene, 2 had a Cofield II all-polyethylene keeled, and 4 had an Aequalis all-polyethylene keeled component. While 92% of patients were satisfied with their outcomes overall, 40% of patients had radiographic evidence of component loosening although only two patients required revision surgery (20). In a 2012 study by Walch *et al.*, the clinical outcomes and Constant Score of 7 patients were reported with 2-year follow-up who had glenoid bone-grafting with 2 patients having a collapsed graft and 3 patients experiencing at least 1 dislocation (21). At final follow-up in the Walch study, mean Constant score improved significantly approximately 30 points.

Boileau *et al.* have also described the technique of using autologous glenoid bone graft from the humeral head in RTSA (angled BIO-RSA) (9). The aim of this technique was initially to lateralize the baseplate to minimize notching. In this technique, a trapezoidal bone graft is used which aims to restore glenoid bone stock and lateralize the center of rotation. The authors report using this technique in patients with greater than  $>15^\circ$  of glenoid retroversion. In a case series of 54 patients with 2-year follow-up, the authors reported complete graft incorporation in 94% of patients and significantly improve patient-reported outcome scores (9).

### **Glenoid component augmentation**

Glenoid component augmentation is an additional method that has been described as a method of addressing glenoid bony defects during both anatomic TSA and RTSA. Augmented components include polyethylene designs utilized for anatomic TSA and are made of metal in baseplate components used in RTSA (22-24). Various augmented glenoid component designs have been described for anatomic TSA including all-polyethylene monoblock with full-wedge (Equinox; Exactech, Gainesville, FL, USA) (22), half-wedge augmented glenoid (Aequalis Perform+; Wright Medical Group, Memphis, TN, USA) (22), or step-cut design (Global StepTech; DePuy Synthes, Warsaw, IN, USA) (22,23) (*Figure 3*).

For RTSA, various metal augmented baseplate designs have been described including the Zimmer Biomet Comprehensive Shoulder System (Zimmer Biomet, Warsaw, IN), Tornier Aequalis Perform+ Reversed half-wedge augmented and full-wedge-augmented baseplates (Wright Medical Group N.V., Memphis, TN, USA) and Exactech Equinox Reverse System (Exactech Inc., Gainesville, FL) (25) (*Figure 3*).

Given that augmented component designs vary significantly between anatomic TSA and RTSA and between companies, there is substantial difficulty in comparing clinical outcomes of these prosthesis options and this should be acknowledged when interpreting studies which report outcomes in patients with glenoid component augmentation. In a 2014 study by Sabesan *et al.*, the authors performed a computer simulation of glenoid component augmentation versus asymmetric reaming in anatomic TSA and found that there was a greater ability to correct version with less joint line medialization through the use of augmented components (26). There are a number of clinical studies evaluating augmented glenoid components and



**Figure 3** Augmented glenoid component designs. Artistic rendering of various augmented glenoid component designs (A-C). Augmented components include polyethylene designs utilized for anatomic TSA (A) and are made of metal baseplate components used in RTSA (B,C). All-polyethylene monoblock designs may be stepped as seen in panel A (DePuy Synthes, Warsaw, IN, USA) or include half or full wedges. Augmented metal baseplates may also either include a full, half, or lateralized design. An example of a half-wedge augmented glenoid is depicted in panel B (Wright Medical Group N.V., Memphis, TN, USA). In addition, augmentation may be posterior and/or superior, and an example of a posterior/superior augmented design is demonstrated in panel C (Exactech Inc., Gainesville, FL, USA). TSA, total shoulder arthroplasty; RTSA, reverse total shoulder arthroplasty.

augmented baseplates used in RTSA. A recent systematic review included nine studies (312 patients total) which used augmented glenoid components at a mean follow-up of 37 months (range, 2.3–72 months) (24). Overall, they found that 35% of patients had reported radiolucency surrounding the components with 44% rate of peg perforation in 5 mm augment stepped implants (24). While glenoid component augmentation is still developing a long-term track-record, larger studies are needed before widespread adoption in dealing with patients who have glenoid bone loss and an intact rotator cuff.

### Deciding between anatomic vs. RTSA in patients with glenoid bone loss

RTSA has been demonstrated to be a viable option for patients with glenoid bone loss and intact rotator cuff function. Although anatomic TSA is conventionally preferred for patients with intact rotator cuff, the improved constraint and fixation of RTSA has led to many authors favoring this option for those with severe glenoid bone loss (18). There are anatomical and demographic factors which need to be considered when determining the best treatment for any particular patient.

#### Anatomical considerations

One advantage of RTSA over TSA is that an intact rotator cuff is not necessary for its success in relieving pain and

improving motion. One of the main causes of failure of anatomical TSA is failure of the rotator cuff either in the short post-operative period or later as the patient ages. This is especially a concern when the patient has significant internal rotation contractures with subscapularis and capsular contracture. For example, the failure rate of anatomic TSA for patients whose indication was dislocation arthropathy is very high due to failure of the subscapularis tendon (27). This failure of the subscapularis tendon does not typically effect the function of RTSA. In a meta-analysis of studies which examine shoulder arthroplasty for dislocation arthropathy, it was found that RTSA had lower rates of complications and reoperation compared to anatomic TSA (28).

#### Elderly patients or those with low functional demand

Patients who are elderly (generally defined as >70 years old) or who have low functional demand in addition to glenoid bone loss may be best suited for primary RTSA. Given the enhanced stability of RTSA it has been shown to have at least equivalent outcomes compared to anatomic TSA when performed in the setting of glenoid bone loss. However, previously active patients may report worse functional outcomes scores compared to anatomic TSA due to improved motion often seen in anatomic TSA over RTSA. Alentorn-Geli *et al.* studied patients with B2 glenoid bone loss and compared anatomic TSA with posterior capsular plication to RTSA without capsular plication. They found



that clinical outcomes (American Shoulder and Elbow Surgeons score and Simple Shoulder test score) of the two groups were equivalent with the exception of the Simple Shoulder Test which was lower than the patients with anatomic TSA (3). Of note, patients in this study were not stratified by age or preoperative functional status.

In a 2020 study by Wright *et al.*, the authors examined 135 patients over the age of 70 who underwent RTSA or anatomic TSA with intact rotator cuff and found no differences between the two groups for patient reported outcomes, complications or revision surgery (29). However, population studies have demonstrated that rotator cuff pathology increases with age each decade beginning around the age of 50 (30). While the numbers were limited, one study found that 80% of the patients with asymptomatic shoulders over the age of 80 had full thickness rotator cuff tears (31). As a result, patients who are above 70 and have clinical signs of rotator cuff dysfunction should be evaluated with further imaging studies to determine the status of the rotator cuff before deciding upon which type of implant to be utilized.

### **Severe glenoid bone loss or retroversion >15°**

Anatomic TSA for biconcave glenoid bone loss has historically been associated with high complication rates. Walch *et al.* reported on 92 patients with biconcave glenoid bone loss and intact rotator cuffs who underwent anatomic TSA (average follow-up of 77 months, average age at time of surgery was 68 years (range, 50–85 years). In their cohort, 15 (16%) revisions were performed, with a rate of 6.5% of glenoid loosening and 5.5% of patients undergoing revision for posterior instability. In addition, only 66% of patients reported being satisfied or very satisfied (21). In contrast, a 2013 study by Mizuno *et al.*, a series of 27 patients received RTSA for an indication of glenoid erosion with biconcavity, mean age of the patients at the time of surgery was 74.1 years (range, 66–82 years) (12). The authors found overall excellent clinical outcomes with significant improvements in the Constant score and shoulder range of motion in all planes. In addition, there was no evidence of glenoid component loosening and no recurrence of posterior instability noted in their cohort (12).

As there are no prospective studies directly comparing anatomic TSA to RTSA in patients with an intact rotator cuff who have significant glenoid bone loss, the options depend upon not only anatomic considerations but also demographic ones. In the patient with an intact rotator

cuff who wants to be very active, an anatomic TSA with bone grafting or with an augmented component might be warranted. However, the same patient who is inactive might be better off with eccentric reaming or an augmented baseplate depending upon whether computer modeling demonstrates that the glenoid pegs will not penetrate the posterior wall of the glenoid vault. In the patient who is inactive the risk of bone graft failing would not typically be the treatment of choice. Similarly, a patient with dislocation arthropathy with a severely contracted rotator cuff might warrant a RTSA rather than risk with an anatomic TSA with or without bone grafting.

### **Suggested treatment algorithm**

A suggested treatment algorithm based upon the literature above is outlined in *Figure 1*. Beginning with patients who present with symptomatic glenohumeral OA which has failed nonoperative treatment and who have an intact rotator cuff, the first factors to consider should be the patient's level of activity and age. Generally, we would recommend RTSA for patients in this category with bone loss that can be managed by a variety of methods including eccentric reaming, bone grafting or augments. In patients who are not deemed to be elderly or low functional demand, bone loss and glenoid retroversion should be measured according to the Walch classification. In active/younger patients with minimal bone loss (A1 glenoid), these patients can usually be managed with anatomic TSA. Activity level should be assessed thoroughly by the surgeon and a shared discussion between the patient and surgeon should take place in these patients. Particular attention should be paid towards overhead activities, manual labor, and interest in sporting activities. In patients with more severe bone loss (A2, B1, B2), we recommend engaging in shared decision-making with the patient as both anatomic and reverse TSA may be viable options depending on a number of nuanced possible patient characteristics including their preference, the surgeon preferences, and implant designs able to be utilized. Finally, in cases of severe bone loss (B3, C1/C2, or D glenoids or >15 degrees of retroversion), the evidence and our experience support using RTSA as the preferred method of restoring glenohumeral function.

In the future, we believe it is important for prospective studies to further improve our suggested treatment algorithm. Specifically, defining specific functional and age thresholds for which the benefits of anatomic TSA may outweigh reverse TSA. Given the complexity of defining

both functional and age-related cutoffs for anatomic TSA vs. reverse TSA, this research question would probably best be answered by a large prospective observational study with long-term follow-up.

## Conclusions

An algorithmic approach for the surgical management of patients who present with symptomatic glenohumeral OA and an intact rotator cuff, while presented here based upon the literature, both anatomical and demographic factors should be considered in the decision make process. Although anatomic TSA has historically been the gold standard for treating these patients, RTSA has become increasingly utilized and proven to be efficacious for treating these complex patients. While younger, active patients with minimal bone loss are the best candidates for anatomic TSA, RTSA become increasingly favored in cases of more severe bone loss or patients who may be elderly or less active.

## Acknowledgments

*Funding:* None.

## Footnote

*Provenance and Peer Review:* This article was commissioned by the Guest Editor (Prashant Meshram) for the series “Controversies in Shoulder Surgery and Algorithmic Approach to Decision Making” published in *Annals of Joint*. The article has undergone external peer review.

*Peer Review File:* Available at <https://aoj.amegroups.com/article/view/10.21037/aoj-22-53/prf>

*Conflicts of Interest:* All authors have completed the ICMJE uniform disclosure form (available at <https://aoj.amegroups.com/article/view/10.21037/aoj-22-53/coif>). The series “Controversies in Shoulder Surgery and Algorithmic Approach to Decision Making” was commissioned by the editorial office without any funding or sponsorship. The authors have no other conflicts of interest to declare.

*Ethical Statement:* The authors are accountable for all aspects of the work in ensuring that questions related to the accuracy or integrity of any part of the work are appropriately investigated and resolved.

*Open Access Statement:* This is an Open Access article distributed in accordance with the Creative Commons Attribution-NonCommercial-NoDerivs 4.0 International License (CC BY-NC-ND 4.0), which permits the non-commercial replication and distribution of the article with the strict proviso that no changes or edits are made and the original work is properly cited (including links to both the formal publication through the relevant DOI and the license). See: <https://creativecommons.org/licenses/by-nc-nd/4.0/>.

## References

1. Mori D, Abboud JA, Namdari S, et al. Glenoid bone loss in anatomic shoulder arthroplasty: literature review and surgical technique. *Orthop Clin North Am* 2015;46:389-97, x.
2. Sears BW, Johnston PS, Ramsey ML, et al. Glenoid bone loss in primary total shoulder arthroplasty: evaluation and management. *J Am Acad Orthop Surg* 2012;20:604-13.
3. Alentorn-Geli E, Wanderman NR, Assenmacher AT, et al. Anatomic total shoulder arthroplasty with posterior capsular plication versus reverse shoulder arthroplasty in patients with biconcave glenoids: A matched cohort study. *J Orthop Surg (Hong Kong)* 2018;26:2309499018768570.
4. Gillespie R, Lyons R, Lazarus M. Eccentric reaming in total shoulder arthroplasty: a cadaveric study. *Orthopedics* 2009;32:21.
5. Walch G, Badet R, Boulahia A, et al. Morphologic study of the glenoid in primary glenohumeral osteoarthritis. *J Arthroplasty* 1999;14:756-60.
6. Gallusser N, Farron A. Complications of shoulder arthroplasty for osteoarthritis with posterior glenoid wear. *Orthop Traumatol Surg Res* 2014;100:503-8.
7. Seidl AJ, Williams GR, Boileau P. Challenges in Reverse Shoulder Arthroplasty: Addressing Glenoid Bone Loss. *Orthopedics* 2016;39:14-23.
8. Formaini NT, Everding NG, Levy JC, et al. The effect of glenoid bone loss on reverse shoulder arthroplasty baseplate fixation. *J Shoulder Elbow Surg* 2015;24:e312-9.
9. Boileau P, Morin-Salvo N, Gauci MO, et al. Angled BIO-RSA (bony-increased offset-reverse shoulder arthroplasty): a solution for the management of glenoid bone loss and erosion. *J Shoulder Elbow Surg* 2017;26:2133-42.
10. Malhas A, Rashid A, Copas D, et al. Glenoid bone loss in primary and revision shoulder arthroplasty. *Shoulder Elbow* 2016;8:229-40.
11. Boileau P, Watkinson DJ, Hatzidakis AM, et al. Grammont reverse prosthesis: design, rationale, and biomechanics. *J*

- Shoulder Elbow Surg 2005;14:147S-61S.
12. Mizuno N, Denard PJ, Raiss P, et al. Reverse total shoulder arthroplasty for primary glenohumeral osteoarthritis in patients with a biconcave glenoid. *J Bone Joint Surg Am* 2013;95:1297-304.
  13. Steen BM, Cabezas AF, Santoni BG, et al. Outcome and value of reverse shoulder arthroplasty for treatment of glenohumeral osteoarthritis: a matched cohort. *J Shoulder Elbow Surg* 2015;24:1433-41.
  14. Harmsen S, Casagrande D, Norris T. "Shaped" humeral head autograft reverse shoulder arthroplasty : Treatment for primary glenohumeral osteoarthritis with significant posterior glenoid bone loss (B2, B3, and C type). *Orthopade* 2017;46:1045-54.
  15. McFarland EG, Huri G, Hyun YS, et al. Reverse Total Shoulder Arthroplasty without Bone-Grafting for Severe Glenoid Bone Loss in Patients with Osteoarthritis and Intact Rotator Cuff. *J Bone Joint Surg Am* 2016;98:1801-7.
  16. McFarland EG, Meshram P, Rojas J, et al. Reverse Total Shoulder Arthroplasty without Bone-Grafting for Severe Glenoid Bone Loss in Patients with Osteoarthritis and Intact Rotator Cuff: A Concise 5-Year Follow-up of a Previous Report. *J Bone Joint Surg Am* 2021;103:581-5.
  17. Bercik MJ, Kruse K 2nd, Yalozis M, et al. A modification to the Walch classification of the glenoid in primary glenohumeral osteoarthritis using three-dimensional imaging. *J Shoulder Elbow Surg* 2016;25:1601-6.
  18. Stephens SP, Paisley KC, Jeng J, et al. Shoulder arthroplasty in the presence of posterior glenoid bone loss. *J Bone Joint Surg Am* 2015;97:251-9.
  19. Clavert P, Millett PJ, Warner JJ. Glenoid resurfacing: what are the limits to asymmetric reaming for posterior erosion? *J Shoulder Elbow Surg* 2007;16:843-8.
  20. Klika BJ, Wooten CW, Sperling JW, et al. Structural bone grafting for glenoid deficiency in primary total shoulder arthroplasty. *J Shoulder Elbow Surg* 2014;23:1066-72.
  21. Walch G, Moraga C, Young A, et al. Results of anatomic nonconstrained prosthesis in primary osteoarthritis with biconcave glenoid. *J Shoulder Elbow Surg* 2012;21:1526-33.
  22. Ghorraishian M, Abboud JA, Romeo AA, et al. Augmented glenoid implants in anatomic total shoulder arthroplasty: review of available implants and current literature. *J Shoulder Elbow Surg* 2019;28:387-95.
  23. Friedman LG, Garrigues GE. Anatomic Augmented Glenoid Implants for the Management of the B2 Glenoid. *J Shoulder Elb Arthroplast* 2019;3:2471549219870350.
  24. Sheth U, Lee JY, Nam D, et al. Early outcomes of augmented glenoid components in anatomic total shoulder arthroplasty: a systematic review. *Shoulder Elbow* 2022;14:238-48.
  25. Mourad W, Wiater JM, Wiater BP, et al. Baseplate Options for Reverse Total Shoulder Arthroplasty. *Curr Rev Musculoskelet Med* 2020;13:769-75.
  26. Sabesan V, Callanan M, Sharma V, et al. Correction of acquired glenoid bone loss in osteoarthritis with a standard versus an augmented glenoid component. *J Shoulder Elbow Surg* 2014;23:964-73.
  27. Coifman I, Brunner UH, Scheibel M. Dislocation Arthropathy of the Shoulder. *J Clin Med* 2022;11:2019.
  28. Cerciello S, Corona K, Morris BJ, et al. Shoulder arthroplasty to address the sequelae of anterior instability arthropathy and stabilization procedures: systematic review and meta-analysis. *Arch Orthop Trauma Surg* 2020;140:1891-900.
  29. Wright MA, Keener JD, Chamberlain AM. Comparison of Clinical Outcomes After Anatomic Total Shoulder Arthroplasty and Reverse Shoulder Arthroplasty in Patients 70 Years and Older With Glenohumeral Osteoarthritis and an Intact Rotator Cuff. *J Am Acad Orthop Surg* 2020;28:e222-9.
  30. Hsu J, Keener JD. Natural History of Rotator Cuff Disease and Implications on Management. *Oper Tech Orthop* 2015;25:2-9.
  31. Geary MB, Elfar JC. Rotator Cuff Tears in the Elderly Patients. *Geriatr Orthop Surg Rehabil* 2015;6:220-4.

doi: 10.21037/aoj-22-53

**Cite this article as:** Harris AB, Familiari F, Russo R, Lukasiewicz P, McFarland EG. Shoulder arthroplasty in patients with glenohumeral osteoarthritis, glenoid bone loss and an intact rotator cuff: an algorithmic approach and review of the literature. *Ann Joint* 2023;8:18.