

## Case Report

# Motor vehicle collision with seatbelt sign and traumatic abdominal wall hernia should raise suspicion for hollow viscus injury<sup>☆</sup>

Michael A. D'Elia<sup>\*</sup>, R. Ian Grant, Nicole O. Kolozsvari, Maher M. Matar

Division of General Surgery, Department of Surgery, The Ottawa Hospital, Ottawa, Ontario, Canada

## ARTICLE INFO

## Keywords:

High speed MVC  
Seatbelt sign  
Traumatic abdominal wall hernia  
Hollow viscus injury

## SUMMARY

Diagnosing hollow viscus injury following motor vehicle collision (MVC) requires a high index of suspicion. Here we present two cases of high velocity MVC, with 3-point restrained occupants, who presented with a seatbelt sign and associated acute traumatic flank herniation. Both patients underwent a computer tomography (CT) scan which did not identify any hollow viscus injuries. Significant injuries were ultimately identified in the operating room (OR). The presence of a seatbelt sign and underlying acute traumatic hernia should prompt a heightened level of suspicion for intra-abdominal injury, particularly hollow viscus. A heightened level of suspicion and a lower threshold for operative exploration is suggested to avoid the morbidity and mortality associated with a delayed diagnosis of hollow viscus injury.

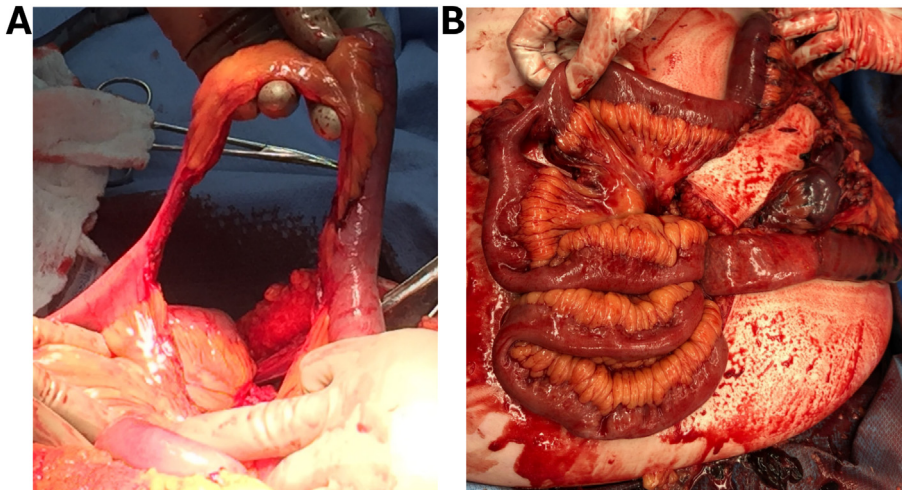
## Case 1

A healthy 52 year old male presented to our level one trauma centre (LITC) via ambulance approximately 30 min after sustaining an MVC with significant impact. On arrival in the trauma bay he was awake and oriented with a GCS of 15. He had good airway entry bilaterally, with a seatbelt sign tracking across his left neck, chest and abdomen. He was tachycardic (heart rate of 120 bpm), but responsive to a minimal fluid challenge. Focussed assessment with sonography for trauma (FAST) scan was positive in Morrison's pouch and the rectovesical pouch. A CT scan demonstrated active contrast extravasation from the small bowel mesentery with moderate hemoperitoneum and a portion of proximal small bowel with differential enhancement suggestive of edema, without free air. There was also an acute left lateral abdominal wall hernia, and a contained right renal injury, with no intra-peritoneal solid organ injuries. Additional orthopedic injuries were noted. Given a transient response to fluid challenge, with active extravasation on CT scan and abdominal tenderness, the patient was brought to the OR for urgent laparotomy.

In the OR, 4 L of hemoperitoneum were evacuated and the mesenteric hemorrhage was identified at the distal ileum and controlled with clips. At this site, there was a complete transection of the distal ileum, 15 cm proximal to the ileocecal valve. There were 2 additional small bowel antimesenteric blowout injuries identified, and a bucket-handle injury involving 15 cm of proximal ileum (Fig. 1A). Within the colon, we identified a serosal injury with bruising at the distal sigmoid which, upon mobilization, revealed a 10 cm bucket-handle injury just proximal to the rectosigmoid junction. The traumatic flank hernia seen on CT contained this portion of the sigmoid colon. The patient's stability allowed for resection and successful primary anastomosis of all hollow viscus injuries.

<sup>☆</sup> Portions of this manuscript were presented at the Trauma Association of Canada meeting in Calgary, Feb 28–Mar 1, 2019 as a poster presentation.

<sup>\*</sup> Corresponding author at: The Ottawa Hospital-Civic Campus, Division of Trauma, 1053 Carling Ave, Ottawa, ON K1Y 4E9, Canada.  
E-mail address: [mrelia@toh.ca](mailto:mrelia@toh.ca) (M.A. D'Elia).



**Fig. 1.** Bucket handle injuries: Intraoperative photographs (A: Case 1, B: Case 2) demonstrating significant bucket handle injuries of the small bowel. (For interpretation of the references to colour in this figure legend, the reader is referred to the web version of this article.)

### Case 2

A healthy 56 year old female, with a history of Roux-en-Y gastric bypass for obesity, was transferred to our L1TC from a community hospital several hours post MVC, with hypotension (95/50 mm Hg) and abdominal pain. Her examination revealed multiple bruises over her face and a seatbelt sign over her chest and abdomen. A CT scan identified a traumatic right flank hernia containing small bowel and fluid, with only trace intra-abdominal free fluid. There was no free air or evidence of any solid organ injury. Additional orthopedic injuries were identified as well. Despite her relative stability, she was taken to the OR for exploratory laparoscopy due to abdominal pain out of proportion with her assessment.

In the OR, an initial laparoscopic reduction of the distal small bowel from the hernia revealed a bucket handle injury with bowel ischemia precipitating a laparotomy (Fig. 1B). Overall, a total of 160 cm of proximal to mid-jejunum was noted to be ischemic and thus resected with primary anastomosis. Along with this, a primary tissue closure of the right flank hernia was performed. No other abdominal injuries were identified.

### Discussion

These cases highlight the destructive potential of high velocity MVC, even with relatively non-specific CT scan findings. In particular, hollow viscus injuries that go undetected can have significant ramifications. Even short delays in diagnosis and management of hollow viscus injuries can lead to significant increases in morbidity and mortality [1].

Hollow viscus injuries are rare in blunt abdominal trauma and difficult to identify in the initial trauma assessment, even with adjuncts such as CT scans [2,3]. Highly specific, but uncommon findings, such as the presence of free air or oral contrast extravasation, facilitate the diagnosis. However, more common findings, such as bowel wall enhancement or thickening, or the presence of free fluid are more sensitive, but have poor specificity [4,5]. Free fluid in the abdomen can be attributed to a solid organ injury, masking an underlying hollow viscus injury [6]. Furthermore, CT scans have been shown to carry a false negative rate of approximately 15% in diagnosing hollow viscus injury [2]. Although an observational approach can be employed for stable trauma patients without overt objective findings of hollow viscus injury, a delay of 24 h in diagnosis can increase mortality from 2% to 30% [1].

The presence of a seatbelt sign ecchymosis implies significant impact and transfer of kinetic energy to the abdominal wall. It has been shown that up to 10% of MVCs with a seatbelt sign suffer an underlying hollow viscus injury [7]. A study by Chandler et al. showed that the presence of a seatbelt sign resulted in an increased presence of intra-abdominal injuries including small bowel perforation, and an increased need for laparotomy [8]. Moreover, acute traumatic abdominal wall hernia following blunt trauma is a very rare entity, identified in only 0.2% of all blunt traumas [9]. A review by Suhardja et al. demonstrated that 60% of patients with blunt traumatic abdominal wall hernias had concurrent intra-abdominal injuries, of which 72% were hollow viscus in nature [10].

Increased impact velocity results in amplified transfer of kinetic energy, raising the potential for injury. A study by Lamielle et al. demonstrated that vehicle speed at impact was directly proportional to the severity of intra-abdominal organ injuries identified. They showed that a rise in impact velocity from 40 to 50 km/h compared to 70–79 km/h led to an increased rate of abdominal trauma from 2.75% to 24.62% respectively. Furthermore, examining the ratio of hollow viscus to solid organ injury at each respective speed, showed an 11% increase (39% to 50%) in hollow viscus injury with this modest increases in velocity [11].

The presence of a seatbelt sign and an acute traumatic abdominal wall hernia following high speed MCV are an ominous combination. This should be met with a heightened level of suspicion for intra-abdominal injury, particularly hollow viscus, irrespective

of the CT findings. Hollow viscus injuries are particularly difficult to assess, and delays in management significantly increase morbidity and mortality. These cases highlight the destructive nature of high velocity blunt abdominal trauma and the heightened suspicion necessary to allow for early diagnosis and management. In each case we were able to identify significant pathology in the OR which was not appreciated from the clinical exam or on imaging studies preoperatively.

## References

- [1] S.M. Fakhry, M. Brownstein, D.D. Watts, C.C. Baker, D. Oller, Relatively short diagnostic delays (< 8 hours) produce morbidity and mortality in blunt small bowel injury: an analysis of time to operative intervention in 198 patients from a multicenter experience, *J. Trauma* 48 (2000) 408–414 (discussion 14-5).
- [2] S.M. Fakhry, D.D. Watts, F.A. Luchette, Group EM-IHVIR, Current diagnostic approaches lack sensitivity in the diagnosis of perforated blunt small bowel injury: analysis from 275,557 trauma admissions from the EAST multi-institutional HVI trial, *J. Trauma* 54 (2003) 295–306.
- [3] D.D. Watts, S.M. Fakhry, Group EM-IHVIR, Incidence of hollow viscus injury in blunt trauma: an analysis from 275,557 trauma admissions from the East multi-institutional trial, *J. Trauma* 54 (2003) 289–294.
- [4] J.A. Soto, S.W. Anderson, Multidetector CT of blunt abdominal trauma, *Radiology* 265 (2012) 678–693.
- [5] V. Virmani, U. George, B. MacDonald, A. Sheikh, Small-bowel and mesenteric injuries in blunt trauma of the abdomen, *Can. Assoc. Radiol. J.* 64 (2013) 140–147.
- [6] J.M. Brody, D.B. Leighton, B.L. Murphy, G.F. Abbott, J.P. Vaccaro, L. Jagminas, et al., CT of blunt trauma bowel and mesenteric injury: typical findings and pitfalls in diagnosis, *Radiographics* 20 (2000) 1525–1536 (discussion 36-7).
- [7] G.S. Allen, F.A. Moore, C.S. Cox, J.T. Wilson, J.M. Cohn, J.H. Duke, Hollow visceral injury and blunt trauma, *J. Trauma* 45 (1998) 69–75 (discussion -8).
- [8] C.F. Chandler, J.S. Lane, K.S. Waxman, Seatbelt sign following blunt trauma is associated with increased incidence of abdominal injury, *Am. Surg.* 63 (1997) 885–888.
- [9] R.W. Dennis, A. Marshall, H. Deshmukh, J.S. Bender, N. Kulvatunyou, J.S. Lees, et al., Abdominal wall injuries occurring after blunt trauma: incidence and grading system, *Am. J. Surg.* 197 (2009) 413–417.
- [10] T.S. Suhardja, M.A. Atalla, W.M. Rozen, Complete abdominal wall disruption with herniation following blunt injury: case report and review of the literature, *Int. Surg.* 100 (2015) 531–539.
- [11] S. Lamielle, S. Cuny, J. Foret-Bruno, P. Petit, P. Vezin, J. Verriest, et al., Abdominal injury patterns in real frontal crashes: influence of crash conditions, occupant seat and restraint systems, *Annu. Proc. Assoc. Adv. Automot. Med.* 50 (2006) 109–124.