

## CASE REPORT

## An Unusual Case of Delayed Complete Aortic Graft Occlusion Treated by Kissing Balloon Expandable Covered Stents and Renal Chimney

Gianmarco de Donato<sup>\*</sup>, Claudia Panzano, Edoardo Pasqui, Mariagnese Mele, Carlo Setacci, Giancarlo Palasciano

Department of Vascular and Endovascular Surgery, University of Siena, Italy

**Introduction:** Late occlusion of the entire stent graft after endovascular aortic repair (EVAR) is a rare condition which often requires open surgery. This is a case of endovascular rescue of chronic total occlusion of an aortic stent graft in a patient at high risk of open surgery and lysis.

**Report:** An 82 year old male was admitted with bilateral lower limb rest pain eight years after EVAR. Endovascular relining with a covered stent under local anaesthesia was planned. Antegrade recanalisation from brachial access was achieved, then VBX balloon expandable covered stents (W. L. Gore & Associates Inc. Flagstaff, AZ, USA) were deployed in a kissing configuration to reline the occluded stent graft, alongside a double renal chimney. The post-operative period was uneventful, and a six month CT angiogram confirmed the technical success with complete patency of the aorto-iliac segment and visceral arteries.

**Discussion:** Complete stent graft thrombosis after EVAR is typically managed by open conversion to aortobifemoral or axillobifemoral bypass graft, surgical thrombectomy or catheter directed thrombolysis, carrying a considerable mortality and morbidity rate. Endovascular relining with kissing covered balloon expandable stents with double renal chimneys is a less invasive option. By offering a unique combination of radial strength and flexibility, associated with a trackable delivery system and a high retention capability, the GORE VBX is the present authors' preferred stent option for this procedure. The present case shows how endovascular recanalisation by antegrade and retrograde approaches may be an effective option, especially in a patient at high risk of open surgery and lysis.

© 2020 The Authors. Published by Elsevier Ltd on behalf of European Society for Vascular Surgery. This is an open access article under the CC BY-NC-ND license (<http://creativecommons.org/licenses/by-nc-nd/4.0/>).

Article history: Received 12 August 2019, Revised 17 November 2019, Accepted 26 November 2019

**Keywords:** EVAR, Thrombosis, Endovascular relining, Covered stent

### INTRODUCTION

Aortic stent graft limb thrombosis is a well described and relatively common complication after endovascular aortic repair (EVAR) as a result of several anatomical predisposing factors and device accommodation.<sup>1–3</sup> The occlusion of the entire endoprosthesis has been reported rarely, and may require late open conversion.<sup>4,5</sup> This is the report of a case of endovascular rescue of chronic total occlusion of an aortic stent graft in a patient at high risk of open surgery and lysis.

### CASE REPORT

An 82 year old male was admitted to the emergency room with bilateral lower limb rest pain eight years after EVAR with an Anaconda stent graft (Vascutek Ltd.) for a 62 mm infrarenal aortic aneurysm. He had a history of coronary

artery bypass grafting, chronic obstructive pulmonary disease, gastric cancer surgery, and intracerebral haemorrhage. One year before admission he presented with mild left buttock claudication, revealed by CT to be due to thrombosis of the left iliac graft limb (Fig. 1A). At that time, medical treatment was suggested because of the mild symptoms and relatively high operative risk for the patient. When re-admitted he complained of increasing rest pain and a CT angiogram revealed occlusion of the entire endograft, extending from juxtarenal level to both iliac limbs (Fig. 1B).

The patient was not considered to be eligible for open repair because of comorbidities, and lysis was also not an option because of the previous intracerebral haemorrhage event. Endovascular relining with a covered stent under local anaesthesia was planned.

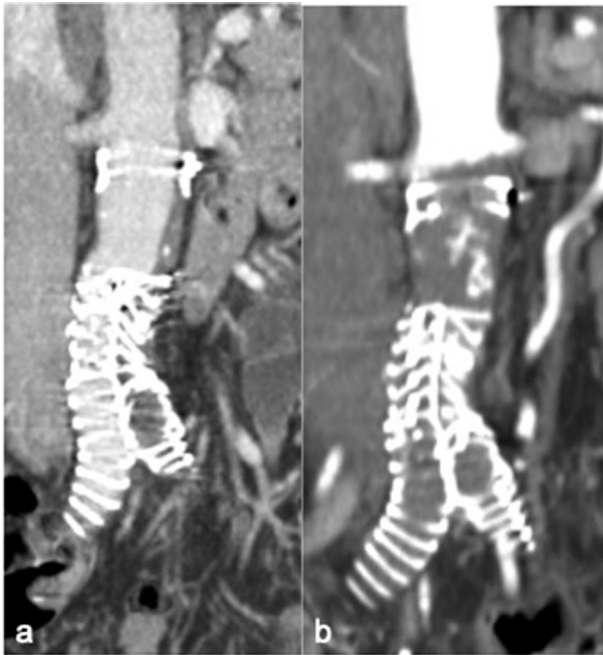
Via percutaneous left brachial access, a 90 cm 5 Fr. introducer sheath was advanced to the suprarenal aorta. Then, antegrade recanalisation of the occluded stent graft was achieved using a 0.035" guidewire supported by a 5 Fr. Bernstein catheter (Fig. 2), minimising the risk of thrombus dislodgement into renal arteries. Under fluoroscopic guidance, puncture of both common femoral arteries and

<sup>\*</sup> Corresponding author. Department of Vascular and Endovascular Surgery, University of Siena, Viale Bracci, 53100, Siena, Italy.

E-mail address: [dedonato@unisi.it](mailto:dedonato@unisi.it) (Gianmarco de Donato).

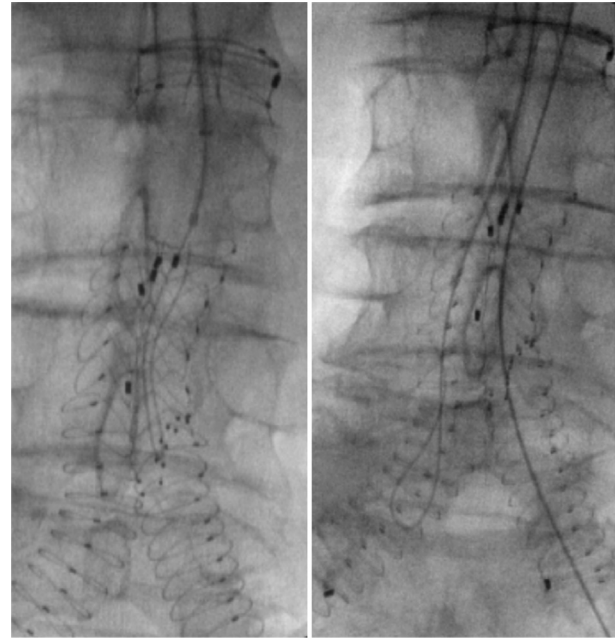
2666-688X/© 2020 The Authors. Published by Elsevier Ltd on behalf of European Society for Vascular Surgery. This is an open access article under the CC BY-NC-ND license (<http://creativecommons.org/licenses/by-nc-nd/4.0/>).

<https://doi.org/10.1016/j.ejvssr.2019.11.005>



**Figure 1.** (A) Computed tomography (CT) angiography images showed thrombosis of the left iliac limb graft (untreated because of mild symptoms). (B) One year later occlusion of the entire endograft occurred extending from juxtarenal level to both iliac limbs.

guidewire passage was carried out. Then, the brachial guidewire was introduced into the 8 Fr. femoral sheath (rendez vous manoeuvre) (Fig. 3). Initially, two 8×79 mm VBX balloon expandable covered stents (W. L. Gore & Associates Inc. Flagstaff, AZ, USA) per side were placed in a kissing configuration to reline the occluded stent graft, alongside a single renal chimney (a 5×29 mm VBX).

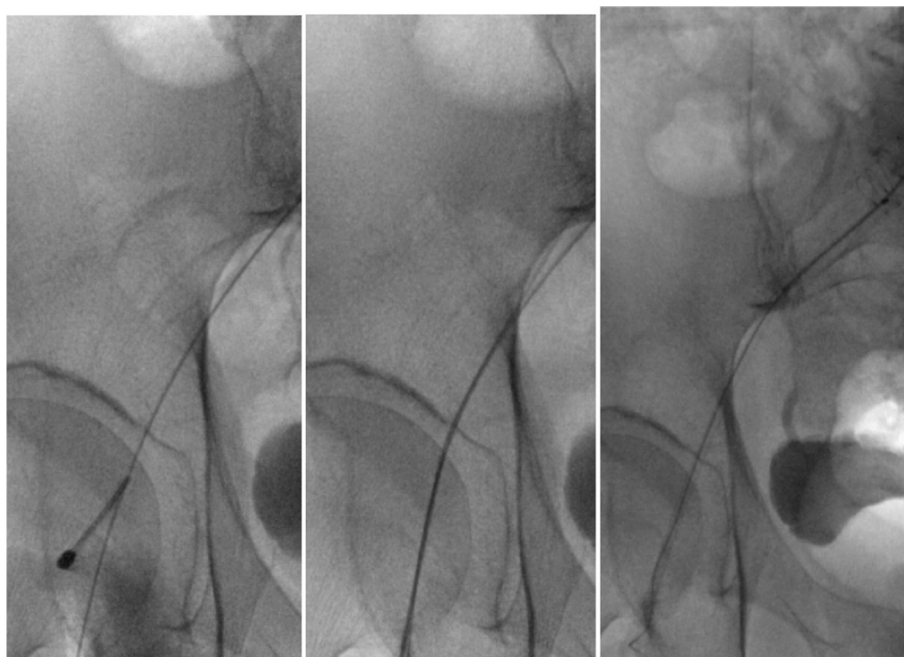


**Figure 2.** From left percutaneous brachial access, antegrade recanalisation of the occluded main stent graft body and iliac limbs using a 0.035'' guidewire supported by 5 Fr. 90 cm introducer sheath and a 5 Fr. Bernstein catheter.

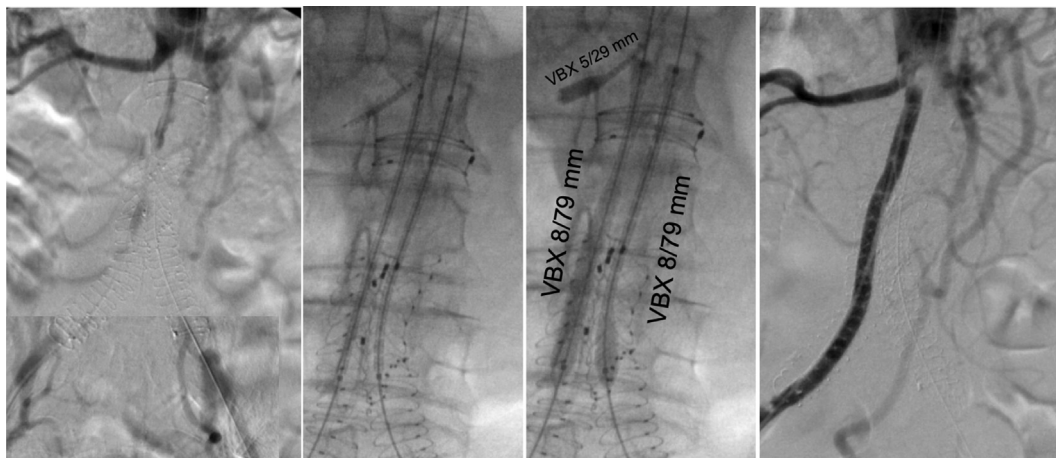
However, angiography revealed persistent thrombus at juxtarenal level (Fig. 4), demanding relining of the vessel with a double renal chimney (Fig. 5).

The final angiographic result revealed good flow restoration to the femoral arteries with complete preservation of both hypogastric arteries. Estimated blood loss was 140 mL, and 80 mL of contrast was used.

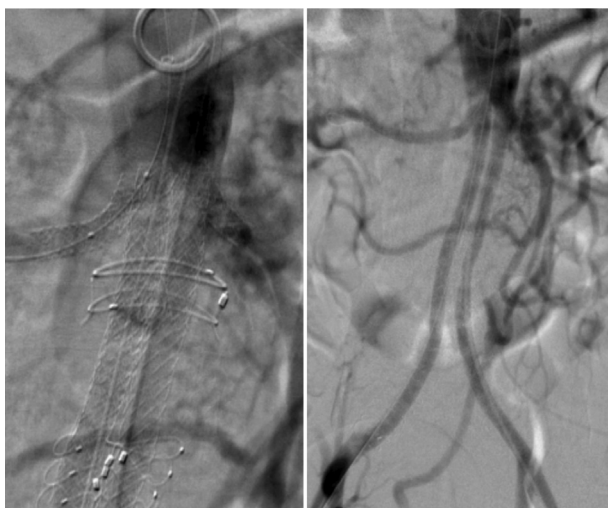The patient presented slight haematuria during the first two post-operative days, and no contrast induced



**Figure 3.** After antegrade recanalisation, common femoral artery puncture under fluoroscopic guidance and guidewire rendez vous into an 8 Fr. Femoral introducer sheath.



**Figure 4.** (A) Angiography confirming complete juxtarenal occlusion of the endovascular aortic (EVAR) main body and limbs. (B, C) Kissing balloon expandable covered stenting (VBX, W. L. Gore & Associates Inc. Flagstaff, AZ, USA) to reline the occluded stent graft, alongside a single renal chimney. (D) Angiography revealed persistent thrombus at juxtarenal level, demanding the relining of the vessel with a double renal chimney.



**Figure 5.** Final angiogram.

nephropathy was recorded. Rest pain and claudication disappeared immediately after intervention. He was discharged on the third post-operative day.

Dual antiplatelet therapy was continued for six months, when a CT angiogram confirmed the technical success of the procedure with complete patency of renal arteries, superior mesenteric artery, and aorto-iliac segment (Fig. 6).

## DISCUSSION

Complete stent graft thrombosis after EVAR is rare and typically managed by open conversion to aortobifemoral or axillobifemoral bypass,<sup>4,5</sup> surgical thrombectomy or catheter directed thrombolysis.<sup>6–8</sup> Major open conversion is typically associated with high post-operative risk, so a less invasive option combining surgical thrombectomy and endovascular relining has been described.

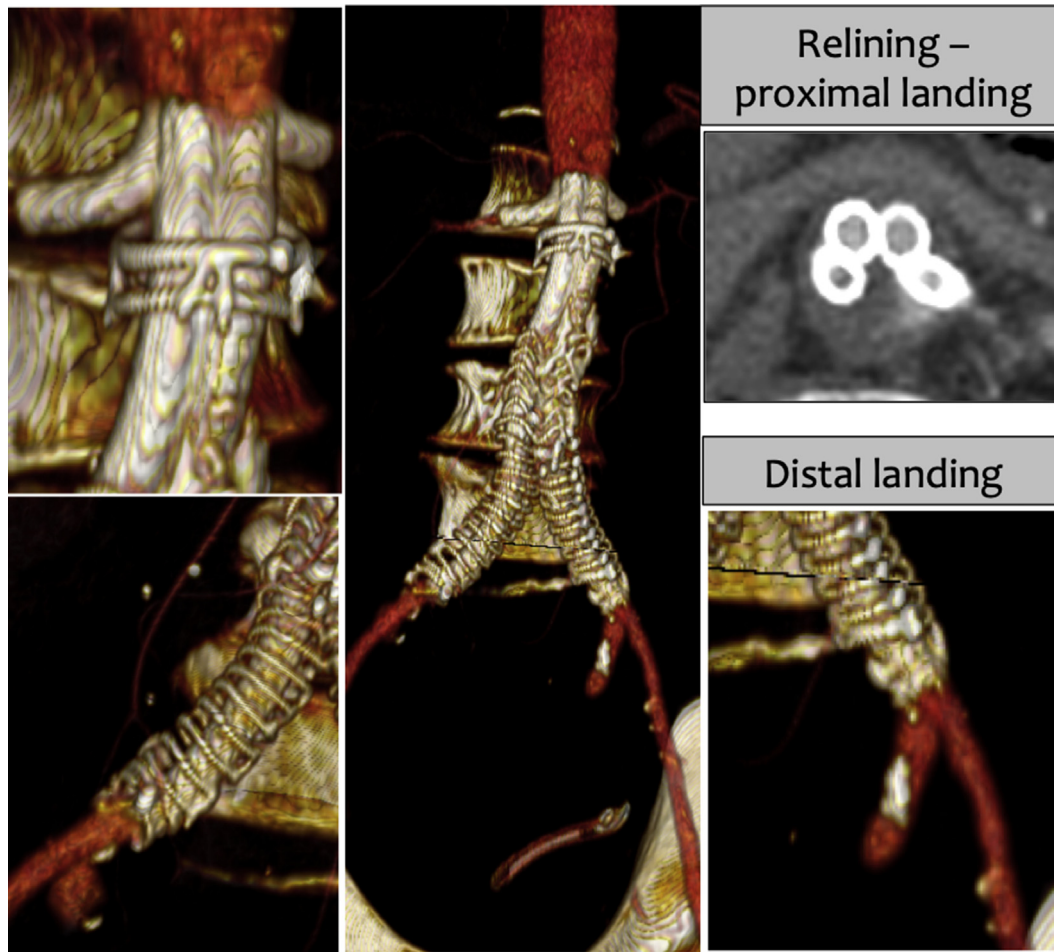
Thurley et al. proposed use of a large diameter angioplasty balloon (10–12 mm) to trawl the whole graft to remove large quantities of fresh thrombus.<sup>7</sup> This manoeuvre remains questionable and carries a risk of uncontrolled proximal and distal thrombus dislodgment as well as endograft component migration.

Catheter directed thrombolysis is a recognised treatment for EVAR graft limb thrombosis, but when reported for complete endograft thrombosis the drug dose is typically higher (from 32 mg 8–40 mg 6 of alteplase) and may be associated with retroperitoneal haematoma. These points make this option of debatable value in patients with previous bleeding events. Moreover, Waiting et al.<sup>8</sup> reported that lysis was effective for fresh thrombus of EVAR main body, but was unsuccessful for limb occlusion that had occurred sometime previously.

In the present patient, although the initial left limb occlusion caused only slight symptoms, complete endograft occlusion was responsible for rest pain and CT images revealed that thrombus had risen above renal level, giving considerable risk of kidney infarction. At that time there was an urgent need for aortobi-iliac recanalisation together with a clinical request for a minimally invasive approach.

From a technical point, the present authors' feeling is that antegrade recanalisation with a 0.035" guidewire from the percutaneous brachial access minimised the risk of renal embolisation, because all the pushing manoeuvres are in the direction of the infrarenal aorta. The use of balloon expandable covered stents from the femoral accesses allowed a very precise proximal and distal landing, offering complete coverage of fresh thrombus and treatment of established underlying thrombus. In detail, the Gore VBX has a unique combination of radial strength and flexibility, being the only commercially available covered stent graft with no longitudinal stent struts. The overall length of the covered stents was also very important in this case, allowing complete relining of the previous endograft with just





**Figure 6.** Computed tomography (CT) angiogram six months after the procedure confirmed the complete patency of the aorto-iliac segment and visceral arteries.

two 79 mm long pieces per side. Finally, two other advantages offered by these new generation covered stents were the trackable delivery system and the retention — having the stent very well fixed on the semi-compliant balloon during the manoeuvres — means that there was no need for pre-dilatation, which in this case might have meant thrombus dislodgement and renal or peripheral embolisation.

As far as the present authors are aware, this is the only reported case of successful endovascular relining of a completely thrombosed endograft. In particular this case demonstrated the feasibility of endovascular rescue by kissing covered balloon expandable stents with double renal chimneys in a patient with juxtarenal stent graft occlusion and several comorbidities, which made him unfit for open surgery as well as for lysis.

### CONCLUSION

Complete EVAR graft body and bilateral limb thrombosis is a challenging situation, especially in patients at high risk of open surgery and lysis. The present case shows how endovascular recanalisation by a combined antegrade and retrograde approach followed by kissing balloon expandable stents may be an effective option.

### CONFLICTS OF INTEREST

None.

### FUNDING

None.

### REFERENCES

- 1 Perini P, Bianchini Massoni C, Azzarone M, Ucci A, Rossi G, Gallitto E, et al. Significance and risk factors for intraprostatic mural thrombus in abdominal aortic endografts: a systematic review and meta-analysis. *Ann Vasc Surg* 2018;**53**:234–42.
- 2 Taudorf M, Jensen LP, Vogt KC, Grønvald J, Schroeder TV, Lönn L. Endograft limb occlusion in EVAR: iliac tortuosity quantified by three different indices on the basis of preoperative CTA. *Eur J Vasc Endovasc Surg* 2014;**48**:527–33.
- 3 Mantas GK, Antonopoulos CN, Sfyroeras GS, Moulakakis KG, Kakisis JD, Mylonas SN, et al. Factors predisposing to endograft limb occlusion after endovascular aortic repair. *Eur J Vasc Endovasc Surg* 2015;**49**:39–44.
- 4 Perini P, de Troia A, Tecchio T, Azzarone M, Bianchini Massoni C, Salcuni P, et al. Infrarenal endograft clamping in late open conversions after endovascular abdominal aneurysm repair. *J Vasc Surg* 2017;**66**:1048–55.

- 5 Botsios S, Bausback Y, Piorkowski M, Werner M, Branzan D, Scheinert D, et al. Late open conversion after endovascular aneurysm repair. *Interact Cardiovasc Thorac Surg* 2014;**19**: 622–6.
- 6 Alder L, Al-Jarrah Q, Rahi MA, Wilde N, Al-Khaffaf H. Percutaneous catheter-directed thrombolysis for treatment of complete body and bilateral limb endovascular aortic graft occlusion. *EJVES Extra* 2012;**6**:37–8.
- 7 Thurley P, Glasby M, Pollock J, Bungay P, De Nunzio M, El-Tahir AM, et al. Endovascular management of delayed complete graft thrombosis after endovascular aneurysm repair. *Cardiovasc Intervent Radiol* 2010;**33**:840–3.
- 8 Waiting J, Dias A, Patel T, Pencavel T, Rosenfeld K, Sarin S. Successful thrombolysis of a late acute thrombotic occlusion of an aortic prosthesis after endovascular aneurysm repair. *Ann Vasc Surg* 2014;**28**:1791–4.