



## Review

# A review of evidence-based clinical practice on fascia iliaca compartment block for lower limb injury

Fantahun Tarekegn<sup>\*</sup>, Amanuel Sisay

Department of Anesthesia, Bahir Dar University, Ethiopia

## ARTICLE INFO

## Keywords:

Anesthesia  
Fascia iliaca compartment block  
Femur shaft surgery  
Hip surgery  
Knee surgery

## ABSTRACT

**Background:** The main objective of this study was to resolve fascia iliaca compartment block controversies by putting the currently available evidences applied for knee, femoral shaft, and hip bone injury or related to surgery.

**Methods:** The databases PubMed, Cochrane Review, and Google Scholar were searched without regard to language or publication type for fascia iliaca compartment block before December 2020. After eligibility sorting and duplicate removal, a total of 26,609 articles were identified, with 21 of them being included for review.

**Discussion:** In the emergency department, fascia iliaca compartment block (FICB) has now become the standard of practice. Various evidence suggested that 20–40 ml of local anesthetic was required for an effective block in adult patients.

**Conclusion:** For the knee, femoral bone, and hip region surgery, the fascia iliaca compartment block (FICB) provided better anesthesia quality, reduced systemic morphine consumption, and had fewer complications than epidural anesthesia. Anesthetists and surgical department staff should promote the FICB's benefits by emphasizing its superiority in pain management.

## 1. Background

Dalens et al. developed the fascia iliaca compartment block (FICB) in the pediatric population under general anesthesia to block the three major lumbar plexus nerves of the thigh [1,2]. It is also mentioned as an alternative to Winnie et al.'s 3-in-1 block technique for lumbar plexus nerves [2,3]. The fascia iliaca compartment block is a triangular space formed by the inner aspect of the fascia iliaca and the outer aspects of the iliacus muscle. It is attached to the vertebral column with the upper parts of the sacrum, and laterally to the inner lip of the iliac crest where it is firmly attached [1–4].

Several anesthesia providers tout the benefits of the fascia iliaca compartment block (FICB) technique, which is farther away from the femoral neurovascular structure, reducing the chances of intravascular or intraneural injection [1,2,4]. FICB can be performed using an ultrasound-guided technique [5–8] or a land mark technique with certain adjustments made by guiding the cannula to the cranial region [9–11]. It also relies on the use of a continuous infusion catheter [6,8,9,12].

When a single bolus local anesthetic is injected into the

compartment's triangular-shaped space, the lumbar plexus of the femoral, lateral cutaneous nerve of the thigh, and obturator nerves are paralyzed [3,4]. Even though it is uncommon, some groups of patients experienced coverage of the genitofemoral nerve using local anesthetic diffusion [4]. FICB is intended to provide adequate pain relief with less complication than systemic analgesics, particularly in the elderly population [13,14]. It has also a greater anesthetic effect than systemic analgesics and fewer complications than epidural anesthesia [3]. FICB has significant morphine sparing effect after total hip arthroplasty, according to a randomized controlled trial study [15]. However, another double-blind randomized control trial found that the FICB had no effect on narcotic usage or pain levels after immediate total hip replacement surgery [16].

The main objective of this study was to resolve fascia iliaca compartment block controversies by putting the currently available proofs of this block that applied for knee, femoral shaft, and hip bone injury or related to surgery.

<sup>\*</sup> Corresponding author.

E-mail address: [medeset39@gmail.com](mailto:medeset39@gmail.com) (F. Tarekegn).

<https://doi.org/10.1016/j.amsu.2021.102758>

Received 19 July 2021; Received in revised form 22 August 2021; Accepted 22 August 2021

Available online 23 August 2021

2049-0801/© 2021 Published by Elsevier Ltd on behalf of IJS Publishing Group Ltd. This is an open access article under the CC BY license

(<http://creativecommons.org/licenses/by/4.0/>).

## 2. Methods

### 2.1. Protocol and registration

This review’s protocol has been registered with the registry of systematic reviews under the unique identifier (UIN): reviewregistry985. The systematic review study, on the other hand, did not necessitate ethical approval from the ethical review board committee. This review study was carried out following the PRISMA (Fig. 1) and AMSTAR2 guidelines for fascia iliaca compartment block before December 2020.

### 2.2. Eligibility criteria

Eligibility studies included randomized or non-randomized controlled trials that enrolled patients of any age group with knee, femoral shaft, or hip fractures or surgeries. FICB in all forms was included (single dose or continuous catheter infusion, different types, and doses of local anesthetics). Our review did not include any case report studies.

This systematic review has been reported in line with the Preferred Reporting item for Systematic Review and Meta-analysis (PRISMA) [17] and AMSTAR (Assessing the methodological quality of systematic reviews) guidelines [18].

### 2.3. Information sources and search

A literature search was conducted using the PubMed, Cochrane Review, and Google Scholar databases, with no language or publication type restrictions as described in Fig. 1. Keywords and the Boolean operators “AND” and “OR” were used to perform free-text keyword

searches. These were the following combinations: (hip fracture OR hip surgery OR femur fracture OR femur surgery OR knee fracture OR knee surgery) AND (Fascia iliaca block OR Fascia iliaca nerve block OR Fascia iliaca compartment block OR FICB OR FIC OR FIB). Abstracts were reviewed in the middle of the extracted citations to recoup the clinical studies of fascia iliaca compartment block. In addition, the investigator double-checked references to ensure that no articles were missing. As a result, the reference lists of all articles were double-checked using the full text and a similar review using the title and abstract.

### 2.4. Data collection process

The two reviewers considered all relevant data from eligible studies’ full texts. One reviewer (F.T.) extracted the data, and a second reviewer (A.S.) independently checked the comprehensiveness by reading the full-text article. Disagreements between the two researchers were resolved through discussion and, if necessary, by the settlement of a senior researcher.

## 3. Discussion

### 3.1. Fascia iliaca compartment block

#### 3.1.1. Indication, contraindication and complications

The lumbar plexus block is the most widely used technique for providing analgesia or surgical anesthesia to the lower limb following knee, femoral shaft, or hip surgery [3,4,19,20]. It is also approved for the treatment of acute pain in fracture and burn patients admitted to the facility. FICB appeared to be an effective and relatively safe adjunct to perioperative pain management of femoral and hip fractures, according

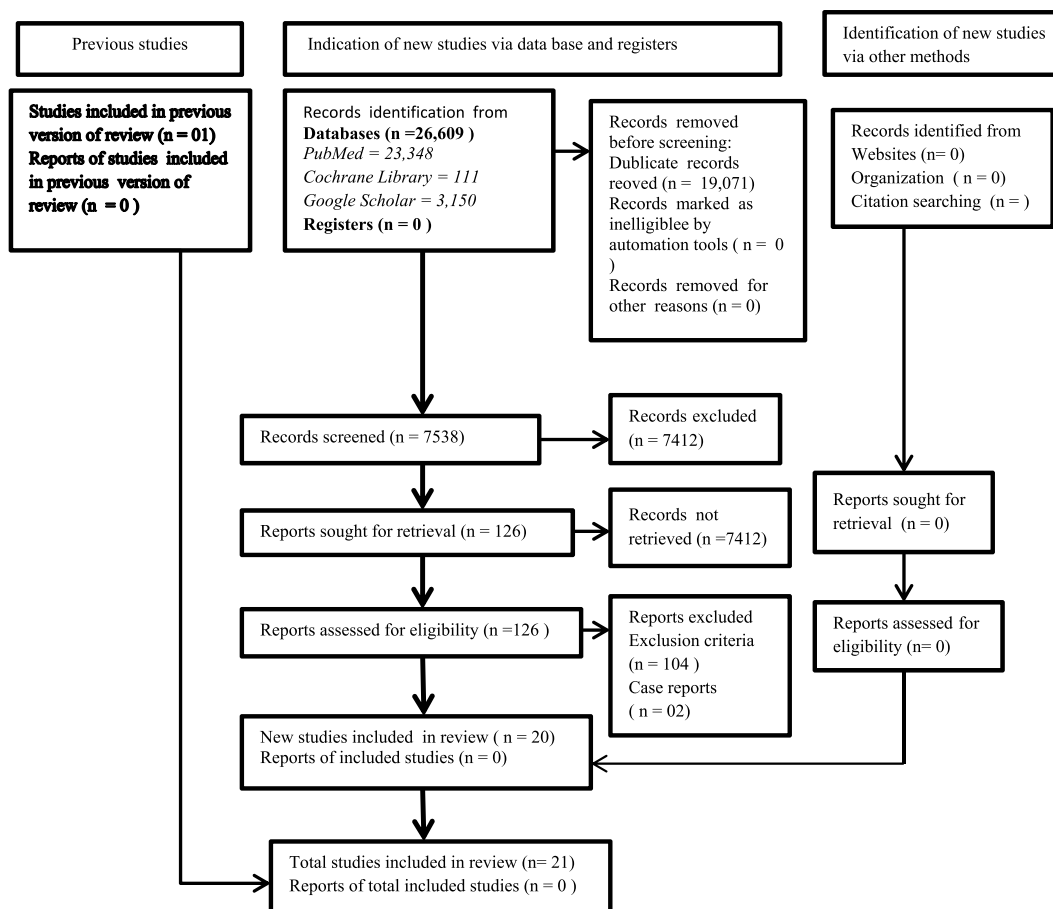


Fig. 1. The search strategy with the form of preferred reporting items for systematic review and meta-analysis (PRISMA) flow diagram.

to a systematic review and meta-analysis research [21–23]. FICB is used for preoperative, intraoperative, and postoperative analgesia after femur, knee, and hip fractures or surgery. Pre-existing femoral bypass surgery, patient refusal, allergy to local anesthetics, and infection at the block site are all contraindications. Furthermore, patients with coagulopathy, peripheral neuropathy, or neurological conditions are among the related contraindications. Local anesthetic toxicity, block failure, hematoma and quadriceps weakness, peritoneal organ perforation, and bladder puncture are all complications to this procedure [24].

### 3.1.2. Safety profile

The fascia iliaca compartment block technique has less complications than epidural and subarachnoid block therapies because it is easier to perform and explain the procedure [2,4,20,25,26]. Although the FICB is further away from the femoral vessels, there is a low risk of local anesthetic toxicity.

### 3.1.3. Anatomy

The fascia iliaca compartment is a latent space located above the upper thigh's inguinal region. It contains the three major lumbar plexus nerves of the femoral, lateral cutaneous nerve of the thigh, and obturator nerves [27,28]. The lateral cutaneous and thigh femoral nerves, on the other hand, are located beneath the fascia iliaca. The majority of the hip surgery incision is innervated by the lateral femoral cutaneous nerve [29].

The FICB's goal was to block the sensory supply and deeper femoral nerves in the thigh, knee, and hip region. Therefore, because of the extensive distribution of sensory innervation in the lower extremity, this block has been initiated to be used for pain management during knee arthroplasty and hip procedures [30].

### 3.1.4. Block techniques

**3.1.4.1. Ultrasound technique.** The FICB ultrasound technique is important for monitoring needle placement, avoiding dangerous structures, and ensuring proper anesthetic placement, as well as assisting with local anesthetic diffusion for sensory nerve blockage [29].

**3.1.4.2. Landmark technique.** FICB is recognized as a quick and relatively simple block to run through the anatomical landmarks technique. It was utilized before the advent of ultrasound and is still beneficial in low-income nations with limited resources of ultrasound and peripheral nerve stimulators.

Anatomical landmarks include the inguinal ligament, anterior superior iliac spine (ASIS), and pubic tubercle. The patient should be positioned supine, and a line drawn in thirds from the ASIS to the pubic tubercle should be drawn. 1 cm caudal to the lateral one-third and medial two-thirds intersection is where the injection is delivered. A 60-degree cranial angle is created by inserting a blunt, short bevel needle perpendicular to the skin. As the needle goes through the fascia lata, a 'give' or POP may be felt, followed by another give as it passes through the fascia iliaca. The local anesthetic should be injected without experiencing any resistance. If resistance develops, gently pull the needle and repeat the process after more aspiration [29,30]. After that, either an ultrasonic technique is utilized to establish a catheter for continuous infusion or a landmark technique is used to place a local anesthetic solution using a "single-shot" of typically 30–40 ml [24].

### 3.1.5. The dose of local anesthetic and implication to practice

The type, amount, and concentrations of local anesthetic agents played a critical role in the proper blockage of sensory and motor nerves. Various evidences suggested that 20–40 ml of local anesthetic was required for an effective block in adult patients. Other references revealed that the bolus dose calculation was based on the patient's weight, with (20 ml for 50 kg, 25 ml for 50–70 kg, and 30 ml for >70 kg)

[30]. In clinical practice, 0.7 ml/kg is commonly used in children. In terms of concentrations, 0.5% or 0.25% Bupivacaine and Ropivacaine were used as a bolus injection. FICB success rates ranged from 67% in junior anesthetists [20] to greater than 90% in skilled senior anesthetists [2,4,29]. The FICB procedure is carried out using aseptic or semi-sterile techniques while wearing sterile gloves, caps, and masks.

### 3.1.6. Evidence

In preliminary trials, the fascia iliaca compartment block (FICB) was found to have a higher rate of success than the 3 in 1 block in both children and adults. Local anesthetic distribution, on the other hand, was varied and inconsistent, with no one block providing sensory anesthesia in three nerves in more than 38% of patients [2,4]. Emerging anatomical, radiological, and clinical research has shown the infrainguinal technique's weaknesses. However, in instances where ultrasonography cannot be utilized due to a lack of equipment or experience, this technique is still useful. With the advent of ultrasound, a new suprainguinal fascia iliaca approach has been described [31].

In a randomized control trial comparing ultrasound guided suprainguinal FICB with placebo in patients having total hip replacement, success rates of obturator nerve blockage and blockade of all three nerves were 86% and 67%, respectively [32]. Furthermore, a recent cadaver study found that the femoral nerve, lateral cutaneous nerve of the thigh, and obturator nerve could all be successfully blocked with ultrasound-guided suprainguinal FICB, but only if 40 ml of local anesthetic was injected [33].

### 3.1.7. Provision of fascia iliaca compartment block

In the emergency department, FICB has now become the standard of practice [34]. Unfortunately, in our nation, Ethiopia, the practice is still underutilized. The most prominent causes for FICB's lack of over-all implementation include a shortage of qualified staff and equipment, as well as procedural time and doubt about the fascia iliaca compartment block's efficacy. To address these issues, many departments have chosen to train practitioners to provide care in the emergency department. The FICB training can be performed for others unit undersupervision of anesthesia department [35]. Prehospital settings may be included [36].

This study had certain limitations that should be mentioned. To begin with, there was no consideration of publication bias in our review. Furthermore, several analytic parameters comprised a small sample size due to variances in the study directions of the authors of the included papers.

## 4. Conclusion and recommendation

We discussed the indications, contraindications, complications, safety profile, anatomy, techniques, and the implications of a suggested dose of fascia iliaca compartment block in clinical practice with pain management of various surgical interventions in our review.

Furthermore, as compared to epidural anesthesia for knee, femoral bone, or hip region surgery, the FICB produced higher anesthetic quality, lowered systemic morphine consumption, and had fewer complications. According to various studies, a successful block in adult patients requires 20–40 mL of local anesthetic.

The landmark technique was particularly suited to resource-limited settings such as countries without access to ultrasound or peripheral nerve stimulator materials due to its ease of use and low complication rate. As a result, anesthetists and surgical department staff should advertise the FICB's advantages.

### Declaration of competing interest

All authors declared that we have not any competing interests.

## Abbreviations

AMSTAR	Assessing the methodological quality of systematic reviews
FIB	Fascia Iliaca Block
FIC	Fascia Iliaca Compartment
FICB	Fascia Iliaca Compartment Block
Kg	Killogram
PRISMA	Preferred Reporting Item for Systematic Review and Meta-analysis
UIN	Unique Identifying Number

## Availability of data and materials

No additional data are required; all information was presented in the main manuscript.

## Funding

We do not receive a grant from any source.

## Ethical approval

Not applicable since it was a systematic review study.

## Consent

Not applicable.

## Author contribution

1. Fantahun Tarekegn: make substantial contributions to conception and design, and/or acquisition of data, and/or analysis and interpretation of data;
2. Amanuel Sisay: participate in drafting the article or revising it critically for important intellectual content

## Registration of research studies

1. Name of the registry: Research Registry
2. Unique Identifying number or registration ID: reviewregistry985
3. Hyperlink to your specific registration (must be publicly accessible and will be checked): <https://www.researchregistry.com/>

## Guarantor

Fantahun Tarekegn, corresponding author of the study.

## References

- [1] S.K. Parkinson, et al., Extent of blockade with various approaches to the lumbar plexus, *Anesth. Analg.* 68 (3) (1989) 243–248.
- [2] B. Dalens, G. Vanneuville, A. Tanguy, Comparison of the fascia iliaca compartment block with the 3-in-1 block in children, *Anesth. Analg.* 69 (6) (1989) 705–713.
- [3] S.D. Waldman, *Atlas of Interventional Pain Management E-Book*, Elsevier Health Sciences, 2014.
- [4] X. Capdevila, et al., Comparison of the three-in-one and fascia iliaca compartment blocks in adults: clinical and radiographic analysis, *Anesth. Analg.* 86 (5) (1998) 1039–1044.
- [5] L. Haines, et al., Ultrasound-guided fascia iliaca compartment block for hip fractures in the emergency department, *J. Emerg. Med.* 43 (4) (2012) 692–697.
- [6] A.J. Mangram, et al., Geriatric trauma G-60 falls with hip fractures: a pilot study of acute pain management using femoral nerve fascia iliac blocks, *J. Trauma Acute Care Surg.* 79 (6) (2015) 1067–1072.
- [7] J.D. Swenson, et al., Local anesthetic injection deep to the fascia iliaca at the level of the inguinal ligament: the pattern of distribution and effects on the obturator nerve, *J. Clin. Anesth.* 27 (8) (2015) 652–657.
- [8] E. Dulaney-Cripe, et al., A continuous infusion fascia iliaca compartment block in hip fracture patients: a pilot study, *J. Clin. Med. Res.* 4 (1) (2012) 45.
- [9] D. Rashwan, Levobupivacaine patient controlled analgesia: epidural versus blind fascia iliaca compartment analgesia—A comparative study, *Egypt. J. Anaesth.* 29 (2) (2013) 155–159.
- [10] D. Lees, et al., Fascia iliaca compartment block for hip fractures: experience of integrating a new protocol across two hospital sites, *Eur. J. Emerg. Med.* 23 (1) (2016) 12–18.
- [11] E. Dochez, et al., Prehospital administered fascia iliaca compartment block by emergency medical service nurses, a feasibility study, *Scand. J. Trauma Resuscitation Emerg. Med.* 22 (1) (2014) 1–7.
- [12] M. Temelkovska-Stevanovska, et al., Continuous femoral nerve block versus fascia iliaca compartment block as postoperative analgesia in patients with hip fracture, *Priilozi* 35 (2) (2014) 85–93.
- [13] A. Chesters, P. Atkinson, Fascia iliaca block for pain relief from proximal femoral fracture in the emergency department: a review of the literature, *Emerg. Med. J.* 31 (e1) (2014) e84–e87.
- [14] S. Pinson, Fascia Iliaca (FICB) block in the emergency department for adults with neck of femur fractures: a review of the literature, *Int. Emerg. Nurs.* 23 (4) (2015) 323–328.
- [15] M. Stevens, G. Harrison, M. McGrail, A modified fascia iliaca compartment block has significant morphine-sparing effect after total hip arthroplasty, *Anaesth. Intensive Care* 35 (6) (2007) 949–952.
- [16] K. Bober, et al., Pain control after total hip arthroplasty: a randomized controlled trial determining efficacy of fascia iliaca compartment blocks in the immediate postoperative period, *J. Arthroplasty* 35 (6) (2020) S241–S245.
- [17] M.J. Page, et al., The PRISMA 2020 statement: an updated guideline for reporting systematic reviews, *BMJ* (2021) 372.
- [18] B.J. Shea, et al., Amstar 2: a critical appraisal tool for systematic reviews that include randomised or non-randomised studies of healthcare interventions, or both, *BMJ* 358 (2017) j4008.
- [19] D. Tran, A. Clemente, R.J. Finlayson, A review of approaches and techniques for lower extremity nerve blocks, *Can. J. Anesth.* 54 (11) (2007) 922.
- [20] N.B. Foss, et al., Fascia iliaca compartment blockade for acute pain control in hip fracture patients: a randomized, placebo-controlled trial, *Anesthesiology: J. Am. Soc. Anesthesiol.* 106 (4) (2007) 773–778.
- [21] J. Steenberg, A. Møller, Systematic review of the effects of fascia iliaca compartment block on hip fracture patients before operation, *Br. J. Anaesth.* 120 (6) (2018) 1368–1380.
- [22] L. Yang, et al., Fascia iliaca compartment block versus no block for pain control after lower limb surgery: a meta-analysis, *J. Pain Res.* 10 (2017) 2833.
- [23] H.-k. Hong, Y. Ma, The efficacy of fascia iliaca compartment block for pain control after hip fracture: a meta-analysis, *Medicine* 98 (28) (2019).
- [24] N. O'Reilly, M. Desmet, R. Kearns, Fascia iliaca compartment block, *Bja Education* 19 (6) (2019) 191–197.
- [25] J. Candal-Couto, et al., Pre-operative analgesia for patients with femoral neck fractures using a modified fascia iliaca block technique, *Injury* 36 (4) (2005) 505–510.
- [26] D.G. Monzon, K.V. Iserson, J.A. Vazquez, Single fascia iliaca compartment block for post-hip fracture pain relief, *J. Emerg. Med.* 32 (3) (2007) 257–262.
- [27] A. Høgh, et al., Fascia iliaca compartment block performed by junior registrars as a supplement to pre-operative analgesia for patients with hip fracture, *Strat. Trauma Limb Reconstr.* 3 (2) (2008) 65–70.
- [28] S. Diwan, Fascia iliaca block—an anatomical and technical description, *J. Anaesth. Crit. Care Case Reports* 1 (1) (2015) 27–30.
- [29] J. Dolan, et al., Ultrasound guided fascia iliaca block: a comparison with the loss of resistance technique, *Reg. Anesth. Pain Med.* 33 (6) (2008) 526–531.
- [30] H. Nie, et al., Effects of continuous fascia iliaca compartment blocks for postoperative analgesia in patients with hip fracture, *Pain Res. Manag.* 20 (2015).
- [31] M. Desmet, A.L. Balocco, V. Van Belleghem, Fascia iliaca compartment blocks: different techniques and review of the literature, *Best Pract. Res. Clin. Anaesthesiol.* 33 (1) (2019) 57–66.
- [32] M. Desmet, et al., A longitudinal supra-inguinal fascia iliaca compartment block reduces morphine consumption after total hip arthroplasty, *Reg. Anesth. Pain Med.* 42 (3) (2017) 327–333.
- [33] K. Vermeylen, et al., The effect of the volume of supra-inguinal injected solution on the spread of the injectate under the fascia iliaca: a preliminary study, *J. Anesth.* 32 (6) (2018) 908–913.
- [34] G. SIGN, *Scottish Intercollegiate Guidelines Network (SIGN)*. Management of attention deficit and hyperkinetic disorders in children and young people, *Nat. Clin. Guideline* (2009) 112.
- [35] A.o.A.o.G. Britain, I.R. Anaesthesia-UK, *Fascia Iliaca Blocks and Non-physician Practitioners*, 2013.
- [36] P.J. McRae, et al., Paramedic-performed fascia iliaca compartment block for femoral fractures: a controlled trial, *J. Emerg. Med.* 48 (5) (2015) 581–589.