

Endovascular and Surgical Treatment of Spinal Dural Arteriovenous Fistulas: Assessment of Post-treatment Clinical Outcome

Panagiotis ZOGOPOULOS,¹ Hajime NAKAMURA,¹ Tomohiko OZAKI,¹
Katsunori ASAI,¹ Hiroyuki IMA,¹ Tomoki KIDANI,¹ Yoshinori KADONO,¹
Tomoaki MURAKAMI,¹ Toshiyuki FUJINAKA,^{1,2} and Toshiki YOSHIMINE¹

¹Department of Neurosurgery, Osaka University Graduate School of Medicine, Suita, Osaka;

²Department of Neurosurgery, Osaka National Hospital, Osaka, Osaka

Abstract

Spinal dural arteriovenous fistulas (DAVFs) are the most commonly encountered vascular malformation of the spinal cord and a treatable cause of progressive para- or tetraplegia. It is an elusive pathology that tends to be under-diagnosed, due to lack of awareness among clinicians, and affects males more commonly than females, typically between the fifth and eighth decades. Early diagnosis and treatment may significantly improve outcome and prevent permanent disability and even mortality. The purpose of our retrospective, single-center study was to determine the long-term clinical and radiographic outcome of patients who have received endovascular or surgical treatment of a spinal DAVF. In particular, during a 6-year period (2009–2014) 14 patients with a spinal DAVF were treated at our department either surgically (n = 4) or endovascularly (n = 10) with detachable coils and/or glue. There was no recurrence in the follow-up period (mean: 36 months, range 3–60 months) after complete occlusion with the endovascular treatment (n = 9; 90%), while only one patient (10%) had residual flow both post-treatment and at 3-month follow-up. All four surgically treated patients (100%) had no signs of residual DAVF on follow-up magnetic resonance angiography (MRA) and/or angiography (mean follow-up period of 9 months). Since improvement or stabilization of symptoms may be seen even in patients with delayed diagnosis and substantial neurological deficits, either endovascular or surgical treatment is always justified.

Key words: spinal dural arteriovenous fistula, endovascular treatment, surgical treatment, recurrence, clinical outcome

Introduction

Spinal arteriovenous shunts occur with direct communication between the arterial and venous system of the spinal cord. Spinal dural arteriovenous fistulas (DAVFs) are the most commonly encountered vascular malformation of the spinal cord and a treatable cause of progressive para- or tetraplegia.

The purpose of our retrospective, single-center study was to determine the long-term clinical and radiographic outcome of patients who have undergone treatment of a spinal DAVF either surgically or endovascularly with detachable coils and/or glue. We also examined epidemiologic characteristics of the patients and DAVF characteristics as possible

prognostic factors of post-treatment clinical and radiographic outcome.

Materials and Methods

Fourteen patients with spinal DAVF were treated at our department during a 6-year period (2009–2014). The patients, 12 men (86%) and 2 women (14%) with mean age of 62.1 years (range: 42–74 years), presented with gradually deteriorating motor and sensory disturbances of the lower extremities (muscle weakness and numbness), while 2 patients had also sphincter dysfunction. Two patients presented with muscle weakness of the upper extremities alone and another patient with sudden onset of motor and sensory disturbances of all four extremities due to a cervical spinal DAVF rupture that caused an intramedullary hemorrhage. The duration of symptoms

before diagnosis ranged from 1 month to 36 months (mean value: 13.5 months). All patients underwent magnetic resonance imaging (MRI) and spinal angiography, which demonstrated the pathological vascular fistula. Based on the imaging characteristics of the spinal DAVF in each case (anatomy and location of the lesion, feeding and draining vessels complexity, and potential difficulties in surgical approach), the most appropriate treatment modality (surgical or endovascular) was chosen. Thus, interruption of the DAVF was achieved by endovascular embolization (n = 10), by surgical ligation (n = 3) or combination of those (n = 1) (Table 1).

Age, sex, and localization of the fistula were examined as independent variables for their relevance with post-treatment clinical outcome (modified Rankin scale, mRS) and radiographic recurrence [conventional angiography, magnetic resonance angiography (MRA)]. Duration of symptoms until diagnosis and treatment, as well as, post-treatment complication rates were also evaluated. Statistical analysis was performed using Student's t-test or analysis of variance (ANOVA), and statistical significance (p) was set at 0.05.

Results

I. Endovascular and surgical treatment

In all 10 patients of the endovascular treatment group, the transarterial route was used. A total of eight patients were treated in one session, two sessions were needed in one patient and three sessions in another patient. Coils, n-butyl-2-cyanoacrylate (NBCA) or their combination was chosen based on DAVF characteristics (location, size, complexity). Two patients were treated with embolization with coils, three patients with combined embolization with coils and NBCA, while four patients with NBCA alone. The patient who required three sessions of embolization was treated with NBCA at the first session, combination of coils and NBCA at the second, and coils alone at the third session (Fig. 1). Finally, one patient required surgical ligation of his spinal DAVF due to a remaining flow after one session of endovascular embolization with NBCA. Another three patients underwent surgical interruption of their DAVF without prior endovascular treatment.

The distribution of spinal DAVFs according to their localization, among the surgically treated patients was as follows: cervical (n = 1), thoracic (n = 1), thoracolumbar (n = 1), and lumbosacral (n = 1). The distribution of spinal DAVFs according to their localization, among the endovascularly treated patients was: cervical (n = 1), thoracic (n = 5), thoracolumbar (n = 3), and sacral (n = 1) (Fig. 2).

II. Complications

One patient (case N:1), treated with endovascular coil embolization, presented a transient deterioration of lower extremity weakness, although there was no radiographic evidence of post-treatment spinal cord edema or venous thrombosis. Patient's motor function was restored after an intense rehabilitation program.

Among the surgically treated patients, one (case N:12) had to be reoperated in order to repair a post-operative cerebrospinal fluid leakage.

III. Radiographic follow-up

Our protocol of follow-up consists of an angiography 1 year after the embolization and MRI/MRA scan at 1 month, 3 months, 6 months, and 12 months after the embolization and yearly thereafter. Mean radiographic follow-up for all 14 patients was 25.5 months (range 3–60 months). All four surgically treated patients (100%) had no signs of residual DAVF on follow-up MRA and/or angiography (mean follow-up period of 9 months).

Among the 10 patients who were treated only with endovascular embolization, after a mean follow-up period of 36 months, 9 patients had no signs of recanalization on MRA (90%) and only 1 patient (10%) had small residual flow at 3-month post-embolization follow up MRA (Fig. 3). When endovascularly treated patients were distributed to groups based on their age, there was no statistically significant difference regarding radiographic recurrence. There was also no statistically significant difference regarding radiographic recurrence between males and females or among groups based on DAVF localization (cervical, thoracic, or lumbosacral spine).

IV. Clinical outcome

All surgically treated patients had successful obliteration of their spinal DAVF and stabilization (n = 2) or even improvement (n = 2) of their neurological deficits over a mean follow-up period of 9 months. Among patients of the embolization treatment group neurological stabilization (no change in mRS score), over a follow-up period of 32 months, was observed in six patients (60%), an improvement by one degree in two patients (20%), while improvement by three degrees and four degrees were each achieved by one patient (10% each) (Fig. 4). Regarding duration of symptoms before diagnosis and treatment, we found no correlation with functional outcome either at 1 month post-treatment (< 6 months vs. > 6 months, p = 0.22) (< 12 months vs. > 12 months, p = 0.14) or at 32-month (mean) follow-up (< 6 months vs. > 6 months, p = 0.90) (< 12 months vs. > 12 months, p = 0.49).

Table 1 Treatment overview

No.	Age	Sex	Localization	Treatment	Complications	Pretreatment symptoms	Post-treatment symptoms	Duration of symptoms	Pretreatment mRS	Post-treatment mRS	Follow-up mRS	Post-treatment radiography	Follow-up radiography
1	67	M	Thoracolumbar	Coils	Deterioration of lower extremity weakness	Lower extremity weakness	Lower extremity pain	6 months	5	4	1	Complete occlusion	5 years (MRI/MRA): No recanalization
2	51	M	Thoracic	Coils	None	Lower extremity numbness	Lower extremity extremity stiffness	24 months	4	3	1	Complete occlusion	5 years (MRI/MRA): No recanalization
3	59	M	Thoracolumbar	Coils + NBCA, Coils +NBCA	None	Lower extremity weakness	Lower extremity extremity weakness	12 months	3	2	3	Complete occlusion	5 years (MRI/MRA): No recanalization
4	74	M	Thoracic	NBCA	None	Lower extremity weakness	Asymptomatic	24 months	1	0	0	Complete occlusion	4 years (MRI/MRA): No recanalization
5	70	M	Thoracic	NBCA	None	Lower extremity weakness	Slight lower extremity weakness	36 months	2	1	1	Complete occlusion	4 years (MRI/MRA): No recanalization
6	61	M	Thoracic	NBCA, Coils + NBCA, Coils	None	Lower extremity weakness	Lower extremity extremity numbness	6 months	4	4	4	Complete occlusion	2 years (MRI/MRA): No recanalization
7	56	M	Thoracic	NBCA	None	Lower extremity numbness	Lower extremity extremity numbness	6 months	1	1	1	Complete occlusion	1 year (MRI/MRA): No recanalization
8	66	M	Sacral	Coils + NBCA	None	Sphincter dysfunction	Sphincter dysfunction	12 months	1	1	1	Residual flow	3 months (MRI/MRA): Residual flow
9	73	F	Cervical	NBCA	None	Four-extremity weakness	Four-extremity weakness	1 month	5	5	5	Complete occlusion	3 months (MRI/MRA): No recanalization
10	57	F	Thoracolumbar	Coils + NBCA	None	Lower extremity weakness	Lower extremity extremity numbness	2 months	1	1	1	Complete occlusion	3 months (MRI/MRA): No recanalization
11	73	M	Lumbosacral	Surgical obliteration	None	Lower extremity weakness	Lumbar pain	24 months	2	2	2	Complete obliteration	6 months (MRI/MRA): No recanalization
12	58	M	Thoracolumbar	Surgical obliteration	Post-operative CSF leakage	Sphincter dysfunction	Sphincter dysfunction	12 months	4	4	2	Complete obliteration	1 year (MRI/MRA): No recanalization
13	63	M	Thoracic	Surgical obliteration	None	Lower extremity numbness	Asymptomatic	12 months	1	0	0	Complete obliteration	1 year (MRI/MRA): No recanalization
14	42	M	Cervical	NBCA, Surgical obliteration	None	Upper extremity weakness	Upper extremity extremity weakness	9 months	1	1	1	Complete obliteration	6 months (MRI/MRA): No recanalization

GSF: cerebrospinal fluid, F: female, M: male, MRA: magnetic resonance angiography, MRI: magnetic resonance imaging, mRS: modified Rankin scale, NBCA: n-butyl-2-cyanoacrylate.

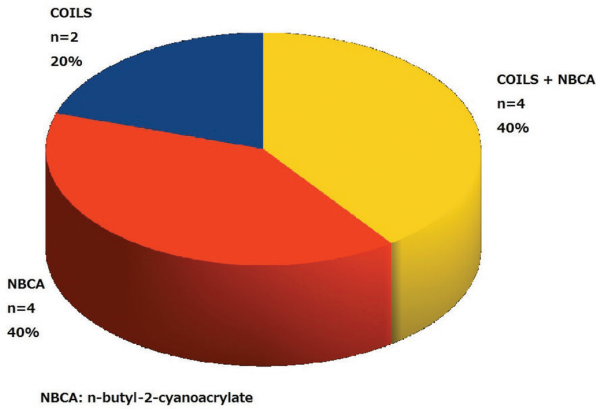


Fig. 1 Embolization material in endovascular treatment group.

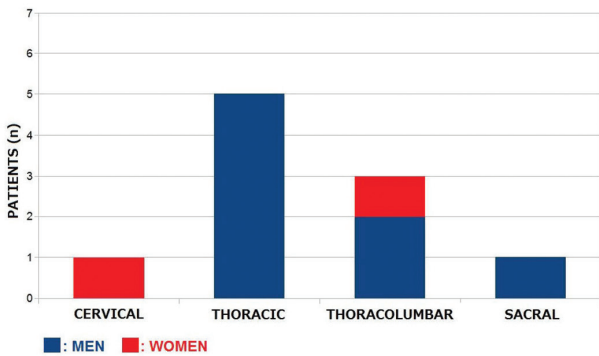


Fig. 2 Localization of endovascularly treated spinal dural arteriovenous fistula.

When patients (either surgically or endovascularly treated) were distributed to groups based on their age, there was no statistically significant difference in clinical outcome (mRS score) either at 1-month or at 32-month (mean) follow-up. There was also no statistically significant difference regarding clinical outcome (mRS score) between males and females or among groups based on DAVF localization (cervical, thoracic, or lumbosacral spine) or when comparing endovascularly versus surgically treated groups, either at 1-month or at 32-month (mean) follow-up. Regarding patients with severe disability (mRS score 4 and 5) half of them (endovascular group) had post-treatment clinical improvement in terms of extremity muscle strength, while the sole patient of the surgical group (who presented with sphincter dysfunction) also improved significantly.

Discussion

Although spinal DAVFs are relatively uncommon lesions, they are clinically important because they

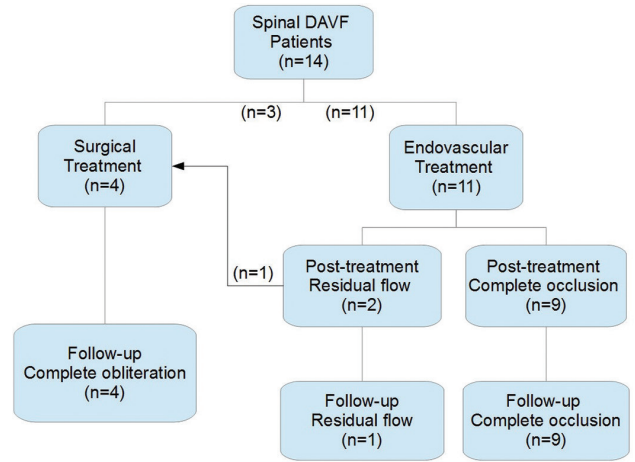


Fig. 3 Radiographic follow-up. DAVF: dural arteriovenous fistula.

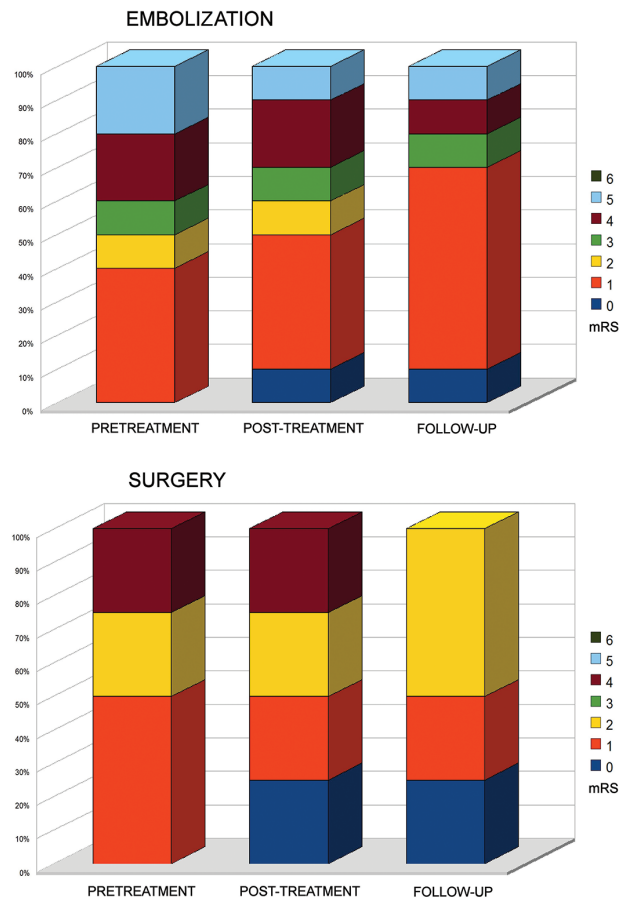


Fig. 4 Clinical outcome—Modified Rankin Scale.

can produce neurological symptoms caused by hemorrhage, ischemia, and mass effect, leading to significant neurological morbidity.¹⁻³⁾ MRI findings are not specific for this diagnosis, but if the clinical course and characteristic MRI findings suggest

the possibility of spinal DAVF, selective spinal angiography is indicated since it is the definitive diagnostic procedure.⁴⁾

Therapy has to be aimed at occluding the shunting zone, either by superselective embolization with a liquid embolic agent and/or coils or by a neurosurgical approach. Following occlusion of the fistula (either surgically or endovascularly), the progression of the disease can be stopped and improvement of symptoms is typically observed.^{1,5)}

Microsurgical closure of the arteriovenous fistula provides long-lasting obliteration of the fistula with almost no risk of recurrence.^{6,7)} Only a few minor complications have been reported, such as accumulation of cerebrospinal fluid, wound-healing impairment, epidural hematoma, and venous thrombosis.⁸⁾ Surgery is indicated if a spinal cord artery shares the same pedicle as the feeder of the spinal DAVF, if endovascular treatment is difficult or dangerous (as in a severe atherosclerotic disease), and after an unsuccessful embolization.⁹⁾

Cure can be obtained by embolization if NBCA is used.¹⁰⁾ The endovascular treatment may be performed in the course of the diagnostic angiogram with a simple technique and without general anesthesia, permitting a short hospital stay and incurring low costs. Nevertheless, it is only efficient if the injection of glue includes the distal feeding artery, the shunt itself, and the initial part of the draining vein. In the series of Merland et al., 31 of 45 patients (69%) showed successful occlusion of the draining vein.¹⁰⁾ Follow-up angiography is the only way to confirm a definitive cure. The best time for this after embolization remains questionable, but has been suggested to be from 15 days to 2 months later.¹¹⁾ Apart from angiography, when the post-embolization computed tomography (CT) shows the presence of NBCA inside the dura mater, it also indicates a complete cure.¹¹⁾

Several factors may render endovascular embolization of a spinal DAVF ineffective/incomplete such as: difficulty in advancing the catheter in the proper position, partial embolization of a complex DAVF, inappropriate glue injection, migration of coils, deliberate preservation of normal spinal vessels that may participate in the DAVF and finally, new anastomosis from the adjacent level of radicular artery.

Although in previous reports prolonged duration of symptoms and poor functional status at diagnosis and treatment were described as negative prognostic factors of clinical outcome,^{12–15)} in our series no such correlation was observed (however, our series contains only 14 patients, due to the rarity of the disease, which could affect statistical analysis).

In accordance with our results, Fugate et al. have also reported that improvement or stabilization of symptoms may be seen even in patients with delayed diagnosis and substantial neurological deficits therefore, treatment is always justified.¹⁵⁾ We have also found that age and sex of the patients, as well as localization of spinal DAVF do not seem to correlate with clinical outcome or radiographic recurrence, as has been also previously reported,^{12,13,16)} although in a previous report by Cenzato et al., patients with spinal DAVFs at the thoracic level, and in particular at the lower level, responded better than those in other spinal areas.¹⁴⁾

The number of cases in our series is indeed small (due to the rarity of this disease per se and to careful selection of patients) and the follow-up period was different between two groups, but even so the high success rate achieved with endovascular embolization managed to prove it, maybe not superior, but at least equally effective and safe to surgical treatment. Although, there is still no concrete evidence supporting that endovascular embolization of spinal DAVFs is superior to surgical treatment (a recently published meta-analysis concluded that primary surgical treatment of spinal DAVFs was superior to endovascular embolization regarding initial failure rate and late recurrences)¹⁷⁾ there is an increasing tendency worldwide to treat them endovascularly. Careful selection of patients, treatment by an experienced team, and the development of new materials and techniques in the future could establish the superiority of endovascular embolization over surgical treatment.

Conclusion

Spinal DAVF is a rare and elusive pathology that tends to be under-diagnosed, due to lack of awareness among clinicians, leading to severe disability and even death. It affects males more commonly than females, typically between the fifth and eight decades,¹²⁾ as was also found in our series. However, age and sex of the patient, as well as localization of the spinal DAVF do not seem to affect post-treatment clinical outcome, neither do they correlate with the probability of radiographic recurrence. Surgical interruption of the DAVF seems to offer a complete cure in select, difficult cases with very low complication rates. Likewise, endovascular embolization is also an efficient and safe treatment modality with very high success rates (90% in our series). Although in the past surgical treatment was believed to be superior to the endovascular one, we have shown here that endovascular embolization of spinal DAVFs can

be equally effective (and significantly less invasive) when applied by an experienced team and to carefully selected patients. The follow-up period was indeed different to great extent among groups in our series (9 months for surgical group and 32 months for endovascular group), so we cannot compare the long-term effectiveness of endovascular versus surgical treatment, but our findings show that endovascular embolization seems to be effective even after a significantly long period.

The history, neurological findings, and radiological changes on MRI scan should alert clinicians to the possibility of spinal DAVF, leading to diagnostic spinal angiography. Treatment should be attempted as soon as the diagnosis is established, even in patients with long-lasting symptoms, to avoid rupture-associated morbidity and mortality. Further studies including more patients are required to definitively determine possible prognostic factors.

Conflicts of Interest Disclosure

The authors declare that there are no conflicts of interest.

References

- 1) Clarke MJ, Patrick TA, White JB, Cloft HJ, Krauss WE, Lindell EP, Piepgras DG: Spinal extradural arteriovenous malformations with parenchymal drainage: venous drainage variability and implications in clinical manifestations. *Neurosurg Focus* 26: E5, 2009
- 2) Sharma RR, Selmi F, Cast IP, O'Brien C: Spinal extradural arteriovenous malformation presenting with recurrent hemorrhage and intermittent paraplegia: case report and review of the literature. *Surg Neurol* 42: 26–31, 1994
- 3) Chen CJ, Huang CC, Hsu YY, Hsu WC: Small isolated paraspinal arteriovenous fistula. *AJNR Am J Neuroradiol* 18: 359–361, 1997
- 4) Jones BV, Ernst RJ, Tomsick TA, Tew J Jr: Spinal dural arteriovenous fistulas: recognizing the spectrum of magnetic resonance imaging findings. *J Spinal Cord Med* 20: 43–48, 1997
- 5) Krings T, Geibprasert S: Spinal dural arteriovenous fistulas. *AJNR Am J Neuroradiol* 30: 639–648, 2009
- 6) Lee TT, Gromelski EB, Bowen BC, Green BA: Diagnostic and surgical management of spinal dural arteriovenous fistulas. *Neurosurgery* 43: 242–246; discussion 246–247, 1998
- 7) Watson JC, Oldfield EH: The surgical management of spinal dural vascular malformations. *Neurosurg Clin N Am* 10: 73–87, 1999
- 8) Huffmann BC, Gilsbach JM, Thron A: Spinal dural arteriovenous fistulas: a plea for neurosurgical treatment. *Acta Neurochir (Wien)* 135: 44–51, 1995
- 9) Niimi Y, Berenstein A, Setton A, Neophytides A: Embolization of spinal dural arteriovenous fistulae: results and follow-up. *Neurosurgery* 40: 675–682; discussion 682–683, 1997
- 10) Merland JJ, Assouline E, Rüfenacht D, Guimaraens L, Laurent A: Dural spinal arteriovenous fistulae draining into medullary veins: clinical and radiological results of treatment (embolization and surgery) in 56 cases. *Excerpta Med Int Congr Ser* 698: 283–289, 1986
- 11) Cognard C, Miaux Y, Pierot L, Weill A, Martin N, Chiras J: The role of CT in evaluation of the effectiveness of embolisation of spinal dural arteriovenous fistulae with N-butyl cyanoacrylate. *Neuroradiology* 38: 603–608, 1996
- 12) Lev N, Maimon S, Rappaport ZH, Melamed E: Spinal dural arteriovenous fistulae—a diagnostic challenge. *Isr Med Assoc J* 3: 492–496, 2001
- 13) Tacconi L, Lopez Izquierdo BC, Symon L: Outcome and prognostic factors in the surgical treatment of spinal dural arteriovenous fistulas. A long-term study. *Br J Neurosurgery* 11: 298–305, 1997
- 14) Cenzato M, Debernardi A, Stefini R, D'Aliberti G, Piparo M, Talamonti G, Coppini M, Versari P: Spinal dural arteriovenous fistulas: outcome and prognostic factors. *Neurosurg Focus* 32: E11, 2012
- 15) Fugate JE, Lanzino G, Rabinstein AA: Clinical presentation and prognostic factors of spinal dural arteriovenous fistulas: an overview. *Neurosurg Focus* 32: E17, 2012
- 16) Song JK, Vinuela F, Gobin YP, Duckwiler GR, Murayama Y, Kureshi I, Frazee JG, Martin NA: Surgical and endovascular treatment of spinal dural arteriovenous fistulas: long-term disability assessment and prognostic factors. *J Neurosurgery* 94(2 Suppl): 199–204, 2001
- 17) Bakker NA, Uyttenboogaart M, Luijckx GJ, Eshghi OS, Mazuri A, Metzemaekers JD, Groen RJ, Van Dijk JM: Recurrence rates after surgical or endovascular treatment of spinal dural arteriovenous fistulas: a meta-analysis. *Neurosurgery* 77: 137–144; discussion 144, 2015

Address reprint requests to: Panagiotis Zogopoulos, MD, 69 Vosporou Str., Lofos Skouze, Athens 10444, Greece.
e-mail: p.zogopoulos@yahoo.com