

Case Report

# Circulating Tumor Cell Count Can Be a Useful Prognostic Factor in Lung Resection via Cardiopulmonary Bypass

Masaki Hashimoto<sup>a</sup> Yoshitomo Okumura<sup>b</sup> Fumihiko Tanaka<sup>c</sup>  
Kazue Yoneda<sup>c</sup> Teruhisa Takuwa<sup>a</sup> Nobuyuki Kondo<sup>a</sup> Seiki Hasegawa<sup>a</sup>

<sup>a</sup>Department of Thoracic Surgery, Hyogo College of Medicine, Nishinomiya, Japan;

<sup>b</sup>Department of Thoracic Surgery, Itami City Hospital, Itami, Japan; <sup>c</sup>Second Department of Surgery (Chest Surgery), University of Occupational and Environmental Health, Kitakyushu, Japan

## Keywords

Circulating tumor cell · Lung cancer · Cardiopulmonary bypass

## Abstract

Tumor resection with cardiopulmonary bypass (CPB) remains controversial in the field of oncology. Here, we present a 57-year-old male patient with locally advanced squamous cell carcinoma. The tumor was located in the left hilum and invaded the left atrium. Complete resection, left pneumonectomy combined with partial left atrium resection, was achieved using CPB. We evaluated the circulating tumor cell (CTC) counts, as a surrogate for micrometastasis, in peripheral blood and the CPB circuit. Both CTC counts were 0, which could indicate local disease without micrometastasis. CTC count may be a useful indicator for tumor resection with CPB in lung cancer.

© 2017 The Author(s)  
Published by S. Karger AG, Basel

## Introduction

The treatment of locally advanced non-small cell lung cancer (NSCLC), particularly those invading the great vessels and left atrium (LA), remains challenging. In selected patients with locally advanced NSCLC, complete resection using cardiopulmonary bypass (CPB) is sometimes performed. This method may contribute to a favorable prognosis [1–5]. However, the safety of using CPB is still controversial in the oncology field. CPB use may be linked to cancer progression because it could induce immunosuppression and tumor dissemination via the CPB circuit [6, 7]. Therefore, patient selection for CPB is essential.

Circulating tumor cells (CTCs) are surrogate markers for distant metastasis. In NSCLC, the presence of CTCs in peripheral blood suggests distant metastases [8]. Here, we evaluated preoperative and intraoperative CTC counts in a patient who underwent complete resection using CPB for locally advanced NSCLC.

## Case Report

The patient was a 57-year-old Japanese male. He was a current smoker (20 cigarettes/day) and had smoked for 40 years. He began to experience coughing but did not seek treatment. Two months later, he consulted a family doctor for his cough; other symptoms, such as hemoptysis, appetite loss, and body weight loss, were absent. Chest X-ray showed an abnormal shadow in the left hilum lesion (Fig. 1). Chest computed tomography (CT) revealed a solid lung tumor in the left lower lobe. Pathological examination by bronchoscopy revealed squamous cell carcinoma. He was then referred to our hospital to receive surgery.

Contrast-enhanced CT showed that blood flow into the left inferior pulmonary vein could not be visualized; therefore, we assumed that the tumor was invading the inferior pulmonary vein to the LA (Fig. 2). Positron emission tomography-CT showed that the lung tumor had very strong uptake, but fortunately, there was no abnormal uptake indicating a distant metastasis (Fig. 3).

We considered complete resection, which would be possible under CPB if the tumor was invading the LA wall. After thoracotomy, we confirmed that the tumor had invaded the left upper lobe and left inferior pulmonary vein without pleural dissemination. The patient then underwent left pneumonectomy combined with LA resection under CPB and complete resection was achieved.

Samples of 7.5 mL blood were taken to evaluate CTC counts; one sample was taken from peripheral blood just before the surgery and the other sample was taken from the CPB circuit. The samples of blood were collected in CellSave tubes (Veridex LLC, Raritan, NJ, USA) and were used for CTC tests. CTCs were quantitatively evaluated using the CellSearch system. The CTC count was found to be 0 in both samples.

The postoperative course was uneventful, and there were no complications. The patient was discharged 14 days after the surgery. Pathological examination showed that the tumor had invaded the left upper lobe and left inferior pulmonary vein and hilum lymph node, indicating TNM stage T4N1M0. The patient received 6 courses of adjuvant chemotherapy (cisplatin and docetaxel). The patient is doing well without tumor recurrence and distant metastases have not been observed for 8 years after the surgery.

## Comment

Despite progress in NSCLC treatment, clinical outcomes for locally advanced NSCLC remain poor, and complete resection is often planned as a part of multimodality therapy. In a case in which a tumor invades a great vessel or LA, CPB is required to achieve complete resection. Although favorable outcomes have been reported many times of using CPB in locally advanced NSCLC [1–5], CPB can induce immunosuppression and tumor dissemination [2, 3, 6]. Muralidaran and co-workers [7] described poor prognoses in patients when CPB is unplanned. Hence, patients should be carefully evaluated if CPB is considered.

Fukuse and co-workers [5] reported that 3-year survival rates are significantly higher in patients with pathologically N0–1 NSCLC than in those with N2–3 NSCLC (37 vs. 0%); therefore, they concluded that complete resection using CPB should be planned in patients with N0–1 NSCLC. With respect to this surgical criteria for locally advanced NSCLC, we are hopeful that a 5-year survival rate will be achieved in the present case. However, it is controversial to base the rationale for complete resection using CPB for locally advanced NSCLC only on the nodal status. We recommend that complete resection using CPB be performed in patients with a truly local case; thus, this decision should be made based not only on the N factor but also in the absence of distant metastases. To identify distant metastases, systemic evaluation is usually performed preoperatively; however, micrometastases may be difficult to be detected using conventional radiology.

CTC is known to be a surrogate marker for distant metastases in various cancers. In NSCLC, Tanaka and co-workers [8] described CTC count as a predictive factor of distant metastases. Here CTC counts in both preoperative peripheral blood and intraoperative CPB circuit were 0/7.5 mL, suggesting an absence of micrometastases. The present case may, therefore, represent a truly local disease, which may have contributed to a favorable prognosis.

Hasegawa and co-workers [2] recommend that a risk/benefit ratio should be considered for surgical resection using CPB because of its invasiveness and associated prognoses. In a case positive for CTC, the risk/benefit ratio would be toward risk because CTC count suggests the presence of distant metastases.

In conclusion, CTC count may be a useful tool to detect micrometastases in patients with locally advanced NSCLC in whom planned complete resections using CPB are being considered. Because CTC is well recognized as a surrogate for distant metastases, this present case may represent a truly local disease, which made it suitable for surgical resection using CPB. CTC counts in peripheral blood may also be a useful index to indicate the appropriateness of performing a surgical resection using CPB.

## Acknowledgements

We thank Miss Yukiko Satake for her assistance in preparing the manuscript. This work was supported by KAKENHI 20390374, 20591679.

## Statement of Ethics

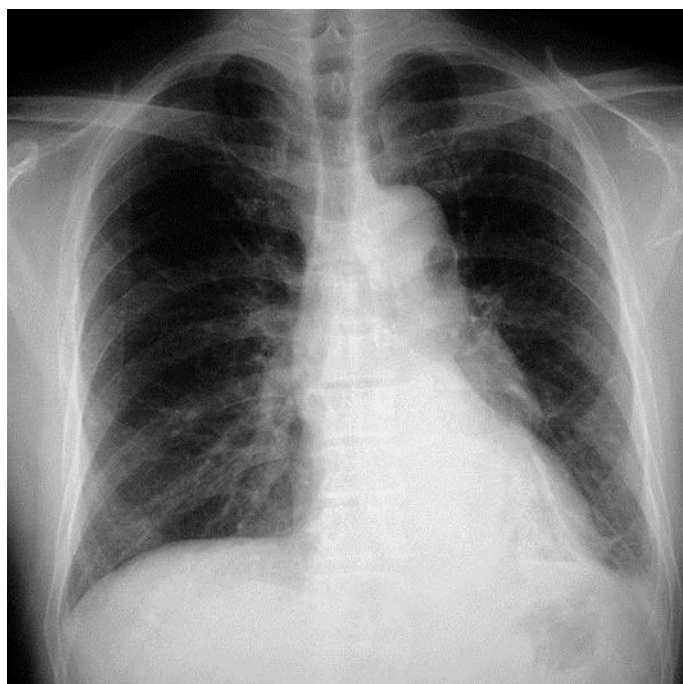
The authors have no ethical conflicts to disclose.

### Disclosure Statement

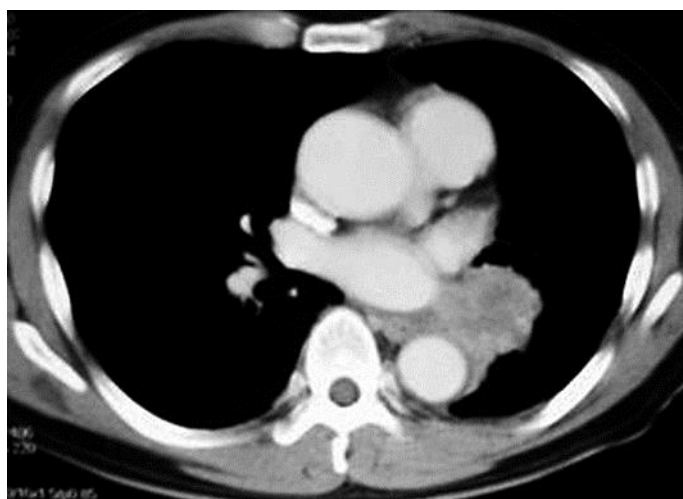The authors declare that they do not have anything to disclose regarding conflict of interest with respect to this article.

### References

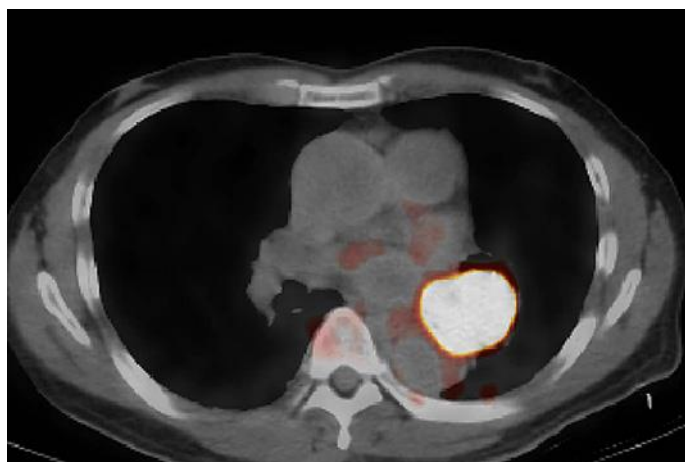
- 1 de Perrot M, Fadel E, Mussot S de Palma A, Chapelier A, Darteville P: Resection of locally advanced (T4) non-small cell lung cancer with cardiopulmonary bypass. *Ann Thorac Surg* 2005;79:1691–1696; discussion 1697.
- 2 Hasegawa S, Bando T, Isowa N, Otake Y, Yanagihara K, Tanaka F, Inui K, Wada H: The use of cardiopulmonary bypass during extended resection of non-small cell lung cancer. *Interact Cardiovasc Thorac Surg* 2003;2:676–679.
- 3 Langer NB, Mercier O, Fabre D, Lawton J, Mussot S, Darteville P, Fadel E: Outcomes after resection of T4 non-small cell lung cancer using cardiopulmonary bypass. *Ann Thorac Surg* 2016;102:902–910.
- 4 Vaporciyan AA, Rice D, Correa AM, Walsh G, Putnam JB, Swisher S, Smythe R, Roth J: Resection of advanced thoracic malignancies requiring cardiopulmonary bypass. *Eur J Cardiothorac Surg* 2002;22:47–52.
- 5 Fukuse T, Wada H, Hitomi S: Extended operation for non-small cell lung cancer invading great vessels and left atrium. *Eur J Cardiothorac Surg* 1997;11:664–669.
- 6 Pinto CA, Marcella S, August DA, Holland B, Kostis JB, Demissie K: Cardiopulmonary bypass has a modest association with cancer progression: a retrospective cohort study. *BMC Cancer* 2013;13:519.
- 7 Muralidaran A, Detterbeck FC, Boffa DJ, Wang Z, Kim AW: Long-term survival after lung resection for non-small cell lung cancer with circulatory bypass: a systematic review. *J Thorac Cardiovasc Surg* 2011;142:1137–1142.
- 8 Tanaka F, Yoneda K, Kondo N, Hashimoto M, Takuwa T, Matsumoto S, Okumura Y, Rahman S, Tsubota N, Tsujimura T, Kuribayashi K, Fukuoka K, Nakano T, Hasegawa S: Circulating tumor cell as a diagnostic marker in primary lung cancer. *Clin Cancer Res* 2009;15:6980–6986.



**Fig. 1.** Chest X-ray showed an abnormal shadow in the left hilum lesion.



**Fig. 2.** Contrast-enhanced chest computed tomography revealed a solid lung tumor in the left lower lobe, and it invaded the inferior pulmonary vein to the left atrium.



**Fig. 3.** Positron emission tomography-computed tomography showed that the lung tumor had very strong uptake. There was no abnormal uptake indicating a distant metastasis.