

Cerebral astroblastoma: A case report and review of literature

Vivek Agarwal, Rahul Mally, D. A. Palande, Vernon Velho

Department of Neurosurgery, Grant Medical College and Sir J. J. Group of Hospitals, Mumbai, Maharashtra, India

ABSTRACT

Astroblastomas are uncommon neuroepithelial tumors of uncertain origin. These occur predominantly in the cerebral hemisphere of young adults and children. They form only 0.45–2.8% of all neuroglial tumors. They can be easily misdiagnosed as they are rarely encountered in clinical practice and share common radiological and histopathologic appearance with other glial neoplasms. A 12-year-old female presented to us with progressive headache and diplopia. Her neurological examination showed right 6th nerve paresis with papilledema. Brain magnetic resonance imaging (MRI) revealed well-demarcated, peripherally enhancing solid cystic mass of 6 cm in right parietal lobe with mass effect. She underwent gross total resection of the lesion through right parietal craniotomy. The histopathologic diagnosis was suggestive of low-grade astroblastoma. The patient had no evidence of recurrence of tumor without adjuvant radiotherapy during the last 14 months of follow-up. Supratentorial astroblastomas are very rare tumors. Complete excision without radiotherapy is sufficient in low-grade variants.

Key words: Astroblastoma, cerebral, report

Introduction

Astroblastomas are uncommon neuroepithelial tumors of uncertain origin. These occur predominantly in the cerebral hemisphere of young adults and children.^[1,2] Incidence of astroblastoma is only 0.45–2.8% of all neuroglial tumors. They can be easily misdiagnosed as they are rarely encountered in clinical practice and share common radiological and histopathologic appearances with other glial neoplasms. We report a rare case of astroblastoma. The clinical presentation, pathology, differential diagnosis, and treatment of this rare disorder are discussed.

Case Report

A 12-year-old, otherwise healthy girl presented to us with progressive headache with diplopia since 3 months. The

neurological examination showed right 6th nerve paresis with papilledema. Brain magnetic resonance imaging (MRI) revealed a well-demarcated mass of 6 cm in diameter in the right parietal lobe with mass effect in the form of effacement of adjacent cortical sulci, compression of frontal and occipital horn of lateral ventricle, and midline shift [Figures 1 and 2]. After an injection of gadolinium, the tumor showed a peripheral enhancement [Figure 3]. The above images were reported as pilocytic astrocytoma.

The patient underwent gross total resection of the lesion through right parietal craniotomy [Figure 4]. The tumor was rubbery, vascular, and well demarcated from the surrounding brain. Postoperative period was uneventful and neurological examination did not reveal any additional deficits. The histopathologic diagnosis was low-grade astroblastoma. Microscopically, the tumor showed papillary architecture and pseudorosettes around the central hyalinized thickened blood vessel throughout the tumor [Figures 5 and 6]. Individual cells were polygonal to spindle, showing moderate eosinophilic cytoplasm and eccentrically placed nuclei. The nucleus was round with coarse chromatin. Mitotic figures were rarely observed. Blood vessels were mostly of capillaries without smooth muscle layers. There was no glial fibrillarity in the fibrovascular stalk. The macrophages were frequently infiltrated in fibrovascular stalks. Immunohistochemical stains revealed Glial fibrillary acidic protein (GFAP) and Epithelial membrane antigen (EMA) positivity. In the absence of any feature suggestive of high-grade lesion, i.e. high cellularity, anaplastic nuclear

Access this article online	
Quick Response Code:	Website: www.asianjns.org
	DOI: 10.4103/1793-5482.98657

Address for correspondence:

Dr. Vivek Agrawal, Department of Interventional neuroradiology, Zurich University Hospital, Switzerland, E-mail: neuro.vi@gmail.com

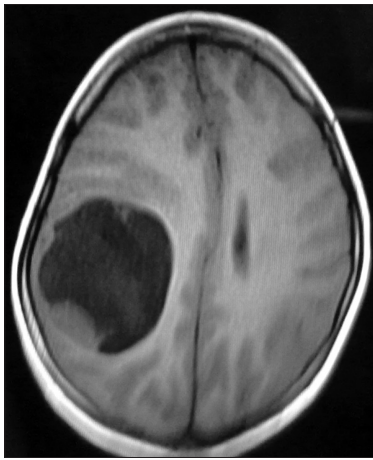


Figure 1: T1W axial image

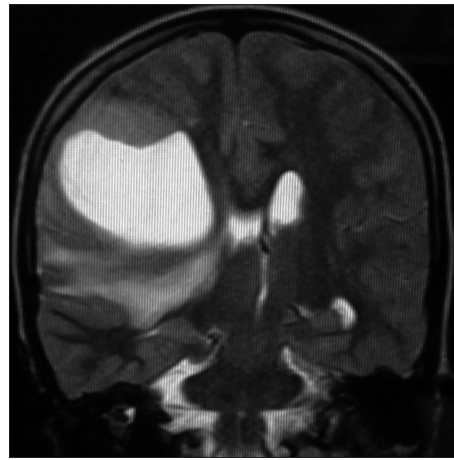


Figure 2: T2W coronal image

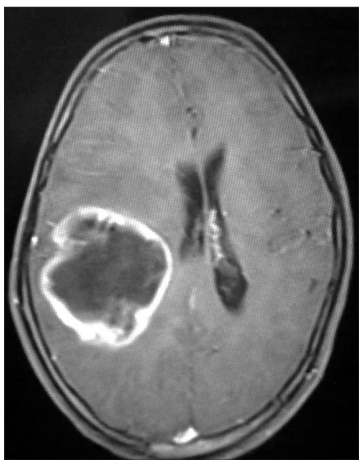

Figure 3: T1W axial post-contrast image

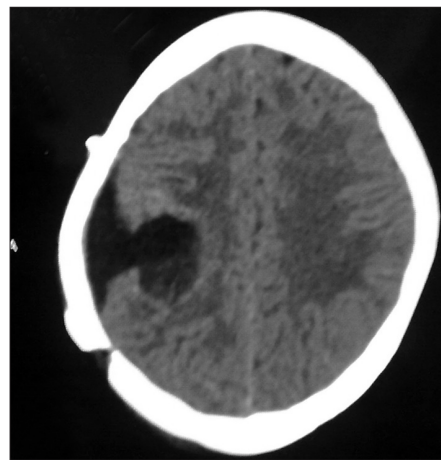


Figure 4: Postoperative CT scan Image

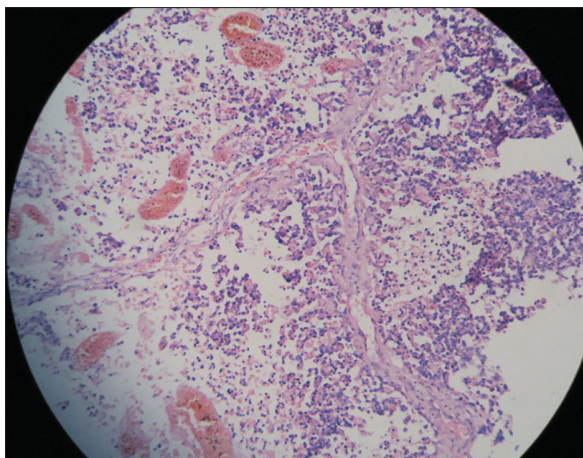


Figure 5: Low-power field slide – Papillary architecture and pseudorosettes around central hyalinized thickened blood vessels

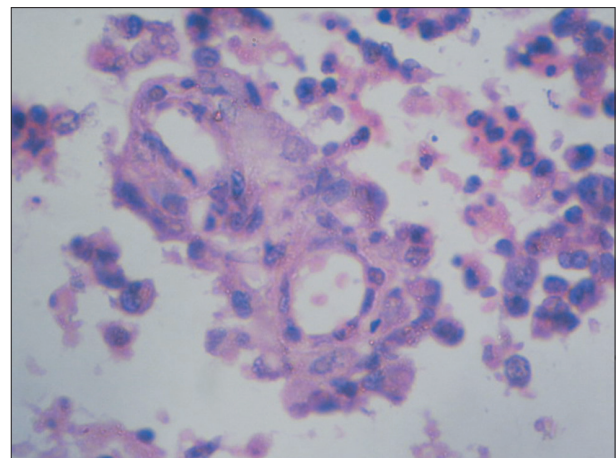


Figure 6: Histopathologic slide – High-power field pseudorosettes around central hyalinized thickened blood vessels with individual cells being polygonal to spindled, showing moderate eosinophilic cytoplasm and eccentrically placed nuclei

features, elevated mitotic indices, vascular proliferation, and necrosis, the patient was advised regular follow-up without adjuvant radiotherapy. The patient had no recurrence of the tumor until the last follow-up done 14 months after the surgery.

Discussion

Approximately 40 cases of astroblastoma have been reported in the literature since Bailey and Bucy reported the condition

for the first time in 1930. Bailey and Bucy believed that astroblastoma originated from astroblasts, an intermediate stage between glioblasts and astrocytes.^[3]

These are rare glial tumors usually located in the cerebral hemisphere. However, tumor invasion has also been reported into corpus callosum, cerebellum, brain stem, and optic nerve.^[4,5] Clinical signs and symptoms depend on the location and size of the neoplasm, with headache and seizures being the most frequently encountered symptoms. Astroblastomas are mostly seen in children and young adults like in this case, but congenital cases have also been reported rarely.^[4]

Bell *et al.* reported the largest imaging series with 12 cases of astroblastomas. As per their report, astroblastomas are almost exclusively seen supratentorially and are peripheral in location with both solid and cystic components.^[6] Our case showed typical solid cystic lesion with rim enhancement without calcification. Based on imaging, the differential diagnoses for astroblastomas include high-grade astrocytoma, pilocytic astrocytoma, oligodendroglioma, primitive neuroectodermal tumor, ependymoma, and atypical rhabdoid tumor. Unlike in high-grade tumors, perilesional edema is usually less in astroblastomas including high-grade variants.

Astroblastomas are defined histologically by the presence of perivascular pseudorosettes and prominent perivascular hyalinization.^[7] They may resemble astrocytic tumors, ependymomas, and non-neuroepithelial tumors due to their astroblastic components. Lack of fibrillarity is an essential feature in distinguishing astroblastomas from other glial neoplasms. Immunohistochemically, astroblastomas are immunoreactive for GFAP, S-100 protein, and vimentin. The majority display a focal cytoplasmic immunoreactivity for EMA.

Astroblastomas along with gliomatosis cerebri and polar spongioblastoma are included in neuroepithelial tumors of uncertain origin and are grade 4 tumors as per 2007 contrary to grade 1 in WHO classification of brain tumors. Bonnin *et al.* reported two distinct histological types: A low-grade type with better differentiated pattern and favorable postoperative prognosis and a high-grade type showing more anaplastic microscopic features with short postoperative survival. High-grade lesions show focal or multifocal regions of high cellularity, anaplastic nuclear features, elevated mitotic indices, vascular proliferation, and necrosis with pseudopalisading.^[5]

Our case was considered in low-grade group as it had well orderly growth pattern with no evidence of necrosis and a high mitotic activity. Although malignant astroblastomas may show infiltration of brain parenchyma, most of them are noninfiltrating.^[8]

Natural history of astroblastoma seems to place it in between astrocytoma and glioblastoma.^[8] Total resection

is the best way of treating an astroblastoma.^[9] Regular follow-up is required even in low-grade variants due to unpredictable behavior. Adjuvant therapy is recommended for high-grade and recurrent cases.^[10] Favorable prognosis is almost invariably associated with well-circumscribed tumors which permit total resection of tumor in all grades. In a series of 23 patients reported by Bonnin and Rubinstein, patients with high-grade astroblastomas who did not receive postoperative radiotherapy had a shorter survival time.^[5] Caroli *et al.* reported a high-grade astroblastoma with a 5-year survival without recurrence after total resection, radiation therapy, and temozolamide usage.^[11] Our case was a low-grade astroblastoma, so we advised regular follow-up without adjuvant radiation. No recurrence was noted till the last follow-up of 14 months.

Conclusion

Supratentorial astroblastomas are very rare. The radiological features of these rare lesions can be heterogeneous. Complete excision without radiotherapy is sufficient in low-grade variants. High-grade and recurrent tumors require adjuvant radiotherapy.

References

1. Rosenblum MK. Neuromuscular system. In: Gery L, editor. Ackermans Surgical Pathology. 8th ed. St. Louis Missouri: Annr S Patterson; 1996. p. 2296-7.
2. Port JD, Brat DJ, Burgle PC, Pomper MG. Astroblastoma, Radiologicpathologic correlation and distinction from ependymoma. AJNR Am J Neuroradiol 2002;23:243-7.
3. Bailey P, Bucy PC. Astroblastomas of the brain. Acta Psychiatr Neurol 1930;5:439-61.
4. Pizer BL, Moss T, Oakhill A, Webb D, Coakham HB. Congenital astroblastoma: An immunohistochemical study. Case report. J Neurosurg 1995;83:550-5.
5. Bonnin JM, Rubinstein LJ. Astroblastomas: A pathological study of 23 tumors, with a postoperative follow-up in 13 patients. Neurosurgery 1989;25:6-13.
6. Bell JW, Osborn AG, Salzman KL, Blaser SI, Jones BV, Chin SS. Neuroradiologic characteristics of astroblastoma. Neuroradiology 2007;49:203-9.
7. McLendon RE, Enterline DS, Tien RD, Thorstad WL, Bruner JM. Astroblastomas. In: Bigner DD, McLendon RE, Bruner JM, editors. Russell and Rubinstein's pathology of tumors of nervous system. 6th ed. London: Arnold; 1998. pp. 419-26.
8. Burger PC, Scheithauer BW. Tumor of the central nervous system. Atlas of tumor pathology. 3rd series. Washington DC: Armed Forces Institute of Pathology; 1994. pp. 146-8.
9. Cabello A, Madero S, Castresana A, Diaz-Lobato R. Astroblastoma: Electron microscopy and immunohistochemical findings: Case report. Surg Neurol 1991;35:116-21.
10. Unal E, Koksai Y, Vajtai I, Toy H, Kocaogullar Y, Paksoy Y. Astroblastoma in a child. Childs Nerv Syst 2008;24:165-8.
11. Caroli E, Salvati M, Esposito V, Orlando ER, Giangaspero F. Cerebral astroblastoma. Acta Neurochir 2004;146:629-33.

How to cite this article: Agarwal V, Mally R, Palande DA, Velho V. Cerebral astroblastoma: A case report and review of literature. Asian J Neurosurg 2012;7:98-100.

Source of Support: Nil, **Conflict of Interest:** None declared.