

RESEARCH

Open Access



# Molecular cytogenetic characterization of a de novo derivative chromosome X with an unbalanced t(X;9) translocation in a fetus and literature review

Qiong Wu<sup>1</sup>, Hui Kong<sup>1</sup>, Yanyan Shen<sup>1</sup> and Jing Chen<sup>2\*</sup>

## Abstract

Partial trisomy 9p is one of the most frequent autosome anomalies in newborn infants featured by craniofacial dysmorphism, intellectual disability and psychomotor growth. Female patients carrying monosomy Xq usually show mild symptoms due to skewed X-chromosome inactivation (XCI). Unbalanced translocation between chromosome X and chromosome 9 is rare in prenatal diagnosis. The skewed inactivation of abnormal X would spread into the extra segment of chromosome 9 presented in the der(X) leading to mild phenotypes. We reported on a fetus with high risk of trisomy 9p(13.32 Mb 9p23-p24.3 duplication)suggested by noninvasive prenatal testing (NIPT), the fetus was normal by ultrasonography. G-banding with trypsin-giemsa (GTG), copy number variations sequencing (CNV-seq) and fluorescence in situ hybridization (FISH) were carried out to delineate the nature of rearrangement. Final karyotype of the fetus was identified as 46,X,der(X)t(X;9)(q27;p23)dn. An unbalanced X-autosome translocation with a deletion of Xqter-q27.2 and a duplication of 9pter-p23 led to mild phenotypes with no obvious alteration by prenatal ultrasonography, or obvious pathological alterations after pregnancy termination.

**Keywords:** Derivative X chromosome, Copy number variation sequencing (CNV-seq), Fluorescence in situ hybridization (FISH), X-chromosome inactivation (XCI)

## Introduction

Partial trisomy 9p featured by craniofacial dysmorphism and intellectual disability and psychomotor growth is the fourth most frequent autosome abnormality in liveborn infants after trisomy 21, 18 and 13 possible due to these chromosomes as well as 9p are relatively gene poor [1, 2]. Patients carrying partial monosomy Xq usually present mild phenotypes due to possibly skewed XCI. Although patients with unbalanced X:autosome translocations are at risk for X-linked disorders and/or partial autosome

trisomy, attenuated phenotypes are frequently observed, for the spread of X-chromosome inactivation into autosomal sequences plays a key role in clinical presentation. The difficulty for such prenatal cases lies in the lack of typical signs and symptoms as postnatal cases. Copy number variations (CNVs) were clinically significant in pregnancies without structural sonographic anomalies, especially for those with a high risk of trisomy 9p suggested by noninvasive prenatal testing (NIPT) [3]. Fluorescence in situ hybridization (FISH) was a reliable method to confirm the positive results of noninvasive free DNA detection and could be used to identify real mosaicism and placental mosaicism by detecting uncultured amniocytes [4]. We report an unbalanced X;9 translocations in a 16-week-old female infant with mild

\*Correspondence: chenjing8469899@126.com

<sup>2</sup> Department of Child Health, Women and Children's Hospital, School of Medicine, Xiamen University, Xiamen 361003, Fujian, China  
Full list of author information is available at the end of the article



features. To the best of our knowledge, this is the first reported fetus with a de novo der(X)t(X;9)(q27;p23). Our findings expand the unknown spectrum of unbalanced X-autosome translocations, and may provide valuable information for prenatal diagnosis and cytogenetic counseling. Moreover, we prompted that NIPT might play a role in the first trimester screening of sub-chromosomal rearrangement.

## Materials and methods

### Ethical approval

This study was performed in accordance with the Declaration of Helsinki, and approved by the Institutional Review Board (IRB) of Xiamen Maternal and Child Health Hospital (Xiamen, China). All participants in this study agreed to donate the remaining samples and data to scientific research, technical innovation and clinical application after the identifiable personal information was removed. All participants provided their informed consent.

### Noninvasive prenatal testing (NIPT)

Experiments and data analysis were performed using the technology platform provided by Beijing Genomics Institution (Beijing Genomics Institution, BGI, CHINA). 5 mL of peripheral blood was collected from the pregnant woman in EDTA containing tubes. The peripheral blood samples were used to extract cell-free fetal DNA (cffDNA) by using of QIAamp DSP DNA Blood Mini Kit (Qiagen, Germany) following the blood protocol. The high-throughput sequencing technology was used to calculate the relative content of cffDNA. The sequence was compared with the human genome reference sequence map. The proportion of each chromosomal was calculated by using Illumina sequencing analysis viewer 19.1 software. If the trisomy risk index Z value  $\geq 3$ , then it indicates high risk of fetal trisomy.

### Cell culture and karyotype analysis

Cell culture and G-banding karyotype analysis were performed in accordance with standard cytogenetic methods. Fetal cells obtained from amniocentesis and peripheral blood lymphocytes from the expecting mother and the expecting father were cultured with a double-line by using standard methodologies, incubated in 37°C and 5% CO<sub>2</sub> incubator for 7 days and 72 h respectively before harvest. The karyotypes were photographed with Zeiss CCD (Carl Zeiss, Germany) and analyzed with AI imaging system (AI, USA). 20 metaphase karyotypes were counted for each case, and 5 karyotypes were analyzed for each sample, all results were interpreted according to an International System for Human Cytogenetic Nomenclature 2020 (ISCN2020).

### Copy number variation sequencing (CNV-seq)

CNV-seq was performed using Low depth whole genome sequencing (Beijing Genomics Institution, BGI, CHINA) according to manufacturer's instructions. The procedure included genomic DNA extraction from amniocytes using DNA easy blood & tissue Kit (Qiagen, Germany), the sequencing library construction, sequencing (BGI seq500 sequence), Using burrows-Wheeler aligner (version 0.7.7) to compare and analyze the sequence information with human reference genome (GRCh37, UCSC release hg19), judged whether there was a chromosome aneuploid variation and CNV, and searched ISCA, Decipher, Clinvar, DGV databases, and Pubmed to evaluate the pathogenicity of the detected CNV. The threshold of CNVs was set at 100 kb with marker count  $\geq 25$ .

### Fluorescence in situ hybridization (FISH)

Metaphase FISH on cultured amniocytes and the parents' peripheral blood lymphocytes were performed using the technology platform provided by Be Reative Lab (BRL, CHINA) using subtelomeric FISH probes of chromosome X (Xpter/Xqter) and chromosome 9 (9pter/9qter) (Vysis, USA) respectively according to the manufacturer's instructions and to reveal the reciprocal translocations. The procedure included hybridization, stringency washes and fluorescence staining using DAPI. All slides were placed under a fluorescence microscope equipped with a CCD camera (Photometrics, USA) (Carl Zeiss, Germany) and analyzed with cytovision system version probe software (Applied imaging, AI, USA). 20 metaphases were analyzed for each probe.

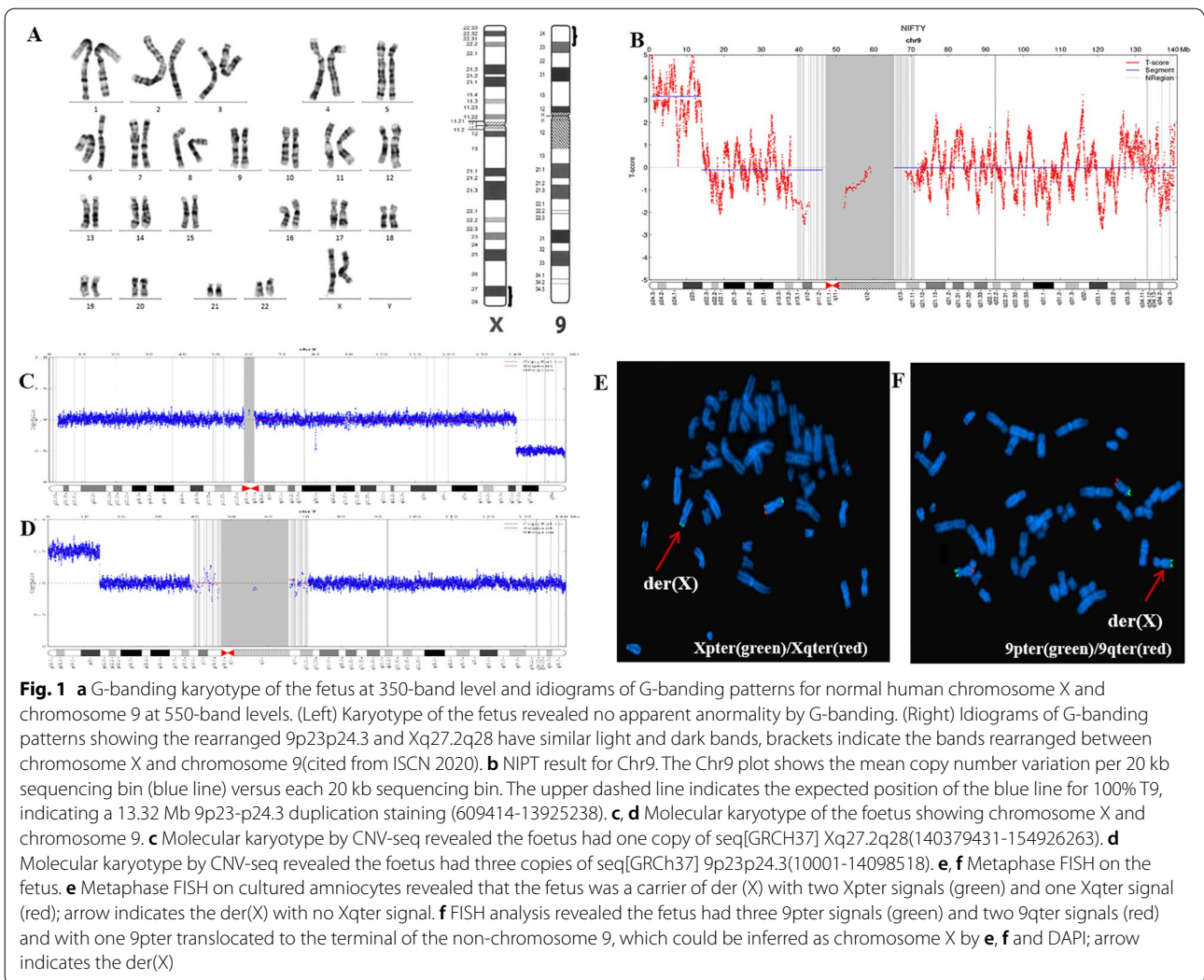
## Results

### Clinical report

A 31-year-old woman, Gravida 1 Para 0 at 16+2 weeks of gestation, referred to our hospital together with her 31-year-old husband. Both the husband and the wife were healthy and unrelated. There was no history of exposure to harmful substances like radiation during pregnancy. Doppler ultrasound image for the pregnant woman in our hospital at 16+2 weeks of gestation revealed no obvious abnormalities for the fetus except for the unclear display of the fetal spine due to the body position of the fetus.

### Non-invasive prenatal testing

Maternal free fetal DNA was detected: The NIPT result revealed that the Z score of chromosomes 9 was 3.093; the score suggested that duplication of fetal DNA fragments occur in chromosome 9. There was



an approximately 13.32 Mb 9p23-p24.3 duplications (609414–13925238) (Fig. 1b).

**Chromosomal analysis**

The conventional cytogenetic analysis revealed no apparent aberrations in the fetus with a karyotype of 46,XX (Fig. 1a). The parents’ karyotypes were 46,XY and 46,XX respectively with no obvious abnormalities (not listed out).

**Copy number variation sequencing**

Fetus: seq[GRCH37] del(Xq27.2q28) ChrX: g.140379431-154926263del; seq[GRCH37] dup(9p23p24.3) chr9: g.10001-14098518dup, suggesting a copy number loss of 14.55 Mb in chromosome Xq27.2q28 (Fig. 1c), accompanied by a copy number gain of 14.09 Mb in 9p23p24.3 (Fig. 1d). The expecting father: seq[GRCH37]

del(9p13.2p13.2) chr9: g.38265518-38384445 del which had a 118.93 kb copy number loss in chromosome 9p13.2p13.2 (not listed out). The expecting mother: revealed no CNVs (not listed out).

**Fluorescence in situ hybridization**

FISH showed that the fetus was a carrier of der(X). Fluorescence signal combined with DAPI analysis revealed that the fetus had two copies of Xpter signals and one copy of Xqter signal, indicating that Xqter was partially deleted. There were three copies of 9pter signals and two copies of 9qter signals indicating a partial trisomy 9pter and one of 9pter was translocated to the end of the long arm of chromosome X (Fig. 1e, f). The fetal mother showed normal Xpqter and 9pqter signals (not listed out). The fetal father revealed normal XYpqter and 9pqter (not listed out).

### Follow up results of fetus

After detailed genetic counseling and full informed consent, though combined with the review of similar patients, a mild phenotypic variation in this fetus might be inferred, the pregnant woman opted to terminate her pregnancy and underwent induced labor in our hospital at 17 weeks of gestation. Pathological examination showed no obvious abnormalities in the induced labor fetus, no abnormality was observed on the face, body weight: 201 g, body length: 20.5 cm, femur length: 2.7 cm. The couple refused pathological dissection on the induced labor fetus.

### Discussion

NIPT was used for the pregnant woman in routine screening of chromosome aneuploidy, and a 13.32 Mb 9p23-p24.3 duplications was suggested prior to ultrasound and invasive prenatal testing. Amniocentesis was performed and a normal karyotype of 46,XX was found for the fetus. The rearranged bands of Xq27.2q28 and 9p23p24.3 are very similar not only in G-dark and G-light bands (Fig. 1a) but also in sizes, 14.55 Mb and 14.09 Mb respectively, which increased the difficulty of identifying chromosome aberrations. This indicated the necessity of combining different cytogenetic/molecular methodologies like CNV-seq and FISH to further exclude unbalanced rearrangements in the fetus and the couple [5]. CNV-seq for the fetus revealed a 14.55 Mb copy number loss in Xq27.2q28 and a copy number gain of 14.09 Mb in 9p23p24.3. These results were further confirmed by FISH using probes of 9pter/9qter, Xpter/Xqter to reveal terminal reciprocal translocations.

Fetuses of partial 9p trisomy might be born with a high survival rate for its relatively poor gene region, some might have growth and developmental problems in infancy, including facial deformation, short state, mental retardation, growth retardation [6–9]. Molecular level study showed that 9p22.1-p22.2 was most closely related to the clinical presentation of partial 9p trisomy [10], while the 9p repeat fragment of this fetus covered 9p23p24.3 with no flanking of key areas of trisomy 9p pathogenicity.

Today, the research on X chromosome translocations has focused on skewed X-chromosome inactivation (XCI) and pseudo-autosomal regions (PARs). PARs are classified as PAR1 and PAR2, the latter located on the qter of chromosome X with a size of about 360 kb including the *SPRY3*, *SYBL1*, and *IL9R* genes, which played a key role in antagonistic pathway of fibroblast growth factor (FGF) synthesis, fusion of vesicles and target membrane and occurrence of asthma respectively [11–13]. Mutations or deletions of the foregoing genes would result in haploinsufficiency. In healthy females, one X chromosome

undergoes random inactivation, but there are genes that escape X-inactivation, including the genes from the pseudo-autosomal regions (PARs) and some other genes, especially in the Xp region. On the other hand, the Xq region presents fewer genes that escape inactivation, and due to preferential inactivation, deletion of this region may result in fewer phenotypic alterations [14].

X-chromosome inactivation has been localized between Xq13.1 and Xq13.2, with the *XIST* gene playing a key role in chromosome X inactivation. For females carrying unbalanced X-autosome translocations, the abnormal X may be tolerated because of the preferential inactivation of the abnormal X chromosome, for the inactivation of the normal X chromosome might result in severe genome imbalance [15–17]. The normal X-chromosome was preferentially inactivated in five patients with balanced X-autosome translocations; while the aberrant X-chromosome was inactivated in most cells from six patients with unbalanced alterations as described by Sisdelli et al. [18]. The spread of X-inactivation into the autosomal regions could affect the phenotype, which could lead to a more severe or a mild clinical presentation depending on the patient's chromosomal constitution. Watanabe et al. reported a 34 years old female with mild phenotypes including congenital heart disease, epicanthal fold, mild intellectual disability, and menstrual irregularity associated with an unbalanced X-autosome translocation, 46,X,der(X)t(X;8)(q28;q13), and suspected that the patient had mild phenotypes due to the inactivation of the abnormal X chromosome 8q13-qter and the presence of a small deletion of Xq28-qter [19].

Patients with unbalanced X:autosome translocations are at risk for X-linked disorders and/or partial autosomal trisomy, however, attenuated phenotypes were frequently observed. It is known that chromosome X inactivation might spread into the autosome part of an unbalanced translocation involving chromosome X and an autosome. A pedigree with 4 women, of 3 different generations, carrying the same cytogenetic anomaly as 46,X,der(X)t(X;7)(q26;q35) with mild clinical presentation mainly characterized by gynecological/hormonal issues and autoimmune disorders was reported to present a skewed X inactivation pattern with a preferential activation of the normal X, in other words, inactivation of the der(X) [20]. Chen et al. described a 33-year-old woman with a karyotype of 46,X,der(X)t(X;5)(q27.3;q32)dn with primary ovarian failure, moderate mental retardation, and mild phenotype of facial dysmorphism [21]. Guo et al. reported a 20-year-old woman with a karyotype of 46,X,der(X)t(X;1)(q28;q32.1)dn with premature ovarian failure, mental retardation, class I obesity, mild dysmorphism and delayed secondary sexual characteristics [22].

**Table 1** Eleven cases of unbalanced X; autosome translocations

Cases	Karyotypes	XCI	Age	Clinical features	References
1	46,X,der(X)t(X;5)(q27.3;q32)dn	Not done	33 y	Primary ovarian failure, moderate mental retardation, and mild phenotype of facial dysmorphism	[21]
2	46,X,der(X)t(X;1)(q28;q32.1) dn	Yes	20 y	Premature ovarian failure, mental retardation, class I obesity, mild dysmorphism and delayed secondary sexual characteristics	[22]
3	46,X, der(X)t(X;15)(q22;q11.2)dn	Yes	3 y	Mild phenotype with normal birth measurements, minor facial dysmorphic features (hypertelorism, short broad nose, and a relatively long philtrum), and moderate developmental delay	[3]
4	46,X, der(X)t(X;18)(q27;q22)mat	Yes	32 y	Fully attenuated or Diminished ovarian reserve (DOR) phenotype in the same family	[24]
5	46,X,der(X)t(X;4)(q22;q24)	Yes	32 y	Secondary amenorrhea, physical exam was within normal limits and was negative for any dysmorphic facial features or physical anomalies	[25]
6	46,X,der(X)t(X;10)(q26.3;q23.3)	Yes	14 y	Secondary amenorrhea with no abnormal external physical features	[6]
7	46,X,der(X)t(X;8)(q28;q13)	Not done	34 y	Mild manifestations, including congenital heart disease, epicanthal fold, mild intellectual disability, and menstrual irregularity	[19]
8	46,X,der(X)t(X;7)(q26;q35)	Yes	fetus 30 y 32 y 60 y	A family with 4 women, of 3 different generations, carrying the same cytogenetic anomaly with mild clinical presentation mainly characterized by gynecological/hormonal issues and autoimmune disorders	[20]
9	46,X,der(X),t(X;1)(q28;q32.1)dn	Yes	11 month	Short stature, unusual head shape, mild dysmorphic features, and mild developmental delay	[27]
10	46,X,der(X)t(X;10)(q26;q21.2)pat	Yes	11 y	Developmental delay and craniofacial, chest, and limb dysmorphism	[28]
11	46,X,der(X)t(X;9)(q27;p23)dn	Not done	fetus	No apparent abnormalities except for the unclear display of the fetal spine	Present study

More cases with mild phenotype are as follow: Fusco et al. a woman with 46,X, der(X)t(X;18)(q27;q22)mat with fully attenuated or diminished ovarian reserve (DOR) phenotype in the same family; Sharp et al. a 46,X,der(X)t(X;10)(q26.3;q23.3) with secondary amenorrhea with no abnormal external physical features, all cases were listed as Table 1 [23–26]. Yatsenko et al. reported a case of an X;1 translocation in a 9-month-old female infant with 46,X,der(X),t(X;1)(q28;q32.1) dn with mild dysmorphic features and developmental delay due to late replication of the derivative X in 80% of the observed cells and XCI spread into the translocated 1q segment [27]. Garcia-Heras et al. described girl of a 46,X,der(X)t(X;10)(q26;q21.2) presenting clinical features of distal trisomy 10q, but lacked the classical cardiovascular and renal malformations observed in duplications of 10q24-10qter [28]. These two cases differed from the above cases in that some cells where X inactivation failed to spread into the translocated autosomes, presenting more severe phenotypes. We could conclude from Table.1 that in case of unbalanced translocations between X-autosomes, XCI would happened in the abnormal chromosome X and might spread into autosomes (8 of 11 cases have been verified) presenting mild phenotypes. For this case, the expecting mother refused further testing like,

## Conclusion

In conclusion, we identified a fetus with 46,X,der(X)t(X;9)(q27;p23)dn suggested by NIPT. Combining cytogenetic study, karyotype analysis, FISH and CNV-seq in prenatal diagnosis of unbalanced X-autosome translation was a reliable method [29]. We would like to speculate that the fetus would have mild phenotypes, the possible reason might be that 9p23p24.3 is relatively gene poor and the skewed inactivation of abnormal X would spread into the extra segment of chromosome 9 presented in the der(X) resulting a mild phenotype. To the best of our knowledge, this is the first description of de novo prenatal case with Xq27-qter deletion and 9p23-pter duplication to date. Rare cases might help to understand the genotype–phenotype relationship of such unbalanced X-autosome translocations. In addition, we prompted that NIPT might play a role in the first trimester screening of sub-chromosomal rearrangement.

## Abbreviations

CNVs: Copy number variations; FISH: Fluorescence in situ hybridization; PAR: Pseudo autosomal region; NIPT: Noninvasive prenatal testing; CNV-seq: Copy number variations sequencing; DGV: Database of Genomic Variants; FGF: Fibroblast growth factor; XCI: X chromosome inactivation; Der chromosome: Derivative chromosome.



### Acknowledgements

The authors would like to thank all the participants for their cooperation in this study and Be Reative Lab (BRL, Beijing), Beijing Genomics Institution (BGI, Beijing) for their expert laboratory work.

### Author contributions

Q.W. and J.C. clinically reviewed the patient and wrote the manuscript. H.K. and Y.S. performed the experiments and interpreted the data. Q.W., H.K., and Y.S. carried out genetic counseling for the pregnant woman. All the authors approved the final version of the manuscript.

### Funding

This work was financially supported by a grant from Youth Fund of National Natural Science Foundation of China (82103859), Guiding project of the Natural Science Foundation of Fujian (Grant No. 2019D010), Young and Middle-aged Talent Cultivation Projects of Fujian Province (Grant No. 2019-ZQN-31) and Xiamen Medical and Health Guidance Project (Grant No. 3502Z20214ZD1234).

### Availability of data and materials

All data generated or analyzed in this study are included in this published article. The raw data of CNV-seq and FISH were available upon request.

### Declarations

#### Competing interests

The authors declare that they have no competing interests.

#### Author details

<sup>1</sup>Department of Central Laboratory, Women and Children's Hospital, School of Medicine, Xiamen University, Xiamen 361003, Fujian, China. <sup>2</sup>Department of Child Health, Women and Children's Hospital, School of Medicine, Xiamen University, Xiamen 361003, Fujian, China.

Received: 28 March 2022 Accepted: 7 June 2022

Published online: 27 June 2022

### References

- Littooij AS, Hochstenbach R, Sinke RJ, van Tintelen P, Giltay JC. Two cases with partial trisomy 9p: molecular cytogenetic characterization and clinical follow-up. *Am J Med Genet.* 2002;109(2):125–32.
- Temtamy SA, Kamel AK, Ismail S, Helmy NA, Aglan MS, El Gammal M, et al. Phenotypic and cytogenetic spectrum of 9p trisomy. *Genet Couns (Geneva, Switzerland).* 2007;18(1):29–48.
- Maya I, Salzer Sheelo L, Brabbing-Goldstein D, Matar R, Kahana S, Agmon-Fishman I et al. Residual risk for clinically significant copy number variants in low-risk pregnancies, following exclusion of noninvasive prenatal screening-detectable findings. *Am J Obstet Gynecol.* 2021.
- Ju D, Li X, Shi Y, Ma Y, Guo L, Wang Y et al. Evaluation of the practical applications of fluorescence in situ hybridization in the prenatal diagnosis of positive noninvasive prenatal screenings. *J Maternal-Fetal Neonatal Med* 2021:1–8
- Mardy A, Wapner RJ. Confined placental mosaicism and its impact on confirmation of NIPT results. *Am J Med Genet C Semin Med Genet.* 2016;172(2):118–22.
- Brar R, Basel DG, Bick DP, Weik L, vanTuinen P, Peterson JF. Mosaic trisomy 9p in a patient with mild dysmorphic features and normal intelligence. *J Assoc Genetic Technol.* 2017;43(2):56–8.
- Cammarata-Scalisi F. Trisomy 9p. A brief clinical, diagnostic and therapeutic description. *Archivos Argentinos de Pediatría.* 2019;117(5):e473–6.
- Sato A, Suzuki T, Ikeno M, Takeda J, Yamamoto Y, Shinohara M, et al. Pure 9p duplication syndrome with aplasia of the middle phalanges of the fifth fingers. *Eur J Med Genet.* 2020;63(10): 104005.
- Leone PE, Pérez-Villa A, Yumiceba V, Hernández M, García-Cárdenas JM, Armendáriz-Castillo I, et al. De novo duplication of chromosome 9p in a female infant: phenotype and genotype correlation. *J Pediatr Genet.* 2020;9(1):69–75.
- Zou YS, Huang XL, Ito M, Newton S, Milunsky JM. Further delineation of the critical region for the 9p-duplication syndrome. *Am J Med Genet A.* 2009;149a(2):272–6.
- Saito T, Parsia S, Papolos DF, Lachman HM. Analysis of the pseudoautosomal X-linked gene SYBL1 in bipolar affective disorder: description of a new candidate allele for psychiatric disorders. *Am J Med Genet.* 2000;96(3):317–23.
- Helena Mangs A, Morris BJ. The human pseudoautosomal region (PAR): origin. *Funct Future Current Genom.* 2007;8(2):129–36.
- Gounni AS, Hamid Q, Rahman SM, Hoeck J, Yang J, Shan L. IL-9-mediated induction of eotaxin1/CCL11 in human airway smooth muscle cells. *J Immunol.* 2004;173(4):2771–9.
- Santos-Rebouças CB, Boy R, Vianna EQ, Gonçalves AP, Piergiorgio RM, Abdala BB, Dos Santos JM, Calassara V, Machado FB, Medina-Acosta E, Pimentel MMG. Skewed X-chromosome inactivation and compensatory upregulation of escape genes precludes major clinical symptoms in a female with a large Xq deletion. *Front Genet.* 2020;11:101.
- Strong A, Callahan KP, Guo R, Ron H, Zackai EH. X-Autosome translocations: X-inactivation and effect on phenotype. *Clin Dysmorphol.* 2021;30(4):186–8.
- Furlan G, Galupa R. Mechanisms of choice in x-chromosome inactivation. *Cells.* 2022;11(3)
- Pereira G, Dória S. X-chromosome inactivation: implications in human disease. *J Genet.* 2021;100:63.
- Sisdelli L, Vidi AC, Moysés-Oliveira M, Di Battista A, Bortolai A, Moretti-Ferreira D, da Silva MR, Melaragno MI, Carvalheira G. Incorporation of 5-ethynyl-2'-deoxyuridine (EdU) as a novel strategy for identification of the skewed X inactivation pattern in balanced and unbalanced X-rearrangements. *Hum Genet.* 2016;135(2):185–92.
- Watanabe T, Ishibashi M, Suganuma R, Ohara M, Soeda S, Komiya H, et al. Mild phenotypes associated with an unbalanced X-autosome translocation, 46, X, der(X)t(X;8)(q28;q13). *Clinical case reports.* 2018;6(8):1561–4.
- Ciaccio C, Redaelli S, Bentivegna A, Marelli S, Crosti F, Sala EM, et al. Unbalanced X; autosome translocations may lead to mild phenotypes and are associated with autoimmune diseases. *Cytogenet Genome Res.* 2020;160(2):80–4.
- Chen CP, Lin CC, Li YC, Hsieh LJ, Lee CC, Wang W. Primary ovarian failure in a mentally retarded woman with a de novo unbalanced X;autosome translocation. *Fertil Steril.* 2006;86(5):1514.e1–e2.
- Guo QS, Qin SY, Zhou SF, He L, Ma D, Zhang YP, Xiong Y, Peng T, Cheng Y, Li XT. Unbalanced translocation in an adult patient with premature ovarian failure and mental retardation detected by spectral karyotyping and array-comparative genomic hybridization. *Eur J Clin Invest.* 2009;39(8):729–37.
- Stankiewicz P, Kuechler A, Eller CD, Sahoo T, Baldermann C, Lieser U, Hesse M, Gläser C, Hagemann M, Yatsenko SA, Liehr T, Horsthemke B, Clausen U, Marahrens Y, Lupski JR, Hansmann I. Minimal phenotype in a girl with trisomy 15q due to t(X;15)(q22.3;q11.2) translocation. *Am J Med Genet A.* 2006;140(5):442–52.
- Fusco F, Paciolla M, Chen E, Li X, Genesis R, Conti A, Jones J, Poeta L, Lioi MB, Ursini MV, Miano MG. Genetic and molecular analysis of a new unbalanced X;18 rearrangement: localization of the diminished ovarian reserve disease locus in the distal Xq POF1 region. *Hum Reprod.* 2011;26(11):3186–96.
- White WM, Willard HF, Van Dyke DL, Wolff DJ. The spreading of X inactivation into autosomal material of an X;autosome translocation: evidence for a difference between autosomal and X-chromosomal DNA. *Am J Hum Genet.* 1998;63:20–8.
- Sharp AJ, Robinson DO, Jacobs PA. Absence of correlation between late-replication and spreading of X inactivation in an X;autosome translocation. *Hum Genet.* 2001;109:295–302.
- Yatsenko SA, Sahoo T, Rosenkranz M, Mendoza-Londono R, Naeem R, Scaglia F. Attenuated phenotype in a child with trisomy for 1q due to unbalanced X;1 translocation [46, X, der(X), t(X;1)(q28;q32.1)]. *Am J Med Genet A.* 2004;128A(1):72–7.
- García-Heras J, Martín JA, Witchel SF, Scacheri P. De novo der(X)t(X;10)(q26;q21) with features of distal trisomy 10q: case report of paternal origin identified by late replication with BrdU and the human androgen receptor assay (HAR). *J Med Genet.* 1997;34(3):242–5.
- Jing X, Liu H, Zhu Q, Liu S, Liu J, Bai T, et al. Clinical selection of prenatal diagnostic techniques following positive noninvasive prenatal screening results in Southwest China. *Front Genet.* 2021;12: 811414.

### Publisher's Note

Springer Nature remains neutral with regard to jurisdictional claims in published maps and institutional affiliations.