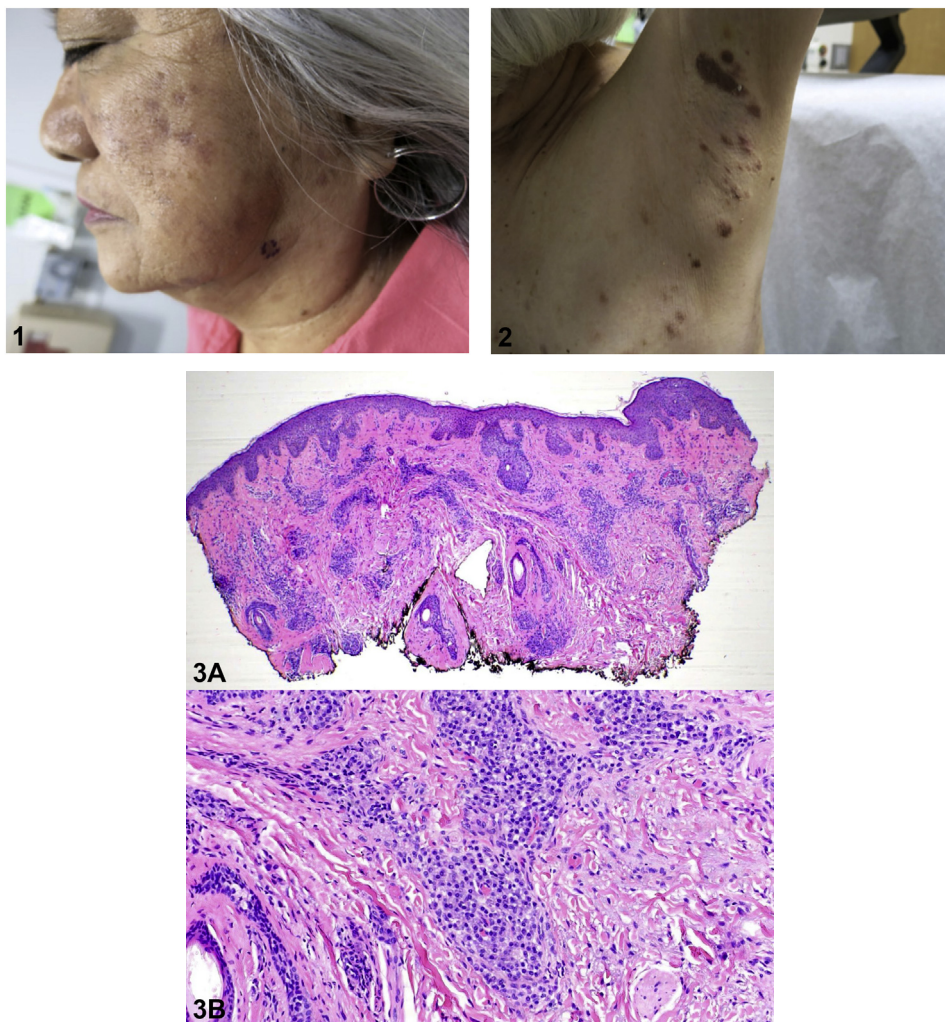


Asymptomatic, reddish-brown papules and plaques in an elderly Japanese woman



Nikifor K. Konstantinov, MD,^{a,b} Christina Boull, MD,^a and Matthew Mansh, MD^a
Minneapolis, Minnesota

Key words: cutaneous and systemic plasmacytosis; IgG4; plasma cells.



A woman in her 70s of Japanese ethnicity presented for evaluation of a more than 10-year history of asymptomatic, reddish-brown papules and plaques on her chest, axillae, face, and neck (Figs 1 and 2). Punch biopsy of a representative lesion demonstrated diffuse and deep, perivascular and perifollicular infiltrate

From the Department of Dermatology^a and the Department of Internal Medicine,^b University of Minnesota, Minneapolis.

Funding sources: None.

IRB approval status: Not applicable.

Correspondence to: Matthew Mansh, MD, Department of Dermatology, University of Minnesota, 516 Delaware St. SE, MMC 98, Minneapolis, MN 55455. E-mail: mansh@umn.edu.

JAAD Case Reports 2022;21:179-81.
2352-5126

© 2022 by the American Academy of Dermatology, Inc. Published by Elsevier, Inc. This is an open access article under the CC BY-NC-ND license (<http://creativecommons.org/licenses/by-nc-nd/4.0/>).

<https://doi.org/10.1016/j.jidcr.2021.09.045>

composed primarily of plasma cells (Fig 3, A and B). Immunohistochemistry for CD20, CD21, B-cell lymphoma 6 protein, and human herpesvirus 8 was negative. *In situ* hybridization demonstrated κ light chain restriction. B-cell gene rearrangement studies from fixed tissue were negative for a clonal population. Serum protein electrophoresis showed a polyclonal increase in the gamma fraction at 2.2 g/dL (normal range: 0.7--1.6 g/dL). Serum IgG4 was elevated at 170 mg/dL (normal range: 11-86 mg/dL), with a normal total IgG level and normal serum interleukin 6 (IL-6) level. IgG and IgG4 immunostains were performed on the biopsy specimen, and IgG4 stained approximately 10% of IgG⁺ plasma cells. The results of computed tomography of the chest, abdomen, and pelvis were unremarkable.

Question 1: What is the most likely diagnosis?

- A. Cutaneous and systemic plasmacytosis (CSP)
- B. Primary cutaneous marginal zone B-cell lymphoma
- C. Pseudolymphoma
- D. Cutaneous sarcoidosis
- E. Multicentric Castleman disease (MCD)

Answers:

A. CSP — Correct. CSP is a rare disorder that occurs most commonly in middle-aged individuals of Japanese descent. It is characterized by extensive reddish-brown papules, plaques, and/or nodules, typically over the trunk. The histologic features most often show a polyclonal plasma cell infiltrate. However, a handful of described cases demonstrate light-chain restriction, as in our case.¹ The disease typically has a benign and chronic course, but it is frequently associated with extracutaneous manifestations, and workup for systemic involvement with long-term follow-up is recommended.

B. Primary cutaneous marginal zone B-cell lymphoma — Incorrect. CSP may be difficult to distinguish from primary cutaneous marginal zone B-cell lymphoma, particularly in cases with light-chain restriction. The presentation of characteristic reddish-brown lesions that favor the trunk, chronicity of eruption, presence of extracutaneous manifestations, Asian (particularly Japanese) ethnicity, absence of CD20⁺ B-cells on immunohistochemistry, and negative B-cell gene rearrangement studies favor CSP.¹

C. Pseudolymphoma — Incorrect. Pseudolymphomas may be B-cell or T-cell predominant and are usually triggered by infections, drugs, or foreign agents (eg, tattoos or vaccinations). The lesions may be solitary or multifocal; however, systemic symptoms are typically absent. Histologically, there is a superficial and deep, nodular lymphocytic infiltrate with admixed histiocytes, occasional plasma cells, and eosinophils; clonality is not usually seen.²

D. Cutaneous sarcoidosis — Incorrect. Although cutaneous sarcoidosis may be a clinical mimic of CSP, the histopathology of our case does not support this diagnosis.

E. MCD — Incorrect. MCD is characterized by generalized lymphadenopathy, hypergammaglobulinemia, anemia, and constitutional symptoms. Cutaneous manifestations of MCD are rare, but may have similar clinical and histopathologic findings to CSP. MCD, however, is classically associated with human herpesvirus 8 infection.³

Question 2: What is the most common extracutaneous manifestation in this condition?

- A. Anemia
- B. Lymphadenopathy
- C. Hepatosplenomegaly
- D. Mesangial proliferative glomerulonephritis
- E. Lymphoid interstitial pneumonia

Answers:

A. Anemia — Incorrect. Although a normocytic anemia is sometimes seen in CSP, it is not the most common extracutaneous manifestation of CSP. Anemia has been reported to occur in about 47% of cases.³

B. Lymphadenopathy — Correct. Lymphadenopathy is the most common extracutaneous manifestation of CSP.¹ One study reported the presence of lymphadenopathy in the cervical, axillary, or inguinal region in 54% of a cohort of 69 cases.³

C. Hepatosplenomegaly — Incorrect. Although hepatosplenomegaly has been reported to occur in CSP, it is not the most common extracutaneous manifestation.¹ Given the high frequency of lymphoplasmacytic infiltration of extracutaneous sites, assessing for internal organ involvement with computed tomographic imaging is recommended.

D. Mesangial proliferative glomerulonephritis — Incorrect. Mesangial proliferative glomerulonephritis is seen in CSP, but it is rare. Other renal

manifestations have also been described, including renal failure and renal amyloidosis.^{1,3} Given the paucity of cases described in the literature, it may be reasonable to monitor for renal involvement.³

E. Lymphoid interstitial pneumonia – Incorrect. Lymphoid interstitial pneumonia may also be seen in CSP, but it is not the most common extracutaneous manifestation. Although most patients with CSP have a benign course, 14% have lung involvement, usually as lymphoid interstitial pneumonia, which can be a marker of severe disease.³

Question 3: Which serologic laboratory test may be elevated in this disorder?

- A.** Hemoglobin
- B.** IL-4
- C.** Lactate dehydrogenase
- D.** Calcium
- E.** IgG4

Answers:

A. Hemoglobin – Incorrect. Hemoglobin is not elevated in CSP. In fact, a normocytic anemia is one of the manifestations that may occur with CSP.¹

B. IL-4 – Incorrect. IL-6, but not IL-4, levels are typically elevated in CSP. IL-6 may be an important marker implicated in the pathogenesis of CSP, because patients may respond to pharmacologic therapy that interferes with IL-6 activity.³ There is no established treatment protocol for CSP yet, given the rarity of the disease.

C. Lactate dehydrogenase – Incorrect. Lactate dehydrogenase is not classically associated with CSP, although it is a marker that may be elevated in certain malignancies, including some forms of cutaneous lymphomas.

D. Calcium – Incorrect. Calcium is not elevated in CSP. It may be elevated in granulomatous conditions, such as sarcoidosis (as discussed in the differential diagnosis above), due to up-regulation of extrarenal hydroxylase, which converts 25-hydroxyvitamin D to the active 1,25-dihydroxyvitamin D, resulting in hypercalcemia.⁴

E. IgG4 – Correct. Observations of a high ratio of IgG4⁺ plasma cells in some CSP patients raise the possibility of a similar pathogenesis in CSP and IgG4-related disease (IgG4-RD). However, it is still unclear whether CSP should be categorized as a subtype of IgG4-RD. IgG4-RD is characterized by high levels of IgG4, tissue infiltration of IgG4⁺ plasma cells, and fibroinflammatory changes involving multiple organs (classically the pancreas, gallbladder, and salivary or lacrimal glands). Immunohistochemistry of involved tissues in IgG4-RD characteristically demonstrates an IgG4:IgG ratio greater than 40%.⁵ Skin manifestations of IgG4-RD typically include papules, plaques, and nodules of the head and neck, but the skin findings are not included in the American College of Rheumatology/European Alliance of Associations for Rheumatology Classification Criteria for IgG4-RD.⁵

The authors thank Daniel D. Miller, MD, and Kevin Gaddis, MD, at the University of Minnesota, for helping with the histopathologic images of this patient.

Abbreviations used:

CSP: cutaneous and systemic plasmacytosis

IgG4-RD: IgG4-related disease

IL: interleukin

MCD: multicentric Castleman disease

Conflicts of interest

None disclosed.

REFERENCES

1. Honda R, Cerroni L, Tanikawa A, et al. Cutaneous plasmacytosis: report of 6 cases with or without systemic involvement. *J Am Acad Dermatol.* 2013;68(6):978-985. <https://doi.org/10.1016/j.jaad.2012.11.031>
2. Romero-Pérez D, Martínez MB, Encabo-Durán B. Cutaneous pseudolymphomas. *Actas Dermosifilogr.* 2016;107(8):640-651. <https://doi.org/10.1016/j.ad.2016.05.003>
3. Haque M, Hou JS, Hisamichi K, et al. Cutaneous and systemic plasmacytosis vs. cutaneous plasmacytic Castleman disease: review and speculations about pathogenesis. *Clin Lymphoma Myeloma Leuk.* 2011;11(6):453-461. <https://doi.org/10.1016/j.clml.2011.07.004>
4. Kamphuis LS, Bonte-Mineur F, van Laar JA, et al. Calcium and vitamin D in sarcoidosis: is supplementation safe? *J Bone Miner Res.* 2014;29(11):2498-2503.
5. Charrow A, Imadojemu S, Stephen S, et al. Cutaneous manifestations of IgG4-related disease (RD): a systematic review. *J Am Acad Dermatol.* 2016;75(1):197-202. <https://doi.org/10.1016/j.jaad.2016.01.046>