

CASE REPORT

# First case of penile metastasis following abdominoperineal resection with VRAM flap reconstruction

Andrei A. Kozan<sup>1,\*</sup>, Adrian M. Smith<sup>2</sup>, David W. Ilsley<sup>2</sup>,  
and Nicholas Rhodes<sup>3</sup>

<sup>1</sup>Department of Urology, Calderdale and Huddersfield NHS Foundation Trust, Huddersfield HD3 3EA, United Kingdom, <sup>2</sup>Department of General Surgery, Calderdale and Huddersfield NHS Foundation Trust, Huddersfield HD3 3EA, United Kingdom, and <sup>3</sup>Department of Plastic Surgery, Calderdale and Huddersfield NHS Foundation Trust, Huddersfield HD3 3EA, United Kingdom

\*Correspondence address. Department of Urology, Calderdale and Huddersfield NHS Foundation Trust, Huddersfield HD3 3EA, United Kingdom.  
Tel: +44-07706463749; E-mail: andreikozan@gmail.com

## Abstract

Penile metastases are rare in colorectal cancer. We report the first case of such a recurrence in a patient who had undergone an extralevator abdominoperineal resection with vertical rectus abdominis myocutaneous flap perineal reconstruction. The patient was treated with curative intent by total penectomy.

## INTRODUCTION

Although a richly vascularized organ with important circulatory communications, the penis is seldom the site of metastases. Since Eberth first reported it in 1870 there have been approximately 300 cases in the English language literature [1]. The primary tumour sites are principally the genitourinary organs, mainly the bladder and prostate gland. Only in 15.7% is the primary from the colon. Metastatic disease isolated to the penis and amenable to potentially curative treatment is very uncommon [1–3]. This is the first case of isolated penile metastasis following abdominoperineal resection (APER) with perineal vertical rectus abdominis myocutaneous (VRAM) flap reconstruction.

## CASE REPORT

A 58-year-old gentleman presented with diarrhoea. Digital rectal examination revealed a low anterior rectal tumour, 3 cm from the anal verge. Staging revealed a 10.5 cm T3 N0 M0 circumferential resection margin (CRM) positive lower third rectal cancer. Due to his frequency he underwent laparoscopic defunctioning colostomy prior to neoadjuvant long course chemoradiation in the Aristotle trial. Restaging showed a modest response to treatment with the CRM still predicted positive (Figs 1 and 2). At 9 weeks post radiotherapy he underwent an open difficult APER at which there was suspicion of previous tumour perforation. The operation was combined with a VRAM flap to reconstruct the pelvic floor. Histology revealed a T3 N0

Received: July 14, 2016. Accepted: October 20, 2016

Published by Oxford University Press and JSCR Publishing Ltd. All rights reserved. © The Author 2016.

This is an Open Access article distributed under the terms of the Creative Commons Attribution Non-Commercial License (<http://creativecommons.org/licenses/by-nc/4.0/>), which permits non-commercial re-use, distribution, and reproduction in any medium, provided the original work is properly cited. For commercial re-use, please contact [journals.permissions@oup.com](mailto:journals.permissions@oup.com)

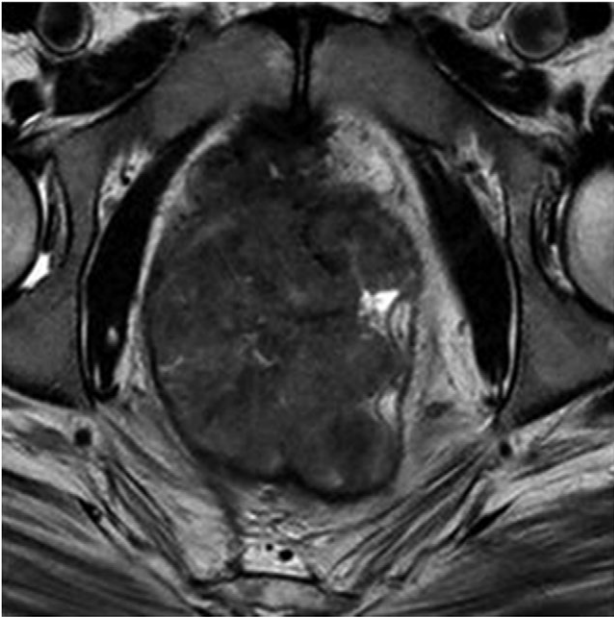


Figure 1: MRI pelvis. T2 waited axial image through lower pelvis through the large polypoid rectal tumour with T3 extension involving the CRM.

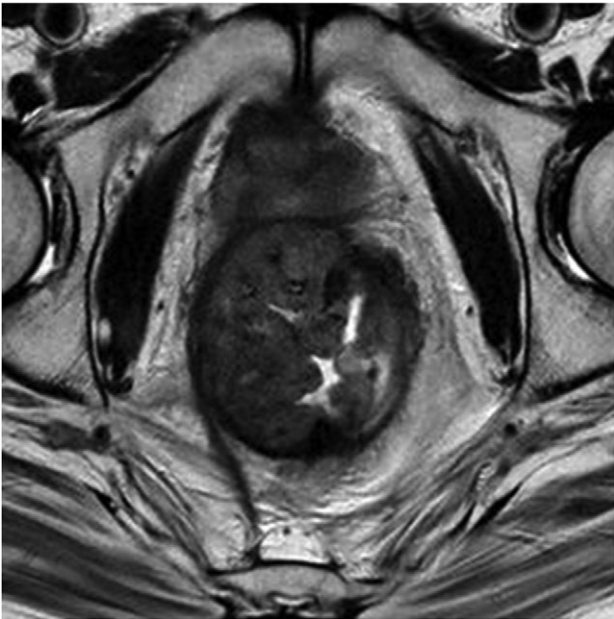


Figure 2: MRI pelvis. T2 axial image through pelvis demonstrating limited response to chemoradiotherapy with tumoral margins still predicted positive.

R1 resection positive at the right lateral margin. He underwent adjuvant chemotherapy as per the trial protocol.

At 18 months post-surgery he presented with an otherwise asymptomatic mass on the lateral aspect of his penile shaft. Restaging with CT and MRI confirmed an isolated 2.7 cm × 6.2 cm lesion in the midshaft involving the corpora cavernosum with extension into the corpus spongiosum. The urethra appeared spared (Fig. 3). Biopsies were consistent with a colorectal primary (Fig. 4). Following multidisciplinary discussions and frank discussions with the patient it was agreed to proceed to total penectomy (Fig. 5) with suprapubic catheter and perineal

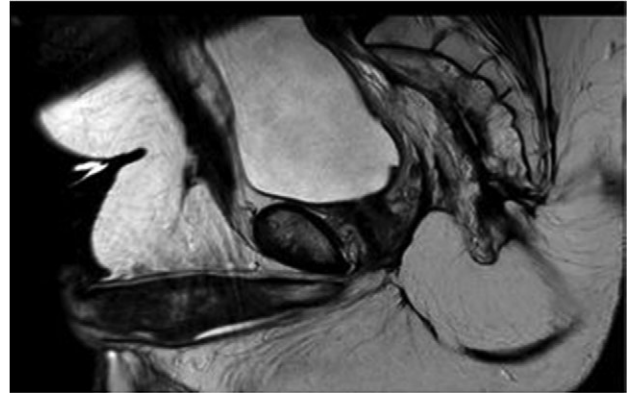


Figure 3: MRI pelvis large field T2 sagittal image through penile shaft showing the lesion involving the corpora cavernosum with extension in the spongiosum.

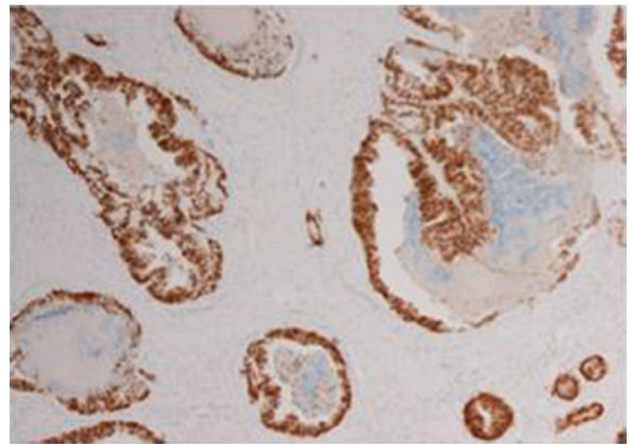


Figure 4: Immunohistochemistry of the biopsied lesion demonstrating CDX2 positivity.

urethrostomy. Histopathology confirmed metastatic rectal adenocarcinoma with clear resection margins though extensive lympho-vascular and perineural involvement. Currently, the patient is clinically doing well, with a reasonable quality of life with his urethrostomy and under close clinical follow up.

## DISCUSSION

It is still a controversial subject the reason why the penis, despite its vascularization is a rare site for metastasis. It has been postulated that the route of metastasis include retrograde venous or lymphatic spread, local direct extension, arterial embolism or instrumental spread [1, 2, 4]. Currently the most accepted theory is the mechanism that involves retrograde venous spread from pudendal to the dorsal venous system of the penis [2, 4]. The most common type of presentation is malignant priapism followed by urinary retention, penile nodules, ulceration, perineal pain, oedema, infiltrative enlargement, dysuria and haematuria, with the corpora cavernosa being the most common site of metastasis and the glans and corpus spongiosum infrequently involved [1]. Our case respected the above mentioned cavernosal involvement but also had mild extension into the corpus spongiosum, more to the fact that this isolated metastatic penile neoplasm is extremely rare.

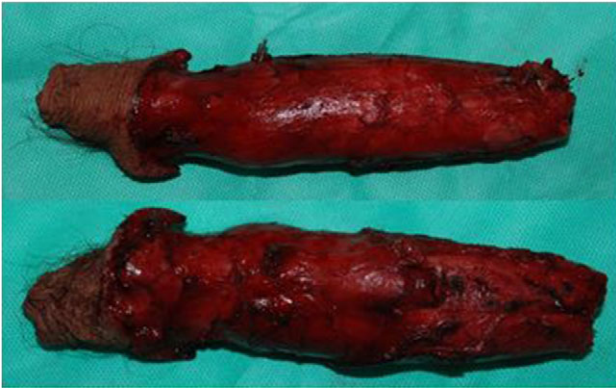

Figure 5: Dorsal and ventral view of specimen following total penectomy.

Management of penile metastasis is mainly palliative [5] as this is a sign of poor prognosis and tends to be part of widely disseminated disease. The majority die within a year [6]. This however is not the case in our present communication.

Treatment plan is influenced by the size of the primary, extent of the metastatic spread, performance status of patient and also prognostic characteristics of the primary tumour [2, 5]. Treatment modalities include the combination of radiotherapy with chemotherapy, local excision and penectomy [2, 4]. In isolated disease, as described in this case, penectomy may offer the possibility of cure although such cases are very rare.

In conclusion, this is a case report of penile metastasis following rectal adenocarcinoma, being the first one described in a patient that had APER with VRAM flap reconstruction.

The patient underwent complete penile resection for curative purpose contrary to palliative treatment. This report highlights the rarity of the penis as site of metastasis and marker of disseminated disease, however this is not the case in our report and albeit rare, cure can be achieved in isolated cases.

### CONFLICT OF INTEREST STATEMENT

None declared.

### REFERENCES

1. Hizli F, Berkmen F. Penile metastasis from other malignancies. A study of ten cases and review of literature. *Urol Int* 2006;**76**:118–21.
2. Kimura Y, Shida D, Nasu K, Matsunaga H, Warabi M, Inoue S. Metachronous penile metastasis from rectal cancer after total pelvic exenteration. *World J Gastroenterol* 2012;**18**:5476–8.
3. Ketata S, Boulaire JL, Soulimane B, Bargain A. Metachronous metastasis to the penis from a rectal adenocarcinoma. *Clin Colorectal Cancer* 2007;**6**:657–9.
4. Park JC, Lee WH, Kang MK, Park SY. Priapism secondary to penile metastasis of rectal cancer. *World J Gastroenterol* 2009;**15**:4209–11.
5. Murhekar KM, Majhi U, Mahajan V, Satheesan B. Penile metastasis from rectal carcinoma. *Indian J Cancer* 2007;**44**: 155–6.
6. Chung TS, Chang HJ, Kim DY, Jung KH, Lim SB, Choi HS, et al. Synchronous penile metastasis from a rectal carcinoma. *Int J Colorectal Dis* 2008;**23**:333–4.