

Development of temporal lobe epilepsy during maintenance electroconvulsive therapy: A case of human kindling?

Caroline Schotte¹ | Evy Cleeren^{1,2} | Karolien Goffin^{3,4}  | Borbala Hunyadi^{5,6} | Satya Buggenhout⁷ | Koen Van Laere^{3,4} | Wim Van Paesschen^{1,2}

¹Department of Neurology, University Hospitals Leuven, Leuven, Belgium

²Laboratory for Epilepsy Research, KU Leuven, Leuven, Belgium

³Department of Nuclear Medicine, University Hospital Leuven, Leuven, Belgium

⁴Department of Imaging and Pathology, Nuclear Medicine and Molecular Imaging, KU Leuven, Leuven, Belgium

⁵Faculty of EEMCS, TU Delft, Delft, The Netherlands

⁶Department of Electrical Engineering (ESAT), STADIUS Center for Dynamical Systems, Signal Processing and Data Analytics, KU Leuven, Leuven, Belgium

⁷Department of Psychiatry, University Psychiatric Centre KU Leuven, Kortenberg, Belgium

Correspondence

Caroline Schotte, Department of Neurology, University Hospital Leuven, Leuven, Belgium.

Email: caroline.schotte@uzleuven.be.

Funding information

European Research Council under the European Union's Seventh Framework Programme, Grant/Award Number: FP7/2007-2013; ERC Advanced Grant: BIOTENSORS, Grant/Award Number: 339804

Summary

We describe a patient with new-onset temporal lobe epilepsy during prolonged maintenance electroconvulsive therapy. We suggest a possible causal relationship with maintenance electroconvulsive therapy through electrical kindling of the temporal lobe.

KEYWORDS

electroconvulsive therapy, kindling, temporal lobe epilepsy

1 | INTRODUCTION

Electroconvulsive therapy (ECT) was developed in 1938 and is used widely in the treatment of severe major depressive disorder, manic states, and schizophrenia. ECT involves the induction of a focal to bilateral tonic-clonic seizure (FBTCS) with

an electrical current administered through cranial electrodes. Most patients are treated twice or three times a week for several weeks and receive on average 6-10 ECT sessions. Some patients require maintenance treatment for an extended period.^{1,2}

Although the treatment is based on repeatedly inducing an FBTCS, ECT is assumed not to cause epilepsy. Two

This is an open access article under the terms of the Creative Commons Attribution-NonCommercial-NoDerivs License, which permits use and distribution in any medium, provided the original work is properly cited, the use is non-commercial and no modifications or adaptations are made.

© 2019 The Authors. *Epilepsia Open* published by Wiley Periodicals Inc. on behalf of International League Against Epilepsy.

epidemiologic surveys of patients treated with ECT found no evidence of increased prevalence of epilepsy independent of host susceptibility.^{3,4} The use of ECT seems safe in patients with epilepsy, and no adjustment in antiepileptic drugs (AEDs) is necessary.^{5,6} In addition, several case reports and small retrospective series on the use of ECT for refractory status epilepticus (RSE) have been published. Although ECT has been reported to improve seizure control in RSE in some studies and to reduce seizure frequency in refractory epilepsy, there is insufficient evidence to conclude on its efficacy.⁷⁻¹⁰

On the other hand, several case reports have documented status epilepticus after ECT.^{11,12} Furthermore, new-onset epilepsy after long-term ECT has been documented.^{13,14} Bryson and colleagues hypothesized electrical kindling as a possible mechanism of epileptogenesis in these patients.¹⁴ We report a patient receiving maintenance ECT for 22 years, who developed temporal lobe epilepsy (TLE), which was not controlled by 2 AEDs.

2 | CASE REPORT

This 67-year-old right-handed Caucasian woman had no personal or family history of epilepsy, febrile seizures, significant cerebral trauma, meningitis, or encephalitis. Past medical history included diabetes mellitus type 2, hyperparathyroidism, and a breast carcinoma in 2013 for which she had been treated with surgery, radiotherapy, and hormonal therapy. In 1974 she was diagnosed with bipolar disorder, which was refractory to medical treatment. Since 1995 she was treated with weekly ECT, initially with bitemporal and since 2004 with unilateral right temporal electrode placement because of cognitive deterioration. The ECT frequency was decreased to once every 2 weeks shortly before her first visit to the outpatient neurologic clinic. She

Key Points

- Electroconvulsive therapy (ECT) is a frequently used treatment in major depressive disorder, manic states, and schizophrenia
- Kindling is an animal model of epilepsy by which repeated induction of a focal seizure discharge, usually carried out by focal electrical stimulation, results in a progressive and long-lasting increase in epileptic response to the inducing stimulus
- We report a patient developing temporal lobe epilepsy after long-term maintenance ECT and suggest a possible causal relationship with maintenance ECT through electrical kindling of the temporal lobe

received a total of over 1100 sessions. ECT proved very effective in controlling the bipolar disorder. Trials to discontinue ECT in the past had resulted in important relapses of her bipolar disorder, requiring prolonged hospitalizations. She was being treated with aripiprazole, metformin, exemestane, simvastatin, acetylsalicylic acid, quetiapine, valproate 1100 mg, and insulin.

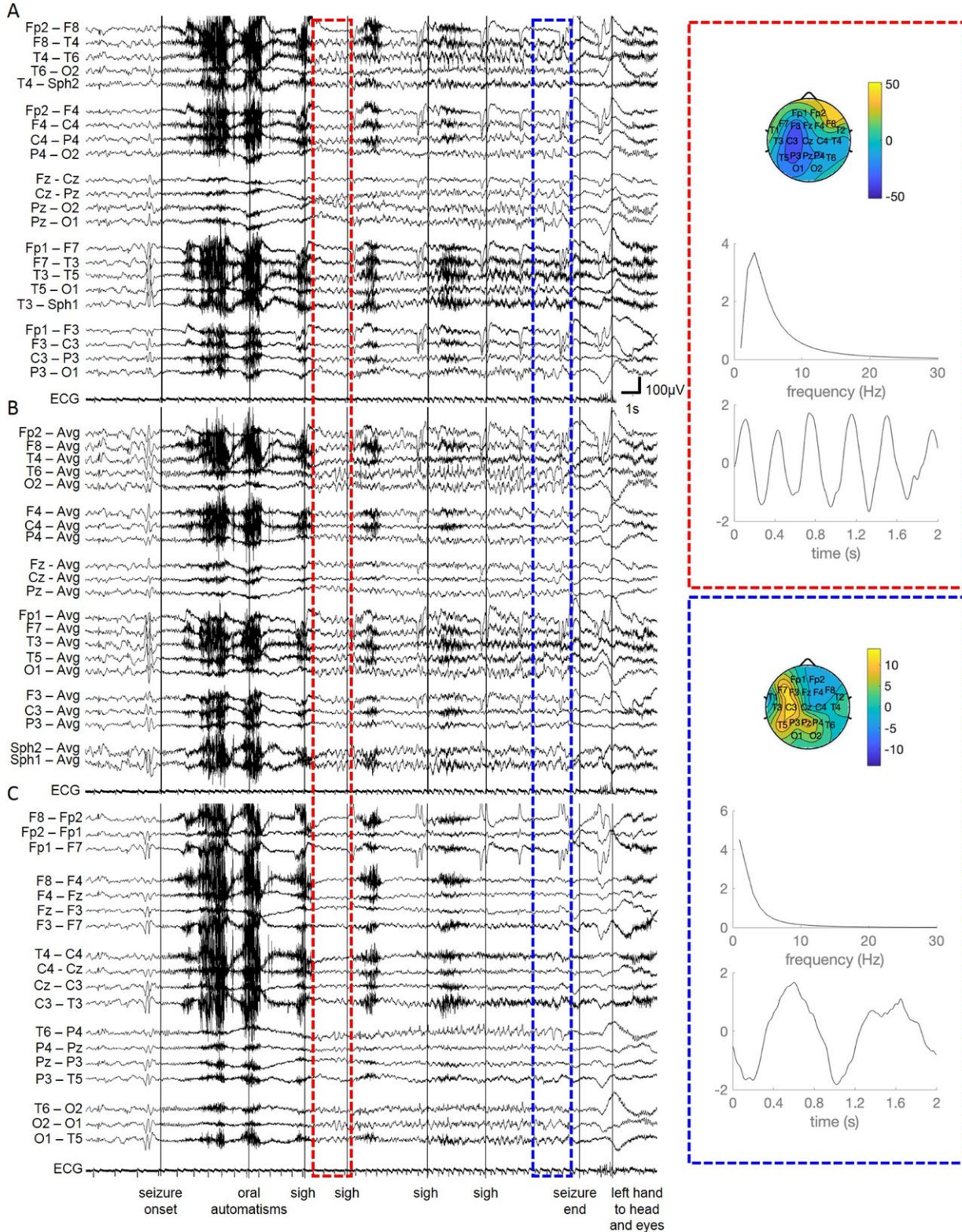
She presented to our epilepsy clinic in January 2017 for the assessment of daily episodes of hyperventilation, pallor, and confusion lasting around 30-60 seconds, which started in 2012 after she had received more than 800 sessions of ECT. No clear temporal association of these episodes and the ECT was observed. In 2013, the patient had 2 FBTCSs. The psychiatrist prescribed valproate in a total daily dose of 1100 mg, which controlled the FBTCSs. The smaller episodes were considered as psychogenic

FIGURE 1 Thirty-second EEG trace showing the ictal evolution during a nocturnal seizure in a (A) longitudinal bipolar montage, (B) common average montage, and (C) transverse montage (0.5 Hz low-pass filter; 70 Hz high-pass filter; and 50 Hz notch filter). Preceding seizure onset there is left temporal theta slowing and spikes (also seen in interictal records). At seizure onset there is a period of background attenuation with muscle artifacts due to oral automatisms. The attenuation is followed by an evolving delta rhythm, more pronounced in the right temporal regions (T4-T6 in panel A; T6-Avg and O2-Avg in panel B). Also a clear increase in ictal heart rate is observed during this seizure. Canonical polyadic decomposition (CPD, also known as PARAFAC^{16,17}) was performed on 2-second-long EEG segments after the ictal attenuation and at the end of the seizure, indicated by the red and blue rectangles, respectively. CPD is a blind source separation technique that can reliably estimate the underlying sources from a mixture of ongoing brain activity and noise using the following procedure: First, the signals were prefiltered between 1 and 30 Hz using a sixth-order Butterworth filter. Then, with application of a wavelet transform on each filtered EEG channel, the EEG matrix was expanded into third-order tensors with channel, time, and frequency along its dimensions. Then, the tensor was decomposed using CPD as a sum of 2, rank-1 tensors (components), that is, tensors that are characterized by the outer product of a single channel, frequency, and temporal signature vector. These signature vectors characterize the topography and frequency content of the seizure pattern. The seizure component can be selected as the component with the largest variance, after excluding components representing eye blinks. Notice that the spatial mode is a 2-dimensional display, with the right side corresponding to the right side of the patient. Yellow regions indicate highly positive potentials; blue regions indicate highly negative potentials. The spatial signatures (topographies) of the seizure component indicate that the seizure evolves in the right side (large values over F8, T4, T2 channels), and propagates to the left side by the end of the seizure (large values over the F7, C3, T3, T5, F3, P3, Pz channels). CPD was implemented in Matlab (Mathworks, Sherborn, MA) using the Tensorlab toolbox (www.tensorlab.net).²² For the exact mathematical formulation of the CPD method, the reader is referred to previous literature^{16,17}

nonepileptic seizures, which were not controlled on valproate. Maintenance ECT was continued.

Our clinical impression of temporal lobe focal seizures was confirmed during 5-day video–electroencephalography (EEG) recording. Six stereotyped seizures were recorded, which were characterized by hyperventilation, tachycardia,

impaired awareness, oral automatisms, automatisms with the left hand, postictal aphasia, and bringing the left hand to her face. We recorded 14 652 spikes over 101 hours, that is, 145 per hour, or 2.4 per minute. Eighty percent were left-sided, mainly midtemporal (T3) (44%) and anterotemporal (F7) (20%). Twenty percent were right-sided spikes,



mainly midtemporal (T4) (10%) and anterotemporal (F8) (8%) (Persyst 13 EEG software, low sensitivity, Persyst Development Corporation, USA). The ictal EEG recordings showed stereotypical generalized attenuation for 2 seconds followed by an evolving bitemporal rhythmic delta rhythm, sometimes lateralized to the right side (Figure 1).

Brain magnetic resonance imaging (MRI) showed frontoparietal atrophy and periventricular vascular lesions, but no temporal lobe abnormalities (Figure 2A). Ictal single-photon emission computed tomography (SPECT) was undertaken; the injection started 22 seconds after the electroencephalographic seizure onset in a seizure of only 23 seconds. SISCOM (subtraction ictal SPECT coregistered with MRI) showed left temporal lobe hyperperfusion (Figure 2A). Fluorodeoxyglucose–positron emission tomography (FDG-PET), performed 8 days after her last right-sided ECT, showed bifrontal and bitemporal hypometabolism (white arrows in Figure 2B). Anatomy-corrected asymmetry index (ACAI) analysis¹⁵ of the FDG-PET scan confirmed the bitemporal hypometabolism (orange arrows in Figure 2C). Throughout the brain, ACAI analysis showed a more extensive hypometabolism in the left

hemisphere compared to the right (for example, in the posterior temporal lobe as depicted by the orange circle in Figure 2C). Autoimmune antibodies associated with limbic encephalitis were negative. We tested for anti-GAD (Glutamic acid decarboxylase) antibodies, paraneoplastic neuronal antibodies (Hu, Yo, Ri, amphiphysin, CV2, Ma2, GAD65, Sox, Tr), anti-NMDA (*N*-methyl-D-aspartate) receptor antibodies, and anti-VGKC (Voltage gated potassium channel) antibodies.

Electroclinical data and SISCOM were consistent with TLE. The canonical polyadic decomposition (CPD, also known as PARAFAC^{16,17}), indicated that the seizure evolves in the right side and propagates to the left side by the end of the seizure (Figure 1). The patient was commenced on treatment with lamotrigine 50 mg twice a day, in addition to valproate 1100 mg daily. The frequency of ECT was reduced to once every 4 weeks but led to a manic episode requiring hospitalization. The patient and the attending psychiatrist decided to restart ECT maintenance once a week, despite the possibility that maintenance ECT was causally related to the epilepsy. Spontaneous temporal lobe focal seizures remained uncontrolled.

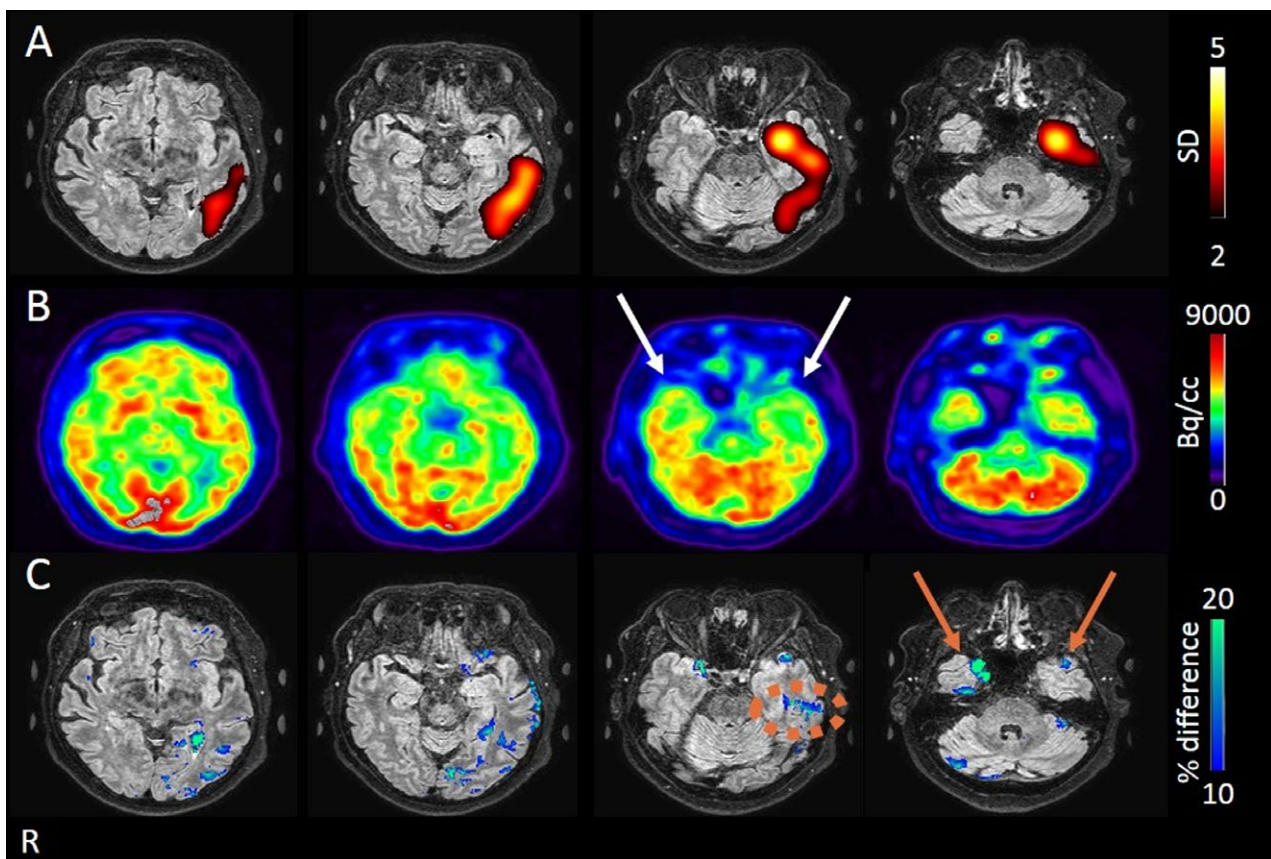


FIGURE 2 A, SISCOM images showing ictal hyperperfusion in the left temporal lobe. SISCOM images were expressed as z-scores on transversal MRI slices showing areas of hyperperfusion (yellow-red) thresholded between 2 and 4 standard deviations (SDs). B, FDG-PET showed bitemporal hypometabolism (white arrows). C, ACAI analysis of the PET image in B confirmed the bitemporal hypometabolism (with left-right asymmetries in both temporal poles, orange arrows) and revealed a more extensive hypometabolism in the left temporal lobe (orange circle). Slices are shown in the radiologic convention

3 | DISCUSSION

Published case reports about spontaneous seizures occurring after ECT are rare. Bryson et al and Rasmussen et al have described 5 and 4 patients, respectively, who developed (temporal lobe) epilepsy in the context of maintenance ECT, as in our patient. In Bryson's patients, cessation of ECT led to a clear reduction in the frequency of interictal discharges and no further clinical seizures, even in 2 patients in whom AEDs were not started.¹⁴ The 4 patients of Rasmussen obtained good seizure control after starting AEDs. In 2 of these 4 patients, maintenance ECT was continued or reintroduced without complications.¹³ In these 9 cases, the median number of administered ECT sessions at the time of diagnosis was 92 (range 36-348). No cases of developing epilepsy after only a short induction therapy of ECT have been described.

Because epilepsy is not a rare disorder and ECT is widely used, co-occurrence of epilepsy and ECT is insufficient to prove a causal relationship. Still, we suggest a possible causal relationship with ECT in our patient through electrical kindling of the temporal lobe. The kindling model was introduced by Goddard et al in 1969 and represents a phenomenon by which repeated induction of a focal seizure discharge, usually carried out by focal electrical stimulation, results in a progressive and long-lasting increase in epileptic response to the inducing stimulus.¹⁸⁻²⁰ There are a number of reports indicating that kindling in animals can lead to the development of spontaneous seizures after a large number of stimulations; nevertheless this observation is not universal for all kindled animals.¹⁹ ECT is different compared to kindling animal models in that the inducing currents in humans are much higher in order to elicit the most severe seizure type, namely FBTCSSs, from the beginning. We have several arguments to suggest that kindling is the probable cause of the TLE in our patient. The temporal lobe, and more particularly the amygdala, is the brain structure most susceptible to kindling epileptogenesis, which is targeted during ECT. To date, the kindling phenomenon has been observed in all animals studied, although more kindling stimulations are needed in phylogenetically higher animals. On average, 18 daily stimulations are required to fully kindle a rat, 25 for a cat, 72 for a baboon, and over 400 days for a rhesus monkey.²¹ From the data available, we estimate that kindling in humans may result in spontaneous seizures after on average 90 ECT sessions (range 36-800), that is, not after an acute ECT treatment that lasts 6-10 sessions. Our patient received more than 1100 ECT treatment sessions, which is the highest number reported in the literature. After around 800 sessions, she developed TLE, which has remained refractory to treatment

with AEDs, consistent with the progressive nature of kindling epileptogenesis.

4 | CONCLUSION

We describe a patient with new-onset TLE during prolonged maintenance ECT. We suggest a possible causal relationship with maintenance ECT through electrical kindling of the temporal lobe. Development of TLE may be a complication of prolonged maintenance ECT.

ACKNOWLEDGMENTS

The research leading to the Canonical polyadic decomposition results has received funding from the European Research Council under the European Union's Seventh Framework Programme (FP7/2007-2013)/ERC Advanced Grant: BIOTENSORS (no 339804). This paper reflects only the authors' views and the EU is not liable for any use that may be made of the contained information.

DISCLOSURE

None of the authors has any conflict of interest to disclose. We confirm that we have read the Journal's position on issues involved in ethical publication and affirm that this report is consistent with those guidelines.

ORCID

Karolien Goffin  <https://orcid.org/0000-0002-7453-0229>

REFERENCES

1. Kellner CH, Knapp RG, Petrides G, et al. Continuation electroconvulsive therapy vs pharmacotherapy for relapse prevention in major depression. *Arch Gen Psychiatry*. 2006;63:1337-44.
2. Petrides G, Tobias KG, Kellner CH, et al. Continuation and maintenance electroconvulsive therapy for mood disorders: review of the literature. *Neuropsychobiology*. 2011;64:129-40.
3. Blackwood DHR, Cull RE, Freeman CPL, et al. A study of the incidence of epilepsy following ECT. *J Neurol Neurosurg Psychiatry*. 1980;43:1098-102.
4. Devinsky O, Duchowny MS. Seizures after convulsive therapy: a retrospective case survey. *Neurology*. 1983;33:921-5.
5. Marchetti RL, Fiore LA, Peluso MA, et al. Safety and efficacy of ECT in mental disorders associated with epilepsy: report of three cases. *J ECT*. 2003;19:173-6.
6. Lunde ME, Lee EK, Rasmussen KG. Electroconvulsive therapy in patients with epilepsy. *Epilepsy Behav*. 2006;9:355-9.
7. Kamel H, Cornes SB, Hegde M, et al. Electroconvulsive therapy for refractory status epilepticus: a case series. *Neurocrit Care*. 2010;12:204-10.

8. Zeiler FA, Matuszczak M, Teitelbaum J, et al. Electroconvulsive therapy for refractory status epilepticus: a systematic review. *Seizure*. 2016;35:23–32.
9. Griesemer DA, Kellner CH, Beale MD, et al. Electroconvulsive therapy for treatment of intractable seizures. Initial findings in two children. *Neurology*. 1997;49:1389–92.
10. Asadi-pooya AA, Razavizadegan MA, Sahraian A. Adjunctive use of electroconvulsive therapy in patients with Lennox-Gastaut syndrome and drug-resistant epilepsy: a pilot study. *Med J Islam Repub Iran*. 2016;30:413.
11. Povlsen UJ, Wildschjødzt G, Høgenhaven H, et al. Nonconvulsive status epilepticus after electroconvulsive therapy. *J ECT*. 2003;19:164–9.
12. Grogan R, Wagner DR, Sullivan T, et al. Generalized nonconvulsive status epilepticus after electroconvulsive therapy. *Convuls Ther*. 1995;11:51–6.
13. Rasmussen KG, Lunde ME. Patients who develop epilepsy during extended treatment with electroconvulsive therapy. *Seizure*. 2007;16:266–70.
14. Bryson A, Gardner H, Wilson I, et al. Temporal lobe epilepsy following maintenance electroconvulsive therapy—Electrical kindling in the human brain? *Epilepsia*. 2016;57:216–20.
15. Zhou L, Dupont P, Baete K, et al. NeuroImage detection of inter-hemispheric metabolic asymmetries in FDG-PET images using prior anatomical information. *NeuroImage*. 2009;44:35–42.
16. De Vos M, Vergult A, De Lathauwer L, et al. Canonical decomposition of ictal scalp EEG reliably detects the seizure onset zone. *NeuroImage*. 2007;37:844–54.
17. Hunyadi B, Camps D, Sorber L, et al. Block term decomposition for modelling epileptic seizures. *EURASIP J Adv Signal Process*. 2014;1:139.
18. Goddard GV, McIntyre DC, Leech CK. A permanent change in brain function resulting from daily electrical stimulation. *Exp Neurol*. 1969;25:295–330.
19. Bertram E. The relevance of kindling for human epilepsy. *Epilepsia*. 2007;48(Suppl. 2):65–74.
20. Morimoto K, Fahnstock M, Racine RJ. Kindling and status epilepticus models of epilepsy: rewiring the brain. *Prog Neurobiol*. 2004;73:1–60.
21. Cain DP. Kindling and the amygdala. In: *The amygdala: neurobiological aspects of emotion, memory, and mental dysfunction*. Aggleton JP, editor. Wilmington, DE: Wiley-Liss Inc; 1992: p. 539–60.
22. Vervliet N, Debals O, Sorber L, et al. Tensorlab 3.0. Available from <https://www.tensorlab.net/>. March 2016.

How to cite this article: Schotte C, Cleeren E, Goffin K, et al. Development of temporal lobe epilepsy during maintenance electroconvulsive therapy: A case of human kindling? *Epilepsia Open*. 2019;4:200–205. <https://doi.org/10.1002/epi4.12294>