

CASE REPORT

doi: 10.5455/medarch.2021.75.467-470

MED ARCH. 2021 DEC; 75(6): 467-470

RECEIVED: NOV 25, 2021

ACCEPTED: DEC 11, 2021

Department of Neonatology, Cantonal Hospital Bihac.

Corresponding author: Mediha Kardasevic, Department of Neonatology, Cantonal Hospital Bihac. E-mail medihakardasevic@hotmail.com.

Therapeutic Modalities in the Treatment of Persistent Ductus Arteriosus in Premature Babies: Report of Two Cases

Mediha Kardasevic, Senka Mesihovic-Dinarevic, Azra Hadzic Kecalovic

ABSTRACT

Background: Persistent Ductus Arteriosus (PDA) is a vascular structure that connects the pulmonary artery and the descending aorta. It plays an important role in the fetal blood flow pattern. **Objective:** The aim of this paper is to present two cases from Neonatology of Cantonal hospital in Bihac, with hemodynamically significant ductus, different "timing" of treatment and different therapeutic options. **Results and Discussion:** The ductus closes functionally within the first 72 to 96 hours after the birth. Its anatomical closure follows in the next 14 days. If it remains open after the third month of life, it is treated as a congenital heart anomaly with a left-right shunt. Approximately 10% of all congenital heart defects are PDA with an incidence of 2-4 per 1000 live births. It has been clinically proven that PDA is present in 45% of premature babies with a birth weight of less than 1750 g and in about 80% of premature babies with a birth weight below 1200 g. As criteria for the application of drug therapy (in this case we use Paracetamol) for ductal closure, we took into account clinical parameters and echo parameters that indicated that it was a hemodynamically significant ductal shunt. Prerequisites for treatment were normal liver function confirmed by laboratory tests, normal platelet count, no intracranial hemorrhage, normal gastrointestinal function, normal coagulation parameters, normal renal function, calm parameters of inflammation. **Conclusion:** The diagnosis of PDA in the early, asymptomatic phase, in premature babies, is made by early echocardiographic examination. The decision on treatment should be based on clinical and echocardiographic criteria. Paracetamol is an alternative in the treatment of this cardiac problem of premature infants and could be more effective if used in early, presymptomatic phase.

Key words: premature babies, persistent ductus arteriosus.

1. BACKGROUND

Persistent Ductus Arteriosus (PDA) is a vascular structure that connects the pulmonary artery and the descending aorta. It plays an important role in the fetal blood flow pattern. The ductus closes functionally within the first 72 to 96 hours after the birth. Its anatomical closure follows in the next 14 days. If it remains open after the third month of life, it is treated as a congenital heart anomaly with a left-right shunt. Approximately 10% of all congenital heart defects are PDA with an incidence of 2-4 per 1000 live births (1). It has been clinically proven that PDA is present in 45% of premature babies with a birth weight of less than 1750 g and in about 80% of premature babies with a birth weight below 1200 g. A hemodynamically significant ductus occurs in about 15% of premature babies with a birth weight of less than 1750 g and in 40 to 50% of premature babies with a birth weight of less than 1500 g (2). Left-right shunt at the level of the ductus, in premature babies, leads to pulmonary hypercirculation, reduction of systemic blood flow, significant pulmonary morbidity. Pulmonary edema reduces lung compliance which increases the premature baby's dependence on oxygen, requires and prolongs respiratory support which results in bronchopulmonary dysplasia, pulmonary hemorrhage. It contributes to the development of necrotizing enterocolitis, intracranial hemorrhage and significantly increases the incidence of premature mortality (3, 4, 5).

Although the effect of moderately large and large shunts at the PDA level on premature baby's morbidity and mortality is well known, there is still no consensus among neonatologists about the treatment of this most com-

© 2021 Mediha Kardasevic, Senka Mesihovic-Dinarevic, Azra Hadzic Kecalovic

This is an Open Access article distributed under the terms of the Creative Commons Attribution Non-Commercial License (<http://creativecommons.org/licenses/by-nc/4.0/>) which permits unrestricted non-commercial use, distribution, and reproduction in any medium, provided the original work is properly cited.

mon cardiac problem in neonatology. Should it be treated? How to treat it? When to treat it?

2. OBJECTIVE

The aim of this paper is to present two cases from Neonatology of Cantonal hospital in Bihac, with hemodynamically significant ductus, different “timing” of treatment and different therapeutic options.

3. METHODS

The presence of PDA was confirmed with bedside ultrasound examination by a pediatric cardiologist. There’s been used GE Logiq V5 ultrasound, 3Sc-RS micro convex probe.

Echocardiographic parameters which was considered:

- Direct visualization of ductus from high short parasternal position and measuring of diameter at the narrowest point, immediately after the junction with the pulmonary artery. PDA with diameter $\geq 1,5$ mm considered as significant.
- Confirming of ductal shunt with color doppler within the main pulmonary artery.
- Shunt to the middle of the main pulmonic artery or the pulmonic valve, considered significant;
- The flow rate was measured by using continuous Doppler (CW). Peak velocity ≥ 2 m/sec considered significant;
- Assessment of systolic function by measuring of fraction of shortening and left atrium- aortic ratio. Increase in diastolic diameter of left chambre and left atrium-aorta ratio $\geq 1,5:1$ considered significant;
- Clinical scoring parameters taken into account was heart murmur, precordium activity, peripheral pulses and heart rate (Table 1).

As criteria for the application of drug therapy for ductal closure, we took into account clinical parameters and echo parameters that indicated that it was a hemodynamically significant ductal shunt. Prerequisites for treatment were normal liver function confirmed by laboratory tests, normal platelet count, no intracranial hemorrhage, normal gastrointestinal function, normal coagulation parameters, normal renal function, calm parameters of inflammation.

4. CASE REPORTS

Case 1: Female preterm infant, gestational age 29.1 weeks. Birth weight was 1240 g. From the eleventh day of life systolic heart murmur was noted. Ultrasound confirmed presence of PDA. The diameter of the ductus from the short parasternal axis, measured at the narrowest point, immediately after the junction with the pulmonary artery, was 2.3 mm. A ductal shunt measured from the same position indicated a large shunt

Parameters	0	1	2
Heart rate	<160/min	160-180/min	>180/min
Heart murmur	None	Systolic	Continuous or dyastolic
Peripheral pulses	Normal	Jumping brachial	Jumping brachial and arteries of the dorsal side of the foot
Precordial activity	None	Palpable	Visible

Table 1. Clinical scoring of ductal shunting

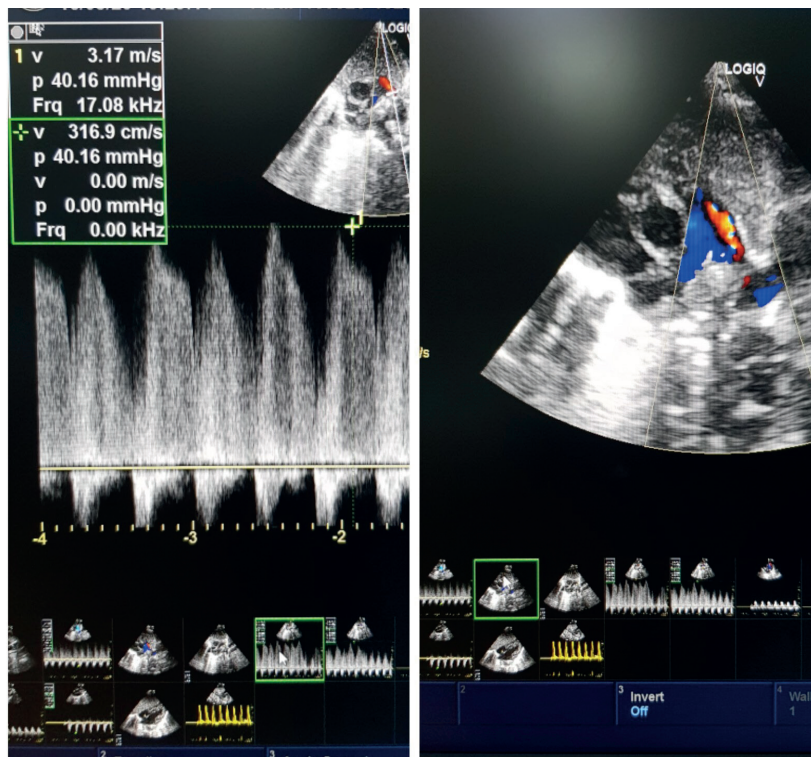


Figure 1. Ductal shunt before paracetamol therapy

to the level of the pulmonary valve with antegrade flow in the pulmonary artery. Peak velocity was 3,17 m/sec. Laboratory findings (c-reactive protein, urea, creatinine, complete blood counts, platelets, total bilirubin, liver enzymes) were in the reference values. Ultrasonography of the brain excludes intraventricular hemorrhage. The child was treated with paracetamol in dose of 10 mg/kg per dose, 4 times a day for three days. During the therapy, a series of bedside echo examinations were performed in order to monitor the dynamics of ductal closure. On the second day of therapy, the ductal shunt reaches the bifurcation of the pulmonary artery with a significantly smaller left-right shunt. On the third day of echo examination, no ductal shunt was found. At the end of the therapy, control laboratory findings (urea, creatinine, complete blood count, liver enzymes, bilirubin) were realized, which are within the reference values. Control ultrasound of the brain does not indicate intraventricular hemorrhage. During the treatment, the child has stable vital parameters, regular diuresis, and optimal enteral intake.

Case 2: Female preterm infant, gestational age 30 weeks. Birth weight was 1400 g. From the tenth day of life noted systolic heart murmur. Echo examination confirmed a ductus with diameter of 2.5 mm and large

ductal shunt reaching the level of the pulmonary valve. Peak velocity was 3,57 m/sec. Realized laboratory tests (c-reactive protein, complete blood counts, urea, creatinine, bilirubin, liver enzymes) was in reference values. Ultrasound of the brain indicates voluminous choroid plexuses with discretely dilated occipital horns of the lateral ventricles but without signs of intraventricular hemorrhage greater than stage III. Paracetamol at a dose of 10 mg/kg per dose, 4 times daily was given. A series of echo examinations did not prove ductal closure. The clinical score pointed that it was a hemodynamically significant ductus (desaturates up to 87%, heart rate above 180/min, visible precordial activity). After a failed therapeutic trial with acetaminophen, patient was treated with i.v. ibuprofen for 3 days by standard protocol, after which the ductal shunt was closed. Control laboratory findings are in reference values. Ultrasound of the brain is without changes in comparison with the findings realized before the start of therapy. During treatment, diuresis is normal, tolerates enteral intake.

5. DISCUSSION

Therapeutic modalities in the treatment of PDA are a challenge for neonatologists and pediatric cardiologists. Ductus management has evolved in the last 4 decades from preventive treatment to surgical ligation. Traditionally, non-invasive methods such as fluid restriction have been used in the conservative treatment of PDA, but it is questionable how effective they are on the large ductal shunt. Drug treatment involves giving prostaglandin synthesis inhibitors, such as indomethacin and ibuprofen, with an efficiency of 70-85% (3). On the other hand, there is a justified fear of the side effects of this therapy, which may be potentially more dangerous than the consequences of the ductal shunt itself, especially if it is a small PDA, prone to spontaneous closure. A promising alternative to the drugs used so far in ductal closure is Paracetamol, which appears to have equal efficacy and significantly fewer side effects. Should a ductal shunt be treated preventively in an asymptomatic child or in already developed symptoms? Should surgical treatment be left as an option in patients with a hemodynamically significant ductus in whom drug treatment did not give the desired effect?

The therapeutic approach varies from prophylactic treatment of the ductus in the first day of life, treatment of the early symptomatic, treatment of the late symptomatic duct to follow-up in anticipation of spontaneous closure. The most commonly used method is to treat a clinically symptomatic child, although there is insufficient evidence to support such an approach (6). In our review, both patients had a clinically positive aheart

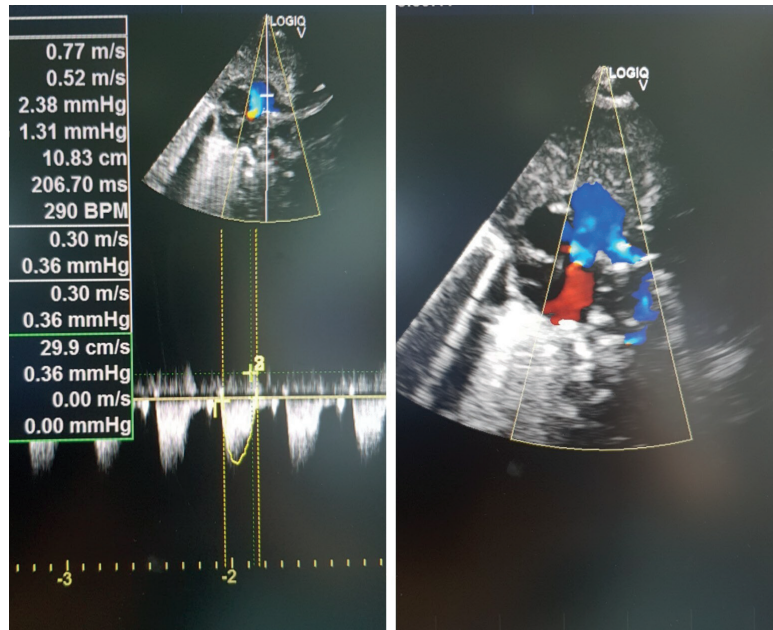


Figure 2. Ductal shunt on the third day of paracetamol therapy

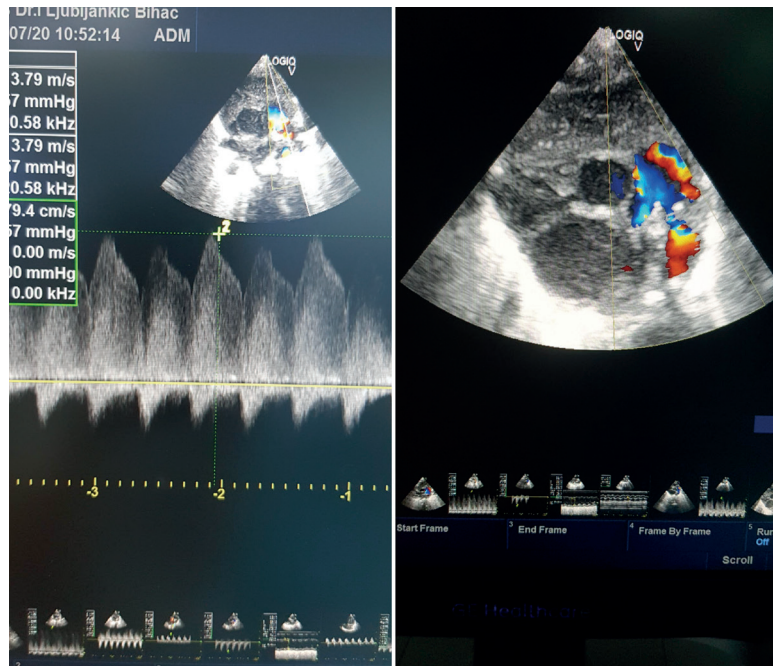


Figure 3. Ductal shunt after unsuccessful paracetamol treatment

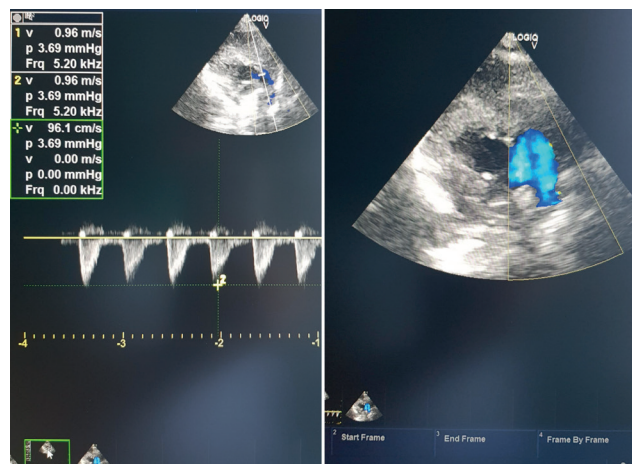


Figure 4. Closed ductus after i.v. ibuprofen treatment

uscultatory finding from tenth day of life. First patient had low clinical score and paracetamol turned out to be effective in this presymptomatic phase, while the second patient had higher clinical score and paracetamol had no effect on ductal closure. According to other authors, clinical findings are nonspecific, do not correlate well with echocardiographic findings (7) and have not been shown to reliably predict responses to treatment or sequelae. Any therapeutic modality should be considered in the light of accompanying premature baby morbidity and mortality, the presence of clinical criteria, and echo parameters. Unlike echocardiographic parameters, clinical criteria are well defined. Among the echocardiographic criteria, ductus diameter, ductal shunt, LA-Ao ratio are most often taken into account. The approach varies from watchful waiting, over conservative treatment, medical therapy to surgical closure (8). Drug treatment traditionally involves the use of cyclooxygenase inhibitors (indomethacin, ibuprofen). Their application has been well studied and side effects of treatment are well known. Hammerman et al. reported the first series of successfully treated premature babies with a ductal shunt with acetaminophen (9). Since then, numerous studies have been conducted presenting acetaminophen as a successful alternative to indomethacin and ibuprofen, in the treatment of ductal shunt, with almost the same efficacy and significantly lower incidence of side effects. Use at a dose twice the equianalgesic dose has been shown not to cause significant side effects other than transiently elevated liver enzymes in several isolated cases (10). A study on 87 premature babies treated with low doses of paracetamol proved its effectiveness in ductal closure (11). There are inconsistent views about the dose of acetaminophen that would be therapeutically effective and safe enough for the child, as well as about the length of treatment. A clinical study conducted by Dash et al. compared the efficacy in ductal closure of oral paracetamol at a dosage of 60 mg per kg body weight per day, divided into 4 doses for 7 days relative to intravenous indomethacin and achieved 100% ductus closure in the group of children treated with paracetamol (12). El Khuffash et al. compared the efficacy of paracetamol in ductal closure as a longer course of treatment (7 days) compared to a shorter course (2 days) and also found significantly better efficacy at longer administration (13). It is believed that the better effect is directly related to the higher plasma concentration of the drug that is achieved by longer administration, and therefore better targeted therapeutic effect. Failure to close with paracetamol has been described in extremely immature children. During a study by Weisz et al., after performing paracetamol therapy on 26 premature babies of extremely low birth weight, 57% of subjects required surgical duct ligation (14). To define the optimal dose of paracetamol, which would be effective and also have a good safety profile, in terms of side effects, additional studies are needed. It is also necessary to define an adequate length of treatment, although the results so far seem to make longer therapy more effective.

6. CONCLUSION

The diagnosis of PDA in the early, asymptomatic phase, in premature babies, is made by early echocardiographic examination. The decision on treatment should be based on clinical and echocardiographic criteria. Paracetamol is an alternative in the treatment of this cardiac problem of premature infants and could be more effective if used in early, presymptomatic phase. A series of bedside echocardiographic examinations should be performed during therapy, in order to avoid prolonged and unnecessary drug exposure.

- **Author's contribution:** All authors were involved in the preparation of this article. Final proofreading was made by the first author.
- **Conflict of interest:** None declared.
- **Financial support and sponsorship:** Nil.

REFERENCES

1. Hoffman JI, Kaplan S. The incidence of congenital heart disease. *J Am Coll Cardiol.* 2002; 39: 1890–9000
2. Park K. Myung. *Park's Pediatric Cardiology for Practitioners.* 6th edition. Elsevier Saunders, 2014
3. Bagheri MM, Niknafs P, Sabsevari F, Torabi MH, Bahman Bijari B, Noroozi E, et al. Comparison of oral acetaminophen versus ibuprofen in premature infants with patent ductus arteriosus. *Iran J Pediatr.* 2016; 26: e3975
4. Dang D, Wang D, Zhang C, Zhou W, Zhou Q, Wu H, et al. Comparison of oral paracetamol versus ibuprofen in premature infants with patent ductus arteriosus: A randomized controlled trial. *PLoS One.* 2013; 8: e77888
5. Pharande P, Watson H, Tan K, Sehgal A. Oral paracetamol for patent ductus arteriosus rescue closure. *Pediatr Cardiol.* 2018; 39: 183–190.
6. Evans N. Preterm patent ductus arteriosus: a continuing conundrum for the neonatologist? *Seminars in fetal & neonatal medicine.* 2015; 20(4): 272–277.
7. Kelton R, Evans N, Smythe J. A blinded comparison of clinical and echocardiographic evaluation of the preterm infant for patent ductus arteriosus. *J Paediatr Child Health.* 1994; 30(5): 406–411
8. Guimaraes AFM, Araujo FDR, Meira ZMA, Tonelli HAE, Duarte GG, Ribeiro EC, et al. Acetaminophen in low doses for closure of the ductus arteriosus of the premature. *Ann Pediatr Cardiol.* 2019 May-Aug; 12(2): 97–102.
9. Dani C, Bertini G, Corsini I, Elia S, Vangi V, Pratesi S, et al. The fate of ductus arteriosus in infants at 23–27 weeks of gestation: from spontaneous closure to ibuprofen resistance. *Acta Paediatr.* 2008; 97: 1176–1180.
10. Hammerman C, Bin-Nun A, Markovitch E, Schimmel MS, Kaplan M, Fink D, et al. Ductal closure with paracetamol: A surprising new approach to patent ductus arteriosus treatment. *Pediatrics.* 2011; 128: e1618–21.
11. Yang B, Gao X, Ren Y, Wang Y, Zhang Q. Oral paracetamol vs. Oral ibuprofen in the treatment of symptomatic patent ductus arteriosus in premature infants: A randomized controlled trial. *Exp Ther Med.* 2016; 12: 2531–2536
12. Dash SK, Kabra NS, Avasthi BS, Sharma SR, Padhi P, Ahmed J, et al. Enteral paracetamol or intravenous indomethacin for closure of patent ductus arteriosus in preterm neonates: A Randomized controlled trial. *Indian Pediatr.* 2015; 52: 573–578.
13. El-Khuffash A, Jain A, Corcoran D, Shah PS, Hooper CW, Brown N, et al. Efficacy of paracetamol on patent ductus arteriosus closure may be dose dependent: Evidence from human and murine studies. *Pediatr Res.* 2014; 76: 238–244.
14. Weisz DE, Martins FF, Nield LE, El-Khuffash A, Jain A, McNamara PJ, et al. Acetaminophen to avoid surgical ligation in extremely low gestational age neonates with persistent hemodynamically significant patent ductus arteriosus. *J Perinatol.* 2016; 36: 649–653.