



Case Study

Cite this article as: *Libyan J Med AOP:060806 published (18 September 2006)*

A 22-year-old woman with recurrent gastrointestinal bleeding since childhood

Naila Arebi MD, PhD, MRCP and Chris Fraser MD, MRCP

St Mark's Hospital, Watford Road, Harrow HA1 3UJ, Tel: +44 208 235 4089, Fax: +44 208 235 4093, e-mail: naila.arebi@imperial.ac.uk

CASE PRESENTATION

page
96

A 22-year-old woman was referred to our unit for capsule endoscopy because of recurrent iron deficiency anaemia and gastrointestinal bleeding since childhood.

Cutaneous vascular lesions had been surgically removed when she was a child. During the preceding year she required blood transfusions every month and had a total of 9 iron infusions.

Gastroscopy and colono-scopy at another hospital had shown small vascular lesions in the stomach, duodenum and colon.

Clinical examination revealed pallor. Blood investigations showed a haemoglobin level of 9.6 g/dl and a MCV of 67 fl. The capsule endoscopy (PillCam, Given Imaging) was performed.

Fifteen lesions similar to those shown in figures 1 and 2 were noted through-out the small bowel. She underwent a laparotomy with intra-operative entero-scopy; the lesions were removed and the histology is shown in figure 3.

What is the diagnosis?

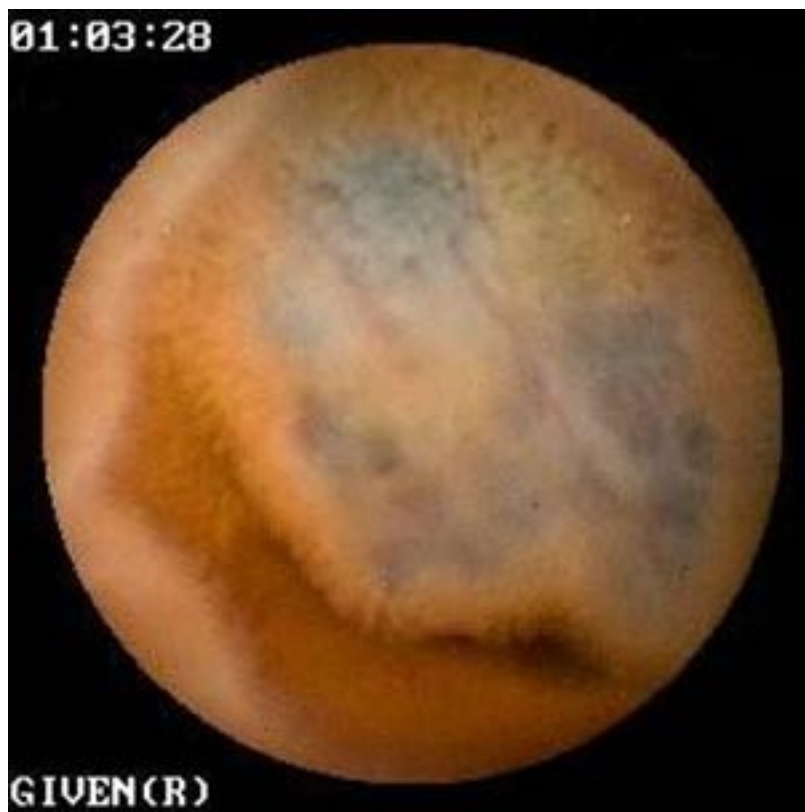

Figure 1

The image obtained from capsule endoscopy shows one of the multiple vascular malformations (figure 1) with evidence of bleeding from one of them (figure 2). Histology (figure 3) revealed the small bowel lesions to be cavernous haemangiomas characteristic of blue rubber bleb naevus syndrome. Thirteen haemangiomas were subsequently confirmed at laparotomy (figure 4) and by intra-operative enteroscopy (figure 5).

page
97

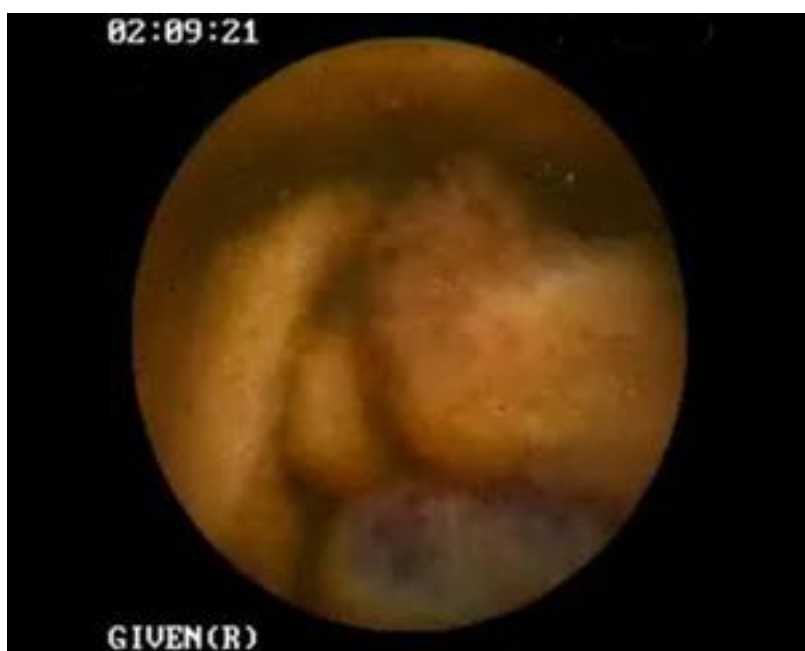


Figure 2

The larger lesions were removed by snare polypectomy using a blended current and the smaller lesions destroyed by argon plasma coagulation. There were no postoperative complications and no recurrence of her anaemia since the procedure. The haemoglobin level 2 months later was 12.6g/dl.

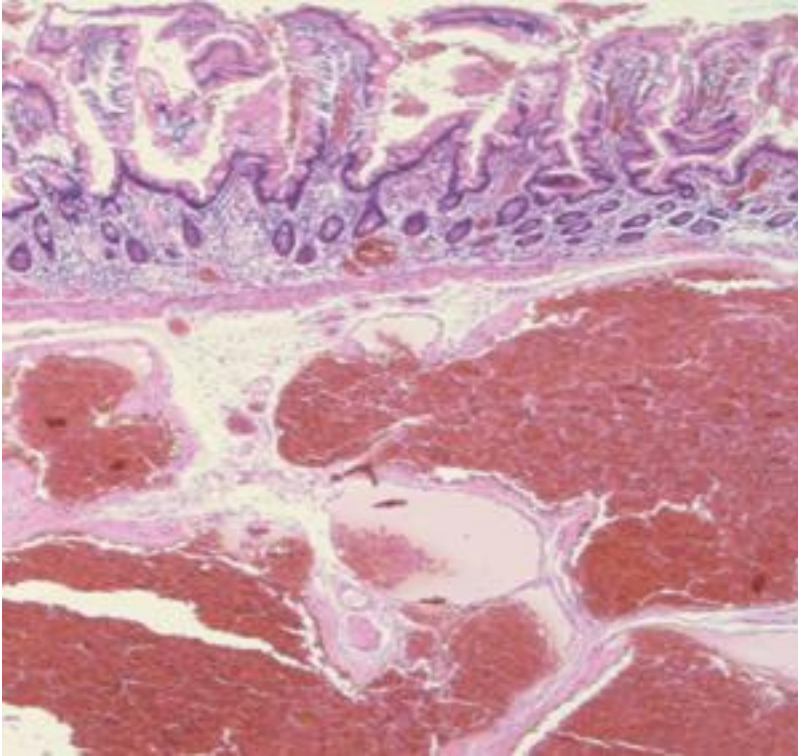


Figure 3

The diagnosis is:
Blue rubber bleb naevus syndrome with visible bleeding haemangiomas on capsule endoscopy.

Blue rubber bleb naevus syndrome, is a rare vascular syndrome characterised by cutaneous haemangiomas and vascular tumours of the gastro-intestinal tract. The gastrointestinal lesions may manifest as occult blood loss with iron deficiency anaemia or overt bleeding or rarely as intussusception. Involvement of other viscera can occur and presentations with haemothorax, haemopericardium, dementia, acute paraparesis and chronic consumption coagulopathy have been described 1.

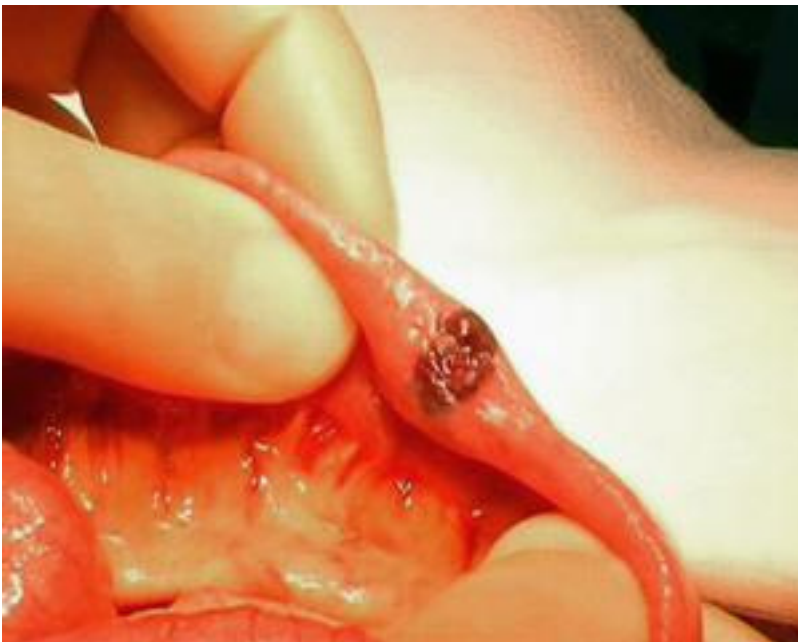

Figure 4

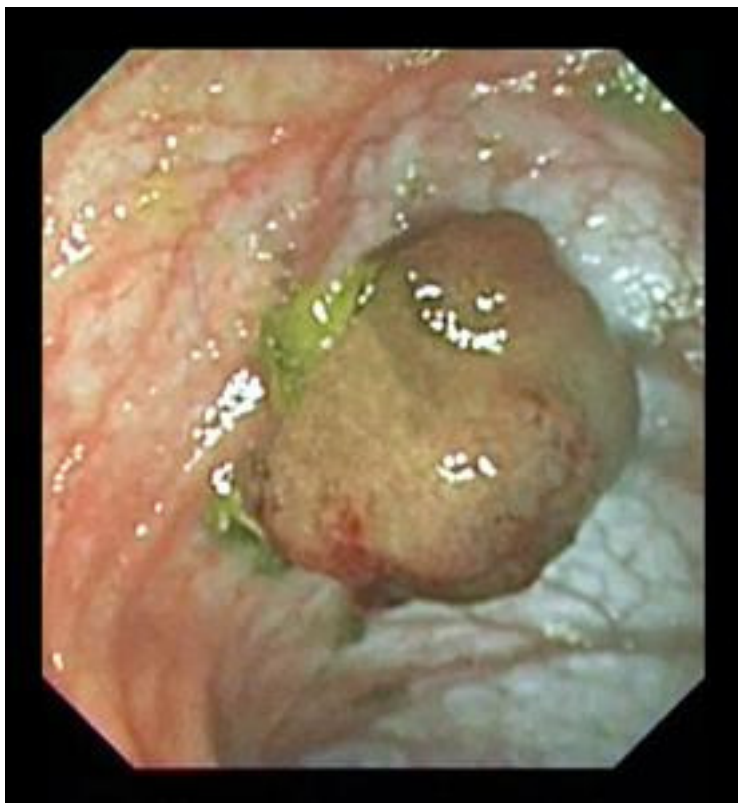

Figure 5

A number of treatment modalities have been shown to be useful in removing the lesions. These include surgical resection, electrocautery, laser photocoagulation, argon plasma coagulation, band ligation and sclerotherapy with

alcohol or ethanol-amine. The effective removal of the haemangiomas by polypectomy using a blended current has previously been reported and is safe as these lesions are not transmural in nature 2, 3.

REFERENCES

1. Wong CH, Tan YM, Chow WC, Tan PH, Wong WK. Blue rubber bleb nevus syndrome: a clinical spectrum with correlation between cutaneous and gastrointestinal manifestations. *J Gastroenterol Hepatol* 2003; 18:1000–1002.
2. Bak YT, Oh CH, Kim JH, Lee CH. Blue rubber bleb nevus syndrome: endoscopic removal of the gastrointestinal hemangiomas. *Gastrointest Endosc* 1997; 45:90–92.
3. Shimada S, Namikawa K, Maeda K, Obata S, Ikei S, Mizutani J, Ogawa M. Endoscopic polypectomy under laparotomy throughout the alimentary tract for a patient with blue rubber bleb nevus syndrome. *Gastrointest Endosc* 1997; 45:423–427.