

# Flexible bronchoscopic argon plasma coagulation for management of massive hemoptysis in bronchial Dieulafoy's disease

**Karan Madan, Ashesh Dhungana, Vijay Hadda, Anant Mohan, Randeep Guleria**

Department of Pulmonary Medicine and Sleep Disorders, All India Institute of Medical Sciences, New Delhi, India

## ABSTRACT

Dieulafoy's disease is an uncommon condition, the usual site of occurrence being the gastrointestinal tract. The condition refers to the presence of a dysplastic submucosal artery with mucosal vascular branches that has propensity to cause recurrent bleeding. Dieulafoy's disease of the bronchus is rare. Herein, we describe the case of a 26-year-old male who presented with recurrent bouts of hemoptysis and bronchial Dieulafoy's disease was diagnosed. Flexible bronchoscopy was performed, and argon plasma coagulation (APC) of the bleeding lesion was done. The procedure was successful and was followed by complete eradication of the vascular malformation and cessation of hemoptysis. APC is a useful tool in the armamentarium of an interventional pulmonologist that can allow rapid and safe control of bleeding from superficially located and bleeding endobronchial lesions, and can be easily and effectively applied using a flexible bronchoscope.

**KEY WORDS:** Argon plasma coagulation, bronchoscopy, Dieulafoy's disease, hemoptysis

**Address for correspondence:** Dr. Karan Madan, Department of Pulmonary Medicine and Sleep Disorders, All India Institute of Medical Sciences, Ansari Nagar, New Delhi - 110 029, India. E-mail: drkaranmadan@gmail.com

## INTRODUCTION

Hemoptysis is a common respiratory symptom and usually originates from the lung parenchyma or the airways. Less than 5% of hemoptysis is massive and warrants urgent investigations and treatment. Dieulafoy's disease is an eponymous disease (referring to a disease/condition named after a person) that was initially described by a French surgeon, Georges Dieulafoy in 1898.<sup>[1]</sup> He described the condition as a vascular malformation characterized by a dysplastic artery in the gastric mucosal epithelium of young asymptomatic men presenting with life-threatening hematemesis. The condition has also been reported in the esophagus, duodenum, jejunum, gall bladder, colon, and rectum.<sup>[2]</sup> The respiratory tract is an extremely rare site of involvement, and only a few case reports describe bronchial Dieulafoy's disease.<sup>[3]</sup> The presentation is usually in adulthood

with one or more episodes of hemoptysis, which may be massive. Conventional management options that have been described for bronchial Dieulafoy's disease include surgical resection and selective arteriographic embolization.<sup>[4,5]</sup> On searching the literature, only one previous report described therapeutic bronchoscopic management for this condition.<sup>[6]</sup>

## CASE REPORT

A 26-year-old, never smoker male presented to the pulmonary outpatient clinic with a history of hemoptysis since 5 days. There was a history of recurrent episodes of hemoptysis over the past 4 years. In the preceding year, the patient had experienced four episodes of massive hemoptysis with expectoration of approximately

This is an open access article distributed under the terms of the Creative Commons Attribution-NonCommercial-ShareAlike 3.0 License, which allows others to remix, tweak, and build upon the work non-commercially, as long as the author is credited and the new creations are licensed under the identical terms.

**For reprints contact:** reprints@medknow.com

**How to cite this article:** Madan K, Dhungana A, Hadda V, Mohan A, Guleria R. Flexible bronchoscopic argon plasma coagulation for management of massive hemoptysis in bronchial Dieulafoy's disease. Lung India 2017;34:99-101.

Access this article online	
<b>Quick Response Code:</b> 	<b>Website:</b> www.lungindia.com
	<b>DOI:</b> 10.4103/0970-2113.197096

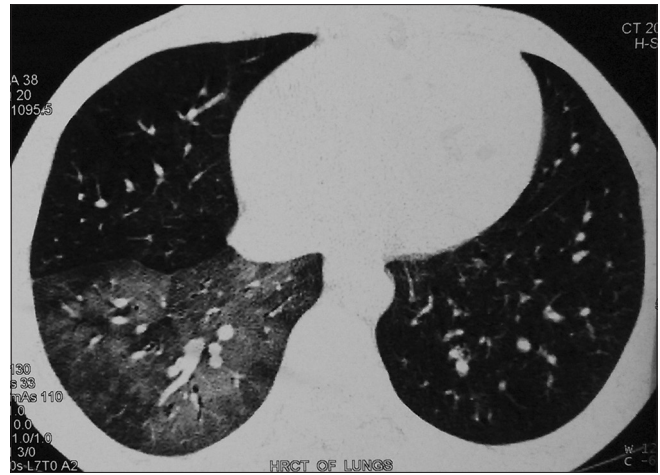200–250 ml of bright red blood. There was no history of dyspnea, chronic cough, wheeze, fever, weight loss, or loss of appetite. There was no history suggestive of connective tissue disease, bleeding diathesis, anticoagulant intake, and close contact with a patient with tuberculosis. The patient was a metal welder by occupation. The patient had received empiric antitubercular therapy (ATT) for 6 months, 1 year, previously. However, sputum smear examination had been negative for acid-fast bacilli on multiple occasions, and hemoptysis persisted despite ATT. No bronchoscopy examination had been performed previously.

On examination, pulse rate was 110/min, blood pressure 124/76 mmHg and respiratory rate 22/min. Oxygen saturation while breathing room air was 97%. General physical examination was unremarkable. On respiratory system examination, few crepitations were audible in the right infrascapular area. Computed tomography scan of the thorax demonstrated ground glass opacity in the right lower lobe with focal bronchiectasis changes [Figure 1].

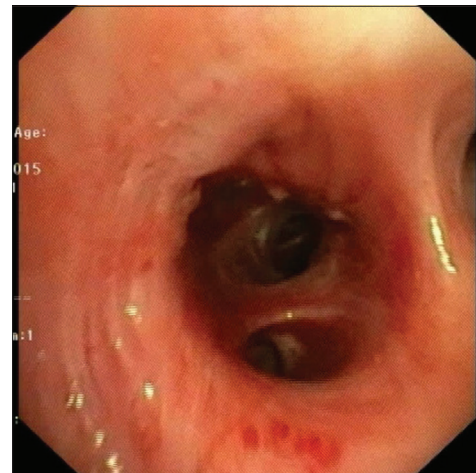
In view of ongoing hemoptysis, an urgent flexible bronchoscopy (FB) examination was planned for localization of the bleeding segment. FB was performed using the Olympus 1T180 flexible video-bronchoscope with 2.8 mm working channel and narrow band imaging (NBI) facility. Extensive blood clots were present in the entire tracheobronchial tree that was cleared with bronchoscopic suction. A focal area of active mucosal blood spurting was visualized in the wall of the right lower lobe bronchus adjacent to the opening of the basal segments. Iced saline lavage was performed, and the bleeding temporarily stopped. At the abnormal site, mucosal irregularity with nodular elevation and mucosal vascular tortuosity was visible [Figure 2]. The abnormal vasculature was highlighted on NBI as a conglomerate tortuous branching pattern [Figure 3]. Flexible bronchoscopic argon plasma coagulation (APC) of the spurting vessel and the entire abnormal mucosal area was performed using the 2.2 mm flexible argon plasma delivery catheter with an APC/electrocautery unit (KLS Martin) [Figure 4]. There was an immediate cessation of hemoptysis following the procedure. The patient was observed as an inpatient for 24 h and there was no recurrence of hemoptysis. Follow-up FB, performed a week later revealed minimal residual mucosal vascularity that was again treated with APC. Follow-up bronchoscopy performed 3 and 6 months following the initial procedure revealed no residual mucosal abnormality [Figure 5] and neither the patient experienced any recurrences of hemoptysis.

## DISCUSSION

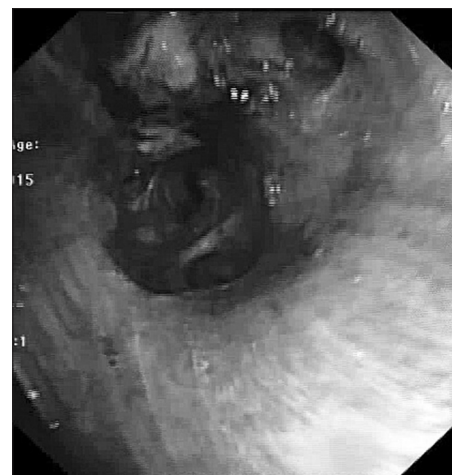Dieulafoy's lesion of the bronchus is a rare cause of hemoptysis but has the propensity to cause massive or submassive episodes of hemoptysis as the bleeding occurs from high-pressure arterial circulation. Hemoptysis is usually the sole presenting manifestation.<sup>[7]</sup> Diagnosis



**Figure 1:** Images of thoracic computed tomography showing ground-glass opacity and focal bronchiectasis in right lower lobe

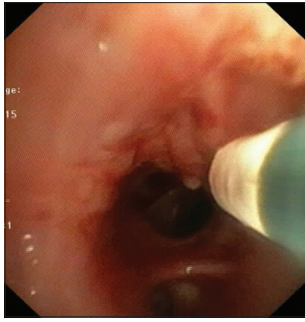


**Figure 2:** Image of the Dieulafoy's lesion – an area of mucosal irregularity with nodular elevation and mucosal vascular tortuosity in the right lower lobe bronchus



**Figure 3:** Narrow band imaging of the lesion highlighting the vascularity of the abnormal mucosal area

of Dieulafoy's lesion is difficult as there is a high likelihood of the lesion being missed on bronchoscopy

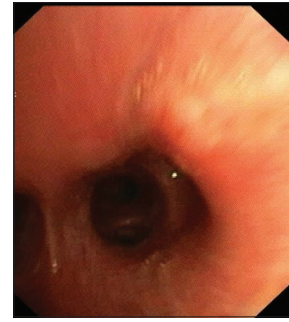


**Figure 4:** Image demonstrating the flexible argon plasma coagulation probe guided treatment of the lesion

by an inexperienced operator. The lesion is submucosal, usually subcentimeter in size and may be pulsating or nonpulsatile. Biopsy from an abnormal endobronchial lesion should be avoided if Dieulafoy's disease is a possibility as the same may lead to fatal hemorrhage.<sup>[8,9]</sup> Van der Werf *et al.* reported a patient with bronchial Dieulafoy's disease, who developed massive bleeding postbiopsy and required mechanical ventilation. The patient finally succumbed to asphyxia due to re-bleeding from the lesion.<sup>[6]</sup> Endobronchial ultrasound with Doppler has been used to confirm the vascular nature of the lesion, but utility may be limited by the size and location of the lesion.

There is no consensus on treatment of bronchial Dieulafoy's lesion in view of its rarity. Selective embolization of abnormal vascular plexus may be performed, and this may avoid surgery in some patients. Bronchoscopic and angiographic follow-up is required even after successful arterial embolization. Failure of embolization may be due to improper localization, vessel arising from pulmonary circulation and neovascularization. Failure of endovascular procedure should prompt surgical management after successful localization of the site of bleeding by bronchoscopy.

On performing a systematic search of the literature, we could identify only one previous report describing definitive bronchoscopic management of bronchial Dieulafoy's disease. Similar to our patient, APC was utilized. However, the procedure was performed under rigid bronchoscopy in contrast to the flexible bronchoscopic application as we herein describe.<sup>[6]</sup> APC is an electrosurgical noncontact thermal ablation technique which assists in endobronchial tumor debulking, achieving hemostasis from bleeding endobronchial lesions, removing granulation tissue and as a definitive modality of treating other benign airway disorders. It has been used successfully with both flexible and rigid bronchoscope. The advantages of APC are rapid, effective coagulation, lower risk of perforation or cartilage damage, better control of depth, and short operating time. The particular advantages of APC are that the argon gas flows around the bends and as the tissue gets coagulated and its resistance increases, flow of argon is automatically directed to the untreated tissue. This makes APC the ideal



**Figure 5:** Follow-up bronchoscopy image demonstrating complete eradication of the abnormal mucosal lesion

modality for electro-coagulation of bronchial lesions located at acutely angled airway branches which is of particular advantage as compared to laser which treats in a linear manner.<sup>[10]</sup>

The above case highlights the importance of bronchoscopy in delineating a cause for massive hemoptysis. If there is a suspicion of a Dieulafoy's lesion, biopsy should not be attempted. Endobronchial electrocautery using APC may be used to acutely control hemorrhage, if a vascular anomaly is detected, which may at times be therapeutic as in our case. Angio-embolization of the arterial plexus in Dieulafoy's disease is an option, but recurrences are known to occur. Those patients with recurrence or failed bronchoscopic procedure/embolization may be offered surgical excision.

#### Financial support and sponsorship

Nil.

#### Conflicts of interest

There are no conflicts of interest.

#### REFERENCES

1. Amaro R, Petruff CA, Rogers AI. Rectal Dieulafoy's lesion: Report of a case and review of the literature. *Dis Colon Rectum* 1999;42:1339-41.
2. Sweerts M, Nicholson AG, Goldstraw P, Corrin B. Dieulafoy's disease of the bronchus. *Thorax* 1995;50:697-8.
3. Ganganah O, Guo S, Chiniah M, Sah SK, Wu J. Endobronchial ultrasound and bronchial artery embolization for Dieulafoy's disease of the bronchus in a teenager: A case report. *Respir Med Case Rep* 2015;16:20-3.
4. Barisione EE, Ferretti GG, Ravera SS, Salio MM. Dieulafoy's disease of the bronchus: A possible mistake. *Multidiscip Respir Med* 2012;7:40.
5. Bhatia P, Hendy MS, Li-Kam-Wa E, Bowyer PK. Recurrent embolotherapy in Dieulafoy's disease of the bronchus. *Can Respir J* 2003;10:331-3.
6. Dalar L, Sökücü SN, Özdemir C, Büyükkale S, Altın S. Endobronchial argon plasma coagulation for treatment of Dieulafoy disease. *Respir Care* 2015;60:e11-3.
7. Sakr L, Dutau H. Massive hemoptysis: An update on the role of bronchoscopy in diagnosis and management. *Respiration* 2010;80:38-58.
8. van der Werf TS, Timmer A, Zijlstra JG. Fatal haemorrhage from Dieulafoy's disease of the bronchus. *Thorax* 1999;54:184-5.
9. Löschnhorn C, Nierhoff N, Mayer R, Zaunbauer W, Neuweiler J, Knoblauch A. Dieulafoy's disease of the lung: A potential disaster for the bronchoscopist. *Respiration* 2006;73:562-5.
10. Bolliger CT, Sutedja TG, Strausz J, Freitag L. Therapeutic bronchoscopy with immediate effect: Laser, electrocautery, argon plasma coagulation and stents. *Eur Respir J* 2006;27:1258-71.