

Comparison of the accuracy of cannulated pedicle screw versus conventional pedicle screw in the treatment of adolescent idiopathic scoliosis

A randomized retrospective study

Sinan Yilar, MD*

Abstract

Background: Pedicle screws are commonly used to treat adolescent idiopathic scoliosis (AIS). Many studies have discussed the rates and effects of pedicle screw misplacement. In this study, to increase the accuracy rate, cannulated pedicle screws were inserted into the periapical vertebrae, highly rotated vertebrae, and vertebrae with very thin pedicles in a single patient group. We compared these results with those of a patient group who underwent conventional pedicle screw placement.

Methods: Twenty-eight AIS patients treated surgically between 2015 and 2017 with cannulated pedicle screws or conventional pedicle screws were included. Group 1 (n = 15) received cannulated pedicle screws, whereas group 2 (n = 13) received conventional pedicle screws. Postoperative computed tomography scans were used to evaluate pedicle screw position. Pedicle perforation was assessed using the classification by Rao et al: grade 0, no perforation; grade 1, only the threads outside the pedicle (less than 2 mm); grade 2, core screw diameter outside the pedicle (2–4 mm); and grade 3, screw entirely outside the pedicle. Medial screw malposition was measured between the medial pedicle wall and the medial margin of the screw. Lateral screw malposition was measured between the lateral corpus wall and lateral screw margin.

Results: Placement accuracy of 703 screws (group 1, 376; group 2, 327) was evaluated. A total of 142 (20.1%) pedicle screw perforations occurred: 63 (17.1%) in group 1 and 79 (25%) in group 2 ($P < .05$). There was no statistically significant intergroup difference in medial perforation (group 1, 34 [9%] vs group 2, 31 [10%]). Lateral perforation was significantly less common in group 1 (n = 29; 7.7%) than in group 2 (n = 4; 14.7%) ($P = .0002$).

Conclusions: The use of cannulated screws to treat AIS decreases perforation and complication rates. Although it did not significantly lower the medial perforation rate, it dramatically reduced the lateral perforation rate. The use of cannulated screws enables intraoperative confirmation of placement accuracy. Our data suggest that cannulated pedicle screw use to treat AIS is safer and more efficient.

Abbreviations: AIS = adolescent idiopathic scoliosis, AP = anteroposterior, CT = computed tomography, NMEP = neurogenic motor evoked potentials, SSEP = somatosensory evoked potentials, T2 = thoracic vertebrae 2, XR = X-ray.

Keywords: accuracy, adolescent idiopathic scoliosis, cannulated pedicle screws, CT scan

1. Introduction

Adolescent idiopathic scoliosis (AIS) is both the most common type of scoliosis and the most common pediatric deformity.^[1] Although its incidence varies among ethnic cultures and regions, the prevalence

of scoliosis varies between 0.013% and 13.6%.^[2] The frequency of scoliosis in Turkey varies between 0.2% and 1%.^[3]

Pedicle screws are widely used in deformity correction surgeries. Pedicle screw constructs were shown to achieve better correction than other techniques.^[4–6] However, pedicle screw placement can be a technically demanding procedure with the potential for significant neurologic, vascular, and visceral injuries within the thoracolumbar region.^[7–10]

In severe deformities, the pedicles are frequently thinner and sclerosed, enabling canal perforation. The medulla spinalis is also often stretched over the pedicles on the concave side of the curve, and even minor violations can damage the spinal cord.^[7,8,11–13] Intraoperative ISO-C 3-dimensional navigation and computed tomography (CT) navigation have been demonstrated to decrease perforation rates.^[4,13,14] However, these systems increase the cost and duration of surgery, and are unavailable in most medical centers.

A large number of studies reported different pedicle screw misplacement rates. In their review, Kwan et al indicated that “reported pedicle screws perforation rates for corrective AIS surgery vary widely from 1.2% to 65.0%.”^[6]

Editor: Yan Li.

The author(s) of this work have nothing to disclose.

Atatürk University, Department of Medicine, Erzurum, Turkey.

* Correspondence: Sinan Yilar, Atatürk University, Department of Medicine, Atatürk Üniversitesi Tıp Fakültesi Ortopedi ve Travmatoloji Anabilim Dalı, 25240 Erzurum, Turkey (e-mail: sinan_yilar@hotmail.com)

Copyright © 2019 the Author(s). Published by Wolters Kluwer Health, Inc. This is an open access article distributed under the terms of the Creative Commons Attribution-Non Commercial License 4.0 (CCBY-NC), where it is permissible to download, share, remix, transform, and buildup the work provided it is properly cited. The work cannot be used commercially without permission from the journal.

Medicine (2019) 98:10(e14811)

Received: 29 May 2018 / Received in final form: 26 January 2019 / Accepted: 12 February 2019

<http://dx.doi.org/10.1097/MD.0000000000014811>

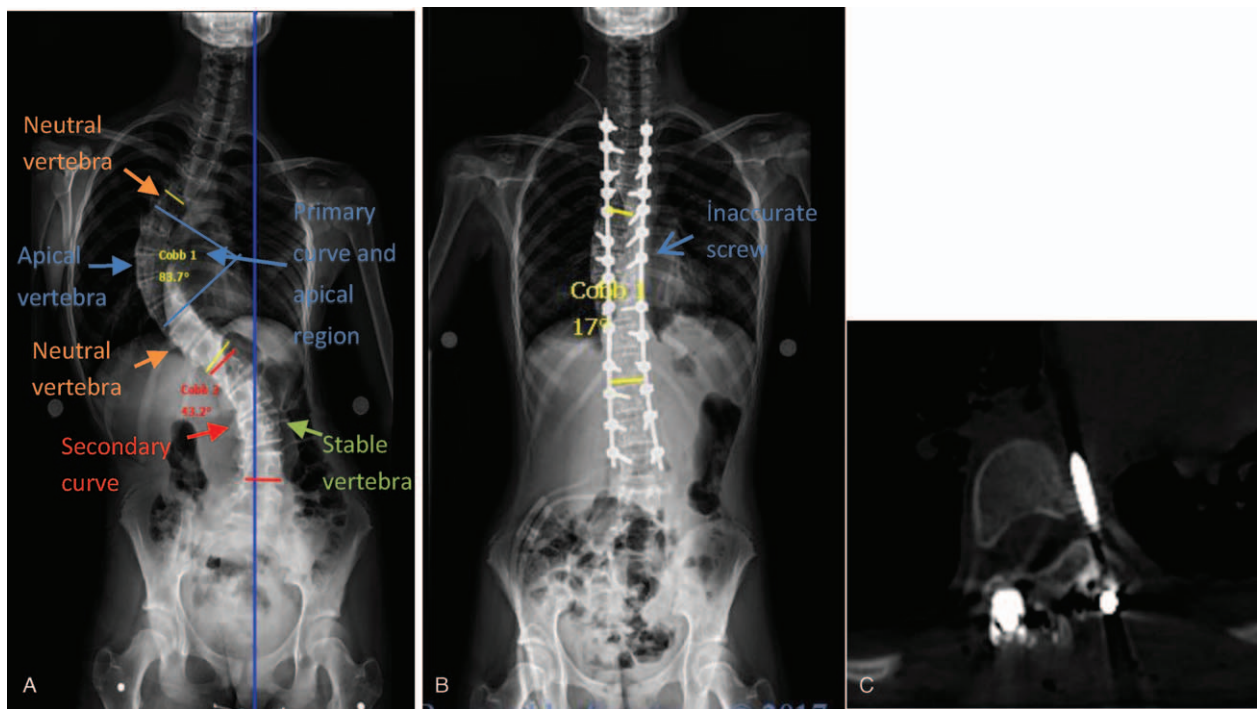


Figure 1. (A) A 13-year-old girl with idiopathic scoliosis Lenke type 1. (B) The postoperative Cobb angle is 17°. (C) The postoperative CT shows that T8 screw was abutting the aorta and this screw was removed with a second operation. CT=computed tomography.

In AIS, the apical region is the most rigid and difficult part into which a screw may be inserted, because apical vertebrae are the narrowest and most rotated. Despite a lack of evidence thereof, to our knowledge, the perforation rate is likely the highest in this region. In this region, at the concave side, in particular, the pedicles are so thin that transpedicular screw fixation is impossible.^[13,15–18] For this reason, the in-out-in technique should be used. After creating a pilot hole in the vertebra using a probe, it is possible to enter from the corpus vertebrae; however, it is extremely difficult to perform this operation with a screw on the highly rotated vertebrae because the screw usually remains in the lateral position and does not reach the corpus. However, when a cannulated system is used, the guide wire prevents screw migration during insertion.

The objective of this study was to compare the accuracy of conventional and cannulated pedicle screws in the treatment of AIS. During the study design phase, the CT scans of our patients who underwent scoliosis surgery in 2015 using conventional pedicle screws were reviewed; we found that 25% of the screws were misplaced. The author who performed the surgeries also assessed that the use of conventional pedicle screws was the main contributor to the high malposition rate. To increase placement accuracy and decrease the associated complications, since 2016, cannulated pedicle screws have been placed in apical region vertebrae because most deviate laterally from the vertical axis that passes from the central sacral line (Fig. 1A). It should be underlined that cannulated pedicle screws were only used in apical region vertebrae using the in-out-in technique (Fig. 2B). The misplaced pedicles were detected on postoperative CT, and the results of this group were compared with those of control group surgeries performed before 2016 using conventional pedicle screws (Fig. 2A).

2. Materials and methods

2.1. Data deposition standards

This retrospective clinical study was performed at the Ataturk University Department of Medicine in Turkey in compliance with the Patient Rights Decree of Turkey according to the standards in this field for data availability. All data and related metadata underlying the findings are reported in this manuscript and have been deposited in our state-owned and state-operated clinic. All data and metadata can be provided to interested reviewers upon request after local and international procedures are completed.

In Turkey, the National Code of Clinical Research published on April 13, 2013 describes how local ethical committees work, what their responsibilities and competencies are, study types, and main requirements for research planning based on international rules. Retrospective studies are excluded from ethics committee consultation. The author considered the ethical, legal, and regulatory norms and standards in preparation of this study in

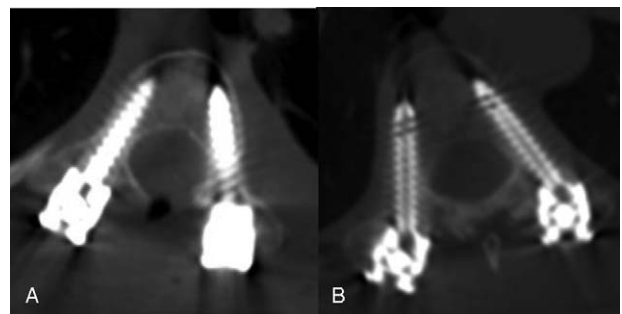


Figure 2. (A) Conventional pedicle screw; (B) cannulated pedicle screw.

Table 1**The comparison of cannulated pedicle screws group (group 1) and conventional pedicle screws group (group 2).**

	Total	Group 1	Group 2	P
Total	28	15	13	
Screws	703	376	327	.54
Age	18.2	18.8	17.6	.41
Preop. Cobb angle	68.8	66.2	70.3	.38
Postop. Cobb angle	21.8	22.4	21.2	.54
Preop. kyphos angle	44.8 (2-82)	45 (2-80)	44.6 (24-82)	.78
Postop. kyphos angle	33.8	34.0	33.6	.71

compliance with the Declaration of Helsinki. All analyzed data were collected as part of routine diagnosis and treatment. Patients were diagnosed and treated according to national guidelines and agreements. Each patient or his/her legal custodian provided informed consent for the collection, analysis, storage, publication, and re-use for human material. The study was submitted to the medical director for consideration, comment, guidance, and publication approval. Atatürk University, Department of Medicine Clinical Studies Ethics Board approved the conduction of the study with the meeting number 08 and decision number 11 dated on December 27, 2018, as the study adheres to scientific and ethical standards.

2.2. Patient classification

In all, 83 patients underwent scoliosis surgery between 2015 and 2017 by the same experienced spine surgeon. Nineteen cases (11 congenital, 5 early-onset scoliosis, and 3 revision) were excluded from the study. Patients with Lenke type 5 (6 patients) or type 6 (2 patients) curves were excluded. Another 4 AIS patients who underwent apical corpectomy were also excluded. Among the remaining 52 patients, 9 patients who could not undergo a postoperative CT scan for any reason, 10 patients with a follow-up period of less than 12 months, and 5 with poor visualization of screw location or position at the CT scan were excluded.

This study ultimately included 28 AIS patients treated surgically between 2015 and 2017 with cannulated or conventional pedicle screws (Table 1). Patients in group 1 (n=15) underwent cannulated pedicle screw placement, whereas those in group 2 (n=13) underwent conventional pedicle screw placement. Of them, 13 had type 1, 6 had type 2, 7 had type 3, and 2 had type 4 Lenke classification.^[19] In the upper part, the instrumentation was at the thoracic vertebrae 2 (T2) to thoracic vertebrae 4 level and in the lower part stable vertebra that is most closely bisected by a vertically directed central sacral line—the vertical line on a frontal radiograph that passes through the center of the sacrum—was instrumented. A total of 703 screws were used. All screws were inserted by the same surgeon. Between T2 and thoracic vertebrae 11, screws were inserted using the free hand technique without C-arm assistance. Between thoracic vertebrae 12 and lumbar vertebrae 4, the point of skin entry was marked with a marker and checked using the C-arm. Screw positioning was checked using anteroposterior (AP) and lateral views, and the screws were inserted accordingly. Screw positioning was controlled using the C-arm, and any misplaced screws were repositioned.

Intraoperative neurophysiologic neuromonitoring systems are commonly used in deformity surgeries and enable surgeons to understand advancing intraoperative neurologic complications.

Intraoperatively, all cases were monitored with somatosensory evoked potentials (SSEP) and neurogenic motor evoked potential (NMEP) by neuromonitoring experts to improve screw placement accuracy and avoid complications associated with screw misplacement. During the screw insertion phase, when a decrease greater than 50% was observed in SSEP and NMEP potentials, misplaced screws were removed and immediately repositioned or replaced.

2.3. Methodology

In this study, for a short segment curve, the apical region was considered the 2 consecutive vertebrae above and below the apex. For a long segment curve, the apical region was considered the region between 2 neutral vertebrae. The neutral vertebrae of patients were selected as the 2 vertebrae located at the beginning (upper end vertebrae) and end (inflection vertebrae) of the primary curve without axial rotation in reference to the most cephalad vertebra in the cephalad direction from a curve apex whose superior surface is tilted maximally toward the concavity of the curve and the caudal vertebrae in the caudal direction from a curve apex whose inferior surface is tilted maximally toward the concavity of the curve. The end vertebrae are commonly defined as the vertebrae that define the ends of a curve in a frontal or sagittal projection; the cephalad and caudal vertebrae were marked as the end vertebrae. In this study, the primary curvature—the curve with the largest Cobb measurement on an upright long cassette coronal X-ray (XR) of the spine—was considered in patient classification, whereas secondary curvatures—any curve that does not have the largest Cobb measurement on an upright long cassette coronal XR of the spine—were not used in the classification (Fig. 1A).

The AP, lateral, and bending XR; CT scans; and preoperative magnetic resonance images were obtained for all patients. The vertebrae into which the screws were planned to be inserted were evaluated on CT and the necessary measurements were made. Three patients underwent craniocervical decompression for Arnold-Chiari type 2 malformation; to achieve a higher degree of correction, 8 patients underwent apical Ponte osteotomies. As in many spine centers, day 1 postoperative CT was performed for all patients. No additional CT scans were performed unless strongly required. All the patients provided written consent for their surgery data and results to be used in academic studies.

In group 2 (conventional screw), when the screw was inserted after entry point was created, a path was created in the pedicle using a curved or straight pedicle finder. Path accuracy was ensured with a probe and pedicle sound. The bone tap was then engaged on the vertebral body wall at a depth of about 20 mm and the screw was inserted.

In group 1 (cannulated screw), when the screw was inserted, the path accuracy was checked with a probe, which was then removed, and a guide wire was inserted. Because our pedicle screw system did not feature a cannulated bone tap, one could not be used; thus, after the guide wire was inserted into the path, the cannulated pedicle screw was inserted. To avoid visceral organ injury, the guide wire was removed after the screw was placed. Fluoroscopy guidance was not needed since the free hand methodology was used (Fig. 3).

The screws were 4.5, 5.5, or 6.5 mm in diameter. CT scans were taken in the axial, coronal, and sagittal views, and classified in accordance with the study by Rao et al.^[20] Superior, inferior, and anterior perforations were considered lateral perforations. The distance of the screw tip from the anterior, medial, or lateral

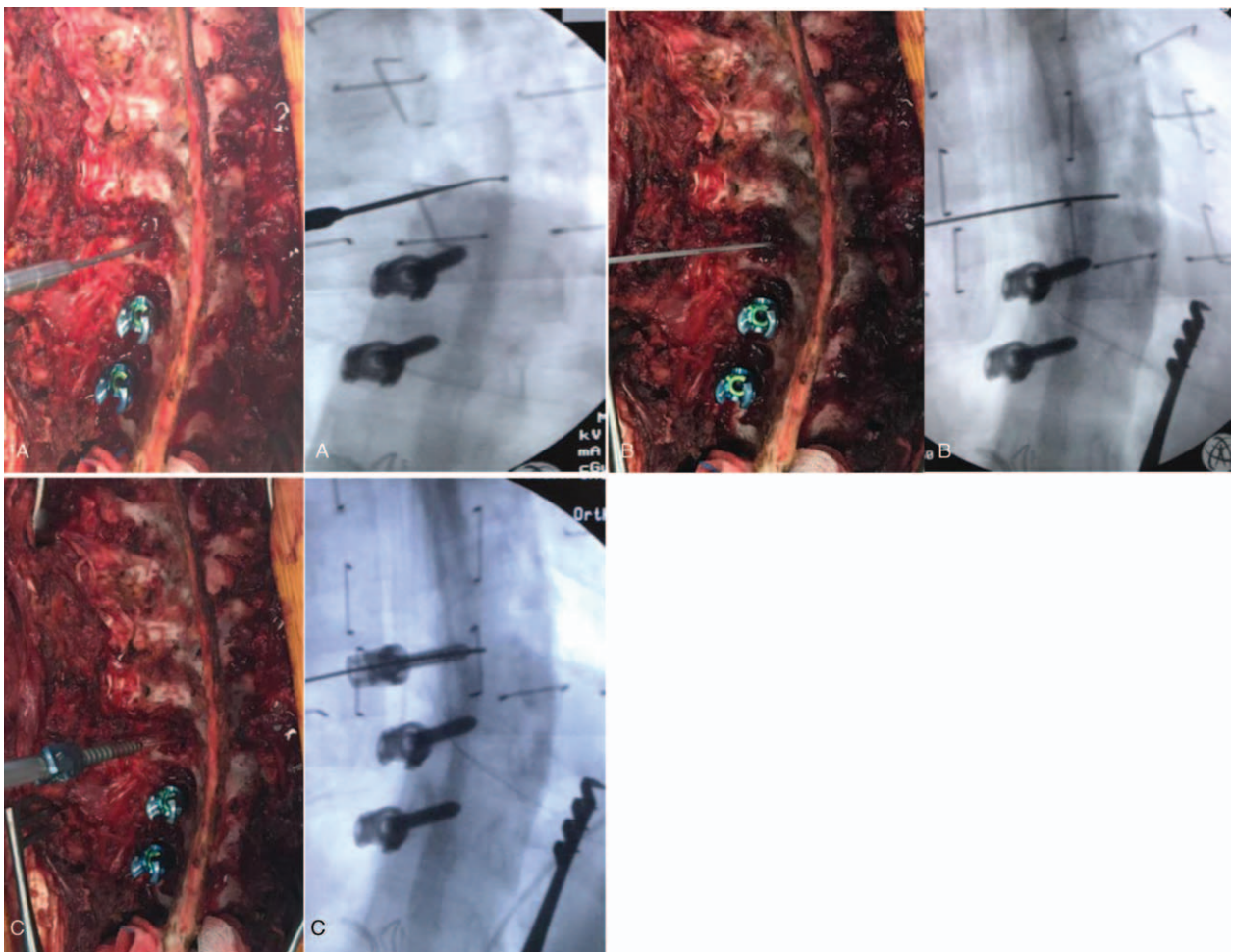


Figure 3. Intraoperative photos and images showing the steps of cannulated pedicle screw placement. Accuracy of the path was ensured with a probe and pedicle sound (A), after checking with pedicular sound for any violation, a guide wire was inserted (B), a cannulated screw was then inserted via the guide wire (C). Note: For illustration we used the technique for the fluoroscopy images, but we did not use fluoroscopy when screw was inserted.

vertebral cortex was also measured on axial CT views. Screw placement was graded on the CT scans as follows: grade 0, no pedicle perforation; grade 1, only the threads outside the pedicle (less than 2 mm); grade 2, core screw diameter outside the pedicle (2–4 mm); and grade 3, screw entirely outside the pedicle (Figs. 4 and 5).^[13,21–23] The mean follow-up period was 16 months, and CT scans were assessed by the surgeon who performed the operations.

2.4. Statistical analyses

The IBM SPSS Statistics for Windows, Version 20.0^[24] was used to analyze the data. The Shapiro-Wilk test was used to test for normal distribution of continuous variables. In the comparison of 2 independent groups, an independent-samples *t* test was used when the normality condition was met, whereas the Mann-Whitney *U* test was used to examine non-normally distributed data. Values of $P < .05$ were considered statistically significant.

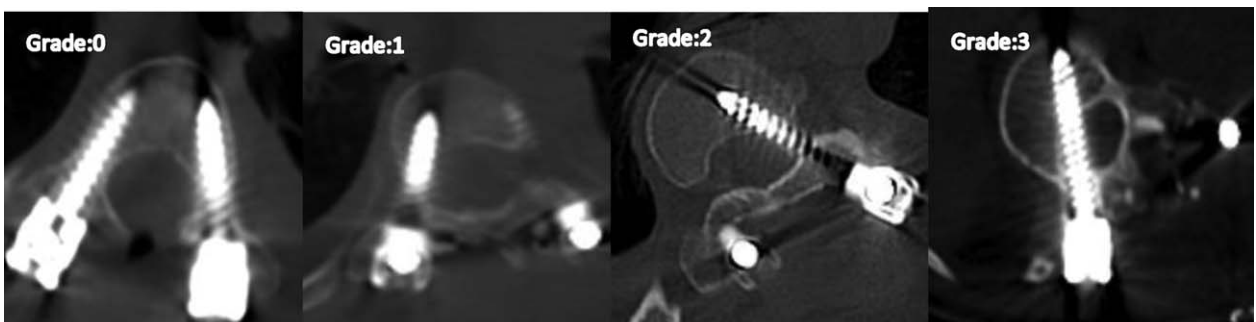


Figure 4. Grading of Rao et al^[20] for the medial perforations.

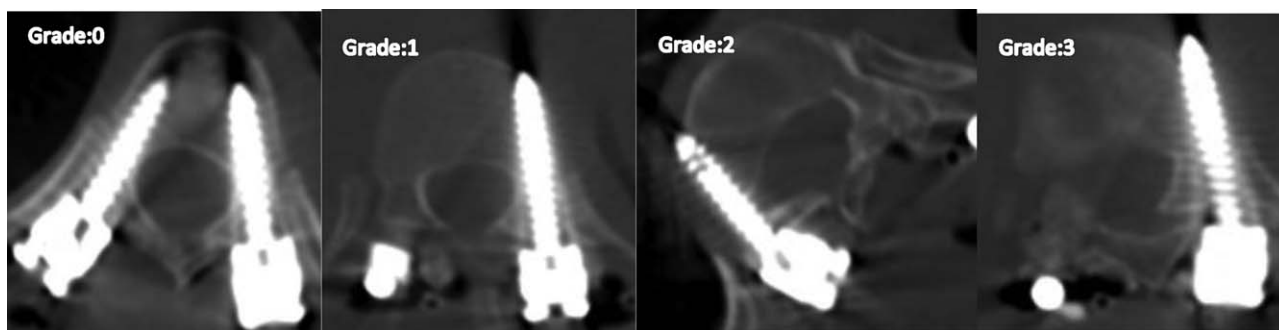


Figure 5. Grading of Rao et al^[20] for the lateral perforations.

3. Results

We examined 28 AIS patients with 703 pedicle screws (Table 2) between 2015 and 2017. The mean follow-up period was 16 months.

The cannulated pedicle screw group (group 1) included 15 patients, whereas the conventional pedicle screw group (group 2) included 13 patients. The mean age of the entire sample was 18.2 (range 2–43) years. The mean age of the cannulated screw group was 18.8 years, whereas that of the conventional pedicle screw group was 17.6 years. The average scoliosis angle of curvature was 68.8 (range 47–112) degrees for the entire sample, that for group 1 was 66.2 (range 48–112) degrees, and that for group 2 was 70.3 (range 47–105) degrees. The average degree of kyphosis was 44.8 (range 2–82) for the entire sample, that for group 1 was 45 (range 2–80) degrees, and that for group 2 was 44.6 (range 24–82) degrees.

A total of 142 (20.1%) perforations occurred: 63 (17.1%) in group 1 versus 79 (25%) in group 2 ($P=.034$). There was no statistically significant intergroup difference in medial perforations (group 1, 34 [9%]; group 2, 31 [10%]). In terms of lateral perforation, group 1 ($n=29$; 7.7%) was significantly better than group 2 ($n=49$; 14.7%) ($P=.0002$). With regard to grade 1, 2, and 3 perforation rates, only the grade 2 perforation rate was better in group 1 than in group 2 (Table 2).

Because the apex of the primary curvature was considered the apical region, the apex of the compensatory curvatures was not considered the apical region (Fig. 1A). Hence, only the perforation rates in the primary curvature were benchmarked. The perforation rate in the primary curvature was better for group 1 ($n=24$; 17.9%) than for group 2 ($n=35$; 30.4%) ($P=.02$).

We examined the complications related to misplaced pedicle screws (Fig. 6) for a mean 16 months. There were no complications related to medial perforation. In group 2, due to an inferior perforation at the T6 level, 1 patient reported numbness at the axillary region in a 10 × 10 cm area that continued after 18 months of follow-up. In group 2, of 4 pedicle screws led to aortic irritation, 2 were removed with a second operation (Fig. 1). In group 1, intervention for an anterior perforation causing aortic irritation was not considered necessary. Intervention was not provided for 2 pedicle screws in both groups carrying a risk of pleural irritation due to lack of clinical symptoms.

4. Discussion

Since Suk et al^[7] first used pedicle screws to treat thoracic idiopathic scoliosis in 1994, bilateral pedicle screw instrumentation has become increasingly popular.^[25,26] Compared with hook and wire fixation, this approach features stronger biomechanical anchoring, thus achieving rigid vertebral stabilization that allows better manipulation and scoliosis correction.^[25–27] Due to the 3-dimensional complex anatomy and close proximity to neurological, vascular, and visceral organs of the vertebrae, screw insertion is difficult and risky. It is even more difficult when the vertebrae are deformed as in cases of AIS.

Numerous studies have examined the safety and efficacy of pedicle screws placed in the deformed spine.^[7,11,18,28–37] To improve thoracic pedicle screw placement accuracy, various techniques have been proposed, such as fluoroscopic and CT guidance surgery, intraoperative electromyography, and SSEP and NMEP monitoring.^[23,34,38,39] Imaging-guided techniques are expensive and time-consuming, and carry the inherent risk of

Table 2
The comparison of screw misplacement of cannulated pedicle screws (group 1) and conventional pedicle screws (group 2).

	Total	Group 1	Group 2	P
Screws	703	376	327	.54
Normally	561 (79.8%)	313	248	
Misplaced	142 (20.1%)	63 (17.1%)	79 (25.0%)	.034
Medial misplaced	65 (9.2%)	31 (9%)	34 (10%)	.65
Lateral misplaced	78 (11.1%)	29 (7.7%)	49 (14.7%)	.0002
Apical screws	249	134	115	
Apical misplaced	59 (23.6%)	24 (17.9%)	35 (30.4%)	.022
Grade 1	64 (9.1%)	33 (8.7%)	31 (9.4%)	.533
Grade 2	55 (7.8%)	22 (5.8%)	33 (10.9%)	.023
Grade 3	24 (3.4%)	13 (3.4%)	11 (3.3%)	.460

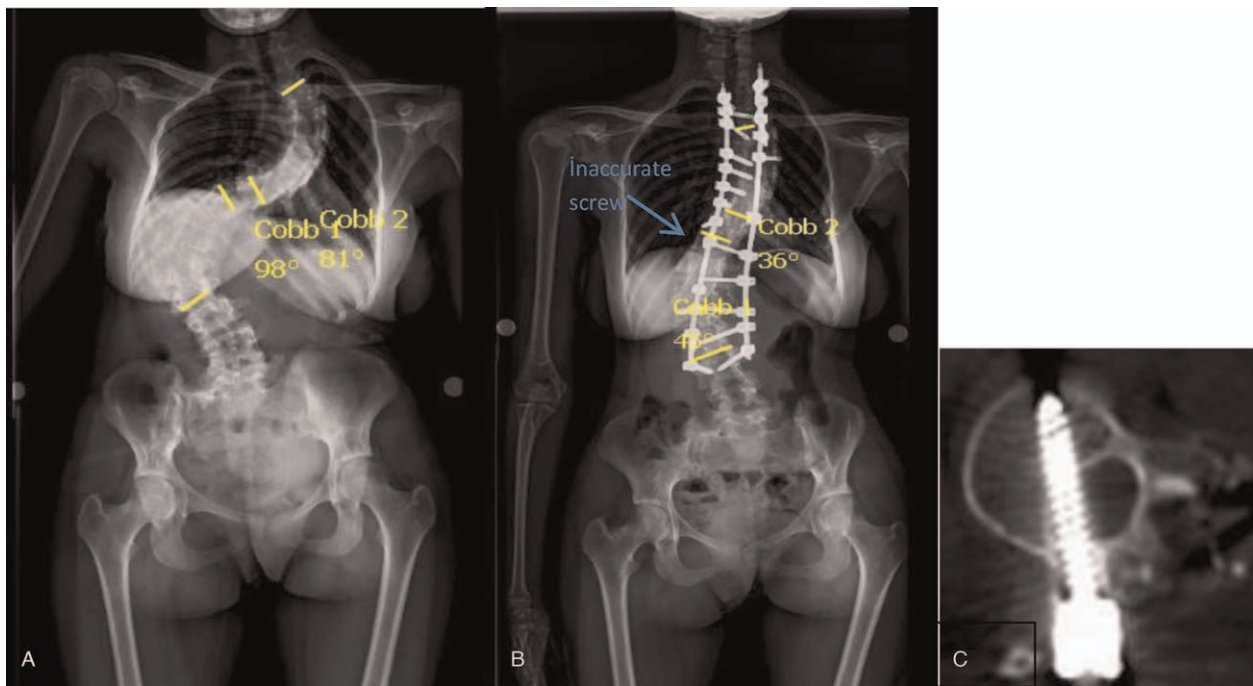


Figure 6. (A) A 15-year-old girl with idiopathic scoliosis Lenke type 3. (B) Postop. Cobb angle was proximal: 36, and distally: 45°. (C) The postoperative CT shows that T12 screw was abutting dura mater. Because the patient was asymptomatic, this screw was not removed. CT=computed tomography, T12=thoracic vertebrae 12.

radiation exposure. In contrast, the free-hand technique is simple, cost-effective, and accurate when used by experienced hands.^[23,34,38,39]

To examine pedicle screw placement accuracy, many studies used XR and CT. However, XRs do not demonstrate actual misplacement rates. Kwan et al reported that pedicle perforation rates in studies using XRs were 1.2% to 3.0%,^[6,29,40–43] whereas pedicle perforation rates of studies using CT were 3.7% to 65%.^[4,6,30,33,34,36,37,44–47] Similarly, Suk et al^[29] indicated a misplacement rate of 1.46% of 4604 pedicle screws by postoperative XRs. When CT scans of patients with misplacements detected by XRs were examined, the perforation rate reached 15%. For this reason, postoperative CT is the gold standard for evaluating pedicle screw misplacement.^[32,37,38,48–50]

Only a few related studies have used postoperative CT. Even fewer studies have analyzed only AIS cases.^[4,6,30,45–47] These studies examined pedicle screw insertion accuracy of only 1 surgeon. Consequently, these studies reflect surgeon dexterity.

Our study, on the contrary, aimed to increase the accuracy rate. When we examined the CT scans of AIS patients who underwent instrumentation, the misplacement rate was around 25%; to decrease this rate, we used cannulated pedicle screws with cement injection. We decided to apply this limited number of screws to the apical vertebrae, highly rotated vertebrae, and vertebrae into which screws are inserted using the in-out-in technique. These represent cases in which the misplacement rate is the highest.

When we reviewed related studies, we found only the recent study of Lee et al^[18] in which the misplacement rate was much lower in the cannulated pedicle screw group than in the conventional pedicle screw group (4.5% vs 15.6%, respectively). However, in the study by Lee et al,^[18] while the classical pedicle screw was positioned using the free-hand technique, the

cannulated pedicle screws were placed under fluoroscopic guidance. We are concerned that this led to extended surgical duration and exposure to additional radiation, possibly impacting the reliability of the comparison results.

On apical vertebrae and a few segments around them, on the concave part, in particular, it is almost impossible to use transpedicular screw fixation; thus, the in-out-in technique should be employed. In the meantime, this technique makes it more difficult to insert screws into the most rotated area—the apical region. After exiting the bone tissue, inserting a blunt screw once again requires a high level of experience. This problem can be overcome with the use of a cannulated pedicle screw. Moreover, after insertion, its placement accuracy should be checked. Considering the proximity of the vertebrae on the concave side to the aorta and other vital organs, it is more convenient to use cannulated pedicle screws in this region.

Şarlak et al^[42] evaluated 185 screws inserted using the free-hand technique into 19 AIS patients using postoperative CT scans. The misplacement rate was 29.1% (54/185). Similarly, Modi et al^[9] evaluated the results of 37 cases of neuromuscular scoliosis and revealed a misplacement rate of 27%. Yingsakmongkol et al^[47] used CT scan to evaluate 14 cases, and found a high misplacement rate of 65%. In various studies,^[4,6,45] the reported misplacement rates are around 25%—close to that of our conventional pedicle screw group (group 2). The results we obtained in the cannulated pedicle screw group were better than those in the literature and in our control group.

The results are more promising when complications related to screw malposition are examined. In their review, Kwan et al^[6] indicated that, regarding 2020 screws, the symptomatic screw rate was only 0.1%, despite a 20% perforation rate. One screw caused numbness, whereas another caused radiculopathy; these 2 patients demonstrated clinically meaningful improvement after

medical treatment. Yılmaz et al^[42] reported no complications with clinical symptoms, despite a screw misplacement rate of 29.1%. Nevertheless, 7 screws causing aortic irritation required revision. Likewise, in various other studies,^[21,37,51] low clinical complication rates were reported, despite higher misplacement rates. In our study, there was only 1 clinical complication (numbness) due to inferior grade 2 malposition in the conventional pedicle screw group (group 2), and it did not require intervention. In group 2, 2 screws abutting the aorta were revised. On the contrary, in the cannulated pedicle screw group (group 1), no clinical complications occurred, and no screws required revision. Although we did not encounter any complications, to prevent possible complications, we withdrew the guide wire when the screw was ideally positioned or when we felt that the screw was not passing along the wire.

Studies examining lateral perforation^[6,36,37,42,45] reported rates of 8.6% to 18.3%; in all of these studies, the lateral perforation rate was much higher than the medial perforation rate. Lehman et al^[37] compared lateral and medial perforation rates in 1023 screws, and reported a lateral perforation rate (88) that was 4 times higher than the medial perforation rate.^[19,38] In our study, the medial perforation rate was consistent with the rates provided in other studies.^[6,36,37,42,45] With regard to medial perforation, there was no statistically significant intergroup difference (group 1, 34 [9%]; group 2, 31[10%]). Because we could only control the lateral perforation with a cannulated screw, it did not contribute to our understanding of the medial perforation. In our study, in group 2, parallel with the literature, the lateral perforation rate (14.7%) was higher than the medial perforation rate (10%). In group 1, on the contrary, the lateral perforation rate (7.7%) was lower than the medial perforation rate (9%) and lower than those reported in other studies. Therefore, we concluded that in the treatment of AIS, cannulated pedicle screws will decrease the lateral perforation rate, and cannulated pedicle screws should be used in treatment, particularly in the apical region.

Despite their many advantages, cannulated pedicle screws have some disadvantages. One such drawback is their lower biomechanical strength than that of classical screws. Cannulated pedicle screws have been shown to have a lesser ability to resist stress than classical pedicle screws. On the contrary, when conical screws were compared, no meaningful difference was found between cannulated and conventional pedicle screws.^[52] Therefore, in this study, only conical screws were used; as expected, no pull-out or broken screw-associated complications were observed in either group. The second main disadvantage is K-wire migration resulting in visceral organ or great vessel wounds.^[18] To prevent these types of complications during screw insertion, we observed the K-wire progress. If K-wire progress was observed, we stopped the process; when we felt that the screw was on this supposed track, the K wire was removed. No K wire-associated complications were observed.

The main weakness of our study is its retrospective design. Additionally, the 2 groups could have been compared in terms of radiation exposure, operation duration, and intraoperative bleeding. These comparisons could not have been performed due to a lack of data. We believe that, although no statistical analyses were performed, because both screws were inserted using the free-hand technique for each group without fluoroscopic guidance in the assessment of lateral perforation in the cannulated pedicle screw group, group 1 was exposed to less radiation. Additionally, because the screw placement accuracy rate was higher and the screw was inserted once easily, no time

was lost for screw replacement, resulting in shorter operative durations. In terms of bleeding, we believe that the cannulated screw is disadvantageous, mainly because of the blood leakage from the cannulation hole that persists until the screws are fixed with rods. Future studies are expected to address these issues.

5. Conclusions

Using cannulated screws in the treatment of AIS decreases perforation and complication rates. Although the use of cannulated pedicle screws does not lead to a statistically significant change in the medial perforation rate, it dramatically decreases the lateral perforation rate. Use of cannulated screws enables the intraoperative check of placement accuracy. The use of cannulated pedicle screws in the treatment of AIS is a safer and more efficient method than the use of conventional pedicle screws.

Author contributions

Conceptualization: sinan yilar.

Investigation: sinan yilar.

Visualization: sinan yilar.

Writing – original draft: sinan yilar.

References

- [1] Weiss H. Best Practice in Conservative Scoliosis Care. 4Munich: Pflaum; 2012.
- [2] Weinstein SL, Dolan LA, Cheng JC, et al. Adolescent idiopathic scoliosis. *Lancet* 2008;371:1527–37.
- [3] Yılmaz H, Zateri C, Vurur S, et al. Prevalence of adolescent idiopathic scoliosis among primary school children in Canakkale, Turkey. *Scoliosis* 2012;7:O37.
- [4] Halm H, Niemeyer T, Link T, et al. Segmental pedicle screw instrumentation in idiopathic thoracolumbar and lumbar scoliosis. *Eur Spine J* 2000;9:191–7.
- [5] Hamill CL, Lenke LG, Bridwell KH, et al. The use of pedicle screw fixation to improve correction in the lumbar spine of patients with idiopathic scoliosis: is it warranted? *Spine* 1996;21:1241–9.
- [6] Kwan MK, Chiu CK, Gani SMA, et al. Accuracy and safety of pedicle screw placement in adolescent idiopathic scoliosis patients: a review of 2020 screws using computed tomography assessment. *Spine* 2017;42:326–35.
- [7] Suk S-I, Lee CK, Kim W-J, et al. Segmental pedicle screw fixation in the treatment of thoracic idiopathic scoliosis. *Spine* 1995;20:1399–405.
- [8] Ugur HÇ, Attar A, Uz A, et al. Thoracic pedicle: surgical anatomic evaluation and relations. *Clin Spine Surg* 2001;14:39–45.
- [9] Modi H, Suh SW, Song H-R, et al. Accuracy of thoracic pedicle screw placement in scoliosis using the ideal pedicle entry point during the freehand technique. *Int Orthop* 2009;33:469–75.
- [10] Rampersaud YR, Pik JH, Salonen D, et al. Clinical accuracy of fluoroscopic computer-assisted pedicle screw fixation: a CT analysis. *Spine* 2005;30:E183–90.
- [11] Vaccaro AR, Rizzolo SJ, Balderston RA, et al. Placement of pedicle screws in the thoracic spine. Part II: an anatomical and radiographic assessment. *J Bone Joint Surg Am* 1995;77:1200–6.
- [12] Panjabi M, O'holleran J, Crisco J, et al. Complexity of the thoracic spine pedicle anatomy. *Eur Spine J* 1997;6:19–24.
- [13] Liljenqvist UR, Link TM, Halm HF. Morphometric analysis of thoracic and lumbar vertebrae in idiopathic scoliosis. *Spine* 2000;25:1247–53.
- [14] Meng X-t, Guan X-f, Zhang H-l, et al. Computer navigation versus fluoroscopy-guided navigation for thoracic pedicle screw placement: a meta-analysis. *Neurosurg Rev* 2016;39:385–91.
- [15] O'brien MF, Lenke LG, Mardjetko S, et al. Pedicle morphology in thoracic adolescent idiopathic scoliosis: is pedicle fixation an anatomically viable technique? *Spine* 2000;25:2285–93.
- [16] Liljenqvist UR, Allkemper T, Hackenberg L, et al. Analysis of vertebral morphology in idiopathic scoliosis with use of magnetic resonance imaging and multiplanar reconstruction. *J Bone Joint Surg Am* 2002;84:359–68.

- [17] Watanabe K, Lenke LG, Matsumoto M, et al. A novel pedicle channel classification describing osseous anatomy: how many thoracic scoliotic pedicles have cancellous channels? *Spine* 2010;35:1836–42.
- [18] Lee CK, Chan CYW, Gani SMA, et al. Accuracy of cannulated pedicle screw versus conventional pedicle screw for extra-pedicular screw placement in dysplastic pedicles without cancellous channel in adolescent idiopathic scoliosis: a computerized tomography (CT) analysis. *Eur Spine J* 2017;26:2951–60.
- [19] Lenke LG, Betz RR, Clements D, et al. Curve prevalence of a new classification of operative adolescent idiopathic scoliosis: does classification correlate with treatment? *Spine* 2002;27:604–11.
- [20] Rao G, Brodke DS, Rondina M, et al. Comparison of computerized tomography and direct visualization in thoracic pedicle screw placement. *J Neurosurg* 2002;97:223–6.
- [21] Sarwahi V, Wendolowski SF, Gecelter RC, et al. Are we underestimating the significance of pedicle screw misplacement? *Spine* 2016;41:E548–55.
- [22] Rao G, Brodke DS, Rondina M, et al. Inter-and intraobserver reliability of computed tomography in assessment of thoracic pedicle screw placement. *Spine* 2003;28:2527–30.
- [23] Schulze CJ, Munzinger E, Weber U. Clinical relevance of accuracy of pedicle screw placement: a computed tomographic-supported analysis. *Spine* 1998;23:2215–20.
- [24] IBM SPSS statistics for Windows, version 20.0. New York: IBM Corp; 2011.
- [25] Liljenqvist U, Lepsien U, Hackenberg L, et al. Comparative analysis of pedicle screw and hook instrumentation in posterior correction and fusion of idiopathic thoracic scoliosis. *Eur Spine J* 2002;11:336–43.
- [26] Kim YJ, Lenke LG, Kim J, et al. Comparative analysis of pedicle screw versus hybrid instrumentation in posterior spinal fusion of adolescent idiopathic scoliosis. *Spine* 2006;31:291–8.
- [27] Suk S, Lee C, Min H, et al. Comparison of Cotrel-Dubousset pedicle screws and hooks in the treatment of idiopathic scoliosis. *Int Orthop* 1994;18:341–6.
- [28] Vaccaro AR, Rizzolo SJ, Allardyce TJ, et al. Placement of pedicle screws in the thoracic spine. Part I: morphometric analysis of the thoracic vertebrae. *J Bone Joint Surg Am* 1995;77:1193–9.
- [29] Suk S-I, Kim W-J, Lee S-M, et al. Thoracic pedicle screw fixation in spinal deformities: are they really safe? *Spine* 2001;26:2049–57.
- [30] Kuklo TR, Lenke LG, O'Brien MF, et al. Accuracy and efficacy of thoracic pedicle screws in curves more than 90. *Spine* 2005;30:222–6.
- [31] Ebraheim NA, Jabaly G, Xu R, et al. Anatomic relations of the thoracic pedicle to the adjacent neural structures. *Spine* 1997;22:1553–6.
- [32] Belmont PJJr, Klemme WR, Dhawan A, et al. In vivo accuracy of thoracic pedicle screws. *Spine* 2001;26:2340–6.
- [33] Smorgick Y, Millgram MA, Anekstein Y, et al. Accuracy and safety of thoracic pedicle screw placement in spinal deformities. *Clin Spine Surg* 2005;18:522–6.
- [34] Kim YJ, Lenke LG, Bridwell KH, et al. Free hand pedicle screw placement in the thoracic spine: is it safe? *Spine* 2004;29:333–42.
- [35] Xu R, Ebraheim NA, Ou Y, et al. Anatomic considerations of pedicle screw placement in the thoracic spine: Roy-Camille technique versus open-lamina technique. *Spine* 1998;23:1065–8.
- [36] Kim YJ, Lenke LG, Cheh G, et al. Evaluation of pedicle screw placement in the deformed spine using intraoperative plain radiographs: a comparison with computerized tomography. *Spine* 2005;30:2084–8.
- [37] Lehman RAJr, Lenke LG, Keeler KA, et al. Computed tomography evaluation of pedicle screws placed in the pediatric deformed spine over an 8-year period. *Spine* 2007;32:2679–84.
- [38] Farber GL, Place HM, Mazur RA, et al. Accuracy of pedicle screw placement in lumbar fusions by plain radiographs and computed tomography. *Spine* 1995;20:1494–9.
- [39] Etemadifar M, Jamalaldini M. Evaluating accuracy of free-hand pedicle screw insertion in adolescent idiopathic scoliosis using postoperative multi-slice computed tomography scan. *Adv Biomed Res* 2017;6:19.
- [40] Di Silvestre M, Parisini P, Lolli F, et al. Complications of thoracic pedicle screws in scoliosis treatment. *Spine* 2007;32:1655–61.
- [41] Suk S-I, Lee S-M, Chung E-R, et al. Selective thoracic fusion with segmental pedicle screw fixation in the treatment of thoracic idiopathic scoliosis: more than 5-year follow-up. *Spine* 2005;30:1602–9.
- [42] Şarlak AY, Tosun B, Atmaca H, et al. Evaluation of thoracic pedicle screw placement in adolescent idiopathic scoliosis. *Eur Spine J* 2009;18:1892.
- [43] Li G, Lv G, Passias P, et al. Complications associated with thoracic pedicle screws in spinal deformity. *Eur Spine J* 2010;19:1576–84.
- [44] Rajasekaran S, Vidyadhara S, Ramesh P, et al. Randomized clinical study to compare the accuracy of navigated and non-navigated thoracic pedicle screws in deformity correction surgeries. *Spine* 2007;32:E56–64.
- [45] Liljenqvist UR, Halm HF, Link TM. Pedicle screw instrumentation of the thoracic spine in idiopathic scoliosis. *Spine* 1997;22:2239–45.
- [46] Samdani AF, Ranade A, Sciubba DM, et al. Accuracy of free-hand placement of thoracic pedicle screws in adolescent idiopathic scoliosis: how much of a difference does surgeon experience make? *Eur Spine J* 2010;19:91–5.
- [47] Yingsakmongkol W, Hangsaphuk N, Lerdlam S. The accuracy of pedicle screw placement in thoracic spine using the Funnel technique in idiopathic scoliosis. *J Med Assoc Thailand* 2007;90:96.
- [48] Zindrick MR, Wiltse LL, Doornik A, et al. Analysis of the morphometric characteristics of the thoracic and lumbar pedicles. *Spine* 1987;12:160–6.
- [49] Raynor BL, Lenke LG, Kim Y, et al. Can triggered electromyograph thresholds predict safe thoracic pedicle screw placement? *Spine* 2002;27:2030–5.
- [50] Castro WH, Halm H, Jerosch J, et al. Accuracy of pedicle screw placement in lumbar vertebrae. *Spine* 1996;21:1320–4.
- [51] Hicks JM, Singla A, Shen FH, et al. Complications of pedicle screw fixation in scoliosis surgery: a systematic review. *Spine* 2010;35:E465–70.
- [52] Shih KS, Hsu CC, Hou SM, et al. Comparison of the bending performance of solid and cannulated spinal pedicle screws using finite element analyses and biomechanical tests. *Med Eng Phys* 2015;37:879–84.