

## Case Report



# White Cord Syndrome: A Reperfusion Injury Following Spinal Decompression Surgery

Jin-Shup So , Young-Jin Kim , and Jaewoo Chung

Department of Neurosurgery, Dankook University Hospital, Cheonan, Korea

## OPEN ACCESS

Received: Mar 18, 2022

Revised: Apr 25, 2022

Accepted: May 13, 2022

Published online: Jun 22, 2022

### Address for correspondence:

Young Jin Kim

Department of Neurosurgery, Dankook University Hospital, 201 Manghyang-ro, Dongnam-gu, Cheonan 05278, Korea.

Email: spine1225@naver.com

Copyright © 2022 Korean Neurotraumatology Society

This is an Open Access article distributed under the terms of the Creative Commons Attribution Non-Commercial License (<https://creativecommons.org/licenses/by-nc/4.0/>) which permits unrestricted non-commercial use, distribution, and reproduction in any medium, provided the original work is properly cited.

### ORCID iDs

Jin-Shup So

<https://orcid.org/0000-0001-5725-4536>

Young-Jin Kim

<https://orcid.org/0000-0002-6770-3523>

Jaewoo Chung

<https://orcid.org/0000-0002-3512-6610>

### Conflict of Interest

The authors have no financial conflicts of interest.

## ABSTRACT

Reperfusion injury of the spinal cord has been scarcely reported. Herein, we present a case of white cord syndrome after spinal decompression. A 61-year-old male, who initially had ossification of the posterior longitudinal ligament at C3-6 level, was admitted to our hospital with a ruptured disc at the C6-7 level. The patient experienced radiating pain in both upper extremities. Anterior cervical discectomy and fusion was performed. However, the patient developed quadriplegia. Emergency magnetic resonance imaging revealed a new and enlarged signal change in the spinal cord at the C4-7 level. Additional posterior decompression surgery was performed. After intense rehabilitation, the patient's motor function improved to grade 4. White cord syndrome is likely due to reperfusion injury following operative decompression of a compressed spinal cord segment. Although rare, spine surgeons should be aware of this complication and warn patients preoperatively.

**Keywords:** Reperfusion injury; Surgical decompression; Neurologic deficit

## INTRODUCTION

White cord syndrome (WCS) is a condition that is characterized by sudden motor weakness and the new appearance of a signal change in the spinal cord on postoperative magnetic resonance imaging (MRI) after decompressive surgery.<sup>4)</sup> There have been only a handful of reports of WCS worldwide.<sup>1,2,3,7,13,15,17,20)</sup> In most reported cases, patients with WCS received additional surgery due to the sudden aggravation of initial neurologic symptoms. A few hypotheses for the cause of this syndrome have been presented but the most prominent theory is the sudden flow of blood due to reperfusion, causing damage to the spinal cord with ischemic damage after decompressive surgery like discectomy, laminectomy, or laminoplasty.<sup>1-3,6,7,11,18)</sup> These procedures are known to be safe, and severe complications such as postoperative neurologic deterioration rarely occur unless there was a direct iatrogenic injury to the spinal cord itself. Past studies showed that such complications occurred in only 1% of the patients who received spine-related surgery.<sup>2,4)</sup> Nevertheless, the result of WCS can be devastating if not treated with the utmost diligence and agility. Here, we present a case of WCS where the patient experienced sudden neurologic aggravation after anterior cervical discectomy and fusion (ACDF) due to cervical stenosis at C4-5 level and a huge rupture at the C6-7 level.

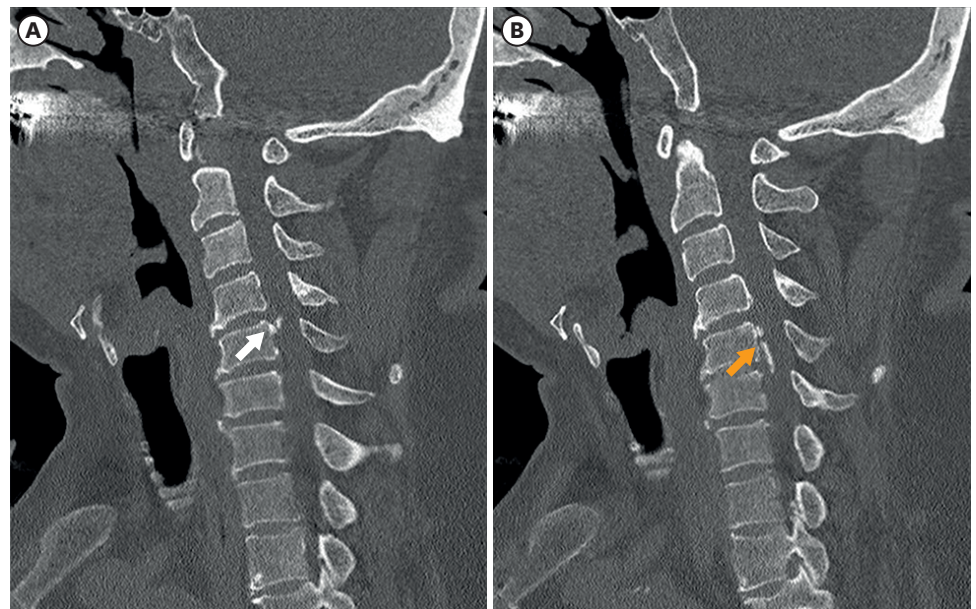
## CASE REPORT

A 61-year-old male who had a known cervical stenosis due to bony spur at C4-5 level (**FIGURE 1A**) and ossification of the posterior longitudinal ligament with a cord signal change at the C5-6 level (**FIGURE 1B**), was admitted to our emergency room for intolerable worsening pain in his scapula area and the motor weakness of his entire upper extremity. He had a car accident two months prior to admission and had visited several pain clinics including oriental medicine clinic. However, his symptoms worsened. Upon admission, the patient presented with radiating pain in both upper extremities, gradually worsening motor weakness (motor grade 4+ to 4), and a positive L'Hermite's sign. Immediate MRI revealed a signal change at C3-5 level with significant compression of the spinal cord (**FIGURE 2**) along with a huge ruptured disc at the C6-7-disc level, severely compressing the spinal cord (**FIGURE 3**).

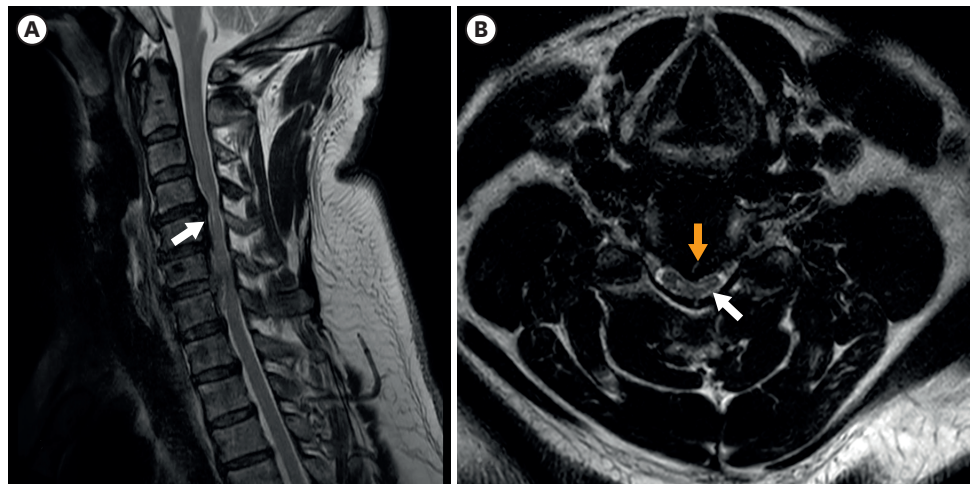
ACDF on C4-5 and C6-7 was performed to relieve the patient from his symptoms. Intraoperative monitoring (IOM) could not be applied since the procedure was an emergency operation.

The patient received general anesthesia with 70 mg of rocuronium, 160 mg of propofol, and 50 mg of lidocaine and remifentanyl. The mean arterial pressure (MAP) during surgery was kept between 60 and 85 mmHg. The procedure was successfully carried out without any adverse events. However, an immediate postoperative neurological examination of the patient showed a near complete quadriplegia.

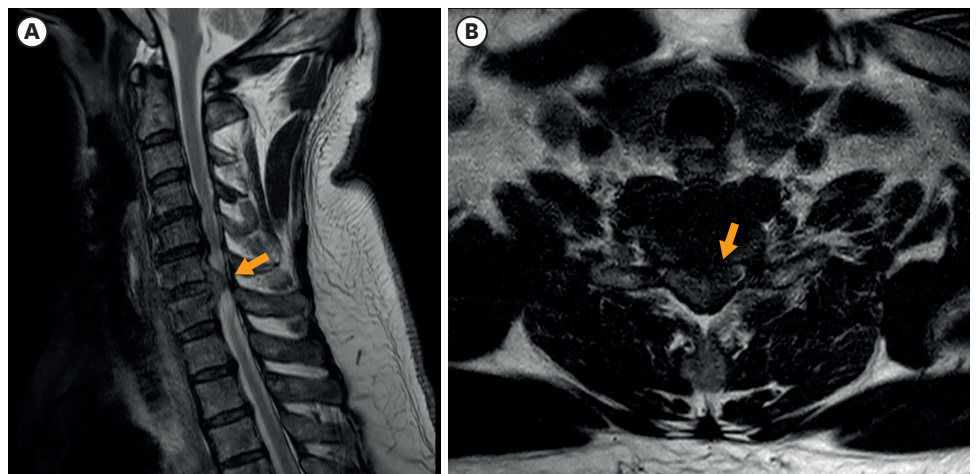
Emergency cervical MRI was performed, showing an extended longitudinal signal change in the spinal cord at the C3-5 levels (**FIGURE 4A**) and a newly formed cord signal change at C6-7 level (**FIGURE 4B**). Additional posterior decompression of the cervical spine via total laminectomy of C4-6, subtotal laminectomy of C7 and lateral mass screw fixation of C4-6 was performed. The patient underwent general anesthesia with 70 mg of rocuronium, 160 mg of



**FIGURE 1.** (A) Known large bony spur on C4-5 level (white arrow). (B) Ossification of posterior longitudinal ligament (yellow arrow) at C5-6 level growing into the spinal canal compressing the spinal cord.



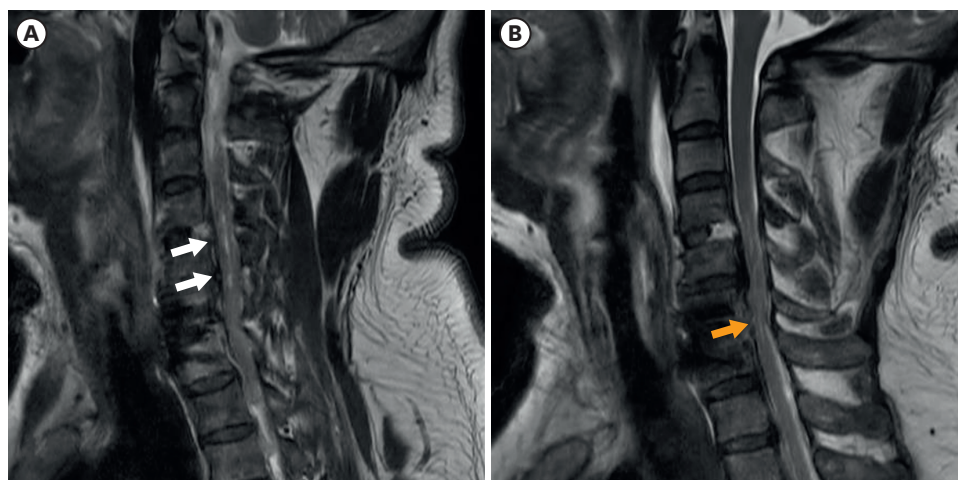
**FIGURE 2.** (A) Preoperative sagittal T2 weighted MRI revealing the high intensity signal change on T2-weighted image at C3-5 level (white arrow). (B) Preoperative axial T2 weighted MRI showing significant cord compression (yellow arrow) with malacic change (white arrow) in C3-4 level. MRI, magnetic resonance imaging.



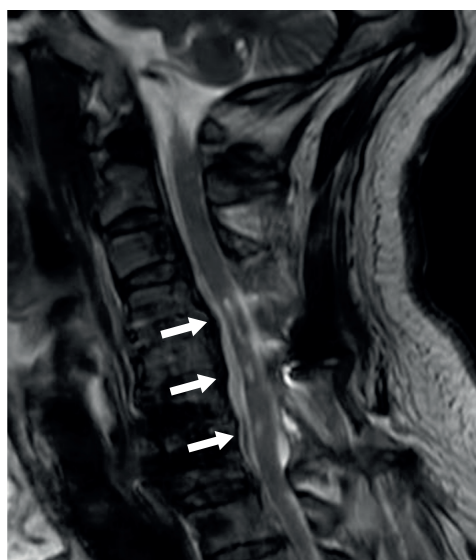
**FIGURE 3.** (A) Preoperative sagittal T2 weighted MRI revealing a huge ruptured disc at C6-7 level (yellow arrow). (B) Preoperative axial T2 weighted MRI showing severely compressed spinal cord at C6-7 level (yellow arrow). MRI, magnetic resonance imaging.

propofol, and 50 mg of lidocaine and remifentanyl. The MAP was maintained between 76 to 93 mmHg during surgery.

The patient's pain sensation recovered and his motor grade improved to grade 3 postoperatively. During hospitalization, he received intravenous methylprednisolone (MP) according to the NASCIS-2 protocol. On the seventh postoperative day, the patient was transferred to the rehabilitation department. His motor weakness fully recovered after two months of intense rehabilitation. Before his discharge his follow up MRI revealed a more prominent signal change of the spinal cord (**FIGURE 5**). He also was prescribed medications to control his mild neuropathic pain for 3 years.



**FIGURE 4.** (A) Postoperative MRI showing elongated and enlarged area of high intensity signal change (white arrows) than the preoperative MRI on T2-weighted image. (B) Postoperative MRI showing new high intensity signal change at C6-7 level (yellow arrow). MRI, magnetic resonance imaging.



**FIGURE 5.** Follow up magnetic resonance imaging reveals the more prominent signal change of the spinal cord (white arrows).

## DISCUSSION

WCS is a very rare but devastating complication. It is usually diagnosed after decompression surgery of the spinal cord due to severe stenosis.<sup>6,18</sup> Patients commonly show sudden loss or aggravation of motor function below the affected lesion after surgery and on postoperative T2-weighted MRI, a newly formed or broadened area of high signal change on the spinal cord is observed.<sup>3,6</sup> In most reported cases, the sudden motor deficit resolves to normal function but in some patients, the symptoms persist without improvement.

Only a handful of WCS cases have been reported (**TABLE 1**) and its pathophysiology has not yet been revealed. Also, since the first report of WCS in 2013 by Chin et al.,<sup>3</sup> the incidence of WCS has seemed to increase as physicians become more aware of the disorder. Numerous

**TABLE 1.** Previous cases reported regarding white cord syndrome

Study	Year	Initial diagnosis	IOM	Initial surgery	Neurology after initial surgery	Emergency treatment	Treatment outcome after emergency treatment
Chin et al. <sup>3)</sup>	2013	Severe HCD C5-6	Yes	ACDF	Incomplete tetraplegia	Corpectomy, HDS	No recovery
Zhang et al. <sup>20)</sup>	2013	Cervical stenosis C5, C5-6, C6-7	No	ACCF	Quadriplegia	1 <sup>st</sup> , 2 <sup>nd</sup> pt: HDS, 3 <sup>rd</sup> pt: HDS, Laminoplasty	1 <sup>st</sup> , 2 <sup>nd</sup> pt: Full recovery, 3 <sup>rd</sup> pt: partial recovery
Giammalva et al. <sup>7)</sup>	2016	Severe HCD C3-4, 5-6	No	ACDF	Tetraplegia in Both U/Ext.	HDS, Rehabilitation	Minimal recovery
Khan et al. <sup>10)</sup>	2017	Severe HCD C5-6	No	ACDF	Anterior cord syndrome	Rehabilitation	Residual motor weakness
Antwi et al. <sup>1)</sup>	2018	Severe cervical stenosis C4-6	Yes	Laminectomy and posterior fixation	Hemiparesis	HDS, Rehabilitation	Residual motor weakness
Vinodh et al. <sup>17)</sup>	2018	Severe cervical stenosis C3-4 (Tumor)	No	Laminectomy and TPSF	Quadriplegia	HDS, Rehabilitation	No recovery
Papaoiannou et al. <sup>13)</sup>	2019	Cervical stenosis	Yes	Laminectomy and TPSF	Incomplete paraplegia	HDS, Posterior decompression	Residual motor weakness
Wiginton et al. <sup>18)</sup>	2019	Cervical stenosis C1-2	Yes	Laminectomy	Quadriplegia	HDS, Increased MAP	Full recovery
Busack and Eagleton <sup>2)</sup>	2020	Severe cervical stenosis C2-6	Yes	Laminectomy and TPSF	Tetraplegia	HDS, Rehabilitation	Full recovery
Jun et al. <sup>9)</sup>	2020	Severe HCD C6-7	No	ACDF	Paraplegia of L/Ext.	HDS, Laminoplasty	Full recovery
Sepulveda et al. <sup>15)</sup>	2020	Acquired arachnoid cyst On C1-4	Yes	Laminectomy and arachnoid cyst fenestration	Rt. U/Ext. Monoplegia	HDS, Rehabilitation	Full motor recovery, Chronic pain on Rt. U/Ext.
Liao et al. <sup>11)</sup>	2020	OPLL C2-4	No	Laminectomy and TPSF	Hemiparesis	HDS	Full recovery
Kalidindi and Sath <sup>9)</sup>	2020	OPLL C2-T1	Yes	Laminectomy and posterior fixation	Tetraplegia	HDS	No recovery
Mathkour et al. <sup>12)</sup>	2020	Severe cervical stenosis C3-6	Yes	Laminectomy and posterior fixation	Rt. Motor aggravation	HDS, MAP control, Rehabilitation	Full recovery
Segal et al. <sup>14)</sup>	2021	Severe cervical stenosis	No	Laminectomy and posterior fixation	Quadriplegia	HDS, MAP control, Rehabilitation	Full recovery

IOM: intraoperative monitoring, HCD: herniated cervical disc, OPLL: ossification of posterior longitudinal ligament, ACDF: anterior cervical discectomy and fusion, ACCF: anterior cervical corpectomy and fusion, LMSF: lateral mass screw fixation, TPSF: transpedicular screw fixation HDS: high dose steroid M: Male, F: female, pt: patient mo: month, Rt.: right, Lt.: left, U/Ext.: upper extremity, L/Ext. lower extremity.

theories regarding its mechanism have been suggested throughout the years, including micro-emboli causing spinal cord ischemia, alterations in perfusion due to the change in spinal cord architecture after decompression surgery, and ischemia/reperfusion causing spinal cord injury.<sup>18)</sup>

The most supported possible etiology for WCS is spinal cord ischemia/reperfusion injury after decompression surgery. It is hypothesized that when sudden cord expansion occurs after surgery, the abrupt flow of blood to the lesion can either trigger an inflammatory cascade causing the release of oxygen free radicals, which damage the neuronal structure leading to sudden neurologic deficits, or the sudden flow of blood can directly cause blunt damage to the neuronal cells themselves.<sup>2,12,18)</sup> Studies with animal models have supported this phenomenon, showing the increased expression of inflammatory cytokines (up to 1.5 to 2-fold higher than normal) such as interleukin-1 $\beta$ , tumor necrosis factor- $\alpha$ , or 8-oxoG DNA after decompression spinal surgery.<sup>5,19)</sup>

To the author's knowledge, there are no current treatment strategies or preventative measures for WCS. Also, there are few treatment options for neuronal injury in modern medical science. Nevertheless, previous case reports presented several options for the more successful treatment of WCS.

The use of IOM of the somatosensory evoked potential (SSEP) and motor evoked potential (MEP) could play a crucial role in the early detection of WCS.<sup>2)</sup> The syndrome is usually

diagnosed when surgery is completed and the patient is sent back to their ward. However, if early detection is possible, physicians can make quick decisions for whether to extend the extent of the decompression or change the method of surgery. Several case reports have already shown the successful use of SSEP and MEP monitoring where early detection and immediate quick decisions during surgery have helped patients.<sup>1,2,3,9,12-15,18)</sup>

High-dose MP has been used in cases of neuronal damage due to its theoretical capacity to inhibit lipid peroxidation and slow secondary nerve damage. Although the use of MP in neuronal recovery is controversial and still has no level 1 evidence, studies have shown positive outcomes in significant motor recovery by using MP for 24 hours in patients with neurologic injury within 8 hours.<sup>11,16,18)</sup>

Regulation of the MAP has been suggested to reduce the risk of WCS. Similar to cerebral hyperperfusion syndrome, strict control of blood pressure during and after decompression surgery can be crucial in the aggravation of a neuronal injury. Nevertheless, there are no strong evidence regarding the maintenance of MAP in spinal cord injury. Busack and Eagleton<sup>2)</sup> stated that patients with cord injury need to maintain a MAP higher than 85 mmHg since the autoregulatory zone for cerebral perfusion would be relatively higher than that of normal patients, which is usually thought to range between 70 to 150 mmHg for stable cerebral perfusion. Yang et al.<sup>19)</sup> also revealed that increased MAP up to 85 mmHg had positive effects in restoring or improving lost neuromonitoring signals.

Our case demonstrates the devastating results of WCS and physicians should always be cautious when executing cervical decompression surgeries when there is evidence of chronic spinal cord compression. Physicians should also warn patients under these conditions of the possibilities of WCS beforehand to avoid any legal issues.

## CONCLUSION

Due to its scarcity, physicians may disregard the possibility of WCS occurrence and be caught by surprise. The case presented in this report show that WCS can occur in our everyday medical life. In the past, cases such as WCS were unexplainable. Although more prospective multicenter studies need to determine its exact mechanism to prevent and successfully manage WCS, the fact that more and more surgeons are becoming aware is important. Physicians should always warn patients with severe cord-compressing conditions about WCS before surgery.

## REFERENCES

1. Antwi P, Grant R, Kuzmik G, Abbed K. "White cord syndrome" of acute hemiparesis after posterior cervical decompression and fusion for chronic cervical stenosis. *World Neurosurg* 113:33-36, 2018  
[PUBMED](#) | [CROSSREF](#)
2. Busack CD, Eagleton BE. White cord syndrome causing transient tetraplegia after posterior decompression and fusion. *Ochsner J* 20:334-338, 2020  
[PUBMED](#) | [CROSSREF](#)
3. Chin KR, Seale J, Cumming V. "White cord syndrome" of acute tetraplegia after anterior cervical decompression and fusion for chronic spinal cord compression: a case report. *Case Rep Orthop* 2013:697918, 2013  
[PUBMED](#) | [CROSSREF](#)

4. Cramer DE, Maher PC, Pettigrew DB, Kuntz C 4th. Major neurologic deficit immediately after adult spinal surgery: incidence and etiology over 10 years at a single training institution. *J Spinal Disord Tech* 22:565-570, 2009  
[PUBMED](#) | [CROSSREF](#)
5. Dumont RJ, Okonkwo DO, Verma S, Hurlbert RJ, Boulos PT, Ellegala DB, et al. Acute spinal cord injury, part I: pathophysiologic mechanisms. *Clin Neuropharmacol* 24:254-264, 2001  
[PUBMED](#) | [CROSSREF](#)
6. Epstein NE. Reperfusion injury (RPI)/white cord syndrome (WCS) due to cervical spine surgery: a diagnosis of exclusion. *Surg Neurol Int* 11:320, 2020  
[PUBMED](#) | [CROSSREF](#)
7. Giammalva GR, Maugeri R, Graziano F, Guli C, Giugno A, Basile L, et al. White cord syndrome after non-contiguous double-level anterior cervical decompression and fusion (ACDF): a “no reflow phenomenon”? *Interdisciplinary Neurosurgery* 7:47-49, 2017  
[CROSSREF](#)
8. Jun DS, Baik JM, Lee SK. A case report: white cord syndrome following anterior cervical discectomy and fusion: importance of prompt diagnosis and treatment. *BMC Musculoskelet Disord* 21:157, 2020  
[PUBMED](#) | [CROSSREF](#)
9. Kalidindi KK, Sath S. “White cord syndrome” of acute tetraplegia after posterior cervical decompression and resulting hypoxic brain injury. *Asian J Neurosurg* 15:756-758, 2020  
[PUBMED](#) | [CROSSREF](#)
10. Khan MF, Jooma R, Hashmi FA, Raghieb MF. Delayed spinal cord infarction following anterior cervical surgical decompression. *BMJ Case Rep* 2017:bcr-2017-219863, 2017  
[PUBMED](#) | [CROSSREF](#)
11. Liao YX, He SS, He ZM. ‘White cord syndrome’, a rare but disastrous complication of transient paralysis after posterior cervical decompression for severe cervical spondylotic myelopathy and spinal stenosis: a case report. *Exp Ther Med* 20:90, 2020  
[PUBMED](#) | [CROSSREF](#)
12. Mathkour M, Werner C, Riffle J, Scullen T, Dallapiazza RF, Dumont A, et al. Reperfusion “white cord” syndrome in cervical spondylotic myelopathy: Does mean arterial pressure goal make a difference? Additional case and literature review. *World Neurosurg* 137:194-199, 2020  
[PUBMED](#) | [CROSSREF](#)
13. Papaioannou I, Repantis T, Baikousis A, Korovessis P. Late-onset “white cord syndrome” in an elderly patient after posterior cervical decompression and fusion: a case report. *Spinal Cord Ser Cases* 5:28, 2019  
[PUBMED](#) | [CROSSREF](#)
14. Segal DN, Lunati MP, Kukowski NR, Michael KW. White cord syndrome and acute tetraplegia after posterior cervical decompression: a case report. *JBJS Case Connect* 11:11, 2021  
[PUBMED](#) | [CROSSREF](#)
15. Sepulveda F, Carballo L, Carnevale M, Yañez P. White cord syndrome in a pediatric patient: a case report and review. *Radiol Case Rep* 15:2343-2347, 2020  
[PUBMED](#) | [CROSSREF](#)
16. Vidal PM, Ulndreaj A, Badner A, Hong J, Fehlings MG. Methylprednisolone treatment enhances early recovery following surgical decompression for degenerative cervical myelopathy without compromise to the systemic immune system. *J Neuroinflammation* 15:222, 2018  
[PUBMED](#) | [CROSSREF](#)
17. Vinodh VP, Rajapathy SK, Sellamuthu P, Kandasamy R. White cord syndrome: A devastating complication of spinal decompression surgery. *Surg Neurol Int* 9:136, 2018  
[PUBMED](#) | [CROSSREF](#)
18. Wiginton JG 4th, Brazdzionis J, Mohrdar C, Sweiss R, Lawandy S. Spinal cord reperfusion injury: case report, review of the literature, and future treatment strategies. *Cureus* 11:e5279, 2019  
[PUBMED](#) | [CROSSREF](#)
19. Yang T, Wu L, Wang H, Fang J, Yao N, Xu Y. Inflammation level after decompression surgery for a rat model of chronic severe spinal cord compression and effects on ischemia-reperfusion injury. *Neurol Med Chir (Tokyo)* 55:578-586, 2015  
[PUBMED](#) | [CROSSREF](#)
20. Zhang JD, Xia Q, Ji N, Liu YC, Han Y, Ning SL. Transient paralysis shortly after anterior cervical corpectomy and fusion. *Orthop Surg* 5:23-28, 2013  
[PUBMED](#) | [CROSSREF](#)