

Available online at www.sciencedirect.com

ScienceDirect

journal homepage: www.elsevier.com/locate/radcr

Case Report

Anastomosing hemangioma of the liver: An unusual variant in abdominal MRI imaging [☆]

Tyler Rogers, MD^{a,*}, Neil Shah, MD^b, David Mauro, MD^c, Katrina A. McGinty, MD^d

^a University of North Carolina School of Medicine, 101 Manning Dr, Chapel Hill, NC 27514, USA

^b Division of Gastroenterology and Hepatology, Department of Internal Medicine, University of North Carolina Medical Center, Chapel Hill, NC, USA

^c Division of Vascular-Interventional Radiology, Department of Radiology, University of North Carolina Medical Center, Chapel Hill, NC, USA

^d Division of Abdominal Radiology, Department of Radiology, University of North Carolina Medical Center, Chapel Hill, NC, USA

ARTICLE INFO

Article history:

Received 8 September 2022

Accepted 14 September 2022

Keywords:

Anastomosing hemangioma

Hepatic vascular lesions

Hemangioma

MRI of the liver

Postcontrast MRI of the liver

Benign liver lesions

ABSTRACT

The liver is a rare site for anastomosing hemangiomas with only a few cases reported that characterize the lesions on magnetic resonance imaging (MRI). These lesions may be underreported due to overlapping features with classic hemangiomas. Anastomosing hemangiomas have a well-defined histological profile and are often diagnosed by biopsy in the setting of atypical imaging features. We report a case of biopsy-proven hepatic anastomosing hemangioma found on a screening MRI for hepatocellular carcinoma in a 52-year-old female with cirrhosis. This lesion initially demonstrated interval growth but has shown no local recurrence in the 2-year surveillance period following microwave ablation.

© 2022 The Authors. Published by Elsevier Inc. on behalf of University of Washington.

This is an open access article under the CC BY-NC-ND license (<http://creativecommons.org/licenses/by-nc-nd/4.0/>)

Introduction

We report a case of an anastomosing hemangioma detected on hepatocellular carcinoma (HCC) screening magnetic resonance imaging (MRI) in a patient with cirrhosis, which subsequently underwent biopsy, microwave ablation, and post ablation surveillance imaging. Anastomosing hemangiomas

were first described in the genitourinary organs [1]. A large database analysis performed over 6 years between 2009 and 2015 found 32 cases of anastomosing hemangiomas. The majority of these lesions were retroperitoneal (47%), occurring less frequently in the kidneys (22%), ovaries (13%) and only a minority in the liver (6%) [2]. As of 2019, a total of 26 reports of hepatic anastomosing hemangioma were found in the literature [3]. Even fewer cases of hepatic anastomosing heman-

[☆] Competing Interests: The authors have no conflicts of interest to declare. All co-authors have seen and agree with the contents of the manuscript and there is no financial interest to report. We certify that the submission is original work and is not under review at any other publication.

* Corresponding author.

E-mail address: tyler_rogers@med.unc.edu (T. Rogers).

<https://doi.org/10.1016/j.radcr.2022.09.052>

1930-0433/© 2022 The Authors. Published by Elsevier Inc. on behalf of University of Washington. This is an open access article under the CC BY-NC-ND license (<http://creativecommons.org/licenses/by-nc-nd/4.0/>)

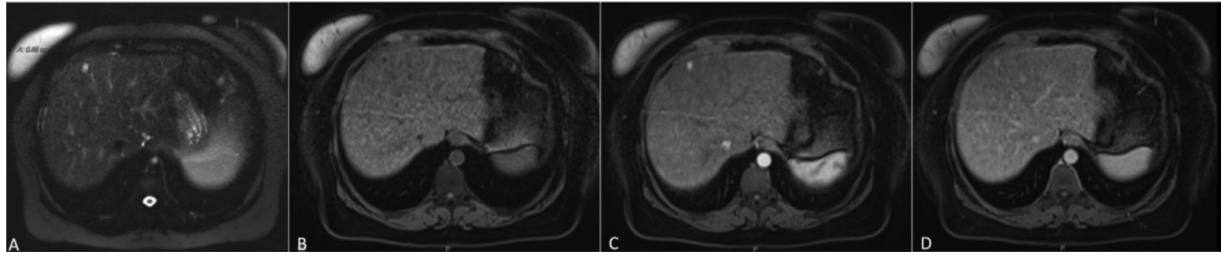


Fig. 1 – Initial MRI performed for HCC screening showing lesion in segment 4A (A) T2 fat-suppressed imaging demonstrating homogenous T2 hyperintense signal. (B) Precontrast imaging demonstrating T1 hypointense lesion with (C) avid arterial enhancement and (D) retention of contrast on equilibrium phase.

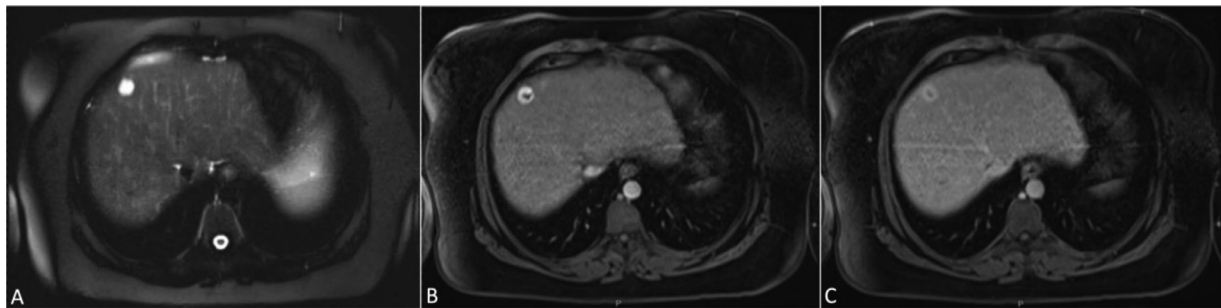


Fig. 2 – MRI performed 18 months later demonstrating interval growth and (A) T2 fat-suppressed imaging demonstrating more heterogeneous T2 signal (B) late arterial phase postcontrast imaging showing rim like pattern of enhancement and (C) equilibrium phase imaging demonstrating persistent rim like pattern of enhancement.

gioma have been characterized by MRI, with those reported lacking documentation of interventions, changes in size, and changes in lesion characteristics on follow-up.

Case description

We describe a 52-year-old female with biopsy proven cirrhosis secondary to non-alcoholic fatty liver disease (NAFLD) undergoing routine HCC screening with MRI. Initial screening MRI demonstrated a sub centimeter T1 hypointense arterially enhancing lesion in segment 4A with faint retention of contrast in equilibrium phase, demonstrating T2 hyperintense signal and no appreciable restricted diffusion (Fig. 1). While small size limited characterization, the lesion was characterized as a probable flash filling hemangioma (Liver Reporting & Data System, LI-RADS 2 lesion). However, over the next 18 months, the lesion demonstrated interval growth, increasing from 0.8 cm to 1.6 cm. Additionally, the enhancement pattern changed with the lesion subsequently demonstrating a nodular, continuous rim enhancement and central non enhancement. Delayed imaging did not demonstrate central filling. T2-weighted imaging demonstrated heterogeneously bright signal and no appreciable restricted diffusion (Fig. 2). In the setting of underlying cirrhosis and threshold growth, the lesion was reclassified as a LI-RADS M lesion. After multidisciplinary discussion, the decision was made to proceed with biopsy and concurrent laparoscopic microwave ablation. Biopsy demon-

strated a well-demarcated proliferation of plump ovoid tumor cells lining compressed small vascular spaces. Focal hobnailing was present. The lesion lacked significant atypia or mitotic activity. Next-generation sequencing (NGS)-based sequencing was not performed to evaluate for GNAQ mutation. Immunohistochemical staining was performed and notably positive for CD34, CD31, ERG, with a low Ki-67 index. Based on this, the lesion was classified as an anastomosing hemangioma. The patient has received follow-up abdominal MRI every 6 months for surveillance and HCC screening, with no signs of recurrence for 2 years following ablation.

Discussion

Few cases of anastomosing hemangioma have been characterized by MRI in the literature, with known reports outlined in Table 1. MRI imaging findings across all reports describe T1 hypointense signal and T2 hyperintense signal. Often, these lesions resemble capillary hemangiomas on post contrast imaging, due to rapid filling time with diffuse heterogeneous or nodular enhancement in the early arterial phase, and continued enhancement in the portal venous and delayed phases and lack of restricted diffusion [3]. Peripheral venous lakes cause classic hemangiomas to demonstrate early arterial peripheral nodular discontinuous enhancement [4,5], which can help differentiate classic hemangiomas from anastomosing hemangiomas.

Table 1 – Previous case reports of anastomosing hemangioma on MRI imaging.

Author	Pt sex	Pt Age	Size (cm)	Growth	Management	Follow-up	Unique MRI features
Peng [6]	F	57	3.3		Biopsy	N/A	Early peripheral rim enhancement and delayed phases with central hypoenhancement
Merritt[3]	M	56	3.4	N/A	Biopsy	N/A	Homogeneous arterial and delayed phase hyperenhancement
Lunn [7]	F	33	5.1	N/A	Biopsy and resection	N/A	Homogeneous arterial and delayed phase hyperenhancement,
	F	67	1.7	0.5 cm	Biopsy	3 years	Homogeneous arterial and delayed phase hyperenhancement,
	M	77	2.1	N/A	Biopsy	N/A	Early arterial rim enhancement with some centripetal filling
	M	2	1.9	N/A	Wedge resection	N/A	Early rim enhancement and delayed phases with central hypoenhancement
Current case	52	F	0.8	0.8 cm	Biopsy w/ ablation	2 years	Early arterial rim enhancement with central hypoenhancement

Table 2 – Immunohistochemical findings.

Immunohistochemical finding	Finding	Interpretation
CD34, CD31, ERG	Positive	Supports endothelial differentiation.
Fli-1	Patchy positive	Supports endothelial differentiation.
CD68	Diffusely positive	Uncertain significance
CD45		Highlights B and T cells, and shows focal staining of tumor cells
CD3, CD5		Highlight scattered background B cells.
PAX5, CD20		Highlight scattered background B cells.
OSCAR	Negative	Does not support epithelial differentiation
HepPar-1	Negative	Does not support epithelial differentiation
S100	Negative	Does not support neural tumor or melanoma.
HMB-45	Negative	Does not support melanoma or angiomyolipoma.
Ki-67	Low activity	Likely low proliferative index, difficult to quantify due to admixed B and T cells.
GNAQ	NGS based sequencing was not performed	Can help differentiate benign vascular lesions from malignant lesions such as angiosarcoma

However, there are variations to radiographic presentations of anastomosing hemangioma, both in the literature, as well as the case presented in this report. The imaging findings of classic hemangiomas represent a spectrum of possible features of anastomosing hemangioma. Small classic hemangiomas (less than 2 cm), also known as flash filling hemangiomas, may present with homogenous late arterial phase enhancement [4] and can be mistaken for HCC or hyper vascular metastases. Giant hemangiomas can demonstrate a T1 hypointense non enhancing central scar, similar to the central clearing seen in our case, representing areas of fibrosis. Other authors have reported similar smooth rim enhancement with central nonenhancement that persists on delayed phases [6] in anastomosing hemangiomas hypothesized to be due to degenerating hyaline globules and fibrin centrally [2,7]. However, the primary differential diagnoses that may be considered with this enhancement pattern include abscesses or mixed HCC-cholangiocarcinoma in a patient with cirrhosis. In our case, the lesion initially presented similarly to a flash filling hemangioma. However, the lesion demonstrated interval growth increased in size, and developed a more contin-

uous thick rim of enhancement with central non enhancement. This would be atypical for a classic hemangioma, which prompted biopsy in this high-risk patient. Given a high probability of malignancy in patient with cirrhosis, our patient proceeded with biopsy and concurrent ablative treatment after discussion in a multidisciplinary tumor board.

Due to its varied imaging presentations and low incidence, many anastomosing hemangiomas will undergo biopsy to rule out malignancy. Immunohistochemical results and significance from our case are shown below in Table 2. Classic biopsy shows non-proliferative capillary vascular channels, hobnailing of endothelial cells, fibrin thrombi, and hyaline eosinophilic globules [8,9]. Presence of GNAQ, Ki-67 index < 10% and lack of cytologic atypia and mitosis can help differentiate anastomosing hemangioma from malignant angiosarcomas [10,11]. Anastomosing hemangioma can also mimic another benign lesion known as hepatic small vessel neoplasm (HSVN) [11,12]. It has been suggested that HSVN represents a form of anastomosing hemangioma, differentiated simply by more infiltrative growth into the adjacent parenchyma leading to a lack of a well-demarcated border. Our patient's lesion

demonstrated a clear border against adjacent parenchyma, thus making it more like to represent an anastomosing hemangioma.

Conclusion

The lesion presented in this case report initially had benign imaging findings, but a growing lesion with an atypical appearance in a patient with cirrhosis is suspicious for malignancy. When definitely benign imaging findings are not present, or when high risk comorbid medical conditions exist, histological and immunohistochemical methods of lesion characterization are necessary to rule out malignancy. Anastomosing hemangioma has a more consistent and defined molecular biology profile than it does imaging profile, and understanding various molecular pathognomonic features is crucial in making an accurate diagnosis. Therefore, knowledge of both imaging and immunohistochemistry findings is required to make appropriate decisions in the various stages of the workup for these lesions

This case report contributes to the current literature by reporting MRI and histologic characteristics of anastomosing hemangioma of the liver, as well as by demonstrating the growth potential of these lesions. While therapeutic intervention is not needed or indicated, use of microwave ablation with post-intervention follow-up in this case does demonstrate the lack of local recurrence of these lesions. Continued reporting of cases is needed to appropriately characterize anastomosing hemangioma, especially given the low number of MRI characterized lesions in the literature, and the low number of lesions with reported growth or follow-up. Overall awareness of this entity is required to avoid unnecessary biopsy, histological misdiagnosis as angiosarcoma, and to avoid unnecessary surgical or ablative procedures.

Patient consent

Informed consent was obtained from the patient.

REFERENCES

- [1] Liau J, Lee J, Tsai J, Chen C, Wang Y, Chung Y, et al. Thrombotic hemangioma with organizing/anastomosing features. *Am J Surg Pathol* 2020;44(2):255–62. doi:[10.1097/PAS.0000000000001392](https://doi.org/10.1097/PAS.0000000000001392).
- [2] O'Neill AC, Craig JW, Silverman SG, Alencar RO. Anastomosing hemangiomas: locations of occurrence, imaging features, and diagnosis with percutaneous biopsy. *Abdom Radiol* 2016;41:1325–32. doi:[10.1007/s00261-016-0690-2](https://doi.org/10.1007/s00261-016-0690-2).
- [3] Merritt B, Behr S, Umetsu SE, Roberts J, Kolli KP. Anastomosing hemangioma of liver. *J Radiol Case Rep* 2019;13(6):32–9. doi:[10.3941/jrcr.v13i6.3644](https://doi.org/10.3941/jrcr.v13i6.3644).
- [4] Albiin N. MRI of focal liver lesions. *Curr Med Imaging Rev* 2012;8(2):107–16. doi:[10.2174/157340512800672216](https://doi.org/10.2174/157340512800672216).
- [5] Madrazo BL. Use of imaging studies to aid in the diagnosis of benign liver tumors. *Gastroenterol Hepatol (N Y)* 2011;7(10):683–5.
- [6] Peng X, Li J, Liang Z. Anastomosing haemangioma of liver: a case report. *Mol Clin Oncol* 2017;7(3):507–9. doi:[10.3892/mco.2017.1341](https://doi.org/10.3892/mco.2017.1341).
- [7] Lunn B, Yasir S, Lam-Himlin D, Menias CO, Torbenson MS, Venkatesh SK, et al. Anastomosing hemangioma of the liver: a case series. *Abdom Radiol* 2019;44:2781–7. doi:[10.1007/s00261-019-02043-x](https://doi.org/10.1007/s00261-019-02043-x).
- [8] Bean GR, Joseph NM, Gill RM, Folpe AL, Horvai AE, Umetsu SE, et al. Recurrent GNAQ mutations in anastomosing hemangiomas. *Modern Pathol* 2017;30(5):722–7.
- [9] Lin J, Bigge J, Ulbright TM, Montgomery E. Anastomosing hemangioma of the liver and gastrointestinal tract: an unusual variant histologically mimicking angiosarcoma. *Am J Surg Pathol* 2013;37(11):1761–5. doi:[10.1097/PAS.0b013e3182967e6c](https://doi.org/10.1097/PAS.0b013e3182967e6c).
- [10] Goh IY, Mulholland P, Sokolova A, Liu C, Siriwardhane M. Hepatic small vessel neoplasm—a systematic review. *Ann Med Surg (2012)* 2021;72:103004. doi:[10.1016/j.amsu.2021.103004](https://doi.org/10.1016/j.amsu.2021.103004).
- [11] Gill RM, Buelow B, Mather C, Joseph NM, Alves V, Brunt EM, et al. Hepatic small vessel neoplasm, a rare infiltrative vascular neoplasm of uncertain malignant potential. *Hum Pathol* 2016;54:143–51. doi:[10.1016/j.humpath.2016.03.018](https://doi.org/10.1016/j.humpath.2016.03.018).
- [12] Joseph NM, Brunt EM, Marginean C, Nalbantoglu I, Snover DC, Thung SN, et al. Frequent GNAQ and GNA14 mutations in hepatic small vessel neoplasm. *Am J Surg Pathol* 2018;42(9):1201–7. doi:[10.1097/PAS.0000000000001110](https://doi.org/10.1097/PAS.0000000000001110).