

Contents lists available at [ScienceDirect](http://www.sciencedirect.com)

International Journal of Surgery Case Reports

journal homepage: www.casereports.com

An interesting case report of vertebral artery dissection following polytrauma

Vikas Acharya^{a,*}, Suresh Chandrasekaran^a, Dr Sujit Nair^b^a Department of Neurosurgery, University Hospitals Coventry and Warwickshire, Clifford Bridge Road, Coventry, West Midlands, United Kingdom^b Department of Neuroradiology, University Hospitals Coventry and Warwickshire, Clifford Bridge Road, Coventry, West Midlands, United Kingdom

ARTICLE INFO

Article history:

Received 28 July 2016

Received in revised form

16 September 2016

Accepted 29 September 2016

Available online 3 October 2016

Keywords:

Arterial dissection

Cerebrovascular disease

Head injury

Case report

Neurosurgery

Polytrauma

ABSTRACT

INTRODUCTION: The authors present an interesting case of a 19-year-old male who presented as a polytrauma patient following a fall from a height.

PRESENTATION OF CASE: He was initially managed on the intensive care unit with intracranial pressure bolt monitoring after being intubated and sedated and having his other traumatic injuries stabilized. Upon attempting to wean sedation and extubation a repeat CT scan of the head was undertaken and showed a new area suggested of cerebral infarction, this was a new finding. Further imaging found that he had a cervical vertebral artery dissection following this polytrauma mode of injury.

DISCUSSION: The incidence of vertebral artery dissection following generalized or local trauma is rising but routine imaging/screening in these patients is not undertaken.

CONCLUSION: Our report displays select images related to this case report and emphasizes the consideration of routine imaging in head and neck traumatic injuries to diagnose internal carotid and/or vertebral artery dissections much earlier.

© 2016 The Authors. Published by Elsevier Ltd on behalf of IJS Publishing Group Ltd. This is an open access article under the CC BY-NC-ND license (<http://creativecommons.org/licenses/by-nc-nd/4.0/>).

1. Introduction

A vertebral artery dissection occurs when blood tracks into or accumulates within the wall of an artery, most commonly secondary to an endothelial surface tear [1]. Though not a commonly pathological occurrence, a vertebral artery dissection can lead to ischaemia and less often, subarachnoid haemorrhage [2]. It has been reported in the literatures that 1–4 cases per annum can be documented from large tertiary referral hospitals [3].

Spontaneous dissections of the vertebral artery are known to cause a stroke in the young and middle aged population [4]. When spontaneous, they are suspected to be either genetic or environmental related although no consistently proven cause has been found [4]. Vertebral artery dissections may be spontaneous or traumatic. If traumatic, they are commonly associated with head, neck and cervical spine injuries [5]. If left undetected or untreated they can potentially lead to significant infarction [6].

2. Case report

A 19 year-old male who jumped off a bridge and was subsequently hit by a passing car presented as a polytrauma call to

our hospital. His Glasgow Coma Scale (GCS) was 3 – E1V1M1 at the scene and he had a tension pneumothorax which was decompressed at the roadside.

He was intubated before arriving in the emergency department. His CT Head showed a fracture to the right pterion with an associated underlying fracture haematoma. There was no intracranial haemorrhage or contusions to note. His cervical spine was radiologically normal. Additionally he had associated lumbar, pelvic and coccygeal fractures.

Initially he was managed for his low GCS and head injury with an intracranial pressure bolt monitor. His repeat CT Head the next day revealed radiological features of diffuse axonal injury. A week later he was difficult to wean off sedation and a repeat CT Head was undertaken which revealed evidence of new left sided hypodensity of the brain, suggestive of an infarction in an area which did not previously show contusion/pathology.

This made us investigate further and a CT Angiogram of the neck was undertaken (Fig. 1) and subsequently an MRI Head with contrast (Figs. 2 and 3).

3. Discussion

Vertebral artery dissections may be spontaneous or traumatic. If traumatic, they are commonly associated with head, neck and cervical spine injuries [5]. If left undetected or untreated they can potentially lead to significant infarction [6]. Usually the dissection occurs at the time of the traumatic injury, where as in our case presentation it occurred some time after the initial insulting injury.

* Corresponding author at: Department of Neurosurgery, University Hospitals Coventry and Warwickshire, Clifford Bridge Road, Coventry, West Midlands, CV2 2DX, United Kingdom.

E-mail addresses: Vikas.acharya@doctors.org.uk (V. Acharya), drcksuresh@yahoo.com (S. Chandrasekaran), Sujit.nair@nhs.net (S. Nair).

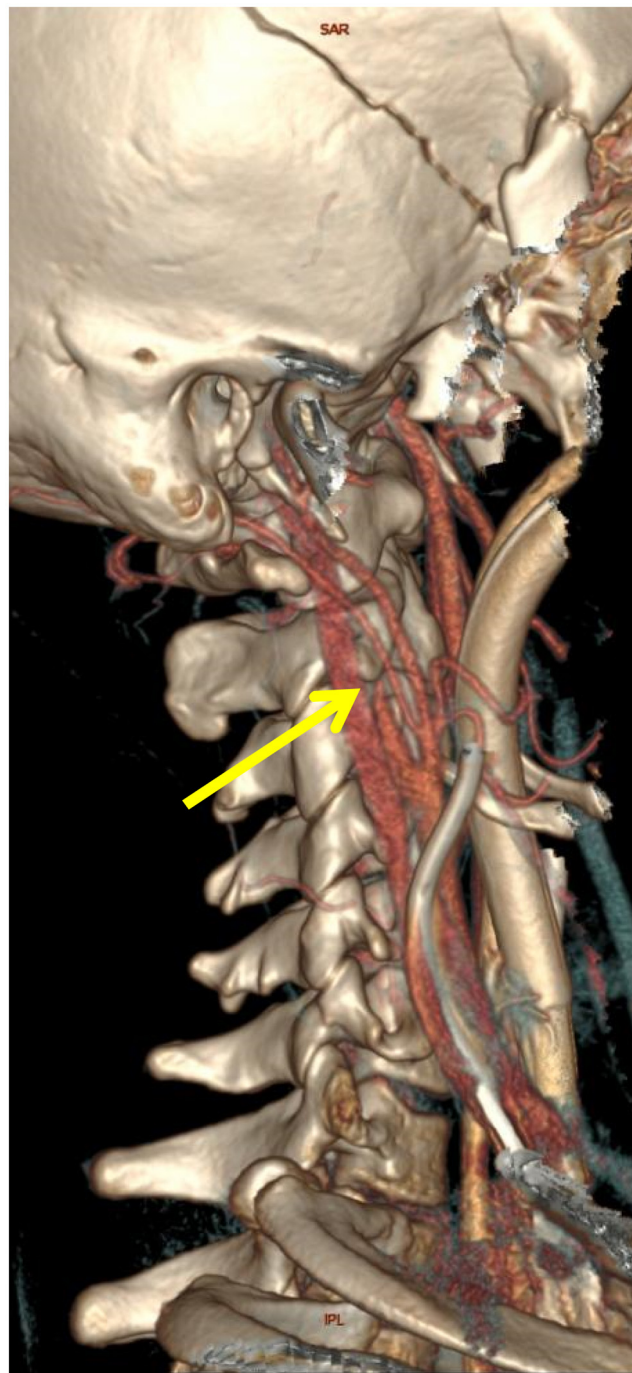


Fig. 1. 3D reformat image of Computed Tomography angiogram of the neck vessels showing gradual tapering of the proximal right internal carotid artery (arrow) and complete occlusion of the internal carotid artery distally indicative of dissection.

There is still controversy over the natural history of these specific dissections [5].

The vascular anatomy is quite consistent and vertebral arteries arise from the subclavian artery on each side and ascend to the base of the skull, uniting to form the single basilar artery [7]. In 70% of the population, the left vertebral artery is dominant and it had been documented that up to 10% may have a unilateral hypoplasia. A dissection can occur at any point in the course of the vertebral artery, but known to most frequently occur in its distal third [7].

The incidence and diagnosis of carotid artery dissection is becoming increasingly more common following polytrauma or localised traumatic injuries but yet routine/regular screening is

not undertaken [8]. It has been documented that the incidence is between 0.5%–2% of all trauma patients [5]. Spinal and trauma literature agree on one common factor, pain is always located on the side of the neck with the dissected carotid or vertebral artery. This is assuming the patient is able to understand and respond to questions asked [8].

Vertebral artery dissection can be clinically challenging to detect and diagnose due to its diverse presentation and the lack of uniform screening/guidelines accepted by any governing body or institution [5]. This was the case in our case report, where the findings were on a follow-up CT scan performed for poor weaning off ventilation, early suspicion was a strong point during the management but

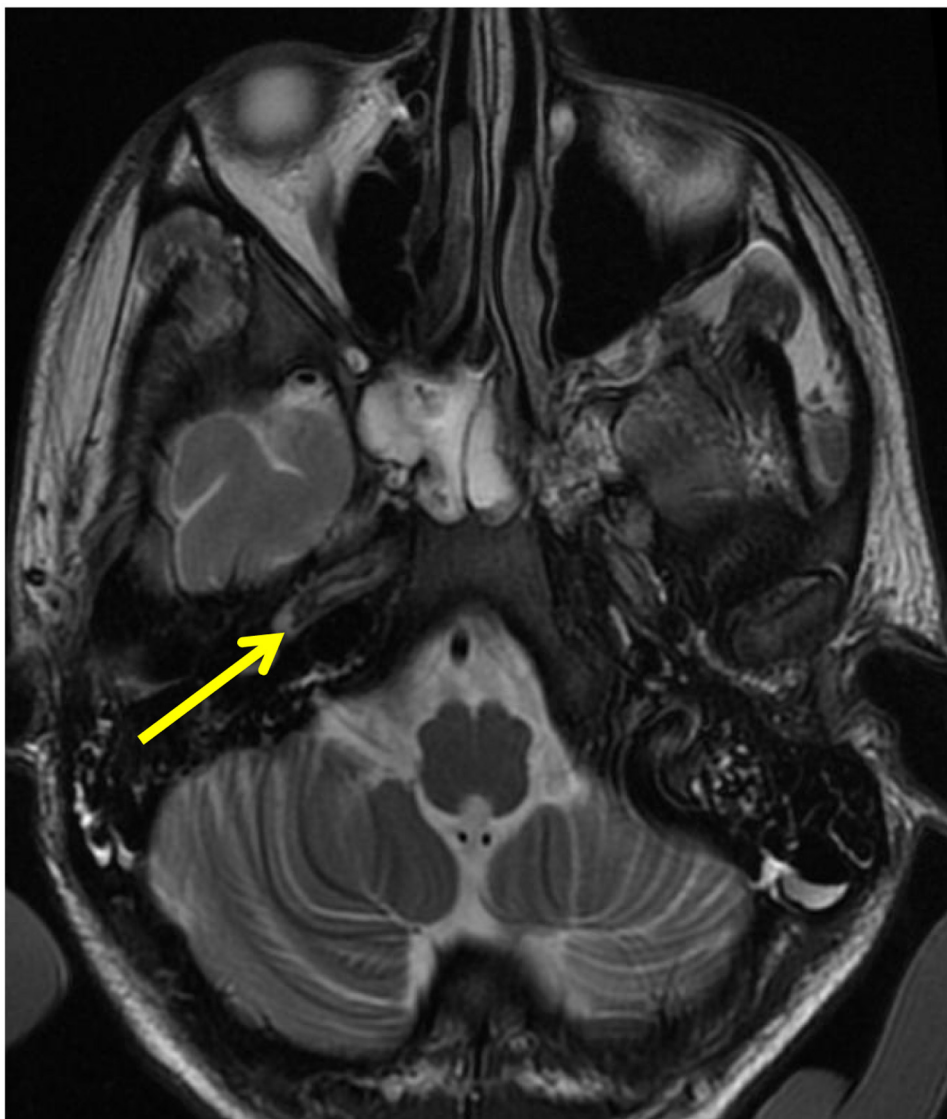

Fig. 2. Axial T2 weighted image of the skull base showing loss of normal flow void (arrow) within the petrous segment of the right internal carotid artery indicative of internal carotid artery occlusion.

one could argue that routine imaging could have been conducted earlier. The pathological process is more common in polytrauma, especially if there are injuries sustained to the head, neck or cervical spine and therefore there needs to be a high index of suspicion in this group of patients. Signs of spinal injury may mimic or disguise the clinical features of vertebral artery dissection and therefore early CT angiogram and/or Doppler and duplex ultrasonography should be used as a non-invasive screening tool in patients with significant traumatic injuries [9]. Early anticoagulation should ideally be the treatment, however, in traumatic injuries it is seldom used. Young age and ischaemic strokes favour better outcomes [10]. This informs and adhered to good clinical practice guidelines.

4. Conclusion

This case report highlights the importance of considering vertebral artery dissection following polytrauma, especially if the patient is sedated secondary to a traumatic head injury. Routine imaging should be considered earlier prior to neurological deficit taking place.

Conflicts of interest

There were no conflicts of interest during the writing or submission of this article.

Funding source

This research did not receive any specific grant from funding agencies in the public, commercial, or not-for-profit sectors.

Ethical approval

Ethical approval was not sought for this case report as it was not required due to the nature of the case report.

Consent

Written informed consent was obtained from the patient for publication of this case report and accompanying images. A copy of the written consent is available for the review of the Editor-in-Chief of this journal on request.

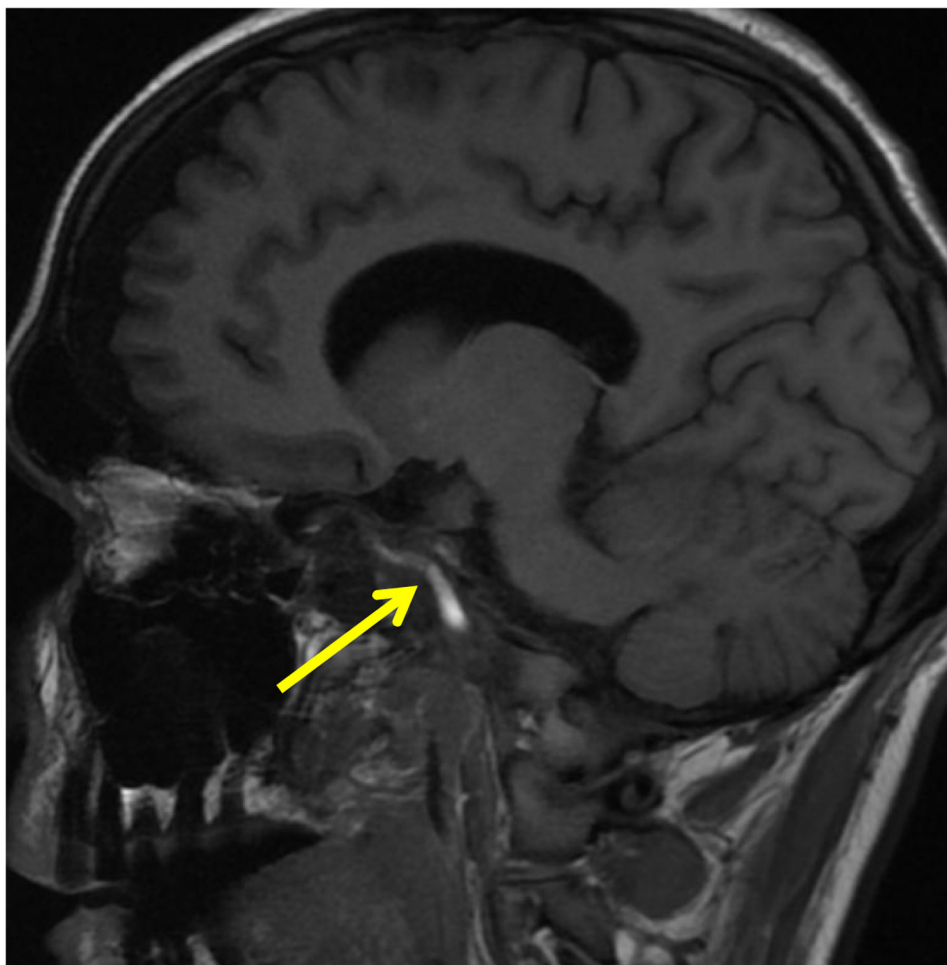

Fig. 3. Sagittal T1 weighted image of the head showing T1 high signal (arrow) suggestive of the periluminal hematoma from the occluded right internal carotid artery.

Authors contributions

All authors were involved in the care of this patient. Additionally, Vikas Acharya and Suresh Chandrasekaran were involved in the writing of the draft manuscript which was reviewed and edited by Sujit Nair. Sujit Nair was additionally involved in the selection of the images and the annotations.

Guarantor

Vikas Acharya BMBS MA MRCS.

References

- [1] R.G. Hart, Vertebral artery dissection, *Neurology* 38 (1988) 987.
- [2] R.G. Hart, V.T. Miller, Cerebral infarction in young adults: a practical approach, *Stroke* 14 (1983) 110–114.
- [3] R.G. Hart, J.D. Easton, Dissections of cervical and cerebral arteries, *Neurol. Clin.* 1 (1983) 155–182.
- [4] W.I. Schievink, The treatment of spontaneous carotid and vertebral artery dissections, *Curr. Opinion in Cardiol.* 15 (2000) 316–321.
- [5] R.M. Desouza, M.J. Crocker, N. Haliasos, A. Rennie, A. Saxena, Blunt traumatic vertebral artery injury: a clinical review, *Eur. Spine J.* 20 (2011) 1405–1416.
- [6] R. Price, R. Sellar, C. Leung, M. O'sullivan, Vertebral arterial dissection and vertebrobasilar arterial thrombosis successfully treated with endovascular thrombolysis and stenting, *AJNR Am. J. Neuroradiol.* 19 (1998) 1677–1680.
- [7] N. Harshavardhana, H. Dabke, Risk factors for vertebral artery injuries in cervical spine trauma, *Orthop. Rev.* 6 (2014) 128–130.
- [8] M. Sturzenegger, The warning symptoms of vertebral artery dissection, *Headache* 34 (1994) 187–193.
- [9] P.D. Schellinger, S. Schwab, D. Krieger, J.B. Fiebach, T. Steiner, E.F. Hund, et al., Masking of vertebral artery dissection by severe trauma to the cervical spine, *Spine* 26 (2001) 314–319.
- [10] M. Arnold, M.G. Bousser, G. Fahrni, U. Fischer, D. Georgiadis, J. Gandjour, et al., Vertebral artery dissection presenting findings and predictors of outcome, *Stroke* 37 (2006) 2499–2503.

Open Access

This article is published Open Access at sciedirect.com. It is distributed under the [IJSCR Supplemental terms and conditions](#), which permits unrestricted non commercial use, distribution, and reproduction in any medium, provided the original authors and source are credited.