

# Percutaneous osteoplasty for the management of a humeral head metastasis

## Two case reports

Guan Shi, MD<sup>a</sup>, Qingshan Liu, MD<sup>b</sup>, Hao Chen, MD<sup>a</sup>, Fei Feng, MD<sup>a</sup>, Pu Jia, MD<sup>a</sup>, Li Bao, MD<sup>a</sup>, Hai Tang, PhD<sup>a,\*</sup>

### Abstract

**Rationale:** Percutaneous osteoplasty (POP) has been proved effective to relieve pain in metastases of vertebral, pelvis, and femur. Nevertheless, there are few reports about the effectiveness of POP in the humeral head metastases. In this study, we described 2 patients with humeral head metastases treated with POP in our hospital.

**Patient concerns:** Case 1 was a 79-year-old man with vertebral and right humeral head metastasis after radical surgery or periods of chemotherapy for bladder cancer. He suffered constant severe back and right shoulder joint pain even if taking much non-steroidal anti-inflammatory drugs. Case 2 was a 59-year-old woman with vertebral and right humeral head metastasis from lung cancer. She received regular radiotherapy and took much painkillers to relieve pain. However, the pain could not be relieved any more after 1 month and severely affects sleeping and daily activities.

**Diagnosis:** Both 2 patients were diagnosed as vertebral metastases and right proximal humeral head metastases.

**Interventions:** POP was performed to treat the right humeral head metastases. Percutaneous vertebroplasty (PVP) was performed to treat vertebral metastases.

**Outcomes:** After surgery, the patients experienced significant decrease in pain and better motor function. Both patients did not suffer from pulmonary embolism, infection, nerve injury, and bone cement syndrome.

**Lessons:** For the pain that cannot be relieved by radiotherapy and analgesic drugs, POP is a safe and beneficial minimally invasive procedure that provides immediate and substantial relief from pain for humerus head metastases.

**Abbreviations:** 18-FDG = 18F-fluorodeoxyglucose, ECG = electrocardiogram, MSTS-93 = Musculoskeletal Tumor Society, PET-CT = positron emission tomography-computed tomography, PKP = percutaneous vertebroplasty, PMMA = polymethylacrylate, POP = percutaneous osteoplasty, PVP = percutaneous vertebroplasty, VAS = visual analogue scale.

**Keywords:** case report, humeral head metastasis, percutaneous osteoplasty

Editor: N/A.

*Patient consent statement: Written consent for publication of the case was obtained.*

*Ethical approval: The study was conducted in accordance with the ethical standards of Medical Ethics Committee of Beijing Friendship Hospital, Capital Medical University, and with the Helsinki Declaration of 1975, as revised in 2000. Informed consents were obtained from the patients for the publication of this study.*

*The authors report no conflicts of interest in this work.*

<sup>a</sup> Department of Orthopedics, Beijing Friendship Hospital, Capital Medical University, Beijing, <sup>b</sup> Department of Orthopedics, The First People's Hospital Of Longquanyi District, Chengdu, China.

\* Correspondence: Hai Tang, Department of Orthopedics, Beijing Friendship Hospital, Capital Medical University No. 95, Yong An Rd, Xi Cheng District Beijing 100050, China (e-mail: tanghai2187@126.com).

Copyright © 2019 the Author(s). Published by Wolters Kluwer Health, Inc. This is an open access article distributed under the terms of the Creative Commons Attribution-Non Commercial-No Derivatives License 4.0 (CCBY-NC-ND), where it is permissible to download and share the work provided it is properly cited. The work cannot be changed in any way or used commercially without permission from the journal.

Medicine (2019) 98:20(e15727)

Received: 12 November 2018 / Received in final form: 4 April 2019 / Accepted: 22 April 2019

<http://dx.doi.org/10.1097/MD.00000000000015727>

## 1. Introduction

The humerus is the second most common site of metastatic bone disease involving long bones.<sup>[1]</sup> Treatment of bone metastases requires multidisciplinary cooperation, including the department of radiotherapy, oncology, and orthopedics. Surgical operation is commonly used as the palliative way to relieve pain and improve the quality of patient's life.

POP is a minimally invasive procedure. It has been verified effective to relieve pain by injecting bone cement to stabilize the pathological fracture. Now, POP has been widely used in treating metastases of vertebral, pelvis, and femur.<sup>[2-5]</sup> Nevertheless, there are few reports about the effectiveness of POP in the humeral head metastases. Therefore, this article mainly aims to report 2 patients with humeral head metastases treated with POP in our hospital. To the best of our knowledge, this is the first report of the use of POP in the humeral head metastases.

## 2. Case reports

### 2.1. Case 1

A 79-year-old man suffered from severe pain in thoracolumbar back and right shoulder joint after the following 4 years of radical surgery for bladder cancer. The right shoulder joint activity was

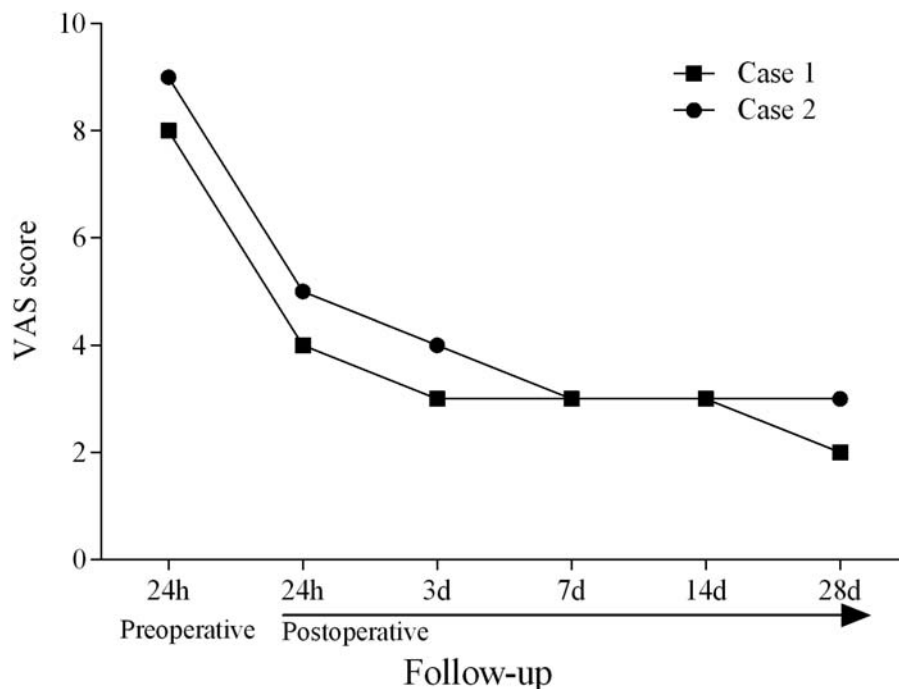
also severely limited. Multiple metastatic bone tumors were diagnosed by bone scan that high metabolism of 18F-fluorodeoxyglucose (18-FDG) in the ninth and tenth thoracic vertebra (T9, T10), and in right proximal humerus. Therefore, the patient received regular radiotherapy to treat metastases and took much opioids to relieve pain. However, the pain could not be relieved any more after 1 month. The unbearable pain severely affects the patient's sleeping and daily activities. Given the patient's short life expectancy and the potential of POP to rapidly relieve pain, we made an individualized treatment strategy. First, percutaneous vertebroplasty (PKP) was performed to treat T9 and T10 osteolytic lesions. Then, POP is performed to the right humeral head metastases. Informed consent about the possible benefits and risks of POP and PKP was signed by the patient and her family.

The procedure was performed under the monitors of electrocardiogram (ECG), pulse oximetry, and non-invasive blood pressure. First, PKP was performed on vertebral metastases (T9, T10). Then, the patient was placed in a prone position to receive POP. The puncture site of the posterolateral skin of the shoulder joint was located by using the C-arm x-ray. Local anesthesia and the puncture site incision were performed after sterilizing the operation area and placing sterile surgical towels. Subsequently, a needle and a working channel (Kyphon, Inc., Minnesota) were slowly punctured into the neck of humerus. The direction of needle in humerus was located and adjusted under the sagittal and axial images of C-arm x-ray to ensure the needle reach the lesion but not pierce the cortical bone of the humerus. Then, the needle was removed and polymethylacrylate (PMMA, Osteopal V, Heraeus Medical, Germany) was slowly injected into the lesion through the working channel under continuous fluoroscopy projection. Once the cement reached the edge of the humeral head, the injection was stopped immediately. A total of about 5 to 9 mL of PMMA was injected.

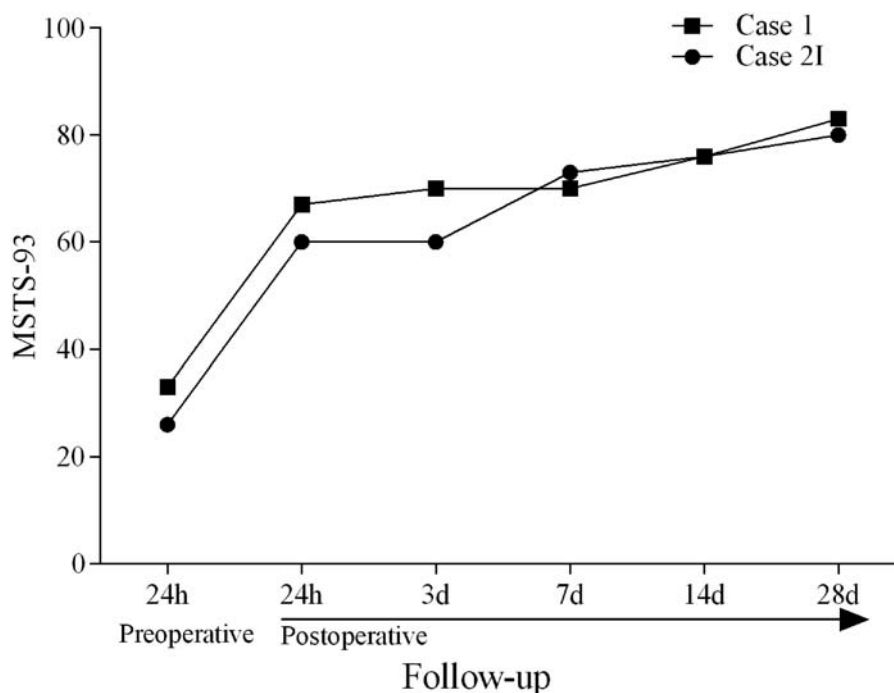
After POP, the patient experienced continuous pain relief and improvement of right upper limb activity without any complications during the operation. At 24 hours after surgery, visual analogue score (VAS) decreased from 9 to 5, and Musculoskeletal Tumor Society (MSTS-93) increased from 26% to 60%. Three days later, VAS decreased to 4, and MSTS-93 was 60%. At 1 week after operation, the patient received further local radiotherapy for humeral head metastases. VAS was evaluated at 3 and MSTS-93 improved to 73%. At 2 weeks after procedure, VAS was stable at 3 and MSTS-93 increased to 76%. At 4 weeks after procedure, VAS was 3, and MSTS-93 of shoulder joint improved to 80%. Details of VAS and MSTS are shown in Figs. 1 and 2, respectively. Preoperative (A, C) and postoperative (B, D) images are showed in Fig. 3. The patient did not suffer from complications such as pulmonary embolism, infection, nerve injury, and bone cement syndrome.

## 2.2. Case 2

A 59-year-old woman suffered from constant severe pain in low back and right shoulder after 4 periods of chemotherapy for advanced lung cancer. Multiple bone metastases was diagnosed according to the high metabolism of 18-FDG in the right humeral head and in the second lumbar vertebral (L2). The patient took much opioids combined with non-steroidal anti-inflammatory drug to relieve pain. However, after 1 month, the patient developed a serious gastrointestinal adverse reaction. Combined with the patient's short life expectancy and the potential of POP to rapidly relieve pain, we developed an individual treatment plan. First, percutaneous vertebroplasty (PVP) was performed to treat L2 osteolytic lesions. Then, POP is performed to treat the right humeral head metastases. Informed consent about the possible benefits and risks of POP and PVP was signed by the patient and her family.



**Figure 1.** Visual analogue score (VAS). Both patients experienced significant pain relief.



**Figure 2.** Musculoskeletal tumor society (MSTS-93). The patients' activity of right upper limb improved significantly.

The patient received the same process of POP in right humeral head as Case 1 and PVP in L2 osteolytic lesions.

The patient did not present any complications during the operation and after surgery. During the follow-up, the patient experienced significant pain relief and improvement of right upper limb activity. At 24 hours after surgery, the patient's VAS decreased from preoperative 8 to postoperative 4. MSTS-93 improved from 33% to 67%. Three days later, VAS decreased to 3, and MSTS-93 increased to 70%. One week after the operation, VAS was stable at 3, and MSTS-93 was 70%. The patient received local radiotherapy for the humeral head metastasis and L2 metastasis in the department of radiotherapy. Two weeks after surgery, VAS was 3 and MSTS-93 improved to 76%. After 4 weeks, VAS decreased from 3 to 2, and MSTS-93 increased to 83%. Details of VAS and MSTS-93 are shown in Figs. 1 and 2. Preoperative (A, C) and postoperative (B, D) images are showed in Fig. 4. The patient did not suffer from complications such as pulmonary embolism, infection, nerve injury, and bone cement syndrome.

### 3. Discussion

Humerus and scapula together formed the most active joint of the whole body, the shoulder joint. The metastases in humerus may cause severe pain that will significantly affect the function of shoulder joint and the patient's quality of life. In addition, osteolytic metastases may cause pathological fracture, which is the most serious complication of humerus metastases and often closely related to poor prognosis.<sup>[6]</sup> Thus, the primary treatment of humerus metastases is to relieve pain and prevent pathological fractures.

The treatments of chemotherapy, immunization therapy and hormone therapy may prolong the lifespan of patients with bone metastases.<sup>[7]</sup> Nevertheless, they cannot correct the instability of

osteolytic bones eroded by metastases and achieve sustained satisfactory effect.

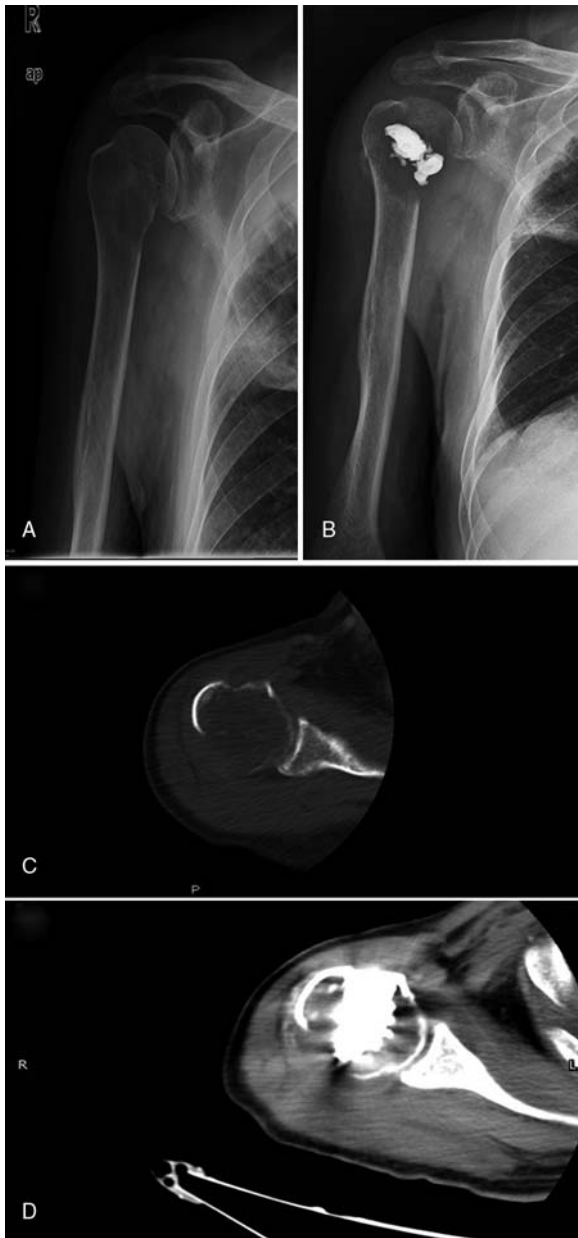
POP has been demonstrated to be potential to quickly relieve pain and increase intraosseous stability in patients with osteolytic lesions. This corrected stability prevents the bones from continuing to deform, which will relieve the stress on the painful periosteum.<sup>[8]</sup>

During the follow-up period, the patients' pain and shoulder function improved significantly. Especially after 2 weeks of surgery, the pain and shoulder function greatly improved in a stabilized situation. Therefore, we believe that POP is an effective treatment and can be used as an alternative method to treat the humeral head metastases. The POP is similar to PVP that involves puncturing a needle into the humeral head and injecting PMMA into the metastatic lesion. A careful analysis of the preoperative images is needed to identify the integrity of the cortical bone of the humeral head in case of bone cement leakage because of negligence.

The humeral head receives blood supply from the anterior and posterior humeral circumflex artery with the arcuate artery originating from the axillary artery. The tendon of the long head of the biceps brachii, originating from the supra-glenoid tubercle, runs between the lesser and greater tubercle. Therefore, caution should be paid not to penetrate the structures when the needle punctured above and outside the humerus to reach the lesion near the neck of the humerus.

The patients in this study received regular radiotherapy and zoledronic acid after surgery. The result of follow-up showed that POP combined with radiotherapy presented a promising effect on the treatment of humeral head metastases.

There are several possible mechanisms of pain relief in osteolytic metastases treated with PMMA. First, PMMA may contribute to the stability of micro-pathological fractures, which will reduce pain stimuli of nerve endings. Second, the toxic effects of PMMA monomers may weaken the ability of nerve endings in

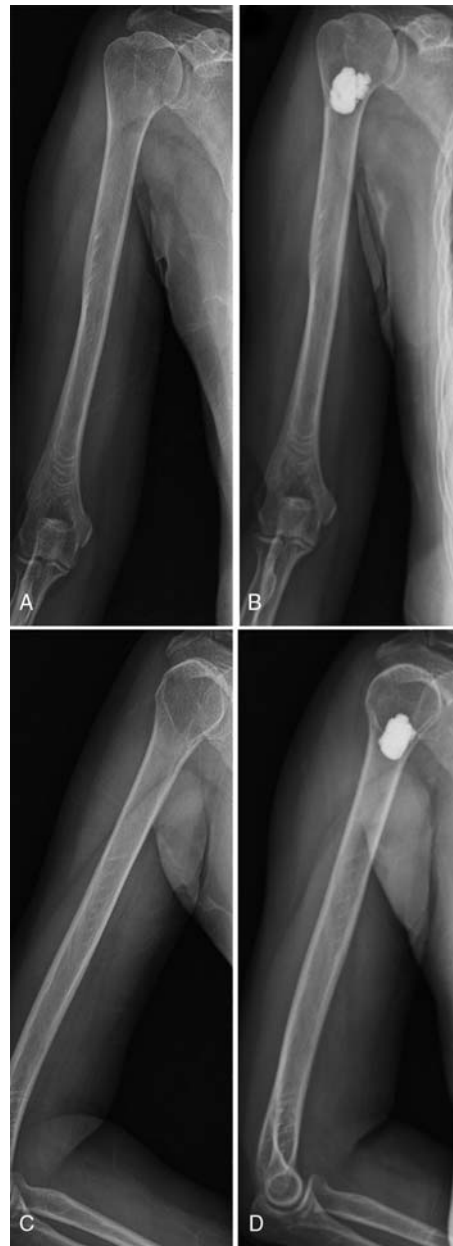

**Figure 3.** Patient I: 79-year-old man with bladder cancer. Preoperative: A and C, postoperative: B and D.

transferring the sense of pain. Third, the exothermic reaction of PMMA polymerization may destroy parts of free nerve endings and block pain sensory.<sup>[9]</sup> Finally, the anti-tumor effect of PMMA may play an important role in the treatment of osteolytic metastases.<sup>[10]</sup>

Although POP achieved satisfactory effect, this is the only one report that describes it for the treatment of humeral head metastasis. Therefore, it is necessary to conduct a large sample of studies to further validate the efficacy and to identify the surgical indications and related complications.

In conclusion, POP is a safe and beneficial minimally invasive procedure that provides immediate and substantial pain relief for patients with humerus head metastases.



**Figure 4.** Patient II: 59-year-old woman with advanced lung cancer. Preoperative: A and C, postoperative: B and D.

### Author contributions

**Investigation:** Guan Shi.

**Resources:** Qingshan Liu, Hao Chen, Fei Feng, Pu Jia, Li Bao.

**Data curation:** Guan Shi, Qingshan Liu.

**Formal analysis:** Guan Shi, Hao Chen, Fei Feng, Pu Jia.

**Writing – original draft:** Guan Shi, Li Bao.

**Writing – review & editing:** Hai Tang.

### References

- [1] Schwabe P, Ruppert M, Tsitsilonis S, et al. Surgical management and outcome of skeletal metastatic disease of the humerus. *Acta Chir Orthop Traumatol Cech* 2014;81:365–70.

- [2] Barragan-Campos HM, LeFaou AL, Rose M, et al. Percutaneous vertebroplasty in vertebral metastases from breast cancer: interest in terms of pain relief and quality of life. *Interv Neuroradiol* 2014;20:591–602.
- [3] Frey ME, Warner C, Thomas SM, et al. Sacroplasty: a ten-year analysis of prospective patients treated with percutaneous sacroplasty: literature review and technical considerations. *Pain Physician* 2017;20: E1063–72.
- [4] Onate MM, Moser TP. A practical guide for planning pelvic bone percutaneous interventions (biopsy, tumour ablation and cementoplasty). *Insights Imaging* 2018;9:275–85.
- [5] Lei M, Liu Y, Yang S, et al. Percutaneous cementoplasty for painful osteolytic distal femur metastases: a case report. *J Pain Res* 2016;9: 859–63.
- [6] Janssen SJ, Paulino Pereira NR, Meijs TA, et al. Predicting pathological fracture in femoral metastases using a clinical CT scan based algorithm: a case-control study. *J Orthop Sci* 2018;23:394–402.
- [7] Liepe K, Shinto A. From palliative therapy to prolongation of survival: (223)RaCl<sub>2</sub> in the treatment of bone metastases. *Ther Adv Med Oncol* 2016;8:294–304.
- [8] Sebaaly A, Nabhane L, Issa El Khoury F, et al. Vertebral augmentation: state of the art. *Asian Spine J* 2016;10:370–6.
- [9] Winking M, Stahl JP, Oertel M, et al. Treatment of pain from osteoporotic vertebral collapse by percutaneous PMMA vertebroplasty. *Acta Neurochir (Wien)* 2004;146:469–76.
- [10] Belkoff SM, Molloy S. Temperature measurement during polymerization of polymethylmethacrylate cement used for vertebroplasty. *Spine (Phila Pa 1976)* 2003;28:1555–9.