

A case of malpositioned catheter via supraclavicular approach for subclavian vein cannulation: A rare technique revisited

Sir,

Correct positioning of any central venous catheter (CVC) is a prerequisite for its intended use. The approach of insertion, the technique used, body position and anatomical variability of central veins used for access are important determinants for CVC misplacement. Use of Ultrasound (USG), chest radiograph, intravascular electrocardiogram, transesophageal echocardiography (TEE) increases success and safety of central venous cannulation. Computed Tomography (CT) scan, magnetic resonance imaging (MRI) and CT volume rendered technique (VRT) images are more definitive and help to ascertain the correct position of CVC when there is a conflict.^[1]

The point of insertion of the needle in the subclavian vein (SCV) via supraclavicular approach coincides with confluence of deep and superficial veins of the neck. Though rare (1.4%), catheter malposition using this approach have been reported in literature^[2]. Anterior jugular venous system is part of collateral venous system of the neck and may become an alternative route of catheter malposition.^[3,4]

We report an extremely unusual malposition of CVC into left anterior jugular vein (AJV) when CVC was inserted through right side by supraclavicular approach for SCV catheterization. Such a malposition is very unique especially in patients without any deep venous obstruction.

A 60-year-old, 80 kg male patient diagnosed as a case of hepatocellular carcinoma was posted for laparoscopic left liver resection. Routine induction of general anesthesia with positive pressure ventilation was done. Central venous cannulation was planned in right internal jugular vein (IJV). After adequate preparation and positioning, needle was inserted using landmark technique through central approach but even after few attempts and change of operator, venepuncture could not be done. Thereafter we tried to increase IJV engorgement by increasing Trendelenburg tilt and doing venepuncture at end inspiration but were unsuccessful.

Due to unavailability of USG for central venous cannulation, a SCV cannulation was planned using supraclavicular approach. The second operator was well versed with technique

and uses it often as a rescue technique. Clavisternomastoid angle was identified and a 23 G finder needle was inserted aiming slightly upwards and towards the contralateral nipple. The vein was punctured on the first attempt and free flow of venous blood was present, then an 18 G introducer needle was inserted and after aspirating a free flowing venous blood, guidewire was threaded through the needle during which slight resistance was felt. After adequate tissue dilatation a 7 Fr triple lumen catheter (Edward Life sciences, Multi-Med and AMC Thromboshield) was threaded over the guidewire, but again slight resistance was felt during threading of the catheter.

Free flow venous blood could be easily aspirated from all the three lumens and so the catheter was secured at 12 cm on the skin. Usual central venous pressure (CVP) waveform and a CVP of 12 mm of Hg were observed on the monitor.

In the postoperative period a check radiograph was done which showed the catheter looping around at upper border of right sternoclavicular joint to the contralateral side of the neck directed upwards [Figure 1]. For further confirmation CT neck and upper thorax was performed which revealed that catheter entered right AJV and jugular venous arch (JVA) junction, traversed JVA and finally reached left AJV [Figure 2]. To further confirm the course of the catheter we performed VRT on contrast CT scan which showed that catheter first entered through the right external jugular vein (EJV) and right AJV junction, and then from the horizontal component of AJV it entered the JVA and finally reached into left AJV.

Once the malposition was diagnosed the CVC was removed and left IJV was inserted uneventfully.

Supraclavicular approach for SCV catheterization first described by Yoffa in 1965^[5] can be used successfully and relatively safely

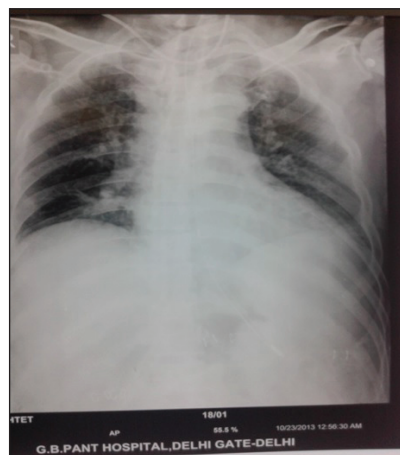


Figure 1: Chest radiograph postero-anterior view showing right side central venous catheter located in suprasternal location along the course of jugular arch and left anterior jugular vein

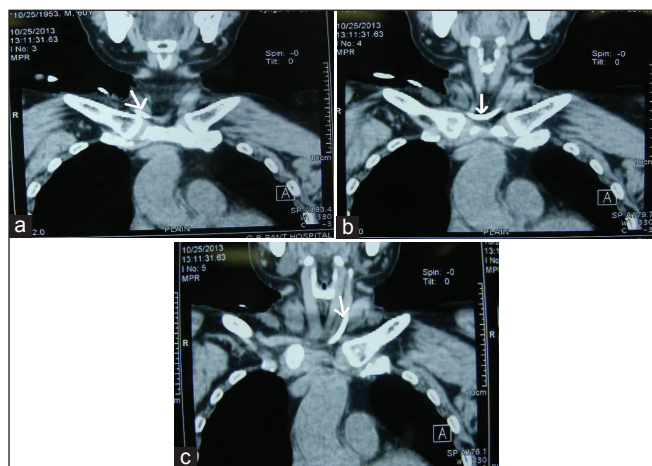


Figure 2: (a) Coronal reconstruction of computed tomography scan of the neck showing central venous catheter entering at the junction of right anterior jugular vein (AJV) (image a) and jugular arch (image b), reaching into left AJV (image c). Labelled by white arrow in each image. (b) Catheter in jugular arch. (c) Catheter in left jugular arch

as a primary or alternative technique. In a review of 178 attempts by Nevarre and Domingo^[6] this technique yielded an overall success rate of 97.8% and complication rate of 0.56%. It was successfully used in patients with failed central lines, hypovolemic shock, and in morbidly obese patients.^[6] The technique used is to identify the clavi-sterno-mastoid angle formed by junction of lateral border of clavicular head of sternocleidomastoid muscle and clavicle, and the needle is inserted 1 cm lateral and superior to this point, directed at a 45° angle towards contralateral nipple, It bisects this angle and enters the jugulo-subclavian junction formed by SCV and IJV.^[7]

The superficial vein of neck EJV also drain in jugulo-subclavian junction in 60% of individuals whereas in 36% it goes into SCV and directly in IJV in 4% case. Another superficial vein, the AJV drains into EJV via a horizontal component in 46% of cases and into SCV in 54% cases. JVA is a communication between two AJVs and lies above the sternum as it crosses the midline of the neck between superficial and pre-tracheal layer of the cervical fascia. These superficial veins serve as collaterals and may become prominent in cases of deep venous outflow obstruction.^[8]

Schummer *et al.*^[4] reported misplaced CVC in JVA while cannulating left IJV reasons for which they hypothesized to be due to unilateral obstruction of the innominate vein with presence of anatomical variation of JVA draining into the innominate vein. Jung and Jee^[3] also reported misplaced CVC into the JVA via subclavian when right supraclavicular approach for SCV cannulation was used in cardiac surgical patient.

In our case no obstruction of neck or thoracic vein was observed in postoperative CT or volume rendered technique (VRT) images.

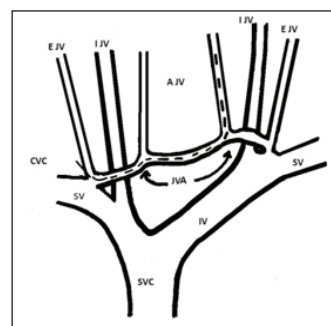


Figure 3: Schematic diagram of the superficial and deep jugular venous system depicting misplacement of the central venous catheter into the jugular venous arch and left anterior jugular vein after venipuncture through right supraclavicular approach for subclavian vein. SV = Subclavian vein; AJV = Anterior jugular vein, EJV = External jugular vein, IJV = Internal jugular vein, IV = Innominate vein, SVC = Superior vena cava

CVC malposition into AJV system usually happens through the horizontal component of AJV, which drains commonly into EJV.^[4] Thus in our case introducer needle inadvertently penetrated right EJV and during threading the guidewire the definite resistance felt means it traversed the horizontal part of right AJV, entered JVA and finally reached into left AJV [Figure 3]. This was confirmed through VRT where the point of entry was seen as right EJV. Once the malposition was diagnosed, the catheter was removed because of inherent risk of thrombosis, endothelial injury, vascular stenosis, catheter wedging or even perforation of the vessel on cannulation of small size vessels.^[5]

Marek^[9] in 40 cardiac surgical patients used USG guided supraclavicular approach for SCV subclavian vein catheterization and observed overall 100% success rate and the first attempt success rate of 92.5%. We could not use it because of unavailability of the equipment.

In this case use of USG, placing the needle more horizontal to the skin, turning the bevel caudad, an early suspicion during advancing the guide wire when resistance was felt and clear knowledge of venous confluence at the site of needle insertion could have prevented the malposition.

**Parin Lalwani, Shiba Aggarwal, Rajeev Uppal,
Somchandra**

Department of Anesthesiology and Intensive Care, Govind Ballabh Pant Hospital, New Delhi, India

Address for correspondence: Dr. Shiba Aggarwal,
House No. 136A, Block M, Vikaspuri,
New Delhi - 110 018, India.
E-mail: shiba.aggarwal@gmail.com

References

- Gibson F, Bodenham A. Misplaced central venous catheters: Applied anatomy and practical management. *Br J Anaesth* 2013;110:333-46.

2. Singh PK, Ali Z, Rath GP, Prabhakar H. Catheter malposition following supraclavicular approach for subclavian vein catheterization — case reports. *Middle East J Anesthesiol* 2008;19:1405-10.
3. Jung TE, Jee D. Misplaced central venous catheter in the jugular venous arch exposed during dissection before sternotomy. *J Clin Anesth* 2008;20:542-5.
4. Schummer W, Schummer C, Bredle D, Fröber R. The anterior jugular venous system: Variability and clinical impact. *Anesth Analg* 2004;99:1625-9.
5. Yoffa D. Supraclavicular subclavian venepuncture and catheterization. *Lancet* 1965;2:614-7.
6. Nevarre DR, Domingo OH. Supraclavicular approach to subclavian catheterization: Review of the literature and results of 178 attempts by the same operator. *J Trauma* 1997;42:305-9.
7. Patrick SP, Tjunelis MA, Johnson S, Herbert ME. Supraclavicular subclavian vein catheterization: The forgotten central line. *West J Emerg Med* 2009;10:110-4.
8. Panagouli E, Tsaraklis A, Gazouli I, Venieratos D. An unusual termination of seven veins in the jugulo-subclavian junction. *Int J Morphol* 2009; 27:1257-60.
9. Marek T. Real-time in-plane ultrasound-guided supraclavicular approach to subclavian vein cannulation in cardiac surgery: An underused approach. *Egypt J Anaesth* 2014; 30:175-80.

Access this article online	
Quick Response Code:	Website: www.joacp.org
	DOI: 10.4103/0970-9185.175720