

Available online at www.sciencedirect.com

ScienceDirect

journal homepage: www.elsevier.com/locate/radcr

Case Report

Unique coexistence of chronic midgut malrotation, mesenteric cyst, and pancreas divisum in a Crohn's disease patient: MR-enterography assessment^{☆,☆☆}

Giuseppe Cicero, MD, PhD, Silvio Mazziotti, MD*

Section of Radiological Sciences, Department of Biomedical Sciences and Morphological and Functional Imaging, University of Messina, Policlinico "G. Martino" Via Consolare Valeria 1, Messina 98100, Italy

ARTICLE INFO

Article history:

Received 2 August 2022

Revised 10 August 2022

Accepted 14 August 2022

Keywords:

Midgut malrotation

Mesenteric cyst

Pancreas divisum

Crohn's disease

Magnetic resonance enterography

ABSTRACT

Chronic midgut malrotation is a rare condition found in the adult age that predisposes to severe complications. It derives from an incomplete rotation of the mesentery around the superior mesenteric artery during embryogenic development. This results in intestinal loops displacement and mesenteric malfixation. Nevertheless, other congenital abnormalities can be also associated, such as mesenteric cysts and biliopancreatic malformations. Imaging modalities employed in the evaluation of chronic midgut malrotation include contrast radiography, which permits to visualize the localization of the intestinal loops, and ultrasound, that can detect a twist of superior mesenteric vessels. Computed tomography is however considered the modality of choice, owing to its wide field of view and the rapid scan times. The role of magnetic resonance imaging in this field has been barely explored. In particular, magnetic resonance enterography has a consolidated role in the assessment of intestinal loops and allows detecting extra-intestinal findings as well. Moreover, the lack of radiation exposure makes this technique suitable for nonemergency cases, especially in young patients. This is the first description of simultaneous chronic midgut malrotation, mesenteric cyst and pancreas divisum discovered in a Crohn's disease patient. The performance of magnetic resonance enterography allowed to properly interpret this multifaceted clinical picture.

© 2022 The Authors. Published by Elsevier Inc. on behalf of University of Washington.

This is an open access article under the CC BY-NC-ND license

(<http://creativecommons.org/licenses/by-nc-nd/4.0/>)

Introduction

Identification of midgut malrotation is rare in the adult population and its recognition is important due to the possible severe complications.

Intestinal malrotation is caused by a partial or complete failure in the rotation of mesentery and bowel along the axis of the superior mesenteric artery during gestational development, with a final abnormal location of duodenojejunal junction and shortening of the mesenteric root [1].

[☆] Competing Interests: The authors declare that they did not receive any funding for this work and they have no conflict of interest.

^{☆☆} IRB approval was not necessary for this study at our institution.

* Corresponding author.

E-mail address: smazziotti@unime.it (S. Mazziotti).

<https://doi.org/10.1016/j.radcr.2022.08.045>

1930-0433/© 2022 The Authors. Published by Elsevier Inc. on behalf of University of Washington. This is an open access article under the CC BY-NC-ND license (<http://creativecommons.org/licenses/by-nc-nd/4.0/>)

This results in higher mobility of the bowel whose possible consequences embrace volvulus, bowel ischemia, obstruction due to internal hernia, intussusception or Ladd's bands presence [2].

Up to 90% of cases of intestinal malrotation are discovered in the first year of life due to volvulus superimposition.

On the other hand, chronic intestinal malrotation in adult patients, although extremely rare, can be identified at any age and it is characterized by subtle symptoms mainly represented by sporadic abdominal pain, nausea and vomiting [2,3].

It can also be associated to coexistent congenital abnormalities including pancreatic anomalies and mesenteric cysts, that are usually discovered as incidental findings at cross-sectional imaging, especially computed tomography (CT) and ultrasound (US) [1,2,4].

The role of magnetic resonance imaging (MRI) for chronic intestinal malrotation has been poorly described so far [2].

Magnetic resonance enterography (MRE) is a technique conceived for the assessment of intestinal loops and its performance is well established in the radiological work-up of Crohn's disease patients.

Nevertheless, the MRE protocol, mainly based on T2-weighted sequences, allows to recognize fluid structures such as mesenteric cysts or pancreatic ducts [5,6].

This work reports the case of a patient suffering from Crohn's disease with a left colon involvement in whom chronic midgut malrotation, mesenteric cyst and pancreas divisum were also identified. For the first time, all these pathologic conditions have been concurrently described. Moreover, this is the first report describing their assessment through the performance of MRE.

Case report

A 44-year-old female patient affected by Crohn's disease underwent MRE scheduled as a routine control.

The patient was in good health, only reporting few episodes of abdominal discomfort with diarrhea during the previous months.

After prior administration of 1500 mL of polyethylene glycol (PEG) water solution, MRE was obtained using a 1.5 T MR imaging system (Gyrosan Achieva, Philips, Best, the Netherlands) and phased-array abdominal coils. The protocol included: coronal and axial true fast imaging with steady-state (True-Fisp; TR/TE: 4.20/2.10 ms, FA: 60°); coronal and axial half-Fourier acquisition single-shot turbo spin echo (HASTE; TR/TE: ∞/80 ms) with and without fat-suppression; axial diffusion-weighted (DWI) sequences at 0, 400, and 800 s/mm² b-values.

At MRE, an adequate filling of the large bowel was achieved and this yielded in identifying a concentric mural thickening of the splenic flexure of the large bowel, extending for 7 cm approximately and characterized by hyperintensity on DWI at 800 s/mm² b-value due to active inflammation. The ileum was instead unremarkable for Crohn's disease lesions.

At the same time, displacement of jejunal loops within the upper right quadrant was noticed.

By the contrary, the ileal loops as well as the ileocecal valve and the large bowel appeared on their normal con-

figuration. These findings configure a partial chronic midgut malrotation.

According to Stringer's classification, mesenteric malrotations can be classified into three main types: nonrotation, duodenal malrotation and combined duodenal and cecal malrotation [7].

However, a higher number of variants have been found on CT-scan by Xiong et al. [8] and, on the basis of their outcomes, the configuration of the present case can be classified as a 4a type.

Moreover, a uniloculated, round-shaped, fluid-filled lesion was detected within the left side of the mesogastric region, compatible with a mesenteric cyst (Fig. 1).

Finally, a main dorsal pancreatic duct draining into the minor papilla was detected, a finding referable to a "pancreas divisum" condition (Fig. 2).

The patient was already undergone a previous MRE (6 years earlier) which similarly showed the midgut malrotation, but was unremarkable for intestinal Crohn's disease lesions. At that time, the mesenteric cyst was appreciable within the right flank (Fig. 3).

The treatment in case of symptomatic malrotation and mesenteric cysts is represented by surgical intervention.

If the latter can be handled by a simple excision, the former is usually approached with a Ladd's procedure, which consist in intestinal repositioning, excision of Ladd's bands and appendectomy [3,9].

In our case, the patient is also affected by colonic Crohn's disease, a condition that could lead to surgical intervention in the future. Since the symptoms were poor and stable over the years, it was decided for a watchful waiting approach.

Discussion

Malrotation is caused by a complete or partial failure in intestinal positioning during embryonic development with consequent anomalous peritoneal fixation [2,10].

At the fourth to fifth week of gestation the gut begins to rapidly develops with external herniation of a large part of the primitive intestine into the stalk of the yolk sac.

Meanwhile, the duodenum starts to curves, with a counter-clockwise turn, along the right side of the superior mesenteric artery, performing an initial 90° rotation and a following 180° rotation by the end of the 8th-10th week. At the 10th-12th, the intestinal tract returns to the abdomen and the ultimate indentation of the cecum yields the duodenum completing its rotation (270°) and achieving its final position (Fig. 4).

Fixation of the intestinal segments occurs within the fourth and the fifth months postconception [4,9,11].

Absent or partial midgut rotation can lead to different scenarios that are mainly defined as: nonrotation, incomplete rotation, reverse rotation, anomalous fixation of the mesentery [4,10,12].

Nevertheless, Xiong et al. have described ten variants of asymptomatic malrotations in adult patients on the basis of duodenum, jejunum, and cecum localization at CT scan [8].

Malrotation is a rarely diagnosed in the adult age (0.2%-0.5%) and it is usually associated to vague and non-specific

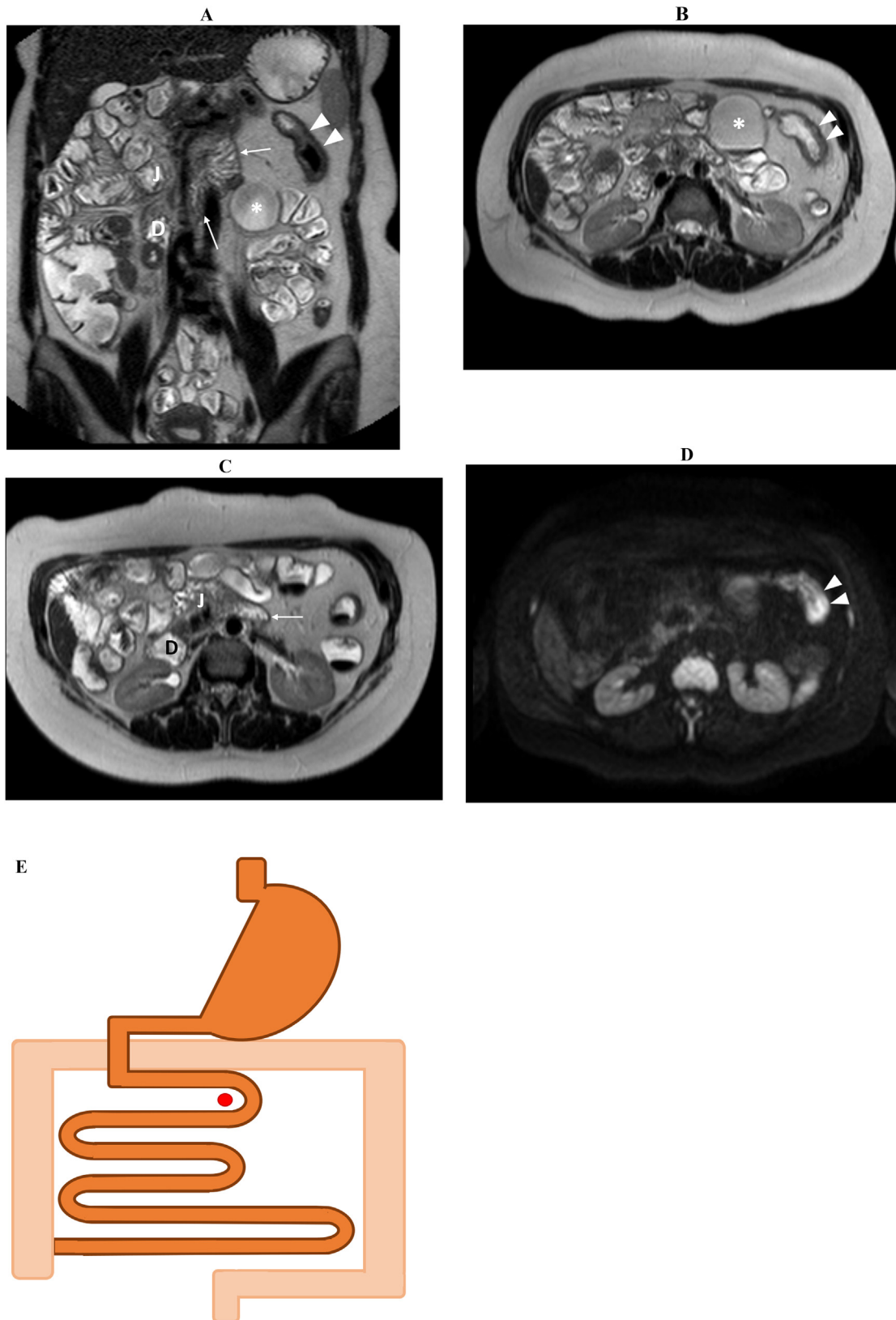


Fig. 1 – Coronal (A) and axial (B, C) T2-w HASTE scans show a Crohn's disease lesion consisting in a mild mural thickening within the splenic flexure of the large bowel (arrowheads). Active inflammation is proved by hyperintensity at axial DWI at 800 s/mm^2 (D). Figures A, B, and C also demonstrate a right displacement of jejunal loops (J). Duodenojejunal junction is pointed by the arrows. Moreover, a fluid-filled mesenteric cyst is visualized on the left side of the central abdomen (asterisk). Graphical drawing that exemplifies the final intestinal configuration (E). D: duodenum. Red dot: superior mesenteric artery.

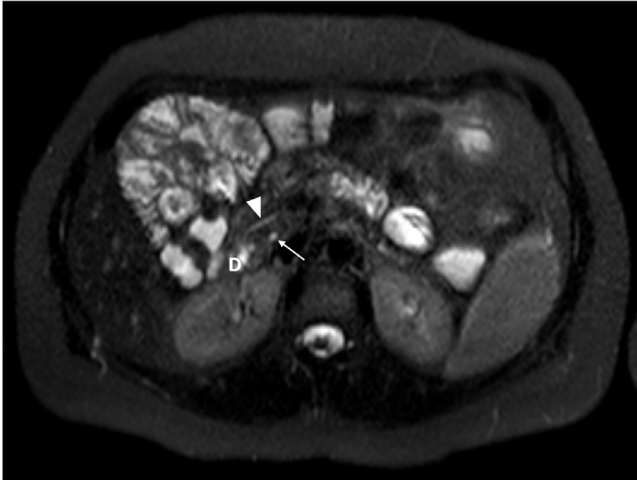


Fig. 2 – Axial T2-w HASTE image with fat-saturation displays the main dorsal pancreatic duct (arrowhead) and the choledocus (arrow) separately draining into the duodenum (D) and thus configuring a “pancreas divisum” condition.

symptoms (ie, abdominal pain, nausea and vomiting, diarrhea or constipation, etc.) and it is usually reported as an incidental finding at radiological work-up [2].

From the radiological point of view, barium follow through (BFT) allows detecting the progression of the oral contrast medium and filling of jejunal loops, which should be positioned within the upper left abdominal quadrant [4,10].

Contrast enema may also show the position of the cecum [10].

Color Doppler ultrasonography is helpful in assessing the relationship between the superior mesenteric vessels which can have abnormal appearance (ie, rotated or vertical) even in nonsymptomatic patients with malrotation [3,4,10].

Finally, CT scan is able in providing an exhaustive evaluation of the abdominal cavity, including intestinal loop positioning and vascular anatomy [3,10].

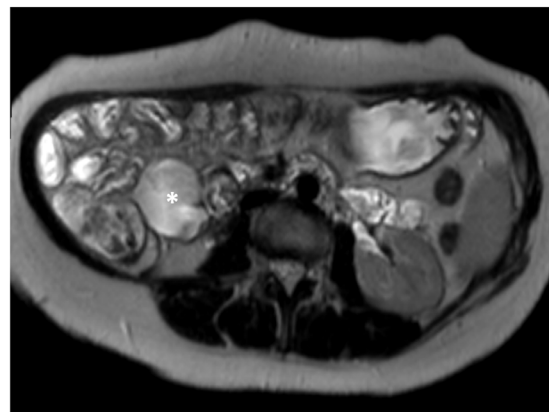
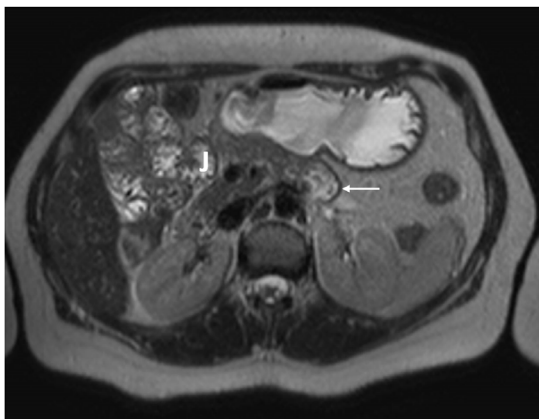


Fig. 3 – At a previous MRE, performed 6 years earlier, axial T2-w HASTE (A) confirmed the right dislocation of the jejunum (J). The duodenojejunal junction is pointed by the arrow. By the contrary, the mesenteric cyst was positioned within the right flank (asterisk).

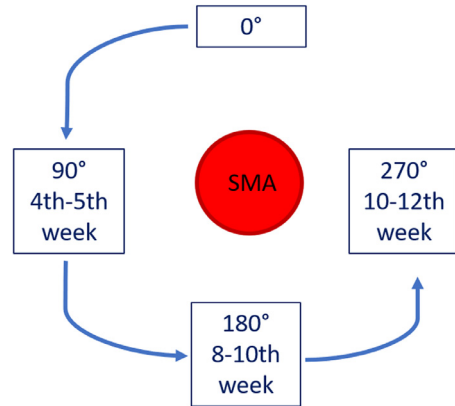


Fig. 4 – Graphical drawing summarizing the normal steps of midgut rotation during gestational development. SMA, superior mesenteric artery.

CT scan, due to the rapid scan times, is particularly indicated in emergency cases, for example, due to volvulus occurrence. The intestinal assessment can be further improved by obtaining a CT enterography through the administration of an oral contrast medium.

Up to now, the role of MRI in evaluating chronic intestinal malrotation has been poorly described.

In particular, MRE has an established role in the evaluation of Crohn’s disease patients although it is gaining increasing attention for the assessment of other intestinal conditions [13].

MRE is provided with higher soft-tissue resolution than CT and it is not burdened by radiation delivery, which makes its use suitable in young subjects or in patients with a not yet defined clinical picture.

Intestinal malrotation can be associated to coexistent congenital abnormalities, including mesenteric cyst and anomalies of the biliopancreatic system [2,4,14,15].

Mesenteric cysts are intra-abdominal, fluid-filled, unilocular, or multiseptated masses that can be detected along any tract of the gut, especially within the small-bowel mesentery.

Among the underlying causes of their origin, traumas, infections and lymphatic malformation are reported, with the latter considered as the most common.

They can be symptomatic when causing obstruction, due to extrinsic compression or volvulus induction, or when rupture occurs [15–17].

Contrast radiography may show displacement of bowel loops, while US and CT can provide detailed information about localization, volume and relationship with the surrounding structures.

Also in this case, MRI can rely on different sequences in order to further characterize the content on the basis of the signal intensity [2,4,16].

Mesenteric cysts fall within the differential diagnosis with enteric duplication cysts, peritoneal inclusion cyst, and pancreatic pseudocyst.

In the case described, although a clear distinction is challenging at radiological imaging and surgical excision with histological correlation was not performed, it can be assumed that the wide mobility of the cyst between the 2 MREs, the lack of prior surgical interventions and of pancreatitis episodes respectively exclude the prementioned hypothesis.

Pancreatic dysmorphisms, such as pancreas divisum, can also be included in the clinical picture of intestinal malrotation [18,19].

Pancreas divisum arises from a failed merging of ventral and dorsal pancreatic buds resulting in a separate emptying of the respective ducts: major papilla for the ventral Wirsung duct, minor papilla for the main dorsal pancreatic duct [20].

Minor papilla may be however insufficient in draining the majority of pancreatic parenchyma thus predisposing to the onset of pancreatitis.

Although MRE is not specific for the assessment of biliopancreatic ducts, the field of view usually covers the upper abdominal organs and the T2-weighted sequences included in the protocol are fluid-sensitive. Therefore, MRE was capable in detecting an anomalous drainage of the main pancreatic duct into the minor papilla.

Conclusions

MRE is a versatile imaging modality that allows an accurate assessment of intestinal loops in different clinical conditions.

In the case presented, bowel Crohn's disease lesion, midgut malrotation, mesenteric cyst and pancreas divisum have been simultaneously detected and characterized at a single time and without any radiation delivery.

On the other hand, MRE provides a high number of information, even beyond the bowel walls, which has to be carefully analyzed by the radiologist in order to achieve the right diagnosis and guide the following management.

Chronic midgut malrotation as well as the associated congenital anomalies should not be underestimated at radiological imaging not only for defining clinically indeterminate intestinal symptoms, but above all because they predispose to more severe and life-threatening complications.

This work was in accordance with the ethical standards of the institutional and/or national research committee and

with the 1964 Helsinki Declaration and its later amendments or comparable ethical standards.

Patient consent

Informed consent was obtained from the patient.

REFERENCES

- [1] Bektasoglu HK, Idiz UO, Hasbahceci M, Yardimci E, Firat YD, Karatepe O, et al. Midgut malrotation causing intermittent intestinal obstruction in a young adult. *Case Rep Surg* 2014;2014:758032. doi:10.1155/2014/758032.
- [2] Neville JJ, Gallagher J, Mitra A, Sheth H. Adult presentations of congenital midgut malrotation: a systematic review. *World J Surg* 2020;44(6):1771–8 PMID: 32030442. doi:10.1007/s00268-020-05403-7.
- [3] Neville JJ, Sharma E, Al-Muzrakchi A, Sheth H. Congenital intestinal malrotation presenting in octogenarians: a report of two cases. *Ann R Coll Surg Engl* 2020;102(1):e12–14. doi:10.1308/rcsann.2019.0169.
- [4] Langer JC. Intestinal rotation abnormalities and midgut volvulus. *Surg Clin North Am* 2017;97(1):147–59. doi:10.1016/j.suc.2016.08.011.
- [5] Cicero G, Mazziotti S. Crohn's disease at radiological imaging: focus on techniques and intestinal tract. *Intest Res* 2021;19(4):365–78. doi:10.5217/ir.2020.00097.
- [6] Cicero G, Ascenti G, Bottari A, Catanzariti F, Blandino A, Mazziotti S. MR enterography: what is next after Crohn's disease? *Jpn J Radiol* 2019;37(7):511–17. doi:10.1007/s11604-019-00838-y.
- [7] Stringer DA, Babyn PS. *Pediatric gastrointestinal imaging and intervention*. 2nd ed. Hamilton, ON, Canada: B.C. Decker; 2000.
- [8] Xiong Z, Shen Y, Morelli JN, Li Z, Hu X, Hu D. CT facilitates improved diagnosis of adult intestinal malrotation: a 7-year retrospective study based on 332 cases. *Insights Imaging* 2021;12(1):58. doi:10.1186/s13244-021-00999-3.
- [9] Kotobi H, Tan V, Lefèvre J, Duramé F, Audry G, Parc Y. Total midgut volvulus in adults with intestinal malrotation. Report of eleven patients. *J Visc Surg* 2017;154(3):175–83. doi:10.1016/j.jviscsurg.2016.06.010.
- [10] Pickhardt PJ, Bhalla S. Intestinal malrotation in adolescents and adults: spectrum of clinical and imaging features. *AJR Am J Roentgenol* 2002;179(6):1429–35. doi:10.2214/ajr.179.6.1791429.
- [11] Sotiropoulou M. *Intestinal malrotation. Pathology of the gastrointestinal tract. Encyclopedia of pathology*. Carneiro F, Chaves P, Ensari A, editors. Cham: Springer; 2017.
- [12] Ben Ely A, Gorelik N, Cohen-Sivan Y, Zissin R, Carpineta L, Osadchy A, et al. Appendicitis in adults with incidental midgut malrotation: CT findings. *Clin Radiol* 2013;68(12):1212–19. doi:10.1016/j.crad.2013.07.001.
- [13] Cicero G, Blandino A, D'Angelo T, Booz C, Vogl TJ, Ascenti G, et al. Mimicking conditions of intestinal Crohn's disease: magnetic resonance enterography findings. *Jpn J Radiol* 2022;40(1):19–28. doi:10.1007/s11604-021-01177-7.
- [14] Yang B, Chen WH, Zhang XF, Luo ZR. Adult midgut malrotation: multi-detector computed tomography (MDCT) findings of 14 cases. *Jpn J Radiol* 2013;31(5):328–35. doi:10.1007/s11604-013-0194-8.
- [15] Pai PK, Gudmundsdottir H, Hull NC, Thacker PG, Klinkner DB. Chylolymphatic mesenteric cyst with midgut volvulus in an

- adolescent: a peculiar presentation. *Radiol Case Rep* 2021;17(2):420–2. doi:[10.1016/j.radcr.2021.10.066](https://doi.org/10.1016/j.radcr.2021.10.066).
- [16] Esen K, Özgür A, Karaman Y, Taşkınlar H, Duce MN, Demir Apaydın F, et al. Abdominal nonparenchymatous cystic lesions and their mimics in children. *Jpn J Radiol* 2014;32(11):623–9. doi:[10.1007/s11604-014-0355-4](https://doi.org/10.1007/s11604-014-0355-4).
- [17] Dioscoridi L, Perri G, Freschi G. Chylous mesenteric cysts: a rare surgical challenge. *J Surg Case Rep* 2014;2014(3):rju012. doi:[10.1093/jscr/rju012](https://doi.org/10.1093/jscr/rju012).
- [18] Alessandri G, Amodio A, Landoni L, De' Liguori Carino N, Bassi C. Recurrent acute pancreatitis in bowel malrotation. *Eur Rev Med Pharmacol Sci* 2016;20(22):4719–24.
- [19] Nakano H, Okamura K, Nakase I, Tamaki H, Kitamura H, Miyazaki K, et al. Coexistence of pancreas divisum and intestinal malrotation in a patient with cholecystolithiasis—a case report. *Jpn J Surg* 1987;17(3):186–9. doi:[10.1007/BF02470597](https://doi.org/10.1007/BF02470597).
- [20] Borghei P, Sokhandon F, Shirkhoda A, Morgan DE. Anomalies, anatomic variants, and sources of diagnostic pitfalls in pancreatic imaging. *Radiology* 2013;266(1):28–36. doi:[10.1148/radiol.12112469](https://doi.org/10.1148/radiol.12112469).