

Conflicts of interest

None declared.

References

1. Walker SL, Lozewicz S, Sood R, Mann TAN, Campalani E, Hubbard VG. Lupus vulgaris due to *Mycobacterium bovis* bacillus Calmette-Guérin (BCG) at the site of previous BCG vaccination. *Clin Exp Dermatol.* 2009;34:e213–5.
2. Bellet J, Prose N. Skin complications of bacillus Calmette-Guérin immunization. *Current Opin Infect Dis.* 2005;18:97–100.
3. Farsinejad K, Daneshpazhooh M, Sairafi H, Barzegar M, Mortazavizadeh M. Lupus vulgaris at the site of BCG vaccination: report of three cases. *Clin Exp Dermatol.* 2009;34:e167–9.

Nisha V. Parmar *, Amani Al Falasi , Alia Almualla 

Dermatology Centre, Dubai Health Authority, Dubai, United Arab Emirates

* Corresponding author.

E-mail: parmarnish@gmail.com (N.V. Parmar).

Received 4 July 2020; accepted 21 July 2020

Available online 14 July 2021

<https://doi.org/10.1016/j.abd.2020.07.022>

0365-0596/ © 2021 Sociedade Brasileira de Dermatologia.

Published by Elsevier España, S.L.U. This is an open access article under the CC BY license

(<https://creativecommons.org/licenses/by/4.0/>).

Effects of dupilumab in type 1 neurofibromatosis coexisting with severe atopic dermatitis^{☆,☆☆}



Dear Editor,

We report the case of a 30-year-old Caucasian woman with type 1 neurofibromatosis (NF1), who came to medical attention for the recent worsening of a concomitant severe form of atopic dermatitis (AD). The patient presented typical features of NF1: axillary and inguinal freckles, café-au-lait spots, multiple subcutaneous neurofibromas, Lisch nodules, spinal alterations with scoliosis. AD was characterized by a generalized pattern and predominant involvement of the face with eyelid eczema and ectropion (Fig. 1). Eczema area severity index (EASI) score was 30 and dermatology life quality index (DLQI) was 25, corresponding to a severe form of the disease. Due to the inefficacy of previous treatments with systemic steroids and cyclosporine in achieving clinical improvement of atopic dermatitis, the patient started therapy with dupilumab at a standard approved dosage of 600 mg subcutaneously followed by 300 mg every two weeks, according to current guidelines. Four weeks after the initiation of therapy, we observed improvement in the signs and symptoms of AD (EASI 4) (Fig. 2). As a collateral finding, we also observed a reduction in the size and swelling of the neurofibromas (Fig. 3). After 16 weeks, we assessed complete remission of AD and no progression of NF1, in terms of number and size of neurofibromas, with an overall improvement in the quality of life of the patient (DLQI 0). After 18 months of treatment, the cutaneous burden of NF1 remained stable.

In our patient, dupilumab proved to be effective both in the management of severe AD and in neurofibromas, achieving stabilization of the disease at one year. The possible effectiveness of the drug on NF1 may reside in the molecular pathology of neurofibromatosis. Fibroblasts and mast cells are key players in the promotion of tumor growth in the neurofibroma microenvironment, as well as in wound healing and scar formation.^{1,2} As previously reported, the activation of IL-4 and IL-13 pathways in fibroblasts, mediated by JAK/STAT intracellular signaling, leads to excessive collagen production, which is responsible for neurofibroma development.³ In regard to NF1, we hypothesize that anti-IL-4 receptor monoclonal antibody dupilumab may inhibit the growth of neurofibromas, interfering with IL-4 and IL-13 binding to type I and type II receptors expressed on mast cells and fibroblasts. This is consistent with the mechanism of action previously described in AD.⁴ To date, pharmacological treatments for neurofibromas in NF1 are still lacking. Moreover, there is no previous reported evidence of the effect of dupilumab in the treatment of NF1. This is probably also due to the paucity of studies highlighting the association between the two disorders. Indeed, only one study reported the co-existence of concomitant AD in 18% of 227 NF1 patients, but these data are not confirmed by further evidence in the current literature.⁵

Our experience could be helpful in the management of NF1, underlining the beneficial anti-inflammatory effect of this biological drug on the neurocutaneous disease, but we are conscious that pathogenetic studies of cytokine interactions and immune signaling pathways as well as RCTs are needed in order to investigate the use of dupilumab in NF1 treatment.

[☆] How to cite this article: How to cite this article: Chello C, Sernicola A, Paolino G, Grieco T. Effects of dupilumab in type 1 neurofibromatosis coexisting with severe atopic dermatitis. *An Bras Dermatol.* 2021;96:638–40.

^{☆☆} Study conducted at the Dermatology Unit, Sapienza University of Rome, Rome, Italy.

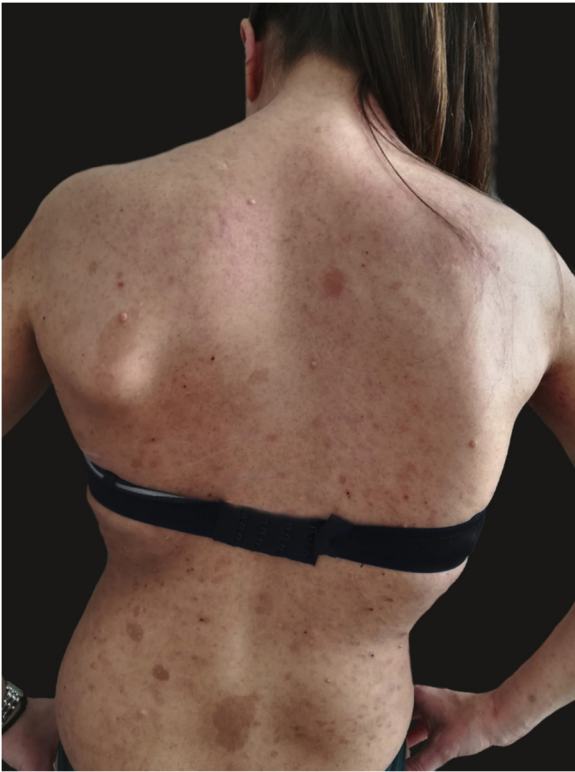

Figure 1 Clinical signs of type 1 neurofibromatosis and atopic dermatitis. Eczematous lesions, with erythema, oozing and crusting, several cafe au lait spots, freckles, cutaneous neurofibromas.

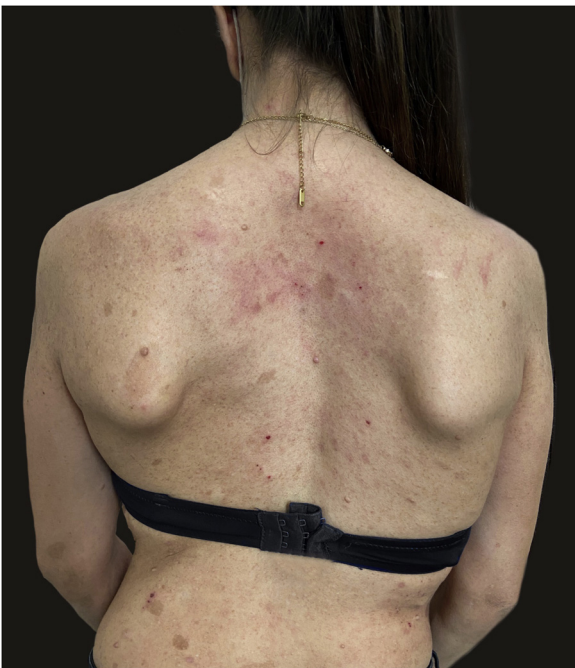

Figure 2 Remission of atopic dermatitis after 4 weeks of treatment with dupilumab. Residual eczematous lesions, as seen on the neck, determined an EASI score of 4.

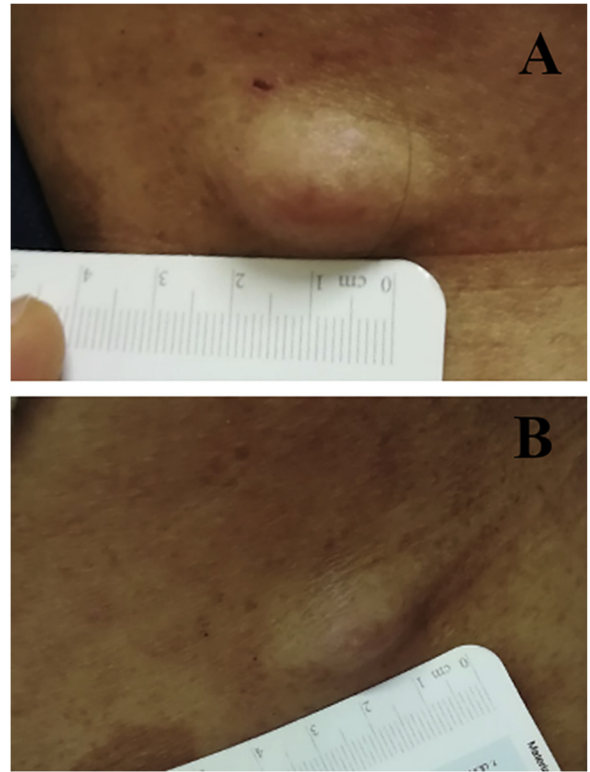


Figure 3 (A), Cutaneous neurofibroma before starting treatment with dupilumab. (B), The same lesion shows evident reduction in swelling and firmness after four weeks of therapy.

Financial support

None declared.

Authors' contributions

Camilla Chello: Study conception and planning; preparation and writing of the manuscript.

Alvise Sernicola: Study conception and planning; preparation and writing of the manuscript.

Giovanni Paolino: Manuscript critical review; preparation and writing of the manuscript.

Teresa Grieco: Study conception and planning; manuscript critical review.

Conflicts of interest

None declared.

References

1. Antonopoulos D, Tsilioni I, Balatsos NAA, Gourgoulianis KI, Theoharides TC. The mast cell – neurofibromatosis connection. *J Biol Regul Homeost Agents*. 2019;33:657–9.
2. Diaz A, Tan K, He H, Xu H, Cueto I, Pavel AB, et al. Keloid lesions show increased IL-4/IL-13 signaling and respond to Th2-targeting dupilumab therapy. *J Eur Acad Dermatol Venereol*. 2020;34:e161–4.

3. Gandhi NA, Bennett BL, Graham NMH, Pirozzi G, Stahl N, Yancopoulos GD. Targeting key proximal drivers of type 2 inflammation in disease. *Nat Rev Drug Discov*. 2016;15:35–50.
4. Gour N, Wills-Karp M. IL-4 and IL-13 signaling in allergic airway disease. *Cytokine*. 2015;75:68–78.
5. Koga M, Koga K, Nakayama J, Imafuku S. Anthropometric characteristics and comorbidities in Japanese patients with neurofibromatosis type 1: A single institutional case-control study. *J Dermatol*. 2014;41:885–9.

Camilla Chello , Alvisè Sernicola ,
Giovanni Paolino , Teresa Grieco *

Dermatology Unit, Sapienza University of Rome, Rome, Italy

*Corresponding author.

E-mail: teresa.grieco@uniroma1.it (T. Grieco).

Received 26 June 2020; accepted 6 October 2020
Available online 16 July 2021

<https://doi.org/10.1016/j.abd.2020.10.006>

0365-0596/ © 2021 Published by Elsevier España, S.L.U. on behalf of Sociedade Brasileira de Dermatologia. This is an open access article under the CC BY license (<https://creativecommons.org/licenses/by/4.0/>).

Infiltrated plaques on the lateral aspects of the hips disclosing a case of adult gluteal granuloma^{☆,☆☆}



Dear Editor,

Adult gluteal granuloma (AGG) is an inflammatory dermatosis that occurs in adults or the elderly on skin exposed to prolonged contact with feces and urine. It presents as well-demarcated areas of erythema, edema, scaling, papules, nodules, erosions, and ulcerations. On histopathological analysis, there is no granuloma, but there is acanthosis, spongiosis, varying degrees of a mixed superficial and deep inflammatory infiltrate, and proliferation of vessels in the dermis.¹ It is a rare condition, with few reports in the literature and it is classically known to occur in children.

An 86-year-old man presented with erythematous, infiltrated, well-defined plaques, with a slightly scaling border and central clearing, asymptomatic, on the lateral aspects of the hips for six months (Figure 1). The patient had a history of diabetes mellitus, radical prostatectomy due to adenocarcinoma, urinary incontinence and recurrent urinary infections. Complementary tests showed glycated hemoglobin of 10.3% and urinary pH of 8.5. Direct mycological examination of the lesion was negative and the histopathological analysis showed acanthosis, spongiosis mainly in the acrosyringial ducts, a discrete perivascular dermal inflammatory infiltrate with lymphocytes, histiocytes, eosinophils, plasmocytes, and red blood cell extravasation (Figure 2). The Grocott stain was negative for fungi. After behavioral measures to keep the diaper area dry and 0.05% fluticasone propionate cream, the lesions disappeared.

Gluteal granuloma is an inflammatory condition, most commonly observed in infancy, in the form of papules

and nodules in the diaper area. Of uncertain etiology, it is believed that a skin reaction occurs to the repeated contact with irritating substances present in feces, urine and cleaning utensils. Infection by *Candida albicans*, occlusion and halogenated corticosteroids are possible pathogenic factors.²

The pH of normal skin is approximately 5.5; while that of urine is around 6 or higher, when there is bacteriuria or infection by urease-producing bacteria, an environment that increases the activity of lipases and proteases, impairs the skin barrier and predisposes to the action of local irritants. Our patient had a urinary pH of 8.5 and bacteriuria, corroborating the findings reported by Isogai et al.³

The distribution of the lesions is related to the patient's position, with nodules located in the scrotum and labia majora of patients who remain seated for a long time, and nodules around the anus in bedridden patients.³ Our patient had the diapers frequently changed during the day and, when sleeping, remained in lateral decubitus, associated with polyuria due to decompensated diabetes, factors that caused the lesions on the lateral aspects of the hips.

Recently, dermoscopic findings have been described in a case of AGG, showing papillae with rounded white areas surrounded by erythema and serrated white borders. These papillae were separated by fissures and contained a whitish mesh, comedo-like openings and dotted vessels under the greatest magnification.⁴

Keeping the skin clean and dry is the main treatment and the best form of prevention. There are individual reports or case series and, in most of them, topical treatments, including corticosteroids, have failed. The use of topical corticosteroids was effective in two patients.⁵

With the aging of the population and the increase in the number of incontinent individuals, we will possibly face this entity more frequently, justifying the importance of learning about it.

☆ How to cite this article: Oliveira AKG, Valente NYS, Cunha TAC, Oppenheimer AR. Infiltrated plaques on the lateral aspects of the hips disclosing a case of adult gluteal granuloma. *An Bras Dermatol*. 2021;96:640–1.

☆☆ Study conducted at the Hospital do Servidor Público Estadual, São Paulo, SP, Brazil.