

Case Report

Coil Extrusion into the Naso- and Oropharynx Ten Years after Internal Carotid Artery Pseudoaneurysm Embolization: A Case Report

Davide Nasi^a Mauro Dobran^a Lucia di Somma^a Alessandro Di Rienzo^a
Maurizio De Nicola^b Maurizio Iacoangeli^a

^aDepartment of Neurosurgery, Università Politecnica delle Marche, Ospedali Riuniti, Ancona, Italy; ^bDepartment of Neuro-Radiology, Università Politecnica delle Marche, Ospedali Riuniti, Ancona, Italy

Keywords

Pseudoaneurysm · Coil extrusion · Embolization · Endoscopic endonasal approach · Internal carotid artery

Abstract

Coil migration and extrusion outside the cranial compartment after embolization of cerebral aneurysms represents a very rare complication of the endovascular procedures and few cases are reported in the literature. Instability of the vascular malformation wall and the resolution of the intramural hematoma, especially in pseudoaneurysm, might generate extravascular migration of the coils in the first months after embolization. However, to the best of our knowledge, an extrusion of coil 10 years after embolization has never been reported. We reported the unique case of a patient with coil extrusion into the naso- and oropharynx 10 years after internal carotid artery pseudoaneurysm embolization. The pseudoaneurysm occurred after an internal carotid artery injury during an endoscopic endonasal surgery for a clival giant cell tumor.

© 2019 The Author(s)
Published by S. Karger AG, Basel

Introduction

Injury to the internal carotid artery (ICA) during endoscopic endonasal approach (EEA) surgery is probably the most feared and catastrophic complication that could happen during an EEA, and control of the surgical field is very challenging [1–5]. Moreover, even if the intraoperative bleeding is controlled, ICA injury may result in the formation of a pseudoaneurysm that can cause delayed bleeding [1, 5]. For this reason, in case of ICA injury during the EEA, after an immediate intraoperative control of the site of bleeding through the packing of the ICA tear with the help of topical hemostatic agents, and once the circulation is stabilized, the patient should undergo ICA angiography to disclose and definitively treat the ICA injury [1, 5–8].

However, endovascular procedures are associated with a wide spectrum of complications, including endovascular coil extrusion and migration, especially in the first 3–12 months after embolization, which could increase the risk of further episodes of bleeding [5–8].

We present a case report with coil extrusion into the naso- and oropharynx 10 years after ICA pseudoaneurysm embolization. The pseudoaneurysm occurred after an ICA injury during an extended endonasal surgery for a clival giant cell tumor [1–4].

To the best of our knowledge, an extrusion of coil 10 years after embolization has never been reported.

Case Report

A 41-year-old male was admitted to our hospital because of progressive pain and discomfort during swallowing. His past medical history was characterized by surgery for clival giant cell tumor complicated by ICA rupture 10 years ago. Indeed, in 2008, the patient was operated on by a fully endoscopic neuronavigation-guided EEA [1–11]. Thanks to the working angle and the better visualization offered by the EEA, we were able to maximize the tumor resection preserving at the same time craniocervical junction stability and avoiding posterior fixation with his relative complications [1–4, 11–15]. Indeed, the lesion was completely removed, but during the drilling of the surrounding healthy bone, there was a little tearing of the left ICA. Local control of the bleeding was challenging, but it was obtained by using topical hemostatic agents and balloon catheter for nasal tamponade. Immediately after surgery, the patient underwent angiography disclosing a pseudoaneurysm originating near the inferior meningohypophyseal trunk, which was successfully treated by embolization with coils (Fig. 1a, b). After 2 days of intensive care unit stay, the patient was transferred to our department, showing no neurological deficit and no signs of CSF leak or other CSF disturbances [16–18]. The nasal tamponade was removed 4 days after surgery, and no bleeding was observed coming out from the nasal cavity. The patient was dismissed and sent home 1 week later. Histologic evaluation of surgical specimens revealed the aspect of a giant cell tumor with no infiltration of the surrounding bone [19].

Radiation therapy was not performed. Brain magnetic resonance imaging with angiographic sequences was done regularly 3, 6, and 12 months after surgery in the first year and every 6 months for a further 2 years, then annually for a further 5 years. All these examinations showed no tumor recurrence or pseudoaneurysm repermeabilization.

For the presence of pain and discomfort during swallowing, the patient was referred to an otorhinolaryngology department, where, during endoscopic examination of the upper airways, a prolapse of the distal tip of the embolization coil wire was detected in the naso- and

oropharynx. Then, after neurosurgical consultation, an urgent CT angiogram was performed which confirmed the extrusion of endovascular coils into the nasal and oropharyngeal cavity (Fig. 1c, d). The pseudoaneurysm was fully thrombosed despite the coil migration. For this reason, under local anesthesia and with the endoscopic technique, the extruded segment was trimmed at the level of its origin in the nasal mucosa. No bleeding, thrombosis or respiratory complications were observed. Endoscopic endonasal office-based control examinations were then performed regularly 1, 3, and 6 months after this event disclosing another coil migration.

Discussion

Laceration of the ICA during endonasal surgery for skull base tumor is a rare complication, but when it happens, it can be potentially fatal [1, 5, 7]. Intraoperative control of bleeding and stabilization of arterial pressure followed by endovascular treatment represents the cornerstone of management of this catastrophic complication [1–8]. Indeed, even if the intraoperative bleeding is controlled, ICA injury may result in the formation of a pseudoaneurysm that can cause delayed bleeding [5–8]. The formation of a pseudoaneurysm after ICA injury is due to the partial resolution of a periarterial hematoma with the development of a fibrinous wall. Then, the continuous pulsatile arterial forces on the fibrinous wall lead to the formation of a sac with globular shape. For this reason, the wall of the pseudoaneurysm, in contrast to a true aneurysm, lacks the media and intima layers and therefore is more fragile with an increasing rupture risk [8].

The development and improvement of new endovascular techniques (balloon occlusion, flow diversion, stent-assisted coiling or coiling alone) has changed the treatment of these complex vascular lesions [5–8].

The most frequently reported complications of coil embolization of pseudoaneurysms are related to thromboembolic events or repermeabilization of the aneurysm [5]. Aneurysm recurrence rates after endovascular treatment range from 15 to 33% [6]. Several studies reported that about 50–55% of these recurrences may be associated with coil extrusion or migration [6].

Several mechanisms have been suggested to explain coil extrusion [5–8]. Some authors reported iatrogenic perforation of the aneurysmal wall during coiling [6]. Another described mechanism is related to the effect of blood flow which compresses the coils against the aneurysmal dome. This phenomenon could lead not only to coil compaction, but could even lead to coil extrusion through a vulnerable site (for example previous rupture sites) or favoring a new tear in the aneurysmal wall [5–8]. In case of pseudoaneurysms, as in our case, after thrombus resorption, the coil complex can be placed adjacent to the external aspect of the vessel which does not present, in contrast to a true aneurysm, the media and intima layers and therefore is more fragile with an increase in coil extrusion [5–8].

The mechanics and process described above usually take time and reflect the fact that aneurysmal repermeabilization caused by extrusion is reported from several months to years after the endovascular coiling procedure [1–20]. However, to the best of our knowledge, an coil extrusion 10 years after embolization has never been reported [1–22].

Sirakov et al. [5] reported a case of intranasal coil extrusion 6 months after endovascular treatment with flow-diverter stenting and coiling for iatrogenic ICA pseudoaneurysm. In this case, pseudoaneurysm originated from the injury of a cavernous segment of the ICA during endonasal transsphenoidal resection of a pituitary adenoma. Another similar case was described by Dedmon et al. [7]. They reported a patient with coil migration into the nasal cavity

2 months after embolization of a cavernous ICA aneurysm. Coil migration was also reported 18 months after embolization of post-traumatic ICA pseudoaneurysm without previous surgery [21].

Moreover, coil herniation in the upper airways was reported in two cases of extracranial iatrogenic ICA pseudoaneurysm after tonsillectomy and glossectomy (respectively 2 years and 3 months after embolization of pseudoaneurysm) [8, 22].

After careful evaluation of the literature, the management of extruded coils must provide a multidisciplinary approach [1–22]. Because extruded coils have the potential to destabilize the prior arterial embolization, CT and/or traditional angiography remain mandatory before excision of the extruded coil wire to check complete aneurysm thrombosis [7]. Then, the extruded coil loop should be treated by trimming at the level of the defect while the embedded portions of coil wire must be left in place for minimizing the risk of possible destabilization of the occlusive matrix [1–22]. Some patients, including our case, were successfully treated under local anesthesia in ENT ambulatory day surgery with the endoscopic technique [5, 8, 20].

In conclusion, we report a unique case of coil extrusion in the nasal and oral cavities 10 years after embolization of iatrogenic ICA aneurysm. This case highlights the possibility that the complications of coil embolization may occur even 10 years after the procedure.

Statement of Ethics

The patient provided informed consent to participate in this paper, which was approved by the institutional review board.

Disclosure Statement

There are no potential conflicts of interest for any of the authors with products or techniques discussed in the paper.

Funding Sources

There are no financial supports or grants to report. There is no funding information to report.

Author Contributions

All authors had access to the data and a role in writing the manuscript; there are no disclaimers.

References

- Iacoangeli M, Di Rienzo A, Re M, Alvaro L, Nocchi N, Gladi M, et al. Endoscopic endonasal approach for the treatment of a large clival giant cell tumor complicated by an intraoperative internal carotid artery rupture. *Cancer Manag Res*. 2013;5:21–4.
- Re M, Iacoangeli M, Di Somma L, Alvaro L, Nasi D, Magliulo G, et al. Endoscopic endonasal approach to the craniocervical junction: the importance of anterior C1 arch preservation or its reconstruction. *Acta Otorhinolaryngol Ital*. 2016 Apr;36(2):107–18.
- Iacoangeli M, Di Rienzo A, Colasanti R, Re M, Nasi D, Nocchi N, et al. Endoscopic Transnasal Odontoidectomy With Anterior C1 Arch Preservation and Anterior Vertebral Column Reconstruction in Patients With Irreducible Bulbomedullary Compression by Complex Craniovertebral Junction Abnormalities: operative Nuance. *Oper Neurosurg (Hagerstown)*. 2016 Sep;12(3):222–30.
- Iacoangeli M, Nasi D, Colasanti R, Pan B, Re M, Di Rienzo A, et al. Endoscopic Endonasal Odontoidectomy with Anterior C1 Arch Preservation in Rheumatoid Arthritis: Long-Term Follow-Up and Further Technical Improvement by Anterior Endoscopic C1-C2 Screw Fixation and Fusion. *World Neurosurg*. 2017 Nov;107:820–29.
- Sirakov S, Panayotova A, Sirakov A, Minkin K, Hristov H. Delayed intranasal coil extrusion after internal carotid artery pseudoaneurysm embolization. *Interv Neuroradiol*. 2018 Oct 9:1591019918805151.
- Aoun SG, Rahme RJ, El Ahmadih TY, Bendok BR, Hunt Batjer H. Incorporation of extruded coils into the third nerve in association with third nerve palsy. *J Clin Neurosci*. 2013 Sep;20(9):1299–302.
- Dedmon M, Meier J, Chambers K, Remenschneider A, Mehta B, Lin D, et al. Delayed endovascular coil extrusion following internal carotid artery embolization. *J Neurol Surg Rep*. 2014 Dec;75(2):e255–8.
- Wiseck Z, Savastano L, Chaudhary N, Pandey AS, Griaudez J, Sankaran S, et al. Delayed extrusion of embolic coils into the airway after embolization of an external carotid artery pseudoaneurysm. *J Neurointerv Surg*. 2018 Jul;10(7):e18.
- Iaccarino C, Romano A, Ramponi V, Nasi D, Maggi M, Pascarella R, et al. Entrapment of temporal horn: first case of bilateral occurrence and review of literature. *Clin Neurol Neurosurg*. 2013 Oct;115(10):2207–12.
- Iaccarino C, Nicoli D, Gallo C, Nasi D, Pisanello A, De Berti G, et al. Analysis of MGMT promoter methylation status on intraoperative fresh tissue section from frameless neuronavigation needle biopsy: a preliminary study of ten patients. *Acta Neurochir (Wien)*. 2010 Jul;152(7):1189–96.
- Iacoangeli M, Nocchi N, Nasi D, Di Rienzo A, Dobran M, Gladi M, et al. Minimally Invasive Supraorbital Key-hole Approach for the Treatment of Anterior Cranial Fossa Meningiomas. *Neurol Med Chir (Tokyo)*. 2016;56(4):180–5.
- Dobran M, Nasi D, Esposito DP, Iacoangeli M. Posterior Fixation with C1 Lateral Mass Screws and C2 Pars Screws for Type II Odontoid Fracture in the Elderly: Long-Term Follow-Up. *World Neurosurg*. 2016 Dec;96:152–8.
- Dobran M, Mancini F, Nasi D, Scerrati M. A case of deep infection after instrumentation in dorsal spinal surgery: the management with antibiotics and negative wound pressure without removal of fixation. *BMJ Case Rep*. 2017 Jul;2017:2017.
- Dobran M, Marini A, Gladi M, Nasi D, Colasanti R, Benigni R, et al. Deep spinal infection in instrumented spinal surgery: diagnostic factors and therapy. *G Chir*. 2017 May-Jun;38(3):124–9.
- Dobran M, Marini A, Nasi D, Gladi M, Liverotti V, Costanza MD, et al. Risk factors of surgical site infections in instrumented spine surgery. *Surg Neurol Int*. 2017 Sep 6;8:212.
- Nasi D, Dobran M, Iacoangeli M, Di Somma L, Gladi M, Scerrati M. Paradoxical Brain Herniation After Decompressive Craniectomy Provoked by Drainage of Subdural Hygroma. *World Neurosurg*. 2016 Jul;91:673.e1–4.
- Nasi D, Dobran M, Di Rienzo A, di Somma L, Gladi M, Moriconi E, et al. Decompressive Craniectomy for Traumatic Brain Injury: The Role of Cranioplasty and Hydrocephalus on Outcome. *World Neurosurg*. 2018 Aug;116:e543–9.
- Nasi D, Gladi M, Di Rienzo A, di Somma L, Moriconi E, Iacoangeli M, Dobran M. Risk factors for post-traumatic hydrocephalus following decompressive craniectomy. *Acta Neurochir (Wien)*. 2018 Sep;160(9):1691–8.
- Nasi D, Somma L, Iacoangeli M, Liverotti V, Zizzi A, Dobran M, et al. Calvarial bone cavernous hemangioma with intradural invasion: an unusual aggressive course-Case report and literature review. *Int J Surg Case Rep*. 2016;22:79–82.
- Nasi D, Iacoangeli M, Di Somma L, Dobran M, Di Rienzo A, Gladi M, et al. Microsurgical endoscopy-assisted anterior corpus callosotomy for drug-resistant epilepsy in an adult unresponsive to vagus nerve stimulation. *Epilepsy Behav Case Rep*. 2016 Jan;5:27–30.
- Singh A, Sikka K, Jain N, Devarajan LJ. Delayed endovascular coil extrusion presenting as a foreign body of the throat: A case report. *Neurointervention*. 2018 Mar;13(1):66–9.
- Jafari A, Nuyen B, Kedarisetty S, Fordham CA, Nation J. Sequential treatment of delayed endovascular coil extrusion from a carotid artery pseudoaneurysm after tonsillectomy. *JAMA Otolaryngol Head Neck Surg*. 2017 Feb;143(2):193–5.

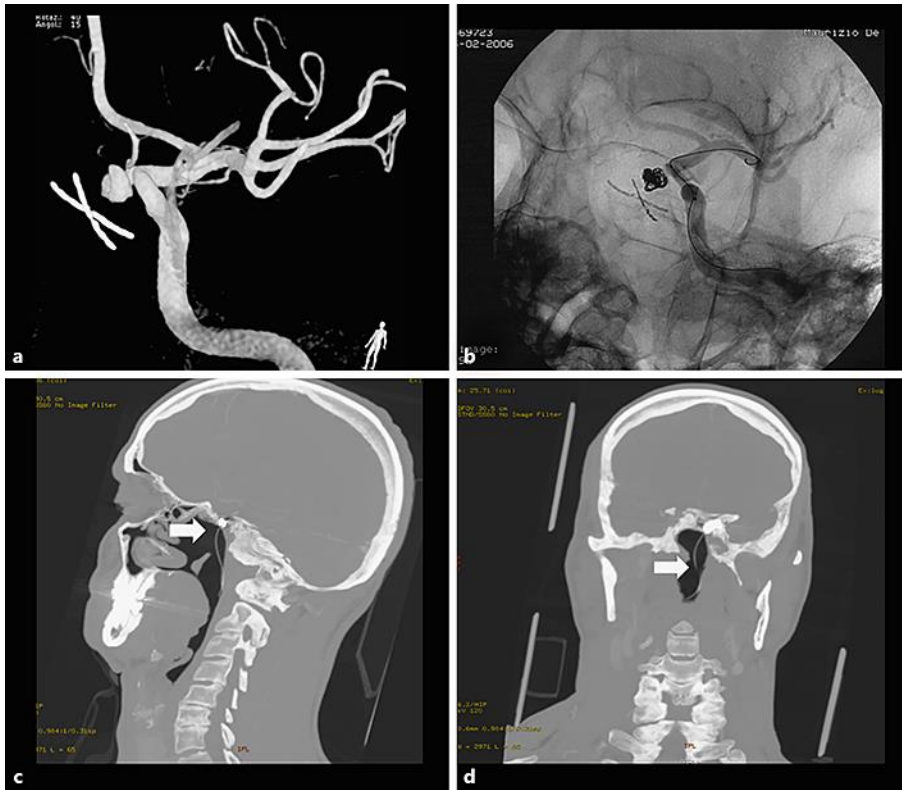


Fig. 1. a, b 3D digital subtraction angiography disclosing a pseudoaneurysm originating near the inferior meningo-hypophyseal trunk (a), which was successfully treated by embolization with coils (b). c, d Sagittal and coronal CT scan images disclosing extrusion of endovascular coils into the nasal and oropharyngeal cavity.