JSES International 7 (2023) 756–762

Contents lists available at ScienceDirect

JSES International

journal homepage: www.jsesinternational.org

What is the most predictive magnetic resonance imaging finding of rotator cuff tear concomitant with shoulder stiffness?

Ji Young Yoon, MD[a], HeeSoo Han, MD[b], Myoung Yeol Shin, MD[a], Hyeon Jang Jeong, MD[b], Yusuhn Kang, MD, PhD[c], Young Dae Jeon, MD[d], Ji Un Kim, MD[e], Joo Han Oh, MD, PhD[b,*]

[a]Department of Orthopaedic Surgery, National Police Hospital, Seoul, Republic of Korea
[b]Department of Orthopaedic Surgery, Seoul National University College of Medicine, Seoul National University Bundang Hospital, Seongnam, Republic of Korea
[c]Department of Radiology, Seoul National University College of Medicine, Seoul National University Bundang Hospital, Seongnam, Republic of Korea
[d]Department of Orthopaedic Surgery, Ulsan University College of Medicine, Ulsan University Hospital, Ulsan, Republic of Korea
[e]Department of Orthopaedic Surgery, Korea University College of Medicine, Korea University Ansan Hospital, Ansan, Republic of Korea

ARTICLE INFO

Keywords:
Adhesive capsulitis
Anterior capsular thickness
Anterior capsular abnormal hyperintensity
Magnetic resonance imaging
Rotator cuff tear
Stiff shoulder

Level of evidence: Level III; Retrospective Case-Control Design; Diagnostic Study

Background: Common magnetic resonance imaging (MRI) findings in adhesive capsulitis are not often evident in rotator cuff tear concomitant with shoulder stiffness. This study aimed to determine the most predictive MRI finding of rotator cuff tear with shoulder stiffness to differentiate from that without stiffness.

Materials and methods: The data of patients who underwent arthroscopic rotator cuff repair between January 2014 and October 2019 were retrospectively reviewed. Stiffness was defined as forward flexion <120°, external rotation at side <30°, and internal rotation at back <L3 in the active range of motion. Propensity score matching (1-to-1) was performed between the stiff and control groups by sex, age, and tear size, and 76 patients per group were matched. Anterior capsular thickness, maximal humeral/glenoid capsular thickness in the axillary recess, coracohumeral ligament thickness, the presence of hyperintensity in the anterior capsule and humeral/glenoid capsule in the axillary recess, and hyperintensity and obliteration of the subcoracoid fat triangle were evaluated.

Results: Anterior capsular thickness, glenoid capsular thickness in the axillary recess, and anterior and axillary capsular hyperintensities were significantly more dominant in the stiff group (all $P < .05$) than in the control group. Anterior capsular thickness and anterior capsular abnormal hyperintensity could be used to differentiate between the stiff and control groups ($P < .05$). Anterior capsular thickness showed high diagnostic performance with an area under the receiver operating characteristic curve of 0.993. The cut-off value for stiffness was 3.07 mm (sensitivity, 96.1%; specificity, 100%).

Conclusion: Anterior capsular thickening and abnormal hyperintensity were the most predictive MRI findings for stiffness in patients with rotator cuff tear and stiffness to differentiate from patients with rotator cuff tear without stiffness.

Rotator cuff tear (RCT) and shoulder stiffness are two major causes of shoulder pain and disability.[21] Shoulder stiffness and RCTs occur concomitantly in 12.3%-41.7% of patients.[3,10,11,19,27] Shoulder stiffness occurs when the glenohumeral joint shows restricted active and passive motions, caused by fibrosis and subsequent contracture of the glenohumeral joint capsule and ligaments.[23] The term "stiff shoulder" commonly refers to adhesive capsulitis, with the shoulder feeling "frozen" and painful with loss of range of motion (ROM).[6] Adhesive capsulitis can be categorized as primary (idiopathic) or secondary, depending on the underlying shoulder pathology, such as RCT, subacromial bursitis, biceps tendinopathy, or recent shoulder surgery or trauma.[6,17]

Common magnetic resonance imaging (MRI) findings in idiopathic adhesive capsulitis include capsular thickening and enhancement, abnormal hyperintensity in the axillary recess, thickening of the coracohumeral ligament, and obliteration of the subcoracoid fat triangle.[2,9,15] Park et al[20] reported that anterior capsular abnormality is suggestive of idiopathic adhesive capsulitis

The study protocol was approved by the Institutional Review Boards of Seoul National University Bundang Hospital [SNUBH], (No. B-2204-754-102).

*Corresponding author: Joo Han Oh, MD, PhD, Department of Orthopaedic Surgery, Seoul National University College of Medicine, Seoul National University Bundang Hospital 82, Gumi-ro 173beon-gil, Bundang-gu, Seongnam-si, Gyeonggi-do 13620, Republic of Korea.

E-mail address: ohjh1@snu.ac.kr (J.H. Oh).

https://doi.org/10.1016/j.jseint.2023.05.001

of the shoulder, in addition to previously known abnormal MRI findings. However, these MRI findings may not always be evident in patients with RCT concomitant with shoulder stiffness in actual clinical situations. To the best of our knowledge, no study has compared the typical MRI findings in patients having RCT with and without shoulder stiffness. Therefore, we aimed to determine the most predictive MRI finding in patients having RCT with shoulder stiffness to differentiate from patients with RCT and without stiffness.

Materials and methods

Inclusion and exclusion criteria

This study was approved by the Institutional Review Boards of Seoul National University Bundang Hospital (No. B-2204-754-102), and in keeping with the policies for a retrospective review, informed consent was not required. Between January 2014 and October 2019, 2333 consecutive patients who underwent arthroscopic rotator cuff repair at the senior author's institution were retrospectively reviewed. We included patients who met the following criteria: patients with RCTs verified using preoperative MRI, who had undergone arthroscopic rotator cuff repair, and in whom shoulder MRI, excluding magnetic resonance (MR) arthrography, was performed for the homogeneity acquisition of MRI. The average duration between MRI acquisition and the measurement of stiffness was approximately 1 month. The exclusion criteria were as follows: patients undergoing revision surgery (n = 6), who had MRI scans acquired from another hospital (n = 1165), and in whom shoulder MR arthrography (n = 393) was performed. After the exclusion of 1564 patients who met the exclusion criteria, 769 patients were included in this study.

The ROM was assessed in the fixed scapular position using a goniometer, including forward flexion, external rotation at side, and internal rotation at back. Forward flexion was measured as the angle between the arm and thorax with the elbow fully extended. External rotation at side was measured as the angle between the forearm and thorax with the upper arm in adduction and the elbow in 90° flexion. Internal rotation at back was measured at the vertebral level that the tip of the patient's thumb could reach in the sitting position. We set the criteria for defining stiffness as forward flexion <120°, external rotation at side <30°, and internal rotation at back <L3 in the active ROM, according to previous studies[5,19,25](Fig. 1). Patients who met any one of these three criteria were considered to have preoperative stiffness. Thereafter, patients were categorized into two groups: RCT with stiffness (stiff group) and RCT without stiffness (control group). Before propensity score matching, the stiff and control groups included 123 and 646 patients, respectively. One-to-one propensity score matching was performed for 76 patients per group to minimize the selection bias. Covariables for matching included age, sex, and tear size of the torn tendon (Fig. 2).

Magnetic resonance imaging (MRI) protocol and acquisition

The same MRI protocol was used in all patients with a 3-T MRI unit (Achieva or Ingenia; Philips Healthcare, Best, The Netherlands) having a dedicated shoulder coil. All examinations were conducted without intravenous or intraarticular administration of contrast material. During imaging, patients were instructed to lie in the supine position with their arms rotated externally to the maximum extent. The standard protocol consisted of acquiring fat-suppressed proton density images in the axial plane (repetition time/time to echo, 2939-2944/30; echo-train length, 11; section thickness, 2.5 mm; matrix, 256 × 246; and field of view, 140 × 140 mm), fat-suppressed T2-weighted images in the axial (repetition time/time to echo, 2591-4613/65-80; echo-train length, 17; section thickness, 2.5 mm; matrix, 256 × 253; and field of view, 140 × 140 mm) and oblique coronal and oblique sagittal (repetition time/time to echo, 2246-2519/80; echo-train length, 17; section thickness, 3.0 mm; matrix, 256 × 237; and field of view, 140 × 140 mm) planes, T2-weighted images in the oblique coronal (repetition time/time to echo, 2246-2418/80; echo-train length, 17; section thickness, 2.5 mm; matrix, 256 × 243; and field of view, 140 × 140 mm) and oblique sagittal (repetition time/time to echo, 2519-3109/80; echo-train length, 17; section thickness, 2.5 mm; matrix, 232 × 230; and field of view, 140 × 140 mm) planes, and T1-weighted images in the oblique sagittal plane (repetition time/time to echo, 584.8-610.9/7.8; echo-train length, 6; section thickness, 3.0 mm; matrix, 256 × 253; and field of view, 140 × 140 mm).

Measurement of MRI variables

Relevant variables were measured independently by two orthopedic shoulder fellowship-trained surgeons. To evaluate the validity of measurements in each group, each surgeon measured each value twice at 1-month intervals to calculate the intraclass and interclass correlation coefficients.

In quantitative analysis, the following variables were measured on MR images (Fig. 3): anterior capsular thickness, humeral and glenoid capsular thickness in the axillary capsule, maximal axillary capsular thickness, and coracohumeral ligament thickness. We determined the anterior capsule to be located from the anterior 2 to 5 o'clock position of the glenohumeral joint capsule, deep to the subscapularis muscle and tendon.[20] The anterior capsular thickness was measured at the thickest portion of this structure, and the measurement was performed on both axial and oblique sagittal fat-suppressed T2-weighted MR images. The humeral and glenoid capsular thicknesses were measured on oblique coronal T2-weighted MR images at the thickest portion in the axillary recess. The maximal axillary capsular thickness was then determined to be the larger value of the humeral and glenoid capsular thicknesses. The maximal coracohumeral ligament thickness was measured on oblique sagittal T2-weighted images. All measurements were recorded to one decimal place.

In qualitative analysis, the presence of the following findings was evaluated (Fig. 4): anterior capsular abnormal hyperintensity, humeral and glenoid capsular abnormal hyperintensities in the axillary recess, and abnormal hyperintensity and obliteration of the subcoracoid fat triangle.[22] The anterior capsular abnormal signal intensity was determined on both axial and oblique sagittal fat-suppressed T2-weighted MR images. In the case of abnormal hyperintensity on either side of the humeral or glenoid capsule of the axillary recess, axillary capsular abnormal hyperintensity was determined to be present.[22] Abnormal hyperintensity of the joint capsule and subcoracoid fat triangle was evaluated on oblique coronal fat-suppressed T2-weighted MR images. Obliteration of the subcoracoid fat triangle was defined as low signal intensity of fat on T1-weighted images with respect to subcutaneous fat on oblique sagittal T1-weighted images.[15,18]

Statistical analyses

All statistical analyses were performed using the Statistical Analysis System statistical software package version 9.4 (SAS Institute Inc., Cary, NC, USA) and R software version 3.6.2 (R Foundation for Statistical Computing, Vienna, Austria).

Power analysis was performed using PASS software version 15.0.3 (NCSS Statistical Software, Kaysville, UT, USA) to confirm that the statistical power was sufficient. Using the average anterior

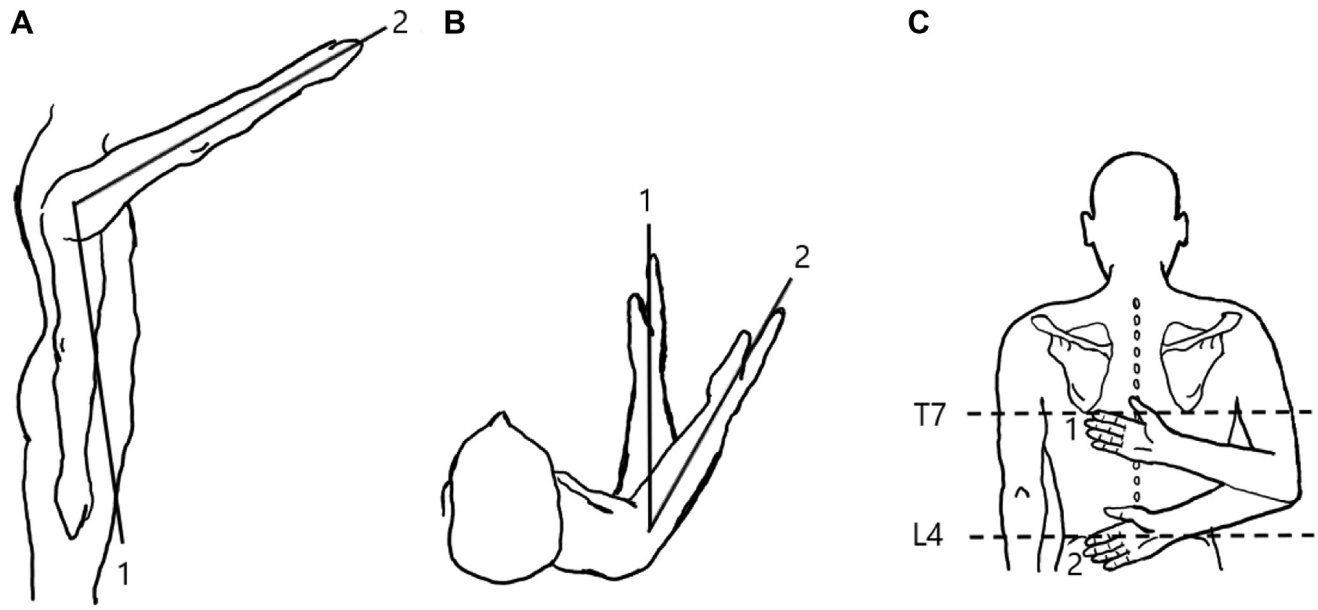

Figure 1 Reference and method of measurement for (**a**) forward flexion, (**b**) external rotation at the side, and (**c**) internal rotation (1, reference point, 2, point reached by arm). * The reference point for forward flexion; the thoracic vertebrae.

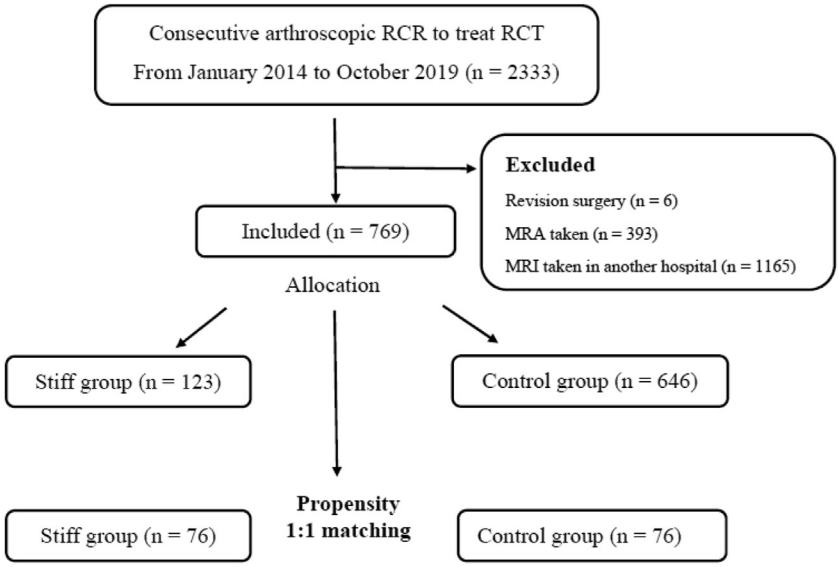

Figure 2 Study design. *MRA*, magnetic resonance arthrography; *MRI*, magnetic resonance imaging; *RCR*, rotator cuff repair; *RCT*, rotator cuff tear.

capsular thicknesses of 3.99 ± 1.64 mm (stiff group) and 1.66 ± 0.79 mm (control group), based on the data reported in the previous literature,[20] we determined that a sample size of 152 patients (76 patients per group) with a two-sided α value of 5% had a sufficient power of >99%.

Demographic characteristics and MRI variables were compared between the stiff and control groups. Fisher's exact test or Mann-Whitney U test was used to compare demographic data and imaging variables between the two groups. Binary multiple logistic regression analysis was performed to determine the relative contributions of MRI variables. Owing to the presence of variables with small event sizes, Firth penalized maximum-likelihood estimation was applied to reduce bias in the 95% confidence interval and parameter estimates.[7] Variables with a P value < .05 upon analysis were used as independent input variables for multiple logistic regression analysis. To eliminate multicollinearity, multivariate analysis was performed separately for quantitative and qualitative variables. To evaluate the diagnostic utilities of various parameters, we performed receiver operating characteristic (ROC) analysis to determine sensitivities, specificities, and cut-off values.

Interclass correlation coefficient was calculated to assess the extent of agreement between two readers in terms of measurements of four parameters in quantitative analysis. The interclass correlation coefficient was calculated using a two-way random model for each reader and patient. To evaluate interobserver variability in qualitative analysis, Cohen kappa statistics were used.

Results

Intraobserver and interobserver agreements

The results of intraobserver and interobserver agreements are summarized in Table I. Good intraobserver agreement was

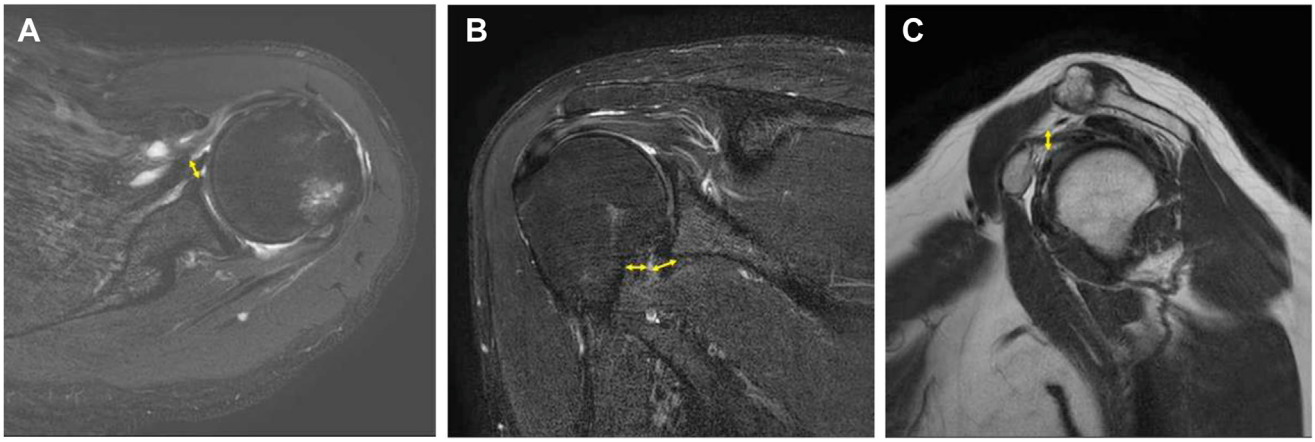

Figure 3 Measurements of quantitative MRI variables. (**a**) MRI of a 72-year-old man with rotator cuff tear and shoulder stiffness. Axial fat-suppressed T2-weighted MR image showing prominent thickening of the anterior joint capsule. The anterior capsule is located from the anterior 2 to 5 o'clock position of the glenohumeral joint capsule, deep to the subscapularis (*double yellow arrow*, 3.83 mm). (**b**) MRI of a 56-year-old man with rotator cuff tear and shoulder stiffness. Oblique coronal fat-suppressed T2-weighted image showing measurement of the thickest portion of the axillary joint capsule in both humeral (*double yellow arrow*, 4.13 mm) and glenoid (*double yellow arrow*, 4.39 mm) attachments. (**c**) MRI of a 71-year-old woman with rotator cuff tear and shoulder stiffness. Oblique sagittal T2-weighted image showing measurement of the coracohumeral ligament thickness (*double yellow arrow*, 1.79 mm). *MRI*, magnetic resonance imaging.

found for anterior capsular thickness measurements (interclass correlation coefficient = 0.83). The intraclass correlation for each assessor was moderate to good for quantitative variables. The interclass correlation was calculated using the first value of measurement of each assessor for quantitative variables. Good interobserver agreement was found for anterior (interclass correlation coefficient = 0.79) and humeral (interclass correlation coefficient = 0.76) capsular thickness measurements. Almost perfect intraobserver agreement was evident for qualitative variables. Thus, the interclass correlation was calculated using the first value of the measurement of each assessor in qualitative analysis variables. Almost perfect interobserver agreement was found for anterior capsular abnormal hyperintensity (κ = 0.85), humeral capsular abnormal hyperintensity (κ = 0.81), abnormal hyperintensity at the subcoracoid fat triangle (κ = 0.89), and obliteration of the subcoracoid fat triangle (κ = 0.94).

Comparisons of MRI variables between groups

After propensity score matching, 76 patients in each group were matched for analysis, and the mean age of all patients was 63.3 ± 8.4 (range, 46-80) years. There was no significant difference in age, sex, site, and tear size between the two groups, which were successfully matched (Table II).

Univariate analysis for quantitative MRI variables showed that the mean anterior capsular thickness ($P < .001$) and mean glenoid capsular thickness in axillary recess ($P = .016$) were significantly greater in the Stiff group than in the Control group (Table II). Univariate analysis for qualitative MRI variables showed that anterior ($P < .001$), axillary ($P = .002$), humeral ($P = .013$), and glenoid ($P = .001$) capsular abnormal hyperintensities were significantly more dominant in the stiff group than in the control group (Table II).

Multivariate analysis demonstrated that anterior capsular thickness and abnormal hyperintensity were specific variables that could be used to differentiate between the stiff and control groups with adjusted odds ratios[7] of 2.544 and 12.807, respectively ($P < .05$, Table II).

Diagnostic performance and cut-off value

In the ROC analysis, anterior capsular thickness showed a high diagnostic performance with an area under the ROC curve of 0.993; this indicates that anterior capsular thickness is an independent factor for predicting the occurrence of stiffness in patients with RCT ($P < .001$). The cut-off value of anterior capsular thickness for diagnosing stiffness was 3.07 mm, with a sensitivity of 96.1% and a specificity of 100% (Fig. 5).

Discussion

Our results demonstrated that anterior capsular thickness and abnormal hyperintensity of the anterior capsule were the most useful variables for predicting stiffness in patients with RCT and had a high diagnostic performance with good reliability. The cut-off value of anterior capsular thickness for diagnosing stiffness was 3.07 mm, with a sensitivity of 96.1% and a specificity of 100%. To the best of our knowledge, this is the first study to evaluate the most predictive MRI finding for differentiating between RCT concomitant with shoulder stiffness and RCT alone. MRI can be useful for the diagnosis of shoulder pathologies and provide important data for determining the appropriate surgical treatment strategy in RCT.[1,4,13] Although stiffness can be diagnosed by recording the patient's history or performing physical examination,[14] abnormal MRI findings suggestive of stiffness can help surgeons determine the location of additional release for the improvement in ROM.

Recently, Kim et al[13] conducted a retrospective study to evaluate the association between MRI findings and preoperative passive ROM in patients with full-thickness RCT. They reported that MRI findings, such as joint capsule edema and thickness at the axillary recess, could be useful for predicting shoulder stiffness in patients with RCTs. Different from their study,[13] the present study is the first to compare the most predictive MRI findings for RCT with (stiff group) and without (control group) stiffness. Furthermore, to reduce selection bias, we performed 1:1 propensity score matching for age, sex, and tear size of the torn tendon. Previous clinical studies have already reported a characteristic correlation between shoulder stiffness and age, sex, and the size of RCT.[26,28] Ueda et al[28] reported a higher proportion of patients of the female sex and younger age in the stiff group. They also reported that the degree of shoulder stiffness was not associated with the size of RCT. In contrast, Seo et al[26] reported no statistically significant differences in age and sex with regard to the presence of stiffness in patients with RCTs. However, they reported that stiffness is related to the size of RCT. Therefore, our comparative study

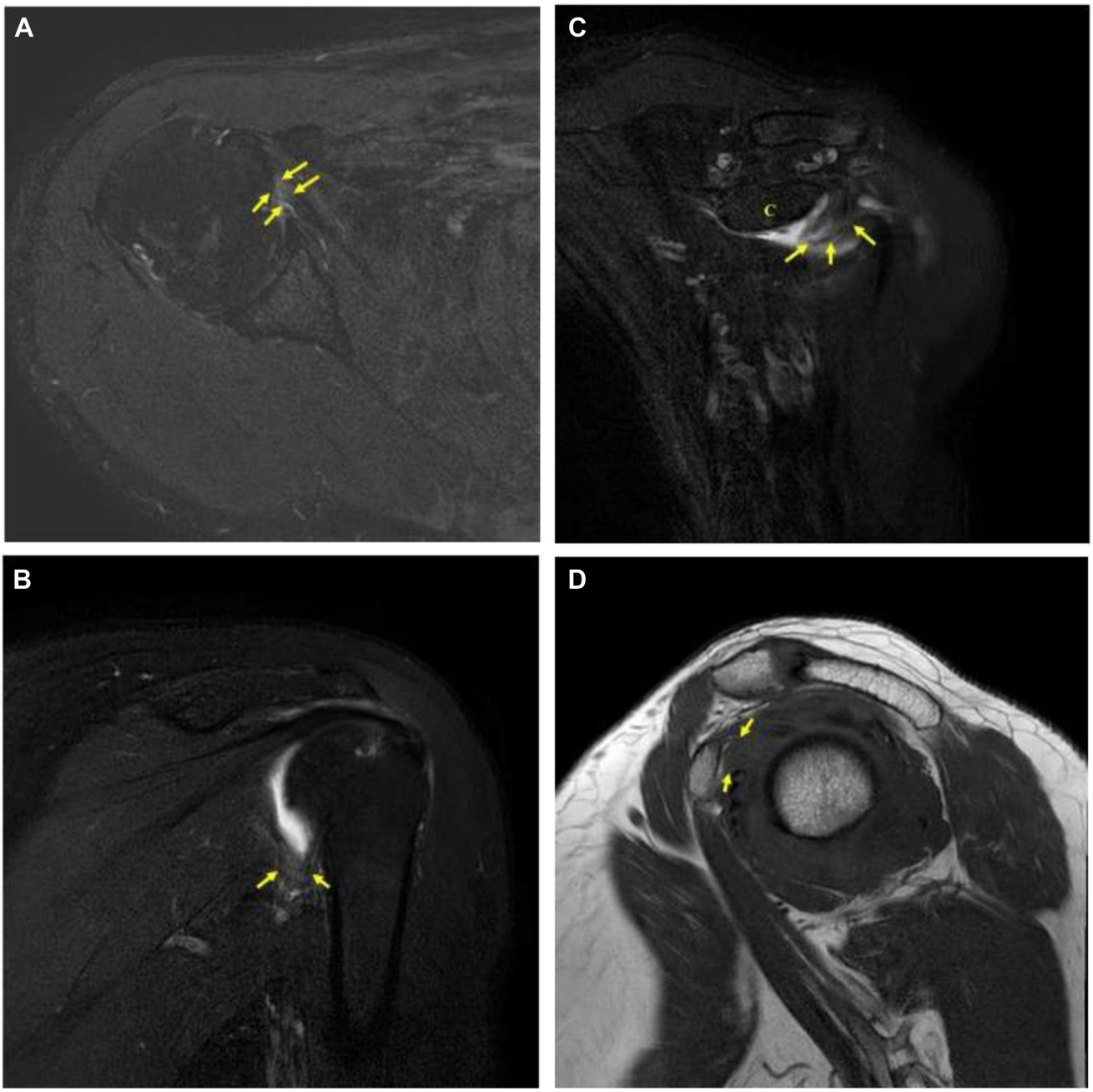

Figure 4 Measurements of qualitative MRI variables. (**a**) MRI of a 71-year-old woman with rotator cuff tear and shoulder stiffness. Axial fat-suppressed T2-weighted MR image showing measurement of anterior capsular hyperintensity. Significant abnormal hyperintensity of the anterior joint capsule. (**b**) MRI of a 53-year-old woman with rotator cuff tear and shoulder stiffness. Oblique coronal fat-suppressed T2-weighted image showing axillary capsular thickening and abnormal hyperintensity. Increased thickness at the glenoid (4.05 mm) and humeral (3.81 mm) portions and T2 signal hyperintensity of the axillary joint capsule (*yellow arrow*). (**c**) MRI of a 53-year-old woman with rotator cuff tear and shoulder stiffness. Oblique coronal fat-suppressed T2-weighted image at the coracoid process (C) level showing abnormal hyperintensity at the subcoracoid fat triangle (*yellow arrow*). (**d**) MRI of a 53-year-old woman with rotator cuff tear and shoulder stiffness. Oblique sagittal T1-weighted image showing obliteration of the subcoracoid fat triangle (*yellow arrow*). *MRI*, magnetic resonance imaging.

is clinically meaningful in that we minimized the confounding factors of stiffness in patients with RCT and stiffness (stiff group) and in those without stiffness (control group) using 1:1 propensity score matching.

Generally, the anterior capsule of the shoulder is located from the anterior 2 to 5 o'clock position of the glenohumeral joint capsule, deep to the subscapularis, and includes the middle and spiral glenohumeral ligaments.[20] In patients with adhesive capsulitis, the anterior capsule typically presents with fibrotic processes,[29] elevated levels of inflammatory cytokines,[16] presence of mature and regenerative nerve fibers, and elevated levels of several immunoreactive neuronal proteins (GAP43, PGP9.5, and P75).[32] Recently, Park et al[20] conducted a retrospective imaging study using MRI to evaluate the usefulness of abnormal thickening or hyperintensity of the anterior capsule to diagnose primary adhesive capsulitis. They reported that anterior capsular thickening and abnormal hyperintensity could be used to diagnose primary adhesive capsulitis of the shoulder in conjunction with previous abnormal MRI findings.[20] In our study, anterior capsular thickening and abnormal hyperintensity were the most predictive MRI

TABLE I
Intraobserver and interobserver agreement.

Intraobserver agreement			Interobserver agreement	
Variable	ICC (95% CI)	κ	ICC (95% CI)	κ
Quantitative analysis				
Anterior capsular thickness (mm)	0.83 (0.77-0.87)		0.79 (0.71-0.85)	
Maximal axillary capsular thickness (mm)	0.61 (0.49-0.70)		0.72 (0.64-0.79)	
Humeral capsular thickness (mm)	0.66 (0.57-0.75)		0.76 (0.68-0.82)	
Glenoid capsular thickness (mm)	0.62 (0.51-0.71)		0.72 (0.64-0.79)	
Coracohumeral ligament thickness (mm)	0.54 (0.42-0.64)		0.64 (0.52-0.73)	
Qualitative analysis				
Anterior capsular abnormal hyperintensity		0.93 (0.88-0.99)		0.85 (0.77-0.94)
Axillary capsular abnormal hyperintensity		0.86 (0.75-0.96)		0.75 (0.62-0.88)
Humeral capsular abnormal hyperintensity		0.84 (0.72-0.96)		0.81 (0.68-0.94)
Glenoid capsular abnormal hyperintensity		0.81 (0.69-0.94)		0.74 (0.60-0.89)
Abnormal hyperintensity at subcoracoid fat triangle		1.00 (1.00-1.00)		0.89 (0.80-0.98)
Obliteration of the subcoracoid fat triangle		1.00 (1.00-1.00)		0.94 (0.88-1.00)

CI, confidence interval; *ICC*, Interclass correlation coefficient; κ, Cohen's kappa.

TABLE II
Results of demographic and magnetic resonance imaging variable comparisons between the two groups after propensity score matching.

Variable	Stiff group (n = 76)	Control group (n = 76)	*P* value	Multivariable analysis	
				aOR*	*P* value
Age (y)	63.3 ± 8.4	63.3 ± 8.4	1		
Sex (male/female)	32 / 44	32 / 44	1		
Tear size (R1: R2: R3: R4)	19 / 35 / 6 / 16	17 / 32 / 7 / 20	1		
Quantitative analysis†					
Anterior capsular thickness (mm)	3.9 ± 0.4	2.5 ± 0.3	***<.001***	***2.544***	***<.001***
Maximal axillary capsular thickness (mm)	3.0 ± 1.1	2.7 ± 1.0	.098		
Humeral capsular thickness (mm)	2.5 ± 0.9	2.2 ± 1.0	.079		
Glenoid capsular thickness (mm)	2.9 ± 1.1	2.5 ± 1.0	***.016***	0.907	.088
Coracohumeral ligament thickness (mm)	1.8 ± 0.6	1.9 ± 0.6	.503		
Qualitative analysis‡					
Anterior capsular abnormal hyperintensity	61 (80.3%)	7 (9.2%)	***<.001***	***12.807***	***.049***
Axillary capsular abnormal hyperintensity	23 (30.3%)	7 (9.2%)	***.002***		
Humeral capsular abnormal hyperintensity	19 (25.0%)	7 (9.2%)	***.013***	25.221	.138
Glenoid capsular abnormal hyperintensity	21 (27.6%)	4 (5.3%)	***.001***	1.454	.832
Abnormal hyperintensity at subcoracoid fat triangle	19 (25.0%)	15 (19.7%)	.437		
Obliteration of the subcoracoid fat triangle	19 (25.0%)	15 (19.7%)	.437		

Mann-Whitney U test was used to compare demographic data. Owing to the presence of variables with small event sizes, Firth penalized maximum-likelihood estimation was applied to reduce bias in the 95% confidence interval and parameter estimates.[7] Significant *P* values are shown in bold and italics.
R1 small-sized tear, *R2* medium-sized tear, *R3* large-sized tear, *R4* massive tear.
*aOR: adjusted odds ratio.
†Data are presented as mean ± standard deviation.
‡Data are presented as number (percentage).

findings for shoulder stiffness. Therefore, the anterior capsule seems to be an important variable in predicting stiffness, regardless of the presence of RCT. This is because shoulder stiffness in the external rotation is common in patients with both RCT and stiffness.[13]

A recent systematic review reported histological findings suggestive of adhesive capsulitis as fibrotic processes limited to the anterior part of the capsule, elevated levels of inflammatory cytokines in the anterior capsule and subacromial bursa, and presence of mature and regenerating nerve fibers in the anterior capsule.[24] Moreover, anterior capsular thickening was frequently evident on arthroscopy in patients with stiffness.[30,31] Similarly, Kim et al[12] conducted a prospective study to compare the genetic expressions of inflammation- and fibrosis-related factors in the anterior and posterior capsules between patients with and without stiffness and having RCT. They reported that more fibrous processes occur in the anterior capsule than in the posterior capsule in patients with stiffness.[12] The levels of fibronectin, matrix metalloproteinase-2, and matrix metalloproteinase-9 in the anterior capsule were significantly higher than those in the posterior capsule.[12] These pathophysiological and histological results also support our findings on the significance of anterior capsular thickness.

This study has some limitations. First, criteria for stiffness may vary across studies. Since there is no single standard for diagnosing stiffness, MRI findings of previous studies may differ from our findings. Second, as this is a retrospective study, selection bias was inevitable because we only enrolled patients who underwent arthroscopic rotator cuff repair. Clinically, these MRI findings are more important in patients requiring rotator cuff repair than in those with partial tears requiring conservative treatment. To minimize the effect of selection bias, we performed 1:1 propensity score matching according to age, sex, and tear size of the torn tendon. Third, discrepancies between the date of MRI acquisition and the date of measurement of stiffness were evident. Therefore, it is difficult to interpret that the MRI scan exactly represents the patient's stiffness. However, as stiffness does not usually resolve in a short period,[8] the effect would not be clinically significant.

Conclusion

The MRI findings of RCT concomitant with shoulder stiffness were different from those of conventional primary adhesive capsulitis. Anterior capsular thickening and anterior capsular abnormal

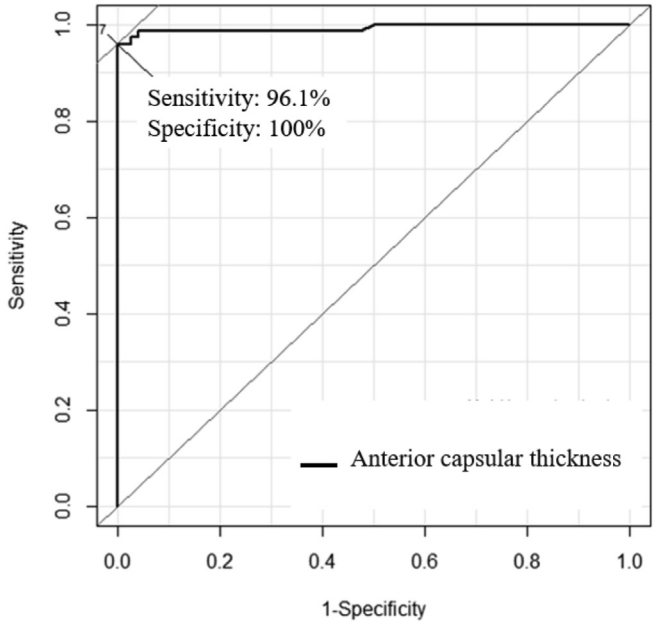

Figure 5 ROC analysis of anterior capsular thickness (area under the ROC curve = 0.993, $P < .001$). The cut-off value of anterior capsular thickness for diagnosing stiffness was 3.07 mm, with a sensitivity of 96.1% and a specificity of 100%. *ROC*, receiver operating characteristic.

hyperintensity were the most predictive MRI findings for stiffness in patients with RCT and shoulder stiffness to differentiate from patients with RCT and without stiffness.

Disclaimers:

Funding: No funding was disclosed by the authors.
Conflicts of interest: The authors, their immediate families, and any research foundation with which they are affiliated have not received any financial payments or other benefits from any commercial entity related to the subject of this article.

References

1. Bhatnagar A, Bhonsle S, Mehta S. Correlation between MRI and arthroscopy in diagnosis of shoulder pathology. J Clin Diagn Res 2016;10:RC18-21. https://doi.org/10.7860/jcdr/2016/14867.7309.
2. Carrillon Y, Noel E, Fantino O, Perrin-Fayolle O, Tran-Minh VA. Magnetic resonance imaging findings in idiopathic adhesive capsulitis of the shoulder. Rev Rhum Engl Ed 1999;66:201-6.
3. Chen Y, Chen S, Qiao Y, Ge Y, Li H, Chen J, et al. A Long preoperative duration of Symptoms is associated with Worse Functional Outcomes after 1-stage arthroscopic treatment of rotator cuff tears with shoulder stiffness. Am J Sports Med 2017;45:2336-44. https://doi.org/10.1177/0363546517707202.
4. Chi AS, Kim J, Long SS, Morrison WB, Zoga AC. Non-contrast MRI diagnosis of adhesive capsulitis of the shoulder. Clin Imaging 2017;44:46-50. https://doi.org/10.1016/j.clinimag.2017.04.002.
5. Chung SW, Huong CB, Kim SH, Oh JH. Shoulder stiffness after rotator cuff repair: risk factors and influence on outcome. Arthroscopy 2013;29:290-300. https://doi.org/10.1016/j.arthro.2012.08.023.
6. Ewald A. Adhesive capsulitis: a review. Am Fam Physician 2011;83:417-22.
7. Firth D. Bias reduction of maximum likelihood estimates. Biometrika 1993;80:27-38.
8. Gillet R, Zhu F, Padoin P, Rauch A, Hossu G, Teixeira PAG, et al. MR imaging Biomarkers for clinical Impairment and disease progression in patients with shoulder adhesive capsulitis: a prospective study. J Clin Med 2021;10:3882. https://doi.org/10.3390/jcm10173882.
9. Gokalp G, Algin O, Yildirim N, Yazici Z. Adhesive capsulitis: contrast-enhanced shoulder MRI findings. J Med Imaging Radiat Oncol 2011;55:119-25. https://doi.org/10.1111/j.1754-9485.2010.02215.x.
10. Ho WP, Huang CH, Chiu CC, Lee CH, Chen CH, Leu TH, et al. One-stage arthroscopic repair of rotator cuff tears with shoulder stiffness. Arthroscopy 2013;29:1283-91. https://doi.org/10.1016/j.arthro.2013.05.024.
11. Hsu SL, Ko JY, Chen SH, Wu RW, Chou WY, Wang CJ. Surgical results in rotator cuff tears with shoulder stiffness. J Formos Med Assoc 2007;106:452-61. https://doi.org/10.1016/s0929-6646(09)60294-1.
12. Kim YS, Lee YG, Park HS, Cho RK, Lee HJ. Comparison of Gene expression of inflammation- and fibrosis-related factors between the anterior and posterior capsule in patients with rotator cuff tear and shoulder stiffness. Orthop J Sports Med 2021;9: 23259671211032543. https://doi.org/10.1177/23259671211032543.
13. Kim YY, Chung BM, Kim WT, Lee Y. MRI findings predictive of shoulder stiffness in patients with full-thickness rotator cuff tears. AJR Am J Roentgenol 2020;214:1146-51. https://doi.org/10.2214/ajr.19.21973.
14. Le HV, Lee SJ, Nazarian A, Rodriguez EK. Adhesive capsulitis of the shoulder: review of pathophysiology and current clinical treatments. Shoulder Elbow 2017;9:75-84. https://doi.org/10.1177/1758573216676786.
15. Lee SY, Park J, Song SW. Correlation of MR arthrographic findings and range of shoulder motions in patients with frozen shoulder. AJR Am J Roentgenol 2012;198:173-9. https://doi.org/10.2214/ajr.10.6173.
16. Lho YM, Ha E, Cho CH, Song KS, Min BW, Bae KC, et al. Inflammatory cytokines are overexpressed in the subacromial bursa of frozen shoulder. J Shoulder Elbow Surg 2013;22:666-72. https://doi.org/10.1016/j.jse.2012.06.014.
17. Lundberg BJ. The frozen shoulder. Clinical and radiographical observations. The effect of manipulation under general anesthesia. Structure and glycosaminoglycan content of the joint capsule. Local bone metabolism. Acta Orthop Scand Suppl 1969;119:1-59.
18. Mengiardi B, Pfirrmann CW, Gerber C, Hodler J, Zanetti M. Frozen shoulder: MR arthrographic findings. Radiology 2004;233:486-92. https://doi.org/10.1148/radiol.2332031219.
19. Oh JH, Kim SH, Lee HK, Jo KH, Bin SW, Gong HS. Moderate preoperative shoulder stiffness does not alter the clinical outcome of rotator cuff repair with arthroscopic release and manipulation. Arthroscopy 2008;24:983-91. https://doi.org/10.1016/j.arthro.2008.06.007.
20. Park J, Choi YH, Chai JW, Cha SW, Lim JH, Jo CH, et al. Anterior capsular abnormality: another important MRI finding for the diagnosis of adhesive capsulitis of the shoulder. Skeletal Radiol 2019;48:543-52. https://doi.org/10.1007/s00256-018-3064-8.
21. Park JY, Chung SW, Hassan Z, Bang JY, Oh KS. Effect of capsular release in the treatment of shoulder stiffness concomitant with rotator cuff repair: diabetes as a predisposing factor associated with treatment outcome. Am J Sports Med 2014;42:840-50. https://doi.org/10.1177/0363546513519326.
22. Park S, Lee DH, Yoon SH, Lee HY, Kwack KS. Evaluation of adhesive capsulitis of the shoulder with fat-suppressed T2-weighted MRI: association between clinical Features and MRI findings. AJR Am J Roentgenol 2016;207:135-41. https://doi.org/10.2214/ajr.15.15200.
23. Pogorzelski J, Imhoff AB, Degenhardt H, Siebenlist S. [Primary (idiopathic) shoulder stiffness: definition, disease progression, epidemiology and etiology]. Unfallchirurg 2019;122:917-24. https://doi.org/10.1007/s00113-019-0703-z.
24. Ryan V, Brown H, Minns Lowe CJ, Lewis JS. The pathophysiology associated with primary (idiopathic) frozen shoulder: a systematic review. BMC Musculoskelet Disord 2016;17:340. https://doi.org/10.1186/s12891-016-1190-9.
25. Sasanuma H, Sugimoto H, Iijima Y, Kanaya Y, Saito T, Takeshita K. Blood flow evaluation by dynamic magnetic resonance imaging of symptomatic rotator cuff tears and frozen shoulders. J Shoulder Elbow Surg 2018;27:e372-9. https://doi.org/10.1016/j.jse.2018.05.042.
26. Seo SS, Choi JS, An KC, Kim JH, Kim SB. The factors affecting stiffness occurring with rotator cuff tear. J Shoulder Elbow Surg 2012;21:304-9. https://doi.org/10.1016/j.jse.2011.04.011.
27. Tauro JC. Stiffness and rotator cuff tears: incidence, arthroscopic findings, and treatment results. Arthroscopy 2006;22:581-6. https://doi.org/10.1016/j.arthro.2006.03.004.
28. Ueda Y, Sugaya H, Takahashi N, Matsuki K, Kawai N, Tokai M, et al. Rotator cuff Lesions in patients with stiff shoulders: a prospective analysis of 379 shoulders. J Bone Joint Surg Am 2015;97:1233-7. https://doi.org/10.2106/jbjs.n.00910.
29. Uhthoff HK, Boileau P. Primary frozen shoulder: global capsular stiffness versus localized contracture. Clin Orthop Relat Res 2007;456:79-84. https://doi.org/10.1097/BLO.0b013e318030846d.
30. Uitvlugt G, Detrisac DA, Johnson LL, Austin MD, Johnson C. Arthroscopic observations before and after manipulation of frozen shoulder. Arthroscopy 1993;9:181-5.
31. Wiley AM. Arthroscopic appearance of frozen shoulder. Arthroscopy 1991;7:138-43.
32. Xu Y, Bonar F, Murrell GA. Enhanced expression of neuronal proteins in idiopathic frozen shoulder. J Shoulder Elbow Surg 2012;21:1391-7. https://doi.org/10.1016/j.jse.2011.08.046.