



Since January 2020 Elsevier has created a COVID-19 resource centre with free information in English and Mandarin on the novel coronavirus COVID-19. The COVID-19 resource centre is hosted on Elsevier Connect, the company's public news and information website.

Elsevier hereby grants permission to make all its COVID-19-related research that is available on the COVID-19 resource centre - including this research content - immediately available in PubMed Central and other publicly funded repositories, such as the WHO COVID database with rights for unrestricted research re-use and analyses in any form or by any means with acknowledgement of the original source. These permissions are granted for free by Elsevier for as long as the COVID-19 resource centre remains active.

J.P. Martínez-Barbero*, P. Tomás-Muñoz,
R. Martínez-Moreno

Sección de Neuroimagen, Hospital Universitario Virgen de las Nieves, Granada, Spain

*Corresponding author.

E-mail address: jpmbhg@hotmail.com
(J.P. Martínez-Barbero).

<https://doi.org/10.1016/j.nrleng.2020.07.003>
2173-5808/

© 2020 Sociedad Española de Neurología. Published by Elsevier España, S.L.U. This is an open access article under the CC BY-NC-ND license (<http://creativecommons.org/licenses/by-nc-nd/4.0/>).

Guillain–Barré syndrome as the first manifestation of SARS-CoV-2 infection



Síndrome de Guillain–Barré como forma de presentación de la infección por SARS-CoV-2

Dear Editor:

In the current context of the COVID-19 pandemic, the neurological complications of SARS-CoV-2 infection and their pathophysiology are being identified.^{1–4} We present a case of Guillain-Barré syndrome (GBS) appearing as a manifestation of COVID-19.

Our patient is a 54-year-old woman with history of arterial hypertension, dyslipidaemia, obesity, obstructive sleep apnoea syndrome, polycystic liver and kidney disease and stage 3b chronic kidney disease, and anterior cervical spondylosis due to disc herniation. She visited the emergency department due to a 4-day history of paraesthesia initially manifesting in the fingertips and subsequently in the tips of the toes, progressively associated with distal weakness. She also reported low-grade fever and vomiting of simultaneous onset, and no diarrhoea or respiratory symptoms.

The neurological examination revealed severe distal weakness in the left hand (0/5 in the extensor digitorum and carpal extensor muscles, 2/5 in the flexor digitorum and carpal flexor muscles, and 2/5 in the interosseous muscles) and mild weakness in the right hand (4/5 in the extensor digitorum and carpal extensor muscles and 4/5 in the interosseous muscles); mild weakness was also observed in the left foot (4/5 in the tibialis anterior, lateral peroneus, and tibialis posterior muscles) as well as dysaesthesia in the tips of the toes and Achilles tendon areflexia.

A lumbar puncture revealed albuminocytologic dissociation; considering the clinical diagnosis of GBS with sensorimotor involvement, we started treatment with intravenous immunoglobulins. Foot weakness worsened during the first 24 hours (3/5 in the tibialis anterior, lateral peroneus, and tibialis posterior muscles bilaterally) but subsequently showed a progressive improvement, with complete resolution at 10 days and only residual dysaesthesia persisting in the tips of the toes.

Given the epidemiological context, SARS-CoV-2 is considered a possible trigger of GBS; a polymerase chain reaction (PCR) test of nasopharyngeal exudate was conducted, yield-

ing negative results. During the course of the symptoms, the patient presented fever, and vomiting persisted, as well as an alveolar infiltrate in the right lower and middle lobes in a chest radiography, with negative results in urine pneumococcal antigen and *Legionella* antigen tests. Blood analysis results revealed lymphocytopenia, as well as elevated levels of D-dimer, ferritin, and lactate dehydrogenase. A second PCR test for SARS-CoV-2, performed at 24 hours, yielded positive results; therefore, we started empirical treatment with ceftriaxone, azithromycin, hydroxychloroquine, and lopinavir/ritonavir.

At day 6 after admission, the patient presented rapidly progressive severe respiratory insufficiency due to acute respiratory distress syndrome (ARDS), requiring non-invasive ventilatory support with continuous positive airway pressure (CPAP). An additional chest radiography revealed bilateral alveolar opacities. Given the clinical and radiological progression, we decided to administer treatment with methylprednisolone and tocilizumab.

Finally, the patient's respiratory symptoms progressively improved, and we were able to suspend ventilatory support and subsequently oxygen therapy. The patient was discharged 15 days after admission, with no vomiting or neurological symptoms.

In the aetiology study, the autoimmunity study yielded negative results for ANA, ANCA, RF, anti-dsDNA, and anti-gangliosides and positive results for anti-Ro antibodies; serology studies for cytomegalovirus, *Borrelia*, *Campylobacter*, *Mycoplasma*, HIV, and syphilis all returned negative results. Cerebrospinal fluid PCR testing for SARS-CoV-2 yielded negative results. An electrophysiological study performed 2 months later showed decreased amplitude of sensory potentials in all 4 limbs and, to a lesser degree, decreased motor evoked potential amplitudes; an electromyography using coaxial needle electrodes showed a slightly neurogenic recruitment pattern in distal muscles of the lower limbs, with no signs of denervation. Results were compatible with the acute motor-sensory axonal neuropathy (AMSAN) subtype of GBS, in the recovery phase.

GBS is a paradigmatic post-infectious inflammatory disease, with a known association with such viral infections as influenza, cytomegalovirus, or Epstein-Barr virus; more recently, it has been associated with emerging viruses, such as Zika, dengue, or chikungunya. Other cases have been reported in association with other coronaviruses, such as the Middle East respiratory syndrome (MERS) coronavirus.^{4,5}

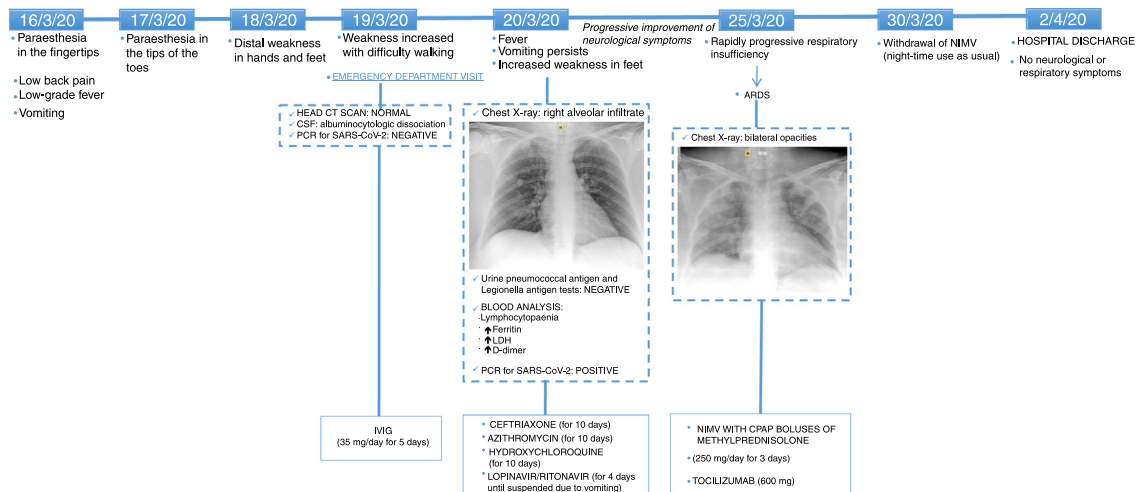


Figure 1 Timeline of symptom onset, complementary tests, treatments administered, and clinical progression. ARDS: acute respiratory distress syndrome; CPAP: continuous positive airway pressure; CSF: cerebrospinal fluid; CT: computed tomography; IVIG: intravenous immunoglobulins; LDH: lactate dehydrogenase; NIMV: non-invasive mechanical ventilation; PCR: polymerase chain reaction.

In general, the timeline of this case (Fig. 1) suggests that the patient presented an initial phase of viral replication, with respiratory involvement manifesting as pneumonia, digestive system involvement manifesting as persistent vomiting, and neurological involvement manifesting as axonal sensorimotor neuropathy. She later presented an inflammatory phase with ARDS.

Several cases of GBS have been reported in association with COVID-19^{4,6}; however, the pathogenic mechanism remains unknown. In most cases, viral symptoms manifest before neurological symptoms, in line with the post-infectious paradigm.^{6–9} In some cases,^{10–13} as in our patient, both types of symptoms overlap, suggesting a possible parainfectious mechanism.

In the current epidemiological context, a high level of suspicion of infection with SARS-CoV-2 should be maintained in all cases of GBS, since systemic symptoms may have an even greater role than neurological signs in the prognosis of these patients.

References

- Matías-Guiu J, Gomez-Pinedo U, Montero-Escribano P, Gomez-Iglesias P, Porta-Etessam J, Matias-Guiu JA. ¿Es esperable que haya cuadros neurológicos por la pandemia por SARS-CoV-2? *Neurologia*. 2020;35:170–5, <http://dx.doi.org/10.1016/j.nrl.2020.03.001>.
- Carod-Artal FJ. Complicaciones neurológicas por coronavirus y COVID-19. *Rev Neurol*. 2020;70:311–22, <http://dx.doi.org/10.33588/rn.7009.2020179>.
- Guidon AC, Amato AA. COVID-19 and neuromuscular disorders. *Neurology*. 2020;94:959–69, <http://dx.doi.org/10.1212/WNL.0000000000009566>.
- Montalvan V, Lee J, Bueso T, De Toledo J, Rivas K. Neurological manifestations of COVID-19 and other coronavirus infections: A systematic review. *Clin Neurol Neurosurg*. 2020;194:105921, <http://dx.doi.org/10.1016/j.clineuro.2020.105921>.

- Kim JE, Heo JH, Kim HO, Song SH, Park SS, Park TH. Neurological complications during Treatment of Middle East Respiratory Syndrome. *J Clin Neurol*. 2017;13:227–33, <http://dx.doi.org/10.3988/jcn.2017.13.3.227>.
- Dalakas MC. Guillain-Barré syndrome: The first documented COVID-19-triggered autoimmune neurologic disease: More to come with myositis in the offspring. *Neurol Neuroimmunol Neuroinflamm*. 2020;7:e781, <http://dx.doi.org/10.1212/NXI.0000000000000781>.
- Toscano G, Palmerini F, Ravaglia S, Ruiz L, Invernizzi P, Cuzzoni MG, et al. Guillain-Barré Syndrome Associated with SARS-CoV-2. *N Engl J Med*. 2020, <http://dx.doi.org/10.1056/NEJMc2009191>.
- Marta-Enguita J, Rubio-Baines I, Gastón-Zubimendi I. Síndrome de Guillain-Barré fatal tras infección por el virus SARS-CoV-2. *Neurologia*. 2020;35(4):265–7, <http://dx.doi.org/10.1016/j.nrl.2020.04.004>.
- Padroni M, Mastrangelo V, Ascoli GM, Pavolucci L, Abu-Rumeileh S, Piscaglia MG, et al. Guillain-Barré syndrome following COVID-19: new infection, old confusion? *J Neurol*. 2020:1–3, <http://dx.doi.org/10.1007/s00415-020-09849-6>.
- Alberti P, Beretta S, Piatti M, Karantzoulis A, Piatti ML, Santoro P, et al. Guillain-Barré syndrome related to COVID-19 infection. *Neurol Neuroimmunol Neuroinflamm*. 2020;7:e741, <http://dx.doi.org/10.1212/NXI.0000000000000741>.
- Zhao H, Shen D, Zhou H, Liu J, Chen S. Guillain-Barré syndrome associated with SARS-CoV-2 infection: causality or coincidence? *Lancet Neurol*. 2020;19(5):383–4, [http://dx.doi.org/10.1016/S1474-4422\(20\)30109-5](http://dx.doi.org/10.1016/S1474-4422(20)30109-5).
- Velayos Galán A, Del Saz Saucedo P, Peinado Postigo F, Botia Paniagua E. Síndrome de Guillain-Barré asociado a infección por SARS-CoV-2. *Neurologia*. 2020;35(4):268–9, <http://dx.doi.org/10.1016/j.nrl.2020.04.007>.
- Ottaviani D, Boso F, Tranquillini E, Gapeni I, Pedrotti G, Cozzio S, et al. Early Guillain-Barré syndrome in coronavirus disease 2019 (COVID-19): a case report from an Italian COVID-hospital. *Neurol Sci*. 2020;41:1351–4, <http://dx.doi.org/10.1007/s10072-020-04449-8>.

O. Barrachina-Esteve^{a,*}, A. Palau Domínguez^b, I. Hidalgo Torrico^c, M.L. Viguera Martínez^a

^a Servicio de Neurología, Parc Taulí Hospital Universitari, Institut d'Investigació i Innovació Parc Taulí I3PT, Universitat Autònoma de Barcelona, Sabadell, Barcelona, Spain

^b Servicio de Medicina Interna, Parc Taulí Hospital Universitari, Institut d'Investigació i Innovació Parc Taulí I3PT, Universitat Autònoma de Barcelona, Sabadell, Barcelona, Spain

^c Servicio de Cirugía Cardíaca, Hospital Universitario Son Espases, Palma de Mallorca, Spain

* Corresponding author.
E-mail address: oriolbe7@gmail.com
(O. Barrachina-Esteve).

<https://doi.org/10.1016/j.nrleng.2020.07.002>
2173-5808/

© 2020 Sociedad Española de Neurología. Published by Elsevier España, S.L.U. This is an open access article under the CC BY-NC-ND license (<http://creativecommons.org/licenses/by-nc-nd/4.0/>).

Refractory status epilepticus in genetic Creutzfeldt-Jakob disease with E200K mutation[☆]



Status epilèptico refractari en enfermedad de Creutzfeldt-Jakob genética por mutación E200K

Dear Editor:

Creutzfeldt-Jakob disease (CJD) is the most common prion disease in humans. It is caused by accumulation of abnormally folded prion proteins in the central nervous system. By aetiology, it is classified as sporadic, acquired, or genetic.¹ Between 10% and 15% of cases are caused by mutations in the prion protein gene (*PRNP*), with E200K being the most common mutation. The disease manifests with rapidly progressive cognitive impairment, cerebellar signs, and myoclonus, and presents a progressive fatal course. Seizures are reported in less than 15% of sporadic cases of CJD.^{2,3}

We present the case of a 48-year-old white man with personal history of arterial hypertension, dyslipidaemia, and chronic tobacco and cannabis use. He had no relevant family history or prior treatments. The patient was admitted due to speech and gait alterations of 2 months' progression. At admission, he presented predominantly motor aphasia and gait ataxia. Physical examination identified dysphasia, disinhibited behaviour with psychomotor agitation and unprovoked laughter, bilateral grasping reflex, dystonia in the left hand, dysmetria in the upper limbs, stimulus-induced multifocal myoclonus, and cerebellar ataxia. A complete blood analysis including serology and autoimmunity studies revealed no pathological findings. The cerebrospinal fluid (CSF) was acellular with slightly elevated protein levels; microbiological findings were negative and a 14-3-3 assay was positive. Brain

magnetic resonance imaging (MRI) showed FLAIR hyperintensity in both caudate nuclei and diffusion restriction in the putamina, both caudate nuclei, frontal and temporal parasagittal areas, and both cingulate gyri, with left predominance (Fig. 1). On the third day after admission the patient presented an episode of tonic ocular deviation to the right and altered level of consciousness, of 2-3 minutes' duration, which suggested a secondarily generalised focal seizure. During the first 2 weeks after admission, 6 electroencephalography (EEG) studies were performed, revealing pseudoperiodic discharges of generalised, predominantly left biphasic and triphasic sharp waves with spikes/polyspikes (Fig. 2). Despite antiepileptic treatment with levetiracetam at 2000 mg/24 hours, on day 11 he presented secondarily generalised status epilepticus with EEG correlate, which was responsive to clonazepam. The patient was transferred to the intensive care unit, and progressed poorly despite treatment with multiple antiepileptics (levetiracetam, lacosamide, phenytoin, clonazepam, midazolam, and propofol) and immunomodulation with corticosteroids and immunoglobulins. Genetic testing for CJD confirmed homozygous presence of the E200K mutation of the *PRNP* gene, with methionine at codon 129 (MM genotype). The patient died 3 weeks after admission. The neuropathological examination showed widespread vacuolisation and transcortical astrocytosis, which were particularly intense in limbic regions and the temporal neocortex; these findings are compatible with diagnosis of CJD.

The clinical presentation, with rapidly progressive cognitive impairment and ataxia, multifocal myoclonus, and focal dystonia, led us to suspect a prion encephalopathy as the most likely diagnosis. Differential diagnosis included autoimmune encephalitis, infectious encephalitis, toxic/deficiency and metabolic encephalopathies, vasculitis, and leptomeningeal carcinomatosis. Due to the episode of status epilepticus, we considered the possibility of autoimmune encephalitis, after ruling out herpes simplex encephalitis, and started empirical treatment with corticosteroids and immunoglobulins. In addition to the characteristic clinical presentation and rapid progression, one of the key clinical findings prompting suspicion of CJD was the presence of myoclonus.

CJD is a rare neurodegenerative disease; diagnosis of probable CJD is based on clinical, EEG, neuroimaging, and

[☆] Please cite this article as: Gómez Roldós A, Esteban de Antonio E, Pérez-Chirinos Rodríguez M, Pérez Sánchez JR. Status epilèptico refractari en enfermedad de Creutzfeldt-Jakob genética por mutación E200K. *Neurología*. 2020;35:712–714.