

# Therapeutic Endoscopic Ultrasound: Current Indications and Future Perspectives

Andrew Canakis<sup>a</sup> Todd H. Baron<sup>b</sup>

<sup>a</sup>Division of Gastroenterology and Hepatology, University of Maryland School of Medicine, Baltimore, MD, USA;

<sup>b</sup>Division of Gastroenterology and Hepatology, University of North Carolina at Chapel Hill, Chapel Hill, NC, USA

## Keywords

Endoscopic ultrasound · Biliary drainage ·  
Hepaticogastrostomy · Choledochoduodenostomy ·  
Pancreatic ductal drainage · Necrotic fluid collections ·  
Pancreatic cyst ablation · Lumen apposing metal stents

## Abstract

The transcendence of endoscopic ultrasound (EUS) from diagnostic to therapeutic tool has revolutionized management options in the field of gastroenterology. Through EUS-guided methods, pancreaticobiliary obstruction can now be utilized as an alternative to surgical and percutaneous approaches. This modality also allows for gallbladder drainage in patients who are not ideal operative candidates. By utilizing its unique imaging capabilities, EUS also allows for drainage access points in cases of gastric outlet obstruction as well as windows to ablate pancreatic cystic lesions. As technical progress continues to evolve, interventional gastroenterology continues to push the envelope of minimally invasive therapeutic procedures in a multidisciplinary setting. In this comprehensive review, we set out to describe current indications and innovations through EUS.

© 2023 The Author(s).

Published by S. Karger AG, Basel

## Ecoendoscopia Terapêutica: Indicações Atuais e Perspetivas Futuras

### Palavras Chave

Ecoendoscopia · Ultrassonografia · Drenagem biliar ·  
Hepatico-gastrostomia · Ablação de cistos pancreáticos ·  
Próteses de aposição de lúmen

### Resumo

A transformação da ecoendoscopia (EUS) de um método de diagnóstico a ferramenta terapêutica revolucionou a abordagem na gastroenterologia. As terapêuticas guiadas por EUS, nomeadamente as obstruções pancreatobiliares, constituem agora alternativas às abordagens cirúrgicas e percutâneas. Esta modalidade terapêutica permite também a drenagem da vesícula biliar em doentes que não são candidatos cirúrgicos. Além disso, ao utilizar as suas capacidades únicas de imagem, a EUS permite a drenagem em casos de obstrução da saída gástrica, bem como realizar a ablação de lesões císticas pancreáticas. O crescente progresso da gastroenterologia permite o desenvolvimento de procedimentos terapêuticos minimamente invasivos num ambiente multidisciplinar. Nesta revisão, propusemos-nos a descrever as atuais indicações e inovações através da EUS.

© 2023 The Author(s).

Published by S. Karger AG, Basel

---

## Introduction

The introduction and widespread implementation of endoscopic ultrasound (EUS) as a minimally invasive therapeutic modality has garnered significant attention in recent years. EUS has significantly revolutionized the field of interventional gastroenterology. The European Society of Gastrointestinal Endoscopy (ESGE) advises that these therapeutic EUS procedures be performed by experienced endoscopists at centers with adequate multidisciplinary support [1, 2]. In this state-of-the-art review, we will highlight the current indications for therapeutic EUS, including drainage of hepatobiliary and pancreatic obstruction, ablation of pancreatic cysts, management of gastric varices (GVs), and gallbladder drainage.

---

## Methods

We conducted a literature search across three databases (PubMed, Embase, and the Cochrane Library) up to November 2022. The research topics were prepared by the senior author (T.H.B.) and the literature search was performed by the first author (A.C.). Topics included drainage of hepatobiliary/pancreatic obstruction, pancreatic cyst ablation, GV management, and gallbladder drainage. All study types were included (randomized controlled trials, retrospective, prospective, meta-analyses, case series, and case reports).

---

## EUS Therapy for Biliary Obstruction

In instances of benign and malignant biliary obstruction, endoscopic retrograde cholangiopancreatography (ERCP) with transpapillary stenting remains the first-line management option [3–6]. In expert hands, ERCP has a success rate of up to 95% with an adverse event (AE) rate <10% [7, 8]. Difficult, failed, or impractical cannulation can be attributed to surgically altered anatomy (SAA), prior duodenal stenting, tumor obstruction, or periampullary diverticulum/tumor [3, 6]. Furthermore, difficult cannulations are also associated with higher rates of AEs, especially post-ERCP pancreatitis (approximately 5.3–6.6% of all cases) [9, 10]. In the setting of unsuccessful ERCP, current guidelines recommend reattempting the procedure at least two to 4 days later in order to optimize success by improving biliary visualization (decreased edema), patient sedation, and availability of specialized guidewire equipment [3].

Historically, percutaneous transhepatic biliary drainage (PTBD) has been utilized as salvage therapy in the

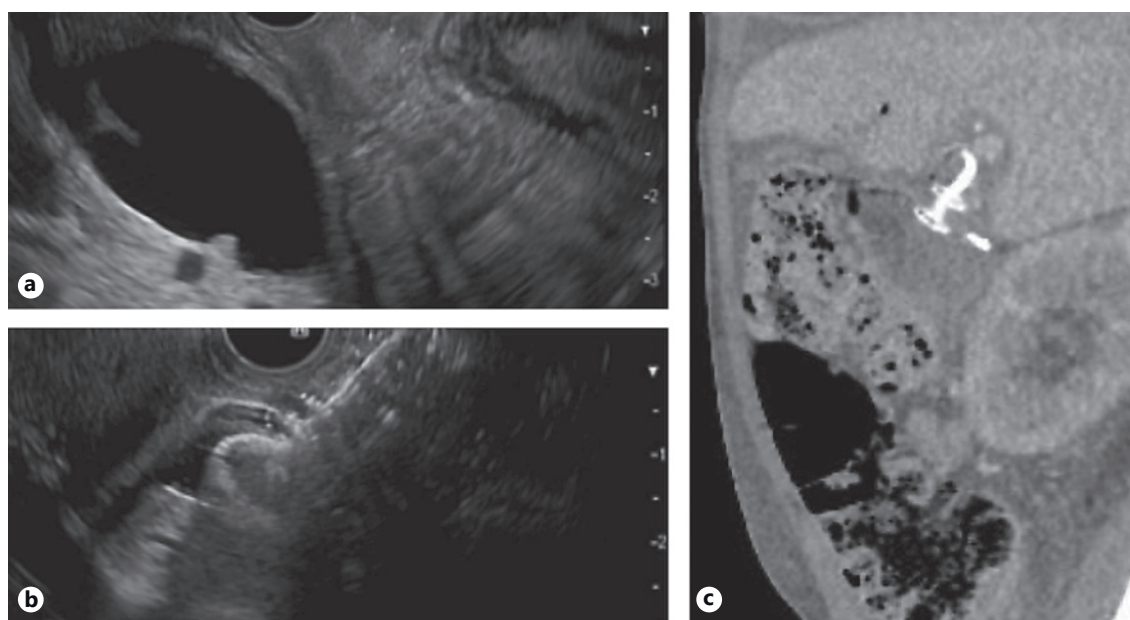
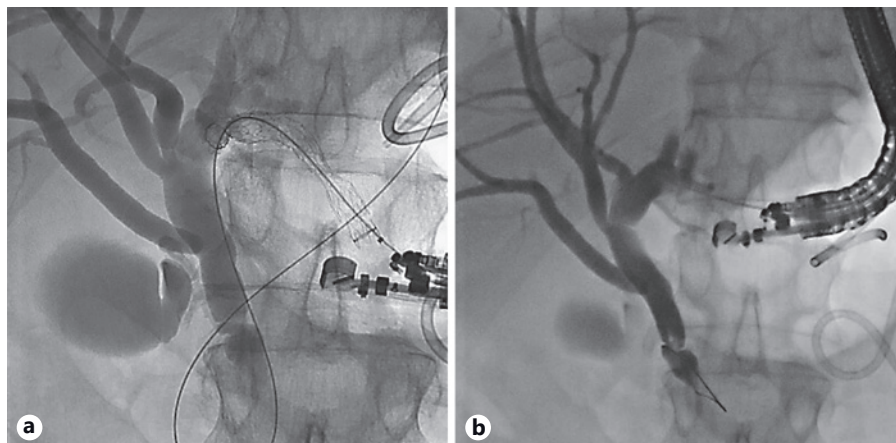
event of ERCP failure. PTBD is associated with a high success rate (95%); however, AEs are not uncommon (up to 30%), and the presence of an external catheter has also been associated with a reduced quality of life [6, 11]. It is in this setting where EUS-guided biliary drainage (EUS-BD) evolved as an alternative minimally invasive approach. The first reported case of EUS-guided bilioduodenal anastomosis was performed in 2001 [12]; since then, there have been a multitude of studies describing various techniques to accomplish EUS-BD. Compared to PTBD, EUS-BD is associated with fewer AEs and unscheduled reintervention rates with similar rates of success [13–15].

As such, EUS-BD has emerged as a reliable alternative when ERCP is not feasible [5]. Currently, performance of EUS-BD is limited to high volume centers driven by local expertise. The endoscopic learning curve is linked to procedural volume whereby technical success, procedure time and decreased AEs dramatically improve with operator experience [16–19]. It has been suggested that 33 and 100 cases are needed to achieve technical proficiency and mastery, respectively [18, 19]. The authors of this review article recently published a large single-center study (all procedures conducted by Dr. Baron) of EUS-guided transhepatic biliary drainage where total AEs (18.6%) significantly decreased over the 7 year time period in a cohort of over 200 patients [20]. That being said, EUS-BD is still a challenging procedure, largely limited to tertiary centers where there are rare instances of ERCP failure. One study found that ERCP failure in native papilla occurred in 0.6% (3/524 cases), in which all 3 patients were successfully managed by EUS-BD [21]. Yet there is growing evidence that EUS-BD can be considered as a first-line approach.

### *EUS-BD Techniques*

Before delving into comparative studies, it is first important to describe the methods of biliary decompression, which can be achieved through rendezvous (RV), antegrade or transluminal approaches [22]. EUS-RV is limited to cases where the papilla can be reached and used as salvage therapy when conventional ERCP fails, whereby guidewire is accessed through the papilla in an antegrade fashion [22]. This approach is associated with a success and a major AE rate of 80% and 11%, respectively [22]. In RV, the puncture site (via transgastric into left intrahepatic duct or transduodenal into the extrahepatic duct) enables guidewire placement across the stricture/papilla without fistula tract formation [2]. Antegrade stent placement involves transhepatic puncture, passage of a guidewire across the obstruction, and passage of a

**Fig. 1.** EUS-guided hepaticogastrostomy in a patient with necrotizing pancreatitis and biliary obstruction due to extrinsic compression, failed ERCP due to duodenal obstruction. **a** Initial puncture through gastric wall and cholangiogram showing distal bile duct obstruction. **b** After placement of transgastric fully covered self-expandable metal biliary stent into left hepatic duct.



**Fig. 2.** EUS-guided choledochoduodenostomy in a patient with malignant biliary and duodenal obstruction. **a** Echoimage of markedly dilated CBD prior to placement of luminal apposing metal stent. **b** Echoimage immediately after deployment of 8 mm diameter luminal apposing metal stent into distal CBD. **c** Follow-up CT for continued care. Sagittal image shows luminal apposing stent with plastic stent within at site of choledochoduodenostomy.

stent antegrade across the obstruction such that the entire stent is within the biliary tree. If technical failure occurs, antegrade stenting can be converted to transmural or PTBD [2]. In general, direct transmural drainage is preferred using a hepaticogastrostomy (HGS) or choledochoduodenostomy (CDS) approach. Antegrade stenting, performed by placing an internal stent transhepatically, has fallen out of favor as it can be cumbersome with only a 77% technical success rate [22].

HGS typically involves creating an anastomosis between the lesser curvature of the stomach and a dilated left intrahepatic duct using a partially or fully covered self-expanding metal stent (SEMS) (Fig. 1) [23]. Meanwhile, CDS involves tract formation between the duodenal bulb and common bile duct with placement of a SEMS or lumen apposing metal stent (LAMS) (Fig. 2) [24]. Of note, luminal access points for transhepatic biliary drainage can also include the esophagus and jejunum [20].

**Table 1.** Comparison of HGS versus CDS

	CDS	HGS
Technical considerations	Long endoscope position in duodenal bulb	Dilated intrahepatic duct of approximately 4 mm is required
Clinical benefits	Smaller diameter (6 or 8 mm) cautery-enhanced LAMs make procedure technically easier	Does not interfere with surgical resection Multiple luminal access points
Limitations	Difficulty managing stent misdeployment Might interfere with pancreaticoduodenectomy (Whipple) May be more stent occlusion due to food, particularly in GOO	Technically more challenging Lack of dedicated stents in most countries

Transhepatic and transduodenal drainage methods have been extensively compared [25–36] with similar rates of technical and clinical successes based on three recent meta-analysis [37–39]. A recent international multicenter study of 182 patients (HGS 95 vs. CDS 87) found that technical success was 92% in both groups, while clinical success was slightly higher in the CDS cohort (100 vs. 86%) [36]. The authors found that CDS was associated longer term stent patency at the expense of slightly higher AEs [36]. Another multicenter randomized trial comparing HGS ( $n = 24$ ) to CDS ( $n = 23$ ) reported a technical success rate of 100% and 95.7%, respectively [35]. They found no differences in stent patency or AEs. Based on their results, the authors felt that switching between either procedure can be considered when technical challenges arise.

At the moment, there is no standardized algorithm between the two techniques. EUS-guided transhepatic drainage is the first-line method for patients with surgically altered anatomy or hilar obstruction (Table 1). Our recent single-center retrospective study of 215 patients primarily utilized a transgastric approach in 188 cases, where we reported a technical and clinical success rate of 85.3% and 87.25, respectively [20]. Advantages to transhepatic drainage are that in the event of complete stent misdeployment, the peritoneal space involving HGS may be easier to manage in the event of emergency surgery [20]. Additionally, the HGS location may allow for easier surgical resection of the duodenum (during Whipple operation for pancreas head cancer) in operative candidates. We do recognize that this is a technically difficult procedure and use in the community is likely impracticable.

There is evidence supporting the use of EUS-BD as the primary method for biliary decompression in instances of malignant biliary obstruction [22]. Three randomized controlled trials comparing EUS-BD to ERCP found no major differences in technical or clinical success rates

[40–42]. That being said, a meta-analysis of these studies found that EUS-BD was linked to a lower rate of stent dysfunction, which leads to less interruption in oncological treatment plans [43]. Similarly, a recent meta-analysis of 5 studies involving 361 patients, found that ERCP was associated with higher rates of reintervention (22.6 vs. 15.2%) and tumor overgrowth (odds ratio 5.3) [44]. While there was no difference in overall survival, one study showed that quality of life was higher in the EUS group [41]. At the moment, larger comparative studies are needed to determine if avoiding transpapillary stenting can influence oncologic treatment outcomes.

#### *EUS Drainage of Pancreatic Ductal Obstruction*

EUS-guided pancreatic duct drainage (EUS-PDD) is a technically complex procedure associated with a high rate of AEs [2]. It is indicated when ERCP fails (3–10% of cases) or is not possible in cases of SAA [1]. While surgery is superior for long-term symptomatic relief of chronic pancreatitis [45], not all patients are ideal operative candidates and some may prefer a minimally invasive alternative. Main pancreatic duct (MPD) obstruction can result from chronic pancreatitis, pancreatojejunostomy anastomotic strictures, congenital anomalies, or disconnected pancreatic duct syndrome; these etiologies can result in significant patient discomfort and/or bouts of acute recurrent pancreatitis due to underlying ductal and interstitial hypertension [46]. At this juncture, EUS-PDD can be utilized to provide decompressive therapy.

The two approaches include RV-assisted endoscopic retrograde pancreatography (RV-ERP) or EUS-antegrade. In terms of safety and efficacy, RV-ERP is favored, while an antegrade approach is typically employed when RV-ERP is technically unsuccessful or not possible [1, 2, 47]. A 19-gauge needle is preferred to create a transgastric to MPD access point – the MPD diameter should be  $\geq 4$  mm [2]. In cases of SAA, a transenteric route can also be

used [46]. Assuming there is an endoscopically accessible native papilla (or anastomosis), a guidewire can be passed in an antegrade fashion in order to perform a ERP. Compared to a transmural approach, the RV-ERP method preserves anatomy and may provide better physiological drainage of the ductal stricture [1, 48]. Furthermore, avoiding the need for thermal energy or tract dilation to create a fistula may reduce the risk of bleeding, pancreatic leakage, and gastric leakage into the retroperitoneal space [1]. Yet, when direct drainage is required, cautery and non-cautery transmural stent placement can be accomplished via an EUS-antegrade fashion.

While there are limited head-to-head studies, RV-ERP is universally considered the first method used followed by EUS-antegrade. A large retrospective study demonstrated improved technical success with ERP-RV (95.6%) versus transgastric pancreaticogastrostomy (77.8%) with an added benefit of a lower rate of AEs [49]. As salvage therapy, antegrade drainage has demonstrated pooled technical and clinical success rates of 89% and 87%, respectively [46]. The critical step of creating a pancreaticogastrostomy is dependent upon successful stent placement through the tract. There are no standardized techniques, though we prefer to use a 19G needle, a 0.025" diameter  $\times$  450 cm long biliary guidewire, avoidance of cautery whenever possible, and least possible dilation of the tract to achieve the desired stent placement. In terms of stent placement, plastic stents are preferential due to ease of placement, which may reduce AEs in the event of stent dislodgement [50]. In one study fully covered SEMS were placed in 25 technically successful cases; no stent migration occurred and mean stent patency was 127 days [51]. There has been a case report using LAMS and a double-pigtail plastic stent [52], though more data are needed to determine patient selection. A recent study utilized a technique to reduce the risk of leakage and stent migration by dilating the pancreaticogastrostomy tract to 4 Fr using an angioplasty balloon and placing a 3-Fr stent with the pigtail in the pancreatic duct and the straight end extending at least 3 cm into the gastric lumen [53]. The authors reported an 88% technical and 62.5% clinical success rate with no instances of stent-related AEs [53].

While the optimal stent type is being investigated, the need for antegrade stent exchange following pancreaticogastrostomy is still debated among centers. Since drainage is occurring through the gastric wall without an intervening stricture, the need for repeat stent exchange of the MPD can be determined based on clinical/radiographic features or as a standard caliber upsizing procedure after the index endoscopy. An early retrospective

study of 36 patients undergoing EUS-guided pancreaticogastrostomy and pancreatobulbostomy found that 55% of patients experienced stent obstruction or migration over a median 14.5-month follow-up period requiring 29 repeat endoscopies [54]. Based on their findings, the authors recommended a proactive stance for stent exchange/upsizing using the existing transmural fistula. However, another group found that only 15% (4/26) of their patients experienced stent dislocation over a median follow-up of 9.5 months [55]. The authors supported watchful waiting in the absence of symptoms and radiologic confirmation of stent placement. A recent technical review recommended an elective stent exchange in order to widen the fistula as means to facilitate additional endoscopic therapy through the tract [46]. In light of these different approaches, we believe that the existing tract can be used  $\geq 4$  weeks after the initial procedure when the tract has matured [56].

The technical difficulties related to antegrade approach limit its use to expert centers. One study suggested that the learning curve for efficiency (i.e., reduction in procedure time), and proficiency were seen following the 27th and 40th cases when performed by a single operator [57]. However, these results are not generalizable given the expertise of that highly experienced endoscopist. With the current available studies, the AE rates of EUS-PDD range from 12 to 15% [46, 58]. The majority of these consist of abdominal pain, bleeding, infection, pancreatitis, and perforation and are recognized immediately or early post-procedurally [2]. While some studies have reported higher AEs than cited above, the heterogeneity of patients, and use of varying equipment and techniques make it difficult to compare and analyze these findings [46]. Moving forward, we believe that pancreatic ductal drainage may evolve to the use of small-diameter CMSEMS (6 mm) that will reduce the risk of leakage and bleeding.

#### *EUS-Guided Gastroenterostomy for Gastric Outlet Obstruction*

Malignant gastric outlet obstruction (GOO) is a mechanical obstruction that can extend from the pylorus or proximal duodenum to the third duodenum. Symptoms range from early satiety to intractable nausea, vomiting, and abdominal pain which result in nutritional deficiencies and poor quality of life [59]. As a result, these patients may also experience significant delays in administration of chemotherapy. Traditionally, bypassing this obstruction was achieved with a surgical gastrojejunostomy (S-GJ) or placement of an enteral self-expandable

**Table 2.** Comparing early versus late drainage of pancreatic fluid collections

First author, year	Study design	Total number of subjects (early vs. late drainage)	Mortality, early versus late drainage, %	Necrosectomy, early versus late drainage, %	Number endoscopic interventions needed for infected necrosis	Total complication rates, %	Length of stay, days
Boxhoorn, 2021 [79]	Multicenter, randomized trial	104 (55 ED vs. 49 LD)	13 versus 10	51 versus 22	4.4 versus 2.6*	76 versus 82	59 versus 51
Rana, 2021 [78]	Single-center, retrospective	170 (34 ED vs. 136 LD)	5.7 versus 0	50 versus 7.4	6 versus 3.1	20 versus 1.5**	N/A
Obizajek, 2020 [82]	Single-center, retrospective	38 (19 ED vs. 19 LD)	0 versus 0	58 versus 79	4 versus 3	21 versus 32	26 versus 6
Trikudanathan, 2018 [80]	Single-center, retrospective	193 (76 ED vs. 117 LD)	13.2 versus 4.3	6.9 versus 0.9	1 versus 1	20.6 versus 18.24***	37 versus 26
Chantarojanasiri, 2018 [81]	Single-center, retrospective	35 (12 ED vs. 23 LD)	8 versus 4	50 versus 69.5	1 versus 9	25 versus 21.7	27.5 versus 31

ED, early drainage; LD, late drainage. \* Included surgical, endoscopic, and radiologic interventions. \*\* Only post-procedure bleeding reported. \*\*\*No difference in total AEs, including stent dysfunction, bleeding, fistulae, and new onset diabetes. There were 7 cases of perforation in LD and none with ED.

metal stent (SEMS). However, both methods are somewhat limiting. While a S-GJ can provide longer palliation than SEMS, its use is offset by the high morbidity and mortality associated with surgery in already frail patients with a poor performance status [60]. Meanwhile, enteral stenting (with SEMS) can produce comparable clinical results, yet these benefits are short-lived due to recurrent obstruction that occurs in 50% of patients within 6 months [59, 61]. The goal for managing GOO is to relieve the obstruction and allow patients to resume peroral intake.

In this context, the application of EUS-guided gastroenterostomy (GE) is a safe and effective, minimally invasive alternative with comparable outcomes and fewer re-interventions compared to enteral stenting [62] and S-GJ [63], when performed by expert endoscopists. This is especially beneficial for patients with end-stage malignancy who are not surgical candidates. A handful of studies have explored outcomes in both benign and malignant GOO with technical and clinical success rates ranging from 87 to 100% and 84 to 92%, respectively [30, 63–66]. The ability to provide durable symptomatic relief may also be enhanced by the use of larger LAMS (20 mm) which may decrease the risk of re-obstruction and allow patients to tolerate a more regular diet [67].

When performing EUS-GE, there are various technical approaches that have been well documented in the literature, including antegrade traditional/downstream method, antegrade RV method, retrograde enterogastrostomy, EUS balloon-occluded GE bypass, direct method, and wireless/water-filling technique [68, 69]. A recent retrospective study analyzed the water-filling technique in 107 patients across three European centers with a technical success, clinical success, and AE rate of 94%, 91%, and 10%, respectively [70]. At our center, we place a nasobiliary tube at or just beyond the ligament of Treitz to distend the duodenum using a standard irrigation system as used for luminal endoscopy. After injection of glucagon to paralyze the bowel, we place a 20 mm LAMS with enhanced electrocautery tip using a “freehand” technique. At the moment, there is no method that has proven superior and comparative studies are needed to determine which approach may limit AEs.

As EUS-GE becomes more widely used, we expect this technique to become a more widely used as a therapeutic method that may potentially replace surgery as a first-line option. Indeed, in our practice, we have largely abandoned enteral SEMS in favor of EUS-GE, except in patients with a life-expectancy inferior to 3 months and those with large volume ascites.

### *EUS-Guided Drainage of Necrotizing Pancreatic Fluid Collections*

Therapeutic EUS has also found a role in ESGE guidelines for managing complications of acute necrotizing pancreatitis by facilitating transmural drainage necrotic pancreatic fluid collections [71]. Acute pancreatitis is common cause of hospitalization, with annual costs exceeding USD 2 billion, where up to 20% of patient develop severe (necrotizing) pancreatitis [72]. Necrotizing pancreatitis, a feared sequel, is associated with a significant morbidity and mortality – especially when infection is present [73]. Infected and symptomatic fluid collections require multidisciplinary treatment [74]. Drainage and debridement are recommended once the collection encapsulates and matures, which typically takes >4 weeks [75]. With advancements in EUS, there has been a paradigm shift in endoscopically managing these collections, instead of traditional surgical necrosectomy [76]. Percutaneous drainage alone is often avoided whenever possible due to the risk of pancreatocutaneous fistula formation. The last author of this review pioneered early work in this setting, over the past few years EUS drainage of pancreatic fluid collections has evolved to the use of LAMS, with the large diameters (15 and 20 mm) for management of WON. Patients with lower percentages of necrotic debris by volume, those with collections less than 10 cm in size and lack of paracolic extension can often avoid the need for additional interventions such as direct endoscopic necrosectomy [77].

Studies have sought to compare early versus late drainage of infected, necrotic pancreatic collections when clinically indicated (Table 2) [78–82]. Overall these studies reported somewhat similar rates of AEs, though the early drainage groups appeared to require more reinterventions [78–82]. A recent meta-analysis of 6 studies with 630 patients reported no significant differences in technical success, clinical success, mortality, or overall AEs in early ( $n = 182$ ) versus standard ( $n = 448$ ) drainage groups [83]. The implementation of LAMS has seemingly revolutionized management by simplifying the technical aspects to potentially limit AEs. Also, the significantly larger stent diameters (15 or 20 mm) can improve drainage and decrease the number of endoscopic sessions needed [84]. A recent study comparing EUS-guided drainage with plastic stents ( $n = 138$ ) and LAMS ( $n = 28$ ) found no differences in mortality, complications, or resolution rates but did note LAMS were associated with a shorter time to resolution [78]. Yet, another comparative study between LAMS ( $n = 78$ ) and traditional cystoenterostomy ( $n = 78$ ) reported a faster resolution time favoring LAMS

(86.9 vs. 133.6 days) [85]. The introduction of a larger, 20 mm LAMS, can further reduce the need for endoscopic necrosectomy [86].

### *EUS-Guided Ablation of Pancreatic Neoplasms*

EUS-guided ablation of pancreatic cystic neoplasms has evolved as a reliable minimally invasive option – especially in patients who are poor surgical candidates. With the advent of improved cross-sectional imaging, incidental findings of pancreatic cysts are rising with no overall change in mortality [87]. Pancreatic cystic neoplasms represent a broad spectrum of clinicopathological lesions with varying degrees of malignant potential. Stratifying these lesions based on their malignant potential and presence of symptoms dictates management options i.e. surveillance versus resection [88]. In patients who require treatment, surgical resection is often associated with a high morbidity and mortality; furthermore, some patients may not be ideal operative candidates or decline surgery. It is in this setting where EUS-guided ablation techniques have emerged as an alternative treatment option [89]. Cyst ablation can be performed by injecting ablative agents (ethanol or paclitaxel) or through radiofrequency ablation (RFA). Ablation is indicated for a presumed mucinous cystadenoma or intraductal papillary mucinous neoplasms (IPMNs) that are unilocular or oligolocular, as well as cyst >3 cm or enlarging cyst with a diameter >2 cm [90]. Typically cyst measuring 2–6 cm with fewer than 6 locules respond best to ablation [90, 91]. The cyst is accessed through a transgastric or transduodenal approach where a 22 gauge or 19-gauge fine needle aspiration is used to evacuate the cyst cavity before lavage with the ablative agent takes place [89].

EUS-ablation with ethanol was first used in 2005 as a means to destroy epithelial lining through cell membrane lysis, vascular occlusion and protein denaturation with complete and partial resolution rates ranging from 9% to 78% and 14–40%, respectively [92–95]. This wide range of result was likely influenced by varying study designs, heterogeneity of cyst treated and differing concentrations of ethanol used (80–100%). In addition to varied results, the AEs associated with ethanol ablation, i.e., abdominal pain and acute pancreatitis occur not uncommonly ranging from 3.3% to 33.2% [88].

The addition of paclitaxel, a chemotherapeutic agent, has been found to improve complete cyst resolution up to 79% (Table 3) [90]. Paclitaxel was initially used following ethanol lavage in 2008 [93], whereby its hydrophobic and viscus properties were thought to reduce the chances of leaking and providing a longer duration of ablation in the

**Table 3.** Summary of EUS-guided ethanol and paclitaxel ablation studies

Author, year	Study design	Total subjects (types of cysts, %)	Mean diameter, mm	Ablative agent used	Median follow-up, months	Complete resolution	AEs (n)
Oh, 2008 [93]	Prospective, single center, pilot	14 (MCN 14%, SCA 2%, lymphangioma 21%, unknown 43%)	22.5	Ethanol 88–99% + paclitaxel	9	79%	Pancreatitis (1), abdominal pain (1), hyperamyloasemia (6)
Oh, 2009	Prospective, single center	10 (MCN 30%, SCA 40%, unknown 30%)	29.5	Ethanol 99% + paclitaxel	8.5	60%	Pancreatitis (1)
Oh, 2011	Prospective, single center	52 (MCN 17%, SCA 29%, PC 4%, unknown 50%)	31.8	Ethanol 99% + paclitaxel	21.7	62%	Pancreatitis (1), splenic vein obliteration (1)
DeWitt, 2014 [92]	Prospective, single center	22 (IPMN 55%, MCN 27%, SCA 18%)	25	Ethanol 99% + paclitaxel	27	50%	Abdominal pain (4), pancreatitis (3), peritonitis (1), gastric wall cyst (1)
Moyer, 2016 [98]	Prospective, single center, RCT, pilot	10 (IPMN 30%, MCN 70%)	30	Ethanol 80% (5) or saline (5) followed by paclitaxel + gemcitabine	6 and 12	Ethanol arm: 6 months: 50%; 12 months 75%, ethanol-free arm: 6 months 67%; 12 months 67%	Ethanol arm: pancreatitis (1), ethanol-free arm: none
Moyer, 2017	Prospective, RCT	39 (IPMN 69%, MCN 23%, indeterminate 8%)	25	Ethanol 80% (18) or saline (21) followed by paclitaxel + gemcitabine	12	Ethanol: 61%, ethanol free: 67%	Ethanol: abdominal pain (4), ethanol free: none
Kim, 2017	Prospective, single center	36 (BD-IPMN 39%, MCN 44%, SCA 14%, PC 3%)	25.8	Ethanol 100% (8) or ethanol 100% + paclitaxel (28)	22.3	56%	Pancreatitis (4), abdominal pain (4), intracystic hemorrhage (1)
Choi, 2017	Prospective, single center	164 (IPMN 6.7%, MCN 43%, SCA 9.7%, PC 1.8%, indeterminate 38.4%)	32	Ethanol + paclitaxel	72	72%	Pancreatitis (6), PCs (2), abscess (2), intracystic hemorrhage (1), pericystic spillage (1), pancreatic duct stricture (1), splenic vein obstruction (1), portal vein thrombosis (1)

RCT, randomized control trial; SCA, serous cystadenomas; MCNs, mucinous cystic neoplasms; IPMNs, intraductal papillary mucinous neoplasms; BD, branch duct; PC, pseudocyst.



cyst itself through microtubule inhibition [89]. The synergistic effects of ethanol and paclitaxel were promising, and one study found that post-ablation neoplastic DNA mutations were disrupted and eliminated in 72% of cases [92]. Compared to ethanol ablation alone, post-ablation AEs (15 vs. 21.7%) and complete resolution rates (63.6 vs. 32.8%) are significantly improved using paclitaxel-based regimens [96]. There was a concern that post-procedural acute pancreatitis (3.3–9.8%) was associated with ethanol extravasation into the pancreatic parenchyma [88]. In an effort to determine the safety and efficacy of alcohol-free ablation, a prospective double-blind randomized trial (known as the CHARM trial) compared an admixture of paclitaxel and gemcitabine with or without 80% ethanol in a cohort of 39 patients with mucinous-type cysts [97]. The investigators found that there was no major difference in complete resolution rates (61% with and 67% without ethanol) with an added benefit of no AEs experienced in the alcohol-free cohort. In order to validate these findings on larger scale, the CHARM II trial is currently underway with an expected study completion date in April 2023 [98].

Alternatively, RFA can be performed through electromagnetic energy and high-frequency alternating currents via mono- or bipolar probe, using an echogenic 19-gauge needle tip, that can induce cell death by causing coagulative necrosis, hyperthermic injury, and a delayed immune response to the cyst in question [88, 89]. When this energy is transmitted to the targeted lesion, echogenic bubbles can be visualized on EUS. Only a handful of studies have explored RFA as means to treat pancreatic cysts and pancreatic neuroendocrine tumors (pNETs) with promising results [99–101]. A recent meta-analysis found that location of a pNET in the pancreatic head/neck was a positive predictor of clinical success [102]. The meta regression reported a pooled clinical success and AE rate of 85.2% and 14.1%, respectively [102]. A prospective multicenter study including 16 IPMNs, 14 pNETs, and 1 mucinous cyst adenoma reported a very low AE rate (only two events occurring in the first 2 patients treated), which was virtually eliminated when prophylactic measures (i.e., antibiotics, rectal diclofenac and cyst aspiration before RFA) were taken [99]. Of note, in regards to pNETs, the best results appear to be for treatment of insulinomas and non-functional pNETs  $\leq 2$  cm.

Still in its infancy, EUS-guided ablation may prove useful in selected patients with high risk or symptomatic pancreatic cysts, further studies will be needed to determine if there is a cost saving and/or mortality reducing component. In patients who are not surgical candidates,

it is possible that EUS-guided ablation could alter surveillance recommendations moving forward, though comparative studies are needed. In current guidelines, EUS-guided cyst ablation should not be performed outside a dedicated investigation protocol.

#### *EUS-Guided Coil Embolization*

While esophageal varices are more common, GVs are associated with severe bleeding, higher mortality rates, and rebleeding episodes [103]. The therapeutic endoscopic armamentarium for GV is somewhat limited, though in recent years EUS methods have found a role in managing these serious bleeds. Injecting cyanoacrylate glue has traditionally been used to resolve acute bleeding and provide secondary prophylaxis. Yet, bleeding is influenced by the size and wall tension of the varix, and endoscopic injection of glue does not always allow for full visualization, which can increase the risks of rebleeding. Furthermore, this technique is technically challenging and associated with severe AEs, including systemic embolization [104]. Other disadvantages include inadvertent unroofing of the varix, deep ulcerations at the injection site, and damage to the endoscope itself [105].

In this context, EUS-guided injection provides unique luminal views that can fully characterize the varix and confirm obliteration on doppler ultrasound while reducing the risks of glue embolization (Fig. 3) [106]. Utilizing this approach, EUS-guided coil embolization has been investigated as an additional hemostatic method that promotes clot formation [104]. In a large study of 152 patients, combination therapy with cyanoacrylate glue and coils was technically successful in 99% of cases with only three episodes of post-treatment bleeding [107]. The coils serve as a scaffold with synthetic fiber that contains and minimizes the amount of glue needed [108]. Compared to glue injection alone, combination therapy requires fewer endoscopic sessions while limiting AEs [109]. A recent randomized trial compared combination (cyanoacrylate plus coil) therapy ( $n = 30$ ) to coil monotherapy ( $n = 30$ ) and found that combination therapy led to significantly higher rates of obliteration (86.7 vs. 13.3%) with lower rates of rebleeding or reintervention needed [110].

In an effort to further describe the benefits of combination therapy, a recent meta-analysis of 11 studies with 536 patients, confirmed that combination therapy resulted in higher rates of technical and clinical success compared to cyanoacrylate alone [111]. In terms of AEs, combination therapy and coil monotherapy demonstrated comparable results (10 vs. 3%), while cyanoacrylate injec-

tion was associated with a 21% adverse event rate [111]. Interestingly, recent studies have postulated the replacement of glue with an absorbable gelatin sponge (AGS), which is typically used as a hemostatic agent in interventional radiology and surgical procedures [105, 112, 113]. The AGS is a purified water-insoluble plug that can absorb 45 times its volume in blood [105, 112, 113]. An added benefit is that it is not associated with post-treatment ulceration and cannot damage the endoscope. In a matched cohort study, the use of coil embolization plus AGS was superior to glue injection alone in terms of lower rebleeding rates, transfusion requirements and rates with up to 9 months of follow-up [112]. The authors added that in their cohort they used more coils (~8 per case) compared to 1–3 coils used in a prior study [114]. Their thought process was that using a significantly larger coil volume could aggressively obliterate feeder vessels at multiple vascular points [112]. While this technique is promising, AGS is not FDA approved and is therefore limited in use.

Another alternative is the use of thrombin injection, which can achieve hemostasis by converting fibrinogen to fibrin thereby promoting clot production and platelet aggregation [115]. One study by Frost and Hebbar [115] demonstrated the feasibility and efficacy of this approach using an EUS-guided injection technique. The authors treated 5 patients for primary prophylaxis and three with active bleeding using EUS-thrombin – and found that only 1 patient with active bleeding failed to achieve hemostasis [115]. There were no AEs. Another randomized control trial (RCT) by Lo et al. [116] compared endoscopic thrombin ( $n = 33$ ) to cyanoacrylate ( $n = 35$ ) and found that both groups had similar rates of hemostasis, but the thrombin cohort experienced lower rates of AEs (12 vs. 51%) with no instances of gastric ulceration. Other added benefits of thrombin are the excellent safety profile (minimal risk of embolism or ulceration compared to glue injection) and ease of use. Additional EUS-guided studies are needed to determine its role in variceal hemorrhage.

The rapid adaptation of EUS-guided coil embolization is emerging as a promising treatment option for GV. The ability to decrease complications while maintain effective hemostasis should reduce the costs associated with GV bleeding, though further studies will be needed.

#### *EUS-Guided Gallbladder Drainage for Acute Cholecystitis*

EUS-guided gallbladder drainage (EUS-GBD) has also emerged as novel and clinically useful management option in patients with symptomatic cholelithiasis and/

or acute cholecystitis who are not optimal surgical candidates. In instances of acute cholecystitis, early laparoscopic cholecystectomy remains the gold standard [117]. However, patients with advanced age, poor performance status, significant comorbidities, or prior abdominal surgery causing adhesions may be unfit for surgery due to high rates of morbidity and mortality [118]. A delay in surgery can increase the risk of gallstone-related complications by 14% at 6 weeks, 19% at 12 weeks, and 29% at 1 year [119]. Thus, providing alternative routes of decompression via a percutaneous or endoscopic approach have been investigated. Traditionally, a percutaneous cholecystostomy has been performed, though tube maintenance, dysfunction and patient discomfort are often challenging for patients [118]. A percutaneous approach may worsen a patient's quality of life, while also increasing costs associated with long-term care issues related to readmissions and reinterventions, with AEs ranging from 4% to 51% [120].

Since its first description in 2007 by Baron and Topazian, EUS-GBD has rapidly evolved with improved clinical outcomes following the introduction of LAMS [121]. Over time, the use of plastic stents, SEMS, and then LAMS has led to ongoing technical and clinical success with a dramatic reduction in AEs (18.2% plastic stent, 12.3% SEMS, 9.9% LAMS) [122]. When compared to percutaneous drainage, EUS-GBD serves an opportunity to treat poor surgical candidates through a minimally invasive approach that lowers rates of reintervention and unplanned readmissions [120, 123–126]. Two recent comparative meta-analyses found no difference in technical or clinical success; however, they demonstrated that EUS-GBD was associated with lower AEs, shorter hospital stays, and fewer reinterventions which lead to decreased readmissions [120, 124]. Similar findings were seen in a randomized control trial of 80 patients undergoing EUS or percutaneous gallbladder drainage in high risk surgical candidates [123]. It has also been associated with significantly lower post-procedural pain [126].

When compared to the gold standard (laparoscopic cholecystectomy), a propensity score analysis found that EUS-GBD was comparable (technical success 100 vs. 100%, clinical success 93.3 vs. 100%, 30 day AEs 13.3 vs. 10%) – suggesting this method can be considered as a reliable alternative in patients who are not ideal operative candidates [127]. It has also been studied in 15 patients with cirrhosis (average MELD  $15 \pm 7$ ) with a technical success rate of 93.3% and two AEs (1 mild, 1 severe) [128].

With increasing use of EUS-GBD with LAMS, higher risk patients are being treated. It is important to comment that with a permanent fistula created with LAMS a bridge to laparoscopic cholecystectomy may not be possible [118]. Though successful surgery has been documented in patients stented with plastic stents [129]. Future studies may yet demonstrate the feasibility of safe laparoscopic resection after LAMS placement, perhaps after resolution of inflammatory changes, endoscopic removal of LAMS, and fistula closure.

---

## Conclusion

Over the past 20-years therapeutic, EUS has catapulted itself as reliable therapeutic tool that has expanded the field of interventional gastroenterology. Translating theoretical implications into practical methods has allowed EUS-guided therapies to change practice management worldwide. We believe it is inevitable that EUS-guided transmural biliary drainage will be accepted as an alternative to ERCP for the relief of malignant biliary obstruction. Similarly, EUS-guided GE will also become the accepted treatment for relief of malignant GOO over S-GJ and endoscopic luminal stent placement. Yet, at the present time, a lack of standardized training and limited expertise will confine these techniques to high volume centers where multidisciplinary ancillary support is required.

---

## References

- 1 van der Merwe SW, van Wanrooij RLJ, Bronswijk M, Everett S, Lakhtakia S, Rimbas M, et al. Therapeutic endoscopic ultrasound: European Society of Gastrointestinal Endoscopy (ESGE) guideline. *Endoscopy*. 2022;54(2):185–205.
- 2 van Wanrooij RLJ, Bronswijk M, Kunda R, Everett SM, Lakhtakia S, Rimbas M, et al. Therapeutic endoscopic ultrasound: European Society of Gastrointestinal Endoscopy (ESGE) technical review. *Endoscopy*. 2022;54(3):310–32.
- 3 Dumonceau J-M, Tringali A, Papanikolaou IS, Blero D, Mangiavillano B, Schmidt A, et al. Endoscopic biliary stenting: indications, choice of stents, and results: European Society of Gastrointestinal Endoscopy (ESGE) Clinical Guideline: updated October 2017. *Endoscopy*. 2018;50(9):910–30.
- 4 Mukai S, Itoi T, Baron TH, Takada T, Strasberg SM, Pitt HA, et al. Indications and techniques of biliary drainage for acute cholangitis in updated Tokyo Guidelines 2018. *J Hepatobiliary Pancreat Sci*. 2017;24(10):537–49.
- 5 Nakai Y, Isayama H, Wang H-P, Rerknimitr R, Khor C, Yasuda I, et al. International consensus statements for endoscopic management of distal biliary stricture. *J Gastroenterol Hepatol*. 2020;35(6):967–79.
- 6 Teoh AYB, Dhir V, Kida M, Yasuda I, Jin ZD, Seo DW, et al. Consensus guidelines on the optimal management in interventional EUS procedures: results from the Asian EUS group RAND/UCLA expert panel. *Gut*. 2018;67(7):1209–28.
- 7 Andriulli A, Loperfido S, Napolitano G, Niro G, Valvano MR, Spirito F, et al. Incidence rates of post-ERCP complications: a systematic survey of prospective studies. *Am J Gastroenterol*. 2007;102(8):1781–8.
- 8 Peng C, Nietert PJ, Cotton PB, Lackland DT, Romagnuolo J. Predicting native papilla biliary cannulation success using a multinational Endoscopic Retrograde Cholangiopancreatography (ERCP) Quality Network. *BMC Gastroenterol*. 2013;13:147.
- 9 Halttunen J, Meisner S, Aabakken L, Arnelo U, Gronroos J, Hauge T, et al. Difficult cannulation as defined by a prospective study of the Scandinavian Association for Digestive Endoscopy (SADE) in 907 ERCPs. *Scand J Gastroenterol*. 2014;49(6):752–8.
- 10 Lee YS, Cho CM, Cho KB, Heo J, Jung MK, Kim SB, et al. Difficult biliary cannulation from the perspective of post-endoscopic retrograde cholangiopancreatography pancreatitis: identifying the optimal timing for the rescue cannulation technique. *Gut Liver*. 2021;15(3):459–65.
- 11 Saad WEA, Wallace MJ, Wojak JC, Kundu S, Cardella JF. Quality improvement guidelines for percutaneous transhepatic cholangiography, biliary drainage, and percutaneous cholecystostomy. *J Vasc Interv Radiol*. 2010;21(6):789–95.
- 12 Giovannini M, Moutardier V, Pesenti C, Borries E, Lelong B, Delperro JR. Endoscopic ultrasound-guided bilioduodenal anastomosis: a new technique for biliary drainage. *Endoscopy*. 2001;33(10):898–900.

---

## Statement of Ethics

This is an invited review article, as such ethics approval does not apply.

---

## Conflict of Interest Statement

Dr. Todd H. Baron is a consultant and speaker for Boston Scientific, W.L. Gore, Cook Endoscopy, and Olympus America. Dr. Andrew Canakis declares no relevant funding for this work. All authors disclosed no financial relationships.

---

## Funding Sources

None.

---

## Author Contributions

Andrew Canakis: performed research, collected, and wrote the paper. Todd H. Baron: designed the study and revised the paper. All authors approved the final version of the manuscript.

---

## Data Availability Statement

All data generated or analyzed during this study are included in this article. Further inquiries can be directed to the corresponding author.

- 13 Baniya R, Upadhaya S, Madala S, Subedi SC, Shaik Mohammed T, Bachuwa G. Endoscopic ultrasound-guided biliary drainage versus percutaneous transhepatic biliary drainage after failed endoscopic retrograde cholangiopancreatography: a meta-analysis. *Clin Exp Gastroenterol*. 2017;10:67–74.
- 14 Sportes A, Camus M, Greget M, Leblanc S, Coriat R, Hochberger J, et al. Endoscopic ultrasound-guided hepaticogastrostomy versus percutaneous transhepatic drainage for malignant biliary obstruction after failed endoscopic retrograde cholangiopancreatography: a retrospective expertise-based study from two centers. *Therap Adv Gastroenterol*. 2017; 10(6):483–93.
- 15 Lee TH, Choi JH, Park DH, Song TJ, Kim DU, Paik WH, et al. Similar efficacies of endoscopic ultrasound-guided transmural and percutaneous drainage for malignant distal biliary obstruction. *Clin Gastroenterol Hepatol*. 2016;14(7):1011–9.e3.
- 16 Attasaranya S, Netinasunton N, Jongboonyanuparp T, Sottisuporn J, Witeerungrot T, Pirathvisuth T, et al. The spectrum of endoscopic ultrasound intervention in biliary diseases: a single center's experience in 31 cases. *Gastroenterol Res Pract*. 2012;2012: 680753.
- 17 Poincloux L, Rouquette O, Buc E, Privat J, Pezet D, Dapoigny M, et al. Endoscopic ultrasound-guided biliary drainage after failed ERCP: cumulative experience of 101 procedures at a single center. *Endoscopy*. 2015; 47(9):794–801.
- 18 Oh D, Park DH, Song TJ, Lee SS, Seo DW, Lee SK, et al. Optimal biliary access point and learning curve for endoscopic ultrasound-guided hepaticogastrostomy with transmural stenting. *Therap Adv Gastroenterol*. 2017; 10(1):42–53.
- 19 Tyberg A, Mishra A, Cheung M, Kedia P, Gaidhane M, Craig C, et al. Learning curve for EUS-guided biliary drainage: what have we learned? *Endosc Ultrasound*. 2020;9(6):392–6.
- 20 Hathorn KE, Canakis A, Baron TH. EUS-guided transhepatic biliary drainage: a large single-center U.S. experience. *Gastrointest Endosc*. 2022;95(3):443–51.
- 21 Holt BA, Hawes R, Hasan M, Canipe A, Tharian B, Navaneethan U, et al. Biliary drainage: role of EUS guidance. *Gastrointest Endosc*. 2016;83(1):160–5.
- 22 Canakis A, Baron TH. Relief of biliary obstruction: choosing between endoscopic ultrasound and endoscopic retrograde cholangiopancreatography. *BMJ Open Gastroenterol*. 2020;7(1):e000428.
- 23 Ogura T, Higuchi K. Endoscopic ultrasound-guided hepaticogastrostomy: technical review and tips to prevent adverse events. *Gut Liver*. 2021;15(2):196–205.
- 24 Ogura T, Itoi T. Technical tips and recent development of endoscopic ultrasound-guided choledochoduodenostomy. *DEN Open*. 2021; 1:e8.
- 25 Artifon ELA, Marson FP, Gaidhane M, Kahaleh M, Otoch JP. Hepaticogastrostomy or choledochoduodenostomy for distal malignant biliary obstruction after failed ERCP: is there any difference? *Gastrointest Endosc*. 2015;81(4):950–9.
- 26 Kim TH, Kim SH, Oh HJ, Sohn YW, Lee SO. Endoscopic ultrasound-guided biliary drainage with placement of a fully covered metal stent for malignant biliary obstruction. *World J Gastroenterol*. 2012;18(20):2526–32.
- 27 Prachayakul V, Aswakul P. A novel technique for endoscopic ultrasound-guided biliary drainage. *World J Gastroenterol*. 2013;19(29): 4758–63.
- 28 Kawakubo K, Isayama H, Kato H, Itoi T, Kawakami H, Hanada K, et al. Multicenter retrospective study of endoscopic ultrasound-guided biliary drainage for malignant biliary obstruction in Japan. *J Hepatobiliary Pancreat Sci*. 2014;21(5):328–34.
- 29 Park DH, Lee TH, Paik WH, Choi JH, Song TJ, Lee SS, et al. Feasibility and safety of a novel dedicated device for one-step EUS-guided biliary drainage: a randomized trial. *J Gastroenterol Hepatol*. 2015;30(10):1461–6.
- 30 Khashab MA, Messallam AA, Penas I, Nakai Y, Modayil RJ, De la Serna C, et al. International multicenter comparative trial of transluminal EUS-guided biliary drainage via hepaticogastrostomy vs. choledochoduodenostomy approaches. *Endosc Int Open*. 2016;4(2):E175–81.
- 31 Guo J, Sun S, Liu X, Wang S, Ge N, Wang G. Endoscopic ultrasound-guided biliary drainage using a fully covered metallic stent after failed endoscopic retrograde cholangiopancreatography. *Gastroenterol Res Pract*. 2016; 2016:9469472.
- 32 Ogura T, Chiba Y, Masuda D, Kitano M, Sano T, Saori O, et al. Comparison of the clinical impact of endoscopic ultrasound-guided choledochoduodenostomy and hepaticogastrostomy for bile duct obstruction with duodenal obstruction. *Endoscopy*. 2016;48(2):156–63.
- 33 Amano M, Ogura T, Onda S, Takagi W, Sano T, Okuda A, et al. Prospective clinical study of endoscopic ultrasound-guided biliary drainage using novel balloon catheter (with video). *J Gastroenterol Hepatol*. 2017;32(3):716–20.
- 34 Cho DH, Lee SS, Oh D, Song TJ, Park DH, Seo DW, et al. Long-term outcomes of a newly developed hybrid metal stent for EUS-guided biliary drainage (with videos). *Gastrointest Endosc*. 2017;85(5):1067–75.
- 35 Minaga K, Ogura T, Shiomi H, Imai H, Hoki N, Takenaka M, et al. Comparison of the efficacy and safety of endoscopic ultrasound-guided choledochoduodenostomy and hepaticogastrostomy for malignant distal biliary obstruction: multicenter, randomized, clinical trial. *Dig Endosc*. 2019;31(5):575–82.
- 36 Tyberg A, Napoleon B, Robles-Medrandra C, Shah JN, Bories E, Kumta NA, et al. Hepaticogastrostomy versus choledochoduodenostomy: an international multicenter study on their long-term patency. *Endosc Ultrasound*. 2022;11(1):38–43.
- 37 Li J, Tang J, Liu F, Fang J. Comparison of choledochoduodenostomy and hepaticogastrostomy for EUS-guided biliary drainage: a meta-analysis. *Front Surg*. 2022;9:811005.
- 38 Mao K, Hu B, Sun F, Wan K. Choledochoduodenostomy versus hepaticogastrostomy in endoscopic ultrasound-guided drainage for malignant biliary obstruction: a meta-analysis and systematic review. *Surg Laparosc Endosc Percutan Tech*. 2021;32(1):124–32.
- 39 Uemura RS, Khan MA, Otoch JP, Kahaleh M, Montero EF, Artifon ELA. EUS-guided choledochoduodenostomy versus hepaticogastrostomy: a systematic review and meta-analysis. *J Clin Gastroenterol*. 2018;52(2):123–30.
- 40 Bang JY, Navaneethan U, Hasan M, Hawes R, Varadarajulu S. Stent placement by EUS or ERCP for primary biliary decompression in pancreatic cancer: a randomized trial (with videos). *Gastrointest Endosc*. 2018;88(1):9–17.
- 41 Paik WH, Lee TH, Park DH, Choi JH, Kim SO, Jang S, et al. EUS-guided biliary drainage versus ERCP for the primary palliation of malignant biliary obstruction: a multicenter randomized clinical trial. *Am J Gastroenterol*. 2018;113(7):987–97.
- 42 Park JK, Woo YS, Noh DH, Yang JI, Bae SY, Yun HS, et al. Efficacy of EUS-guided and ERCP-guided biliary drainage for malignant biliary obstruction: prospective randomized controlled study. *Gastrointest Endosc*. 2018; 88(2):277–82.
- 43 Miller CS, Barkun AN, Martel M, Chen YI. Endoscopic ultrasound-guided biliary drainage for distal malignant obstruction: a systematic review and meta-analysis of randomized trials. *Endosc Int Open*. 2019;7(11): E1563–73.
- 44 Kakked G, Salameh H, Cheesman AR, Kumta NA, Nagula S, DiMaio CJ. Primary EUS-guided biliary drainage versus ERCP drainage for the management of malignant biliary obstruction: a systematic review and meta-analysis. *Endosc Ultrasound*. 2020;9(5):298–307.
- 45 Ahmed Ali U, Pahlplatz JM, Nealon WH, van Goor H, Gooszen HG, Boermeester MA. Endoscopic or surgical intervention for painful obstructive chronic pancreatitis. *Cochrane Database Syst Rev*. 2015;3:CD007884.
- 46 Krafft MR, Nasr JY. Anterograde endoscopic ultrasound-guided pancreatic duct drainage: a technical review. *Dig Dis Sci*. 2019;64(7): 1770–81.
- 47 Chen YI, Levy MJ, Moreels TG, Hajjjeva G, Will U, Artifon EL, et al. An international multicenter study comparing EUS-guided pancreatic duct drainage with enteroscopy-assisted endoscopic retrograde pancreatography after Whipple surgery. *Gastrointest Endosc*. 2017;85(1):170–7.
- 48 Fujii-Lau LL, Levy MJ. Endoscopic ultrasound-guided pancreatic duct drainage. *J Hepatobiliary Pancreat Sci*. 2015;22(1):51–7.

- 49 Dalal A, Patil G, Maydeo A. Six-year retrospective analysis of endoscopic ultrasonography-guided pancreatic ductal interventions at a tertiary referral center. *Dig Endosc*. 2020; 32(3):409–16.
- 50 Khan Z, Hayat U, Moraveji S, Adler DG, Siddiqui AA. EUS-guided pancreatic ductal intervention: a comprehensive literature review. *Endosc Ultrasound*. 2021;10(2):98–102.
- 51 Oh D, Park DH, Cho MK, Nam K, Song TJ, Lee SS, et al. Feasibility and safety of a fully covered self-expandable metal stent with antimigration properties for EUS-guided pancreatic duct drainage: early and midterm outcomes (with video). *Gastrointest Endosc*. 2016;83(2):366–73.e2.
- 52 Gornals JB, Consiglieri C, Vida F, Loras C. Endoscopic ultrasound-guided pancreaticogastrostomy using a lumen-apposing metal stent plus a double-pigtail plastic stent. *Endoscopy*. 2016;48(Suppl 1):E276–7.
- 53 Hayat U, Freeman ML, Trikudanathan G, Azeem N, Amateau SK, Mallery J. Endoscopic ultrasound-guided pancreatic duct intervention and pancreaticogastrostomy using a novel cross-platform technique with small-caliber devices. *Endosc Int Open*. 2020;8(2):E196–202.
- 54 Tessier G, Bories E, Arvanitakis M, Hittelet A, Pesenti C, Le Moine O, et al. EUS-guided pancreatogastrostomy and pancreatobulbostomy for the treatment of pain in patients with pancreatic duct dilatation inaccessible for transpapillary endoscopic therapy. *Gastrointest Endosc*. 2007;65(2):233–41.
- 55 Will U, Reichel A, Fuedner F, Meyer F. Endoscopic ultrasonography-guided drainage for patients with symptomatic obstruction and enlargement of the pancreatic duct. *World J Gastroenterol*. 2015;21(46):13140–51.
- 56 James TW, Baron TH. Antegrade pancreatoscopy via EUS-guided pancreaticogastrostomy allows removal of obstructive pancreatic duct stones. *Endosc Int Open*. 2018;6:E735–8.
- 57 Tyberg A, Bodiwala V, Kedia P, Tarnasky PR, Khan MA, Novikov A, et al. EUS-guided pancreatic drainage: a steep learning curve. *Endosc Ultrasound*. 2020;9(3):175–9.
- 58 Basiliya K, Veldhuijzen G, Gerges C, Maubach J, Will U, Elmunzer BJ, et al. Endoscopic retrograde pancreatography-guided versus endoscopic ultrasound-guided technique for pancreatic duct cannulation in patients with pancreatojejunostomy stenosis: a systematic literature review. *Endoscopy*. 2021;53(3):266–76.
- 59 Carbajo AY, Kahaleh M, Tyberg A. Clinical review of EUS-guided gastroenterostomy (EUS-GE). *J Clin Gastroenterol*. 2020;54:1–7.
- 60 Takeno A, Takiguchi S, Fujita J, Tamura S, Imamura H, Fujitani K, et al. Clinical outcome and indications for palliative gastrojejunostomy in unresectable advanced gastric cancer: multi-institutional retrospective analysis. *Ann Surg Oncol*. 2013;20(11):3527–33.
- 61 Keane MG, Khashab MA. Malignant GOO: are duodenal stenting and surgical gastrojejunostomy obsolete? *Endosc Int Open*. 2020; 8(10):E1455–7.
- 62 Chen YI, Itoi T, Baron TH, Nieto J, Haito-Chavez Y, Grimm IS, et al. EUS-guided gastroenterostomy is comparable to enteral stenting with fewer re-interventions in malignant gastric outlet obstruction. *Surg Endosc*. 2017;31(7):2946–52.
- 63 Perez-Miranda M, Tyberg A, Poletto D, Toscano E, Gaidhane M, Desai AP, et al. EUS-guided gastrojejunostomy versus laparoscopic gastrojejunostomy: an international collaborative study. *J Clin Gastroenterol*. 2017; 51(10):896–9.
- 64 Chen Y-I, Kunda R, Storm AC, Aridi HD, Thompson CC, Nieto J, et al. EUS-guided gastroenterostomy: a multicenter study comparing the direct and balloon-assisted techniques. *Gastrointest Endosc*. 2018;87(5):1215–21.
- 65 Chen Y-I, James TW, Agarwal A, Baron TH, Itoi T, Kunda R, et al. EUS-guided gastroenterostomy in management of benign gastric outlet obstruction. *Endosc Int Open*. 2018; 6(3):E363–8.
- 66 Ge PS, Young JY, Dong W, Thompson CC. EUS-guided gastroenterostomy versus enteral stent placement for palliation of malignant gastric outlet obstruction. *Surg Endosc*. 2019; 33(10):3404–11.
- 67 Canakis A, Hathorn KE, Irani SS, Baron TH. Single session endoscopic ultrasound-guided double bypass (hepaticogastrostomy and gastrojejunostomy) for concomitant duodenal and biliary obstruction: a case series. *J Hepatobiliary Pancreat Sci*. 2022;29(8):941–9.
- 68 Bronswijk M, van Malenstein H, Laleman W, Van der Merwe S, Vanella G, Petrone MC, et al. EUS-guided gastroenterostomy: less is more! the wireless EUS-guided gastroenterostomy simplified technique. *VideoGIE*. 2020;5(9):442.
- 69 Irani S, Itoi T, Baron TH, Khashab M. EUS-guided gastroenterostomy: techniques from East to West. *VideoGIE*. 2019;5(2):48–50.
- 70 van Wanrooij RLJ, Vanella G, Bronswijk M, de Gooyer P, Laleman W, van Malenstein H, et al. Endoscopic ultrasound-guided gastroenterostomy versus duodenal stenting for malignant gastric outlet obstruction: an international, multicenter, propensity score-matched comparison. *Endoscopy*. 2022;54(11):1023–31.
- 71 Arvanitakis M, Dumonceau J-M, Albert J, Badaoui A, Bali MA, Barthet M, et al. Endoscopic management of acute necrotizing pancreatitis: European Society of Gastrointestinal Endoscopy (ESGE) evidence-based multidisciplinary guidelines. *Endoscopy*. 2018;50(5):524–46.
- 72 Trikudanathan G, Wolbrink DRJ, van Santvoort HC, Mallery S, Freeman M, Besselink MG. Current concepts in severe acute and necrotizing pancreatitis: an evidence-based approach. *Gastroenterology*. 2019;156(7):1994–2007.e3.
- 73 ASGE Standards of Practice Committee; Muthusamy VR, Chandrasekhara V, Acosta RD, Bruining DH, Chathadi KV, et al. The role of endoscopy in the diagnosis and treatment of inflammatory pancreatic fluid collections. *Gastrointest Endosc*. 2016;83(3):481–8.
- 74 Baron TH. Drainage for infected pancreatic necrosis: is the waiting the hardest part? *N Engl J Med*. 2021;385(15):1433–5.
- 75 Baron TH, DiMaio CJ, Wang AY, Morgan KA. American gastroenterological association clinical practice update: management of pancreatic necrosis. *Gastroenterology*. 2020; 158(1):67–75.e1.
- 76 van Santvoort HC, Besselink MG, Bakker OJ, Hofker HS, Boermeester MA, Dejong CH, et al. A step-up approach or open necrosectomy for necrotizing pancreatitis. *N Engl J Med*. 2010;362(16):1491–502.
- 77 Chandrasekhara V, Elhanafi S, Storm AC, Takahashi N, Lee NJ, Levy MJ, et al. Predicting the need for step-up therapy after EUS-guided drainage of pancreatic fluid collections with lumen-apposing metal stents. *Clin Gastroenterol Hepatol*. 2021;19(10):2192–8.
- 78 Rana SS, Sharma R, Kishore K, Dhalaria L, Gupta R. Safety and efficacy of early (<4 weeks of illness) endoscopic transmural drainage of post-acute pancreatic necrosis predominantly located in the body of the pancreas. *J Gastrointest Surg*. 2021;25(9):2328–35.
- 79 Boxhoorn L, van Dijk SM, van Grinsven J, Verdonk RC, Boermeester MA, Bollen TL, et al. Immediate versus postponed intervention for infected necrotizing pancreatitis. *N Engl J Med*. 2021;385(15):1372–81.
- 80 Trikudanathan G, Tawfik P, Amateau SK, Munigala S, Arain M, Attam R, et al. Early (<4 weeks) versus standard (≥4 weeks) endoscopically centered step-up interventions for necrotizing pancreatitis. *Am J Gastroenterol*. 2018;113(10):1550–8.
- 81 Chantarojanasiri T, Yamamoto N, Nakai Y, Saito T, Saito K, Hakuta R, et al. Comparison of early and delayed EUS-guided drainage of pancreatic fluid collection. *Endosc Int Open*. 2018;6(12):E1398–405.
- 82 Oblizajek N, Takahashi N, Agayeva S, Bazerbachi F, Chandrasekhara V, Levy M, et al. Outcomes of early endoscopic intervention for pancreatic necrotic collections: a matched case-control study. *Gastrointest Endosc*. 2020;91(6):1303–9.
- 83 Ramai D, Enofe I, Deliwala SS, Mozell D, Faciorusso A, Gkolfakis P, et al. Early (<4 weeks) versus standard (≥4 weeks) endoscopic drainage of pancreatic walled-off fluid collections: a systematic review and meta-analysis. *Gastrointest Endosc*. 2022;14:S0016–5107(22)02140-X.
- 84 Siddiqui AA, Kowalski TE, Loren DE, Khalid A, Soomro A, Mazhar SM, et al. Fully covered self-expanding metal stents versus lumen-apposing fully covered self-expanding metal stent versus plastic stents for endoscopic drainage of pancreatic walled-off necrosis: clinical outcomes and success. *Gastrointest Endosc*. 2017;85(4):758–65.

- 85 Ge PS, Young JY, Jirapinyo P, Dong W, Ryou M, Thompson CC. Comparative study evaluating lumen apposing metal stents versus double pigtail plastic stents for treatment of walled-off necrosis. *Pancreas*. 2020;49(2):236–41.
- 86 Parsa N, Nieto JM, Powers P, Mitsuhashi S, Abdelqader A, Hadzinakos G, et al. Endoscopic ultrasound-guided drainage of pancreatic walled-off necrosis using 20-mm versus 15-mm lumen-apposing metal stents: an international, multicenter, case-matched study. *Endoscopy*. 2020;52(3):211–9.
- 87 Elta GH, Enestvedt BK, Sauer BG, Lennon AM. ACG clinical guideline: diagnosis and management of pancreatic cysts. *Am J Gastroenterol*. 2018;113(4):464–79.
- 88 Canakis A, Lee LS. State-of-the-art update of pancreatic cysts. *Dig Dis Sci*. 2022;67(5):1573–87.
- 89 Canakis A, Law R, Baron T. An updated review on ablative treatment of pancreatic cystic lesions. *Gastrointest Endosc*. 2020;91(3):520–6.
- 90 Teoh AYB, Seo DW, Brugge W, Dewitt J, Kongkam P, Linghu E, et al. Position statement on EUS-guided ablation of pancreatic cystic neoplasms from an international expert panel. *Endosc Int Open*. 2019;7(9):E1064–77.
- 91 Bispo M, Caldeira A, Leite S, Marques S, Moreira T, Moutinho-Ribeiro P, et al. Endoscopic ultrasound-guided ablation of focal pancreatic lesions: the GRUPUGE perspective. *GE Port J Gastroenterol*. 2020;27(6):410–6.
- 92 DeWitt JM, Al-Haddad M, Sherman S, LeBlanc J, Schmidt CM, Sandrasegaran K, et al. Alterations in cyst fluid genetics following endoscopic ultrasound-guided pancreatic cyst ablation with ethanol and paclitaxel. *Endoscopy*. 2014;46(6):457–64.
- 93 Oh HC, Seo DW, Lee TY, Kim JY, Lee SS, Lee SK, et al. New treatment for cystic tumors of the pancreas: EUS-guided ethanol lavage with paclitaxel injection. *Gastrointest Endosc*. 2008;67(4):636–42.
- 94 Park JK, Song BJ, Ryu JK, Paik WH, Park JM, Kim J, et al. Clinical outcomes of endoscopic ultrasonography-guided pancreatic cyst ablation. *Pancreas*. 2016;45(6):889–94.
- 95 Gómez V, Takahashi N, Levy MJ, McGee KP, Jones A, Huang Y, et al. EUS-guided ethanol lavage does not reliably ablate pancreatic cystic neoplasms (with video). *Gastrointest Endosc*. 2016;83(5):914–20.
- 96 Attila T, Adsay V, Faigel DO. The efficacy and safety of endoscopic ultrasound-guided ablation of pancreatic cysts with alcohol and paclitaxel: a systematic review. *Eur J Gastroenterol Hepatol*. 2019;31:1–9.
- 97 Moyer MT, Sharzei S, Mathew A, Levenick JM, Headlee BD, BJT, et al. The safety and efficacy of an alcohol-free pancreatic cyst ablation protocol. *Gastroenterology*. 2017;153(5):1295–303.
- 98 Moyer MT. Charm II: chemotherapy for ablation and resolution of mucinous pancreatic cysts: a prospective, randomized, double-blind, multi-center clinical trial. [Clinical trial registration NCT03085004](https://clinicaltrials.gov/ct2/show/NCT03085004). [clinicaltrials.gov](https://clinicaltrials.gov/ct2/show/NCT03085004). 2021 Dec 7. Available from: <https://clinicaltrials.gov/ct2/show/NCT03085004>. (accessed 2022 Apr 4).
- 99 Barthelet M, Giovannini M, Lesavre N, Boustiere C, Napoleon B, Koch S, et al. Endoscopic ultrasound-guided radiofrequency ablation for pancreatic neuroendocrine tumors and pancreatic cystic neoplasms: a prospective multicenter study. *Endoscopy*. 2019;51(9):836–42.
- 100 Oleinikov K, Dancour A, Epshtein J, Benson A, Mazeh H, Tal I, et al. Endoscopic ultrasound-guided radiofrequency ablation: a new therapeutic approach for pancreatic neuroendocrine tumors. *J Clin Endocrinol Metab*. 2019;104(7):2637–47.
- 101 Pai M, Habib N, Senturk H, Lakhtakia S, Reddy N, Cicinnati VR, et al. Endoscopic ultrasound guided radiofrequency ablation, for pancreatic cystic neoplasms and neuroendocrine tumors. *World J Gastrointest Surg*. 2015;7(4):52–9.
- 102 Garg R, Mohammed A, Singh A, Harnegie MP, Rustagi T, Stevens T, et al. EUS-guided radiofrequency and ethanol ablation for pancreatic neuroendocrine tumors: a systematic review and meta-analysis. *Endosc Ultrasound*. 2022;11(3):170–85.
- 103 Wani ZA, Bhat RA, Bhadoria AS, Maiwall R, Choudhury A. Gastric varices: classification, endoscopic and ultrasonographic management. *J Res Med Sci*. 2015;20(12):1200–7.
- 104 DeWitt JM, Arain M, Chang KJ, Shariha R, Komanduri S, Muthusamy VR, et al. Interventional endoscopic ultrasound: current status and future directions. *Clin Gastroenterol Hepatol*. 2021;19(1):24–40.
- 105 Bazarbashi AN, Wang TJ, Thompson CC, Ryou M. Endoscopic ultrasound-guided treatment of gastric varices with coil embolization and absorbable hemostatic gelatin sponge: a novel alternative to cyanoacrylate. *Endosc Int Open*. 2020;8(2):E221–7.
- 106 Lee YT, Chan FK, Ng EK, Leung VK, Law KB, Yung MY, et al. EUS-guided injection of cyanoacrylate for bleeding gastric varices. *Gastrointest Endosc*. 2000;52(2):168–74.
- 107 Bhat YM, Weilert F, Fredrick RT, Kane SD, Shah JN, Hamerski CM, et al. EUS-guided treatment of gastric fundal varices with combined injection of coils and cyanoacrylate glue: a large U.S. experience over 6 years (with video). *Gastrointest Endosc*. 2016;83:1164–72.
- 108 Wang X, Yu S, Chen X, Duan L. Endoscopic ultrasound-guided injection of coils and cyanoacrylate glue for the treatment of gastric fundal varices with abnormal shunts: a series of case reports. *J Int Med Res*. 2019;47(4):1802–9.
- 109 Romero-Castro R, Ellrichmann M, Ortiz-Moyano C, Subtil-Inigo JC, Junquera-Florez F, Gornals JB, et al. EUS-guided coil versus cyanoacrylate therapy for the treatment of gastric varices: a multicenter study (with videos). *Gastrointest Endosc*. 2013;78(5):711–21.
- 110 Robles-Medranda C, Oleas R, Valero M, Puga-Tejada M, Baquerizo-Burgos J, Ospina J, et al. Endoscopic ultrasonography-guided deployment of embolization coils and cyanoacrylate injection in gastric varices versus coiling alone: a randomized trial. *Endoscopy*. 2020;52(4):268–75.
- 111 McCarty TR, Bazarbashi AN, Hathorn KE, Thompson CC, Ryou M. Combination therapy versus monotherapy for EUS-guided management of gastric varices: a systematic review and meta-analysis. *Endosc Ultrasound*. 2020;9(1):6–15.
- 112 Bazarbashi AN, Wang TJ, Jirapinyo P, Thompson CC, Ryou M. Endoscopic ultrasound-guided coil embolization with absorbable gelatin sponge appears superior to traditional cyanoacrylate injection for the treatment of gastric varices. *Clin Transl Gastroenterol*. 2020;11(5):e00175.
- 113 Ge PS, Bazarbashi AN, Thompson CC, Ryou M. Successful EUS-guided treatment of gastric varices with coil embolization and injection of absorbable gelatin sponge. *VideoGIE*. 2019;4:154–6.
- 114 Robles-Medranda C, Valero M, Nebel JA, de Brito Junior SR, Puga-Tejada M, Ospina J, et al. Endoscopic-ultrasound-guided coil and cyanoacrylate embolization for gastric varices and the roles of endoscopic Doppler and endosonographic varicealography in vascular targeting. *Dig Endosc*. 2019;31(3):283–90.
- 115 Frost JW, Hebbbar S. EUS-guided thrombin injection for management of gastric fundal varices. *Endosc Int Open*. 2018;6:E664–8.
- 116 Lo G-H, Lin C-W, Tai C-M, Perng DS, Chen IL, Yeh JH, et al. A prospective, randomized trial of thrombin versus cyanoacrylate injection in the control of acute gastric variceal hemorrhage. *Endoscopy*. 2020;52(7):548–55.
- 117 Mori Y, Itoi T, Baron TH, Takada T, Strasberg SM, Pitt HA, et al. Tokyo Guidelines 2018: management strategies for gallbladder drainage in patients with acute cholecystitis (with videos). *J Hepatobiliary Pancreat Sci*. 2018;25(1):87–95.
- 118 Law R, Baron TH. Endoscopic ultrasound-guided gallbladder drainage. *Gastrointest Endosc Clin N Am*. 2018;28(2):187–95.
- 119 de Mestral C, Rotstein OD, Laupacis A, Hoch JS, Zagorski B, Nathens AB. A population-based analysis of the clinical course of 10,304 patients with acute cholecystitis, discharged without cholecystectomy. *J Trauma Acute Care Surg*. 2013;74(1):26–30; discussion 30–1.

- 120 Luk SW-Y, Irani S, Krishnamoorthi R, Wong Lau JY, Wai Ng EK, Teoh AYB. Endoscopic ultrasound-guided gallbladder drainage versus percutaneous cholecystostomy for high risk surgical patients with acute cholecystitis: a systematic review and meta-analysis. *Endoscopy*. 2019;51(8):722–32.
- 121 Baron TH, Topazian MD. Endoscopic transduodenal drainage of the gallbladder: implications for endoluminal treatment of gallbladder disease. *Gastrointest Endosc*. 2007;65(4):735–7.
- 122 Anderloni A, Buda A, Vieceli F, Khashab MA, Hassan C, Repici A. Endoscopic ultrasound-guided transmural stenting for gallbladder drainage in high-risk patients with acute cholecystitis: a systematic review and pooled analysis. *Surg Endosc*. 2016;30(12):5200–8.
- 123 Teoh AYB, Kitano M, Itoi T, Perez-Miranda M, Ogura T, Chan SM, et al. Endosonography-guided gallbladder drainage versus percutaneous cholecystostomy in very high-risk surgical patients with acute cholecystitis: an international randomised multicentre controlled superiority trial (DRAC 1). *Gut*. 2020;69(6):1085–91.
- 124 Hemerly MC, de Moura DTH, do Monte Junior ES, Proenca IM, Ribeiro IB, Yvamoto EY, et al. Endoscopic ultrasound (EUS)-guided cholecystostomy versus percutaneous cholecystostomy (PTC) in the management of acute cholecystitis in patients unfit for surgery: a systematic review and meta-analysis. *Surg Endosc*. 2022.
- 125 Tyberg A, Saumoy M, Sequeiros EV, Giovannini M, Artifon E, Teoh A, et al. EUS-guided versus percutaneous gallbladder drainage: isn't it time to convert? *J Clin Gastroenterol*. 2018;52(1):79–84.
- 126 Irani S, Ngamruengphong S, Teoh A, Will U, Nieto J, Abu Dayyeh BK, et al. Similar efficacies of endoscopic ultrasound gallbladder drainage with a lumen-apposing metal stent versus percutaneous transhepatic gallbladder drainage for acute cholecystitis. *Clin Gastroenterol Hepatol*. 2017;15(5):738–45.
- 127 Teoh AYB, Leung CH, Tam PTH, Au YKKY, Mok RYC, Chan DL, et al. EUS-guided gallbladder drainage versus laparoscopic cholecystectomy for acute cholecystitis: a propensity score analysis with 1-year follow-up data. *Gastrointest Endosc*. 2021;93(3):577–83.
- 128 James TW, Krafft M, Croglio M, Nasr J, Baron T. EUS-guided gallbladder drainage in patients with cirrhosis: results of a multicenter retrospective study. *Endosc Int Open*. 2019;7(9):E1099–104.
- 129 Jang JW, Lee SS, Song TJ, Hyun YS, Park DH, Seo DW, et al. Endoscopic ultrasound-guided transmural and percutaneous transhepatic gallbladder drainage are comparable for acute cholecystitis. *Gastroenterology*. 2012;142(4):805–11.