

Metastatic Melanoma With Leptomeningeal Disease

AMANDA M. MARINOVA, MS, PA-C, JENNIFER L. REILLY, CRNP, BSN, MSN, RN, AANP, VICTORIA WONG, MS, PA-C, STEPHANIE WEISS, MD, and ANTHONY J. OLSZANSKI, MD

From Fox Chase Cancer Center, Philadelphia, Pennsylvania

Authors' disclosures of conflicts of interest are found at the end of this article.

Correspondence to: Jennifer Reilly, CRNP, BSN, MSN, RN, AANP, 333 Cottman Avenue, Philadelphia, PA 19111.

E-mail: jennifer.reilly@tuhs.temple.edu

<https://doi.org/10.6004/jadpro.2021.12.1.6>

© 2021 Harborside™

Abstract

Leptomeningeal disease in patients with melanoma historically portends a grim prognosis, with median survival measured in weeks to months. The advent of effective immunotherapy and targeted agents may modify the outcome of such patients. This case report describes a 43-year-old patient diagnosed with stage IIIa *BRAF*-positive cutaneous melanoma in 2012 who subsequently developed leptomeningeal involvement as her sole site of melanotic metastasis. She received multiple systemic therapies and radiotherapy and survived 2.5 years after her diagnosis with central nervous system involvement. This case report highlights the importance of a multidisciplinary team and the advent of effective agents, which offers the potential for significantly improved outcomes for patients with metastatic melanoma involving the central nervous system.

CASE STUDY

In 2012, a 43-year-old female underwent an excisional biopsy of a mole that was present on her posterior trunk, near her midline. The pathology report was consistent with an ulcerated 2.9 mm malignant melanoma. She underwent a wide local excision and sentinel lymph node mapping. In the right axilla, a sentinel lymph node was excised and found to be negative. However, in the left axilla, one of two excised lymph nodes were found to be positive for melanoma. Imaging studies (PET/CT and MRI brain) were negative for metastatic disease. As per the American Joint Committee on Cancer (AJCC) 7th edition staging manual, she was diagnosed with T3b, N1a, cM0, stage IIIa melanoma. Molecular testing on the tumor was found to harbor a *BRAF* V600E mutation.

The patient enrolled in the second Multicenter Selective Lymphadenectomy Trial (MSLT-II trial) and underwent bilateral axillary lymph node dissections. She then received adjuvant pegylated interferon (PEG-INF) therapy. Despite reasonable tolerability with this therapy, 12 months after initiation, the PEG-INF was discontinued due to persistent and profound drug-induced thrombocytopenia. The patient's platelet count trended

to 4,000, which was thought to be secondary to an immune-mediated cause. Due to the low platelet count, the patient received a platelet transfusion and treatment for likely immune thrombocytopenic purpura (ITP), including dexamethasone 40 mg \times 4 days. The patient's platelet count responded to steroid treatment, strengthening the probable diagnosis of ITP.

Within 4 1/2 months, the patient began experiencing mild headaches. A brain MRI was performed but was negative for any acute findings. Over time, her headaches became more persistent and severe, and she began developing intermittent diplopia. Neurology was consulted urgently due to these findings. A repeat brain MRI revealed leptomeningeal enhancement concerning for leptomeningeal carcinomatosis. Cytology of the central nervous system (CNS) fluid from a lumbar puncture was positive for metastatic melanoma, confirming the diagnosis.

The patient underwent whole-brain radiation treatment (WBRT) and initiated immunotherapy with the programmed cell death protein 1 (PD-1) inhibitor, pembrolizumab. The patient's symptoms soon resolved, and she returned to baseline performance status, ECOG 0 (fully active and able to carry on all predisease performance without restriction). Six months after the diagnosis of leptomeningeal disease, she was found to have evidence of an asymptomatic recurrence at the right Sylvian fissure, and underwent CyberKnife radiation therapy for this lesion.

Over the next 2 years, she developed multiple parenchymal brain metastases recognized during surveillance MRIs, all effectively treated with stereotactic radiotherapy. Nearly 2 years and 4 months from the diagnosis of leptomeningeal disease, in late July 2017, she

developed a CNS recurrence at the right insular cortex and right inguinal lymph node systemic disease. Due to the apparent progression of her illness (both CNS and lymph node), pembrolizumab was discontinued.

At that time, the patient met again with radiation oncology, and her case was discussed at the multidisciplinary tumor board. Options included neurosurgery, additional radiation therapy to the brain lesions with fractionated stereotactic radiation therapy, or systemic therapy. Systemic therapy was felt to be in the patient's best interest. Given the presence of the patient's known V600E mutation and recognition that targeted therapy can translate to CNS disease control, she initiated therapy with targeted BRAF/MEK inhibition (dabrafenib plus trametinib).

Within 2 months of starting this therapy, the patient's neurological symptoms escalated to mental confusion, expressive aphasia, intermittent nausea and vomiting, and coordination difficulties. Repeat brain MRI was performed and confirmed the progression of brain metastases (Figure 1). Therefore, BRAF/MEK inhibitor therapy was discontinued, and nivolumab and ipilimumab were urgently initiated as combination immunotherapy.

Shortly after her first dose, her cognitive function declined markedly. Oral steroids and a high-volume lumbar puncture provided slight symptomatic improvement, but subsequent reimaging confirmed worsening of intraparenchymal CNS disease, with new hemorrhagic metastasis and evidence of subfalcine and transtentorial herniation. The patient required emergent intensive care but became comatose and ultimately underwent terminal extubation. She had lived 2 years and 7 months after the diagnosis of leptomeningeal disease.

Leptomeningeal metastasis, also known as carcinomatous meningitis, occurs secondary to the dissemination of cancer cells into the pia-arachnoid meninges and/or cerebrospinal fluid. Leptomeningeal disease most commonly occurs in patients with melanoma and lung cancer (Pape et al., 2012; Raizer et al., 2008). Leptomeningeal disease occurs in approxi-

mately 5% to 25% of cases across multiple cancer types, and the overall prognosis is grave, with a median survival of only 8 to 10 weeks (Taillibert & Chamberlain, 2018). Treatments predating the advent of immunotherapy and targeted therapy were notable for their toxicity and lack of robust efficacy. However, since the introduction of these agents, the landscape has significantly changed for the better.

The patient described in the case study began to experience mild but new headaches. Systemic scans remained negative for disease. A physical examination enhanced with a symptom-directed focus and a thorough review of systems remains a critical need, especially while on active surveillance.

The most common neurological symptoms of CNS involvement include headache, altered mental status, and focal weakness. Headaches are usually generalized, often occur during sleep, or are present upon waking, and become progressively more severe. Mental status changes may initially be subtle. Patients may exhibit lethargy, loss of interest in activities, irritability, or memory loss. The development of weakness and degree of weakness depends on the location of the tumor, but a hemiparetic pattern is most common (Newton, 1999).

Due to the onset of new mild headaches, there was a clinical concern for possible brain metastasis. An initial brain MRI was negative for metastatic disease. However, due to her escalating neurological deficits (mental confusion, expressive aphasia, intermittent nausea and vomiting, and coordination difficulties), the clinical suspicion for brain metastasis was high, which warranted repeat brain MRIs. These confirmed acute findings in her brain, and cytology from a lumbar puncture confirmed metastatic melanoma. The patient then underwent WBRT and initiated immunotherapy with the PD-1 inhibitor, pembrolizumab (Keytruda).

The historic median overall survival (mOS) in patients with metastatic melanoma treated with chemotherapy is less than 1 year; the mOS in patients with leptomeningeal involvement is only 8 to 10 weeks despite treatment. Pembrolizumab, an anti-PD-1 monoclonal antibody, received U.S. Food & Drug Administration breakthrough therapy designation in September 2014 for the treatment of patients with unresectable or metastatic melanoma based on the KEYNOTE-001 trial. In this trial, 85 patients (27 refractory to ipilimumab and 58 treatment naive) were treated with variable doses and schedules of pembrolizumab. The overall response rate (ORR) was 40% (95% confidence interval = 29%–51%) per central independent review using RECIST v1.1. Duration of response (DOR) ranged from 0.9 to 7.9 months

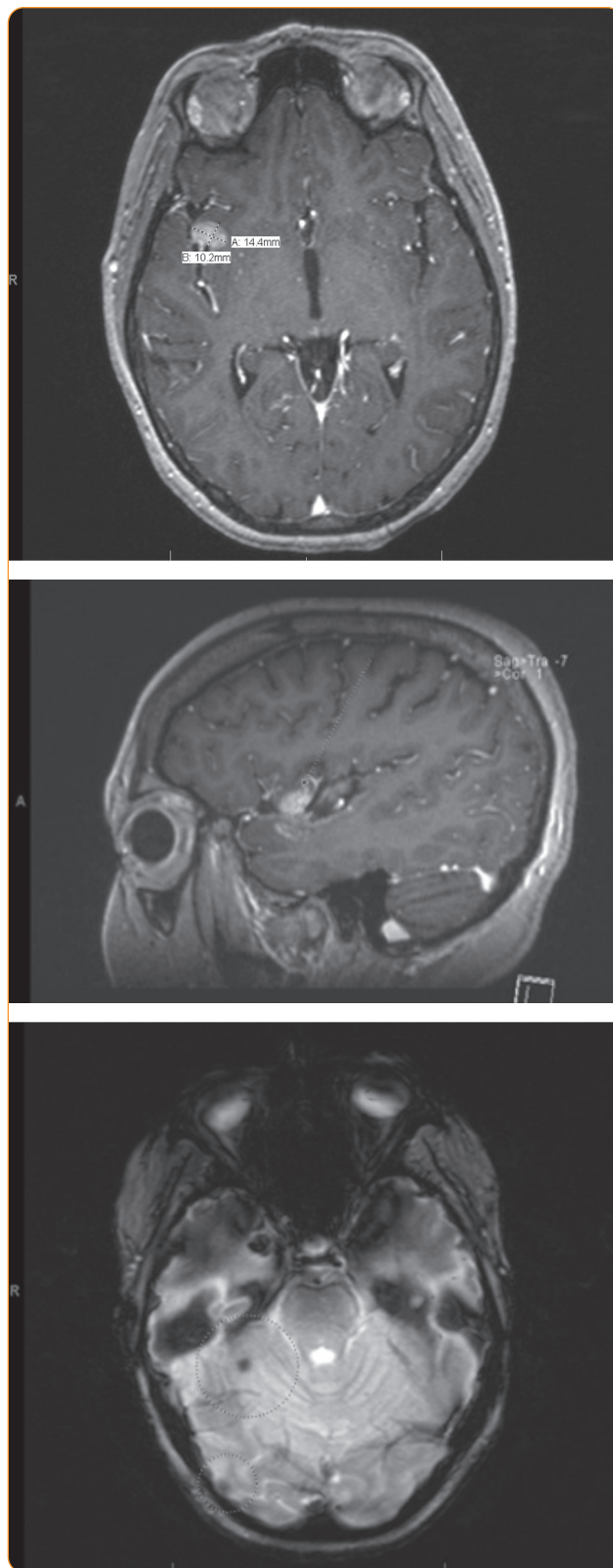


Figure 1. MRI brain with and without contrast showing significant progression of extensive leptomeningeal carcinomatosis (10/6/2017).

(Chuk et al., 2017). However, patients with brain metastasis were excluded from this trial. In a phase II trial comparing nivolumab (Opdivo) and ipilimumab (Yervoy) vs. nivolumab alone in patients with melanoma and CNS metastases by Long and colleagues (2018), intracranial responses were reached by 46% of the patients on combination therapy compared with 20% on monotherapy. These results conclude that anti-PD-1 drugs have activity in the CNS.

In June and July 2017, both a repeat brain MRI and full-body PET/CT revealed progressive disease inside the brain parenchyma, and the patient was switched to dabrafenib (Tafinlar)/trametinib (Mekinist), given that her melanoma exhibited a *BRAF* V600E driver mutation.

Approximately 40% of patients diagnosed with melanoma have a *BRAF* V600 driver-mutation, which can be treated with targeted therapy. Robert and colleagues (2015) found an overall response rate of 64% and a median duration of 13.8 months when *BRAF* plus *MEK* inhibition is utilized in the first-line setting. However, it should be noted that patients were only enrolled in this study if their brain metastases were stable for at least 12 weeks before enrollment. It is clear that this patient's leptomeningeal disease had limited her long-term therapeutic responses. However, there are a few reports suggesting that both *BRAF*/*MEK* inhibitor therapy and immunotherapy have some demonstrable treatment benefits in the setting of brain metastases, and with leptomeningeal disease in particular (Smalley, Fedorenko, Kenchappa, Sahebjam, & Forsyth, 2016).

Due to the patient's disease progression on a targeted therapy, she was swiftly changed to combination immunotherapy due to the high overall response rate. Unfortunately, by this time, she was already experiencing significant CNS symptomatology as detailed previously, and the team was only able to provide her with one dose of ipilimumab and nivolumab combination. Ultimately, the team was not able to decrease her symptoms or halt the progression of brain metastases, and within a short period of time, she died of CNS complications from melanoma.

This patient's overall survival of over 2.5 years was remarkable; most patients die of leptomeningeal disease within 2 months. The most effective

therapeutic interventions this patient received included PD-1 inhibition and radiotherapy. Other treatments for leptomeningeal disease include intrathecal chemotherapy or systemic chemotherapy. Whole-brain radiation was chosen in this patient due to the quick symptomatic relief of this treatment compared with the other options. Side effects that may occur with WBRT include fatigue, nausea, and diarrhea.

It is plausible that the specific combination of radiation and immune checkpoint inhibitors led to an additive effect and impacted her survival. Radiation therapy affects both tumor cells and surrounding cells within the microenvironment. Melanoma-specific antigens may be more readily shed, increasing exposure to the PD-1 inhibited upregulated cytotoxic T cells. The tumor microenvironment may also be affected, leading to an increase in immune cells and tumor recognition. However, there is also a concern for increased toxicity when using radiation therapy in combination with immune checkpoint inhibitors. Additionally, nonspecific upregulation of T cells may lead to immunotherapy-related adverse events, mimicking an autoimmune disease. Such immune-related adverse effects include colitis, dermatitis, and fatigue (Deng et al., 2014; Dovedi et al., 2014; Wang et al., 2018).

ROLE OF THE ADVANCED PRACTITIONER

Immunotherapy and targeted therapy have been shown to be beneficial in patients with CNS disease. This case demonstrates the importance of a multidisciplinary team approach, which includes medical oncologists, oncology advanced practitioners, and radiation oncologists. These patients are often assessed in clinic by both the medical oncologist and advanced practitioner, who then order the appropriate imaging and make the proper referral to the radiation oncologist. The multidisciplinary tumor board also consists of surgeons and radiologists who review individual cases together. It is crucial for clinicians, including advanced practitioners, to recognize symptoms of CNS disease so that they can promptly perform the appropriate workup and referrals to other teams to ensure timely evaluation and treatment.

CONCLUSION

This case report demonstrates the effective management of a patient with leptomeningeal disease from metastatic melanoma. Both immunotherapy and targeted therapy (in *BRAF*-positive melanoma patients) have been shown to confer benefits in patients with parenchymal CNS disease. However, their effectiveness in patients with diffuse leptomeningeal disease is less well studied. This patient, diagnosed with metastatic melanoma with leptomeningeal involvement, lived for 2.5 years after confirmation of CNS leptomeningeal disease, with remarkably sustained disease control and maintenance of her quality of life through the judicious application of checkpoint inhibition and radiotherapy. The treatment landscape for metastatic melanoma patients continues to expand and offers hope for patients with CNS involvement. ●

Disclosure

Ms. Marinova is an employee of Bristol Myers Squibb. The remaining authors have no conflicts of interest to disclose.

References

- Chuk, M. K., Chang, J. T., Theoret, M. R., Sampene, E., He, K., Weis, S. L.,...Pazdur, R. (2017). FDA approval summary: Accelerated approval of pembrolizumab for second-line treatment of metastatic melanoma. *Clinical Cancer Research*, 23(19), 5666–5670. <https://doi.org/10.1158/1078-0432.CCR-16-0663>
- Deng, L., Liang, H., Burnette, B., Beckett, M., Darga, T., Weichselbaum, R. R., & Fu, Y. X. (2014). Irradiation and anti-PD-L1 treatment synergistically promote antitumor immunity in mice. *Journal of Clinical Investigation*, 124(2), 687–695. <https://doi.org/10.1172/JCI67313>
- Dovedi, S. J., Adlard, A. L., Lipowska-Bhalla, G., McKenna, C., Jones, S., Cheadle, E. J., & Illidge, T. M. (2014). Acquired resistance to fractionated radiotherapy can be overcome by concurrent PDL1 blockade. *Cancer Research*, 74(19), 5458–5468. <https://doi.org/10.1158/0008-5472.can-14-1258>
- Long, G. V., Atkinson, V., Lo, S., Sandhu, S., Guminski, A. D., Brown, M. P.,...McArthur, G. A. (2018). Combination nivolumab and ipilimumab or nivolumab alone in melanoma brain metastases: A multicentre randomised phase 2 study. *Lancet*, 19(5), 672–681. [https://doi.org/10.1016/S1470-2045\(18\)30139-6](https://doi.org/10.1016/S1470-2045(18)30139-6)
- National Comprehensive Cancer Network. (2020). NCCN Clinical Practice Guidelines in Oncology: Melanoma. Version 3.2020.
- Newton, H. B. (1999). Neurologic complications of systemic cancer. *American Family Physician*, 59(4), 878–886. Retrieved from <https://www.aafp.org/afp/1999/0215/p878.html>
- Pape, E., Desmedt, E., Zairi, F., Baranzelli, M.-C., Dziwniel, V., Dubois, F.,...Le Rhun, E. (2012). Leptomeningeal metastasis in melanoma: A prospective clinical study of nine patients. *In Vivo*, 26(6), 1079–1086. Retrieved from <http://iv.iiarjournals.org/content/26/6/1079.long>
- Raizer, J. J., Hwu, W.-J., Panageas, K. S., Wilton, A., Baldwin, D. E., Bailey, E.,...Gutin, P. H. (2008). Brain and leptomeningeal metastases from cutaneous melanoma: Survival outcomes based on clinical features. *Neuro-Oncology*, 10(2), 199–207. <https://doi.org/10.1215/15228517-2007-058>
- Robert, C., Karaszewska, B., Schachter, J., Rutkowski, P., Mackiewicz, A., Stroiakovski, D.,...Schadendorf, D. (2015). Improved overall survival in melanoma with combined dabrafenib and trametinib. *New England Journal of Medicine*, 372, 30–39. <https://doi.org/10.1056/NEJMoa1412690>
- Smalley, K. S., Fedorenko, I. V., Kenchappa, R. S., Sahebjam, S., & Forsyth, P. A. (2016). Managing leptomeningeal melanoma metastases in the era of immune and targeted therapy. *International Journal of Cancer*, 139(6), 1195–1201. <https://doi.org/10.1002/ijc.30147>
- Taillibert, S., & Chamberlain, M. C. (2018). Chapter 13 - Leptomeningeal metastasis. *Handbook of Clinical Neurology*, 149, 169–204. <https://doi.org/10.1016/B978-0-12-811161-1.00013-X>
- Wang, Y., Deng, W., Li, N., Neri, S., Sharma, A., Jiang, W., & Lin, S. H. (2018). Combining immunotherapy and radiotherapy for cancer treatment: Current challenges and future directions. *Frontiers in Pharmacology*, 185. <https://doi.org/10.3389/fphar.2018.00185>