

Posterior dynamic stabilization: The interspinous spacer from treatment to prevention

Antoine Nachanakian, Antonios El Helou, Moussa Alaywan

Department of Neurosurgery, Saint George Hospital University Medical Center in Collaboration with Balamand University, Beirut, P.O Box 166378, Lebanon

ABSTRACT

Introduction: Managements of lumbar stenosis evolved over the time from decompression to dynamic stabilization preserving the motion segment passing by the rigid fixation. After long years of rigid fusion, adjacent segment disease became more and more frequent and the concept of dynamic stabilization emerged.

Materials and Methods: We report our experience with posterior dynamic stabilization using an interspinous distracter (ISD). One hundred and eight patients were operated between September 2008 and January 2012 with different lumbar spine pathologies. The ages of our patients were between 45 years and 70 years, with a mean age of 55 years. With our growing experience, indication of ISD became narrowed and the interspinous spacer became an absolute tool for adjacent segment disease as a treatment as well as prophylactic with rigid stabilization.

Results and Discussion: Overall clinical improvement was noted in ISD-treated patients, with considerable satisfaction in 77% of patients on average. The patient at first reported an improvement of their radicular pain with a mean reduction of 3.6/10 on visual analog scale. Post-operative walking distance progressively increased during the next 3 months. Whereas, a radiological evaluation at 3 months showed a mean of 42% improvement of the disc height. On the other hand, all patients operated with posterior dynamic stabilization (PDS) at the time of rigid stabilization showed no adjacent segment disease compared to those operated with posterior arthrodesis ($P < 0.05$).

Conclusion: Interspinous spacer after surgical decompression for spinal stenosis by excision of Ligamentum flavum demonstrates excellent short-term and long-term results for improvement in back pain, neurogenic claudication, and patient satisfaction. It provides restoration of disc height, reduction of vertebral slip and it's a necessary tool in the management and the prevention of adjacent segment disease.

Key words: Adjacent segment disease, interspinous spacer, posterior dynamic stabilization

Introduction

Degenerative lumbar disease is an increasing medical problem with aging of the population.^[1] Degenerative disease leads to spinal stenosis, leading to neurogenic claudication. The management of this pathology started

with de-compressive surgery in the past decade. Because decompression alone might not change the course of segmental degeneration process, the concept of posterior stabilization was born. Rigid fusion was efficient and provided better outcome compared to decompression alone but it couldn't resolve the problem of disc degeneration without evident radicular compression.^[2] In addition, with time a new pathology known as adjacent segment disease was described. From this evidence for adjacent-segment degeneration emerged the concept of dynamic or non-fusion stabilization of the lumbar spine.^[3] It is supposed to limit extension and expand the spinal canal at the symptomatic level, however, with reduced effect on the range of motion of the adjacent segments.^[4]

Posterior dynamic stabilization, in which pedicle screw fixation is coupled with a flexible longitudinal connecting system, presumably allows for the normalization of inter-segmental motion.^[5] This stands in contrast to traditional fusion surgery, in which the goal is complete and immediate

Access this article online	
Quick Response Code:	Website: www.asianjns.org
	DOI: 10.4103/1793-5482.177662

Address for correspondence:

Prof. Antoine Nachanakian, Department of Neurosurgery, Saint George Hospital University Medical Center in Collaboration with Balamand University, Beirut, P.O Box 166378, Lebanon.
E-mail: nachanakian@gmail.com

elimination of motion and ultimately, arthrodesis.^[6] While both strategies seek to address the underlying pathology of micro-instability, the dynamic stabilization approach promises to do so in a more physiological manner. By restoring normal motion, mobility is theoretically preserved rather than eliminated, and the forces acting above and below the construct are altered to a lesser extent, reducing the potential undesirable effects of fusion.^[7] Recently, new concepts, such as soft stabilization, dynamic stabilization, and motion preservation, have been explored as alternative treatment options to lumbar fusion.

Interspinous process spacers have been introduced as a possible alternative to spinal decompression and fusion for the treatment of neurogenic intermittent claudication and discogenic lower back pain.^[8] The interspinous devices distract the Neural Foramen, unload the intervertebral disc, and limit spinal extension, improving central canal, and foraminal stenosis. Interspinous distracter (ISD) is designed to stabilize the motion segment after neural elements decompression in lumbar stenosis, tolerating flexion and extension in this segment thus, preserving the adjacent segment from deterioration.^[5-8]

Materials and Methods

Our experience is based on 108 cases performed between September 2008 and January 2012 with different lumbar spine pathologies [Table 1]. The ages of our patient were between 45 years and 70 years, with a mean age of 55 years. All patients were treated with ISD.

Inclusion criteria

Patients are eligible for enrolment if they have:

- Degenerative disk disease and subsequent bilateral foraminal stenosis [Figure 1]
- Foramino-canal stenosis, due to Ligamentum flavum hypertrophy, declared symptoms consisting of neurogenic claudication
- Suspended vertebra shown on X-ray and is due to facet degenerative disease [Figure 2]
- Facet joint syndrome
- Adjacent segment syndrome [Figure 3] which refers to degenerative changes that occurs in the mobile segment next to spinal fusion (Schlegel, *et al.* 1996)^[9]
- Degenerated disc at a level superior to the one necessitating posterior rigid fusion [Figure 4].

Non-inclusion criteria

Patients were not included if they present:

- Lumbar stenosis of more than 2 adjacent levels
- The level of stenosis above Th11-Th12 level or below L4-L5 level
- Fracture of the spinous process of the stenotic level
- Operated previously by a laminectomy with removal of the spinous process

- Degenerative and congenital spondylolisthesis
- Osteoporosis (T score < -2.5 in the lumbar region).

Pre-operative evaluation

The patients completed the visual analog scale (VAS) for pain and Oswestry disability index (ODI).

Para clinical evaluation included plain lumbar film, lumbar magnetic resonance imaging (MRI) or computed tomography and osteodensitometry.

The global and segmental lordotic angles (stabilized segments, above and below adjacent segments) were measured using Cobb's method on lateral neutral position lumbosacral spine X-ray.

The segmental lordotic angles (stabilized segments and adjacent segments) were measured from between the upper end plates of the corresponding segments.

Operative procedure Preparation

The procedure is carried out under general anesthesia. All patients were operated in a prone position, flexed on a Wilson surgical frame with the thoracolumbar spine segment in neutral to a slightly kyphotic position, avoiding hyperlordosis for a better interspinous distraction.

Product used

Different interspinous spacers' types are used in our institution.

The instrument used

A set of lumbar laminectomy is used. In addition, a set of interspinous spacer measurer is utilized to define the depth and width of the spacer to be used.

Surgical note

The level of the procedure is localized under fluoroscopy after positioning. Midline vertical skin incision is carried out. Dissection of the subcutaneous layer and the paraspinal muscles until identification of the articular facets.

The decompression of the neural elements for stenosis is made through surgical interlaminar fenestrations with flavectomy and opening of the lateral recess, and not by the old-fashioned

Table 1: Number of cases in correlation with disease and sex

Number of cases	Pathology	Male/female ratio
36	Bi-foraminal stenosis	24/12
15	Ligamentum flavum hypertrophy	8/7
6	Suspended vertebrae	4/2
3	Facet syndrome	All females
38	Adjacent syndrome	23/15
10	Adjacent syndrome prevention	3/7

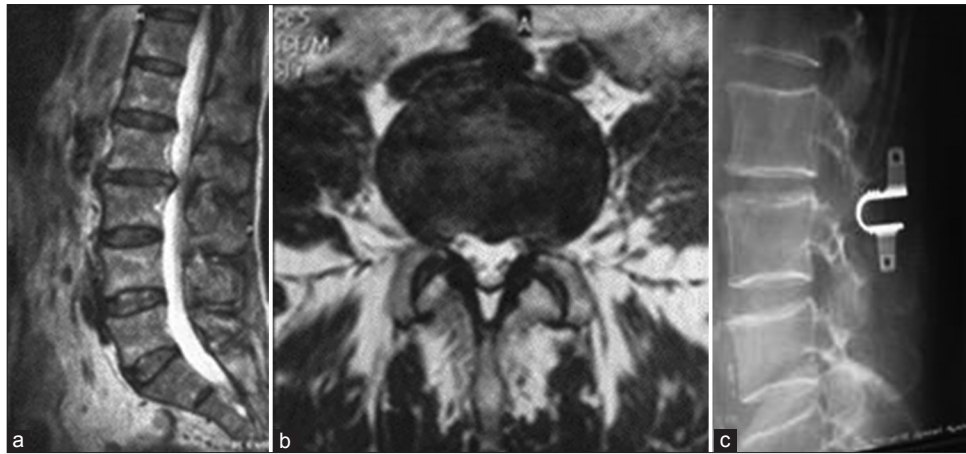


Figure 1: (a) Sagittal T2 magnetic resonance imaging image showing L2-L3 Bi-foraminal Stenosis. (b) Axial T2 MRI image showing L2-L3 Bi-foraminal Stenosis. (c) Plain lumbar X-ray after insertion of interspinous spacer

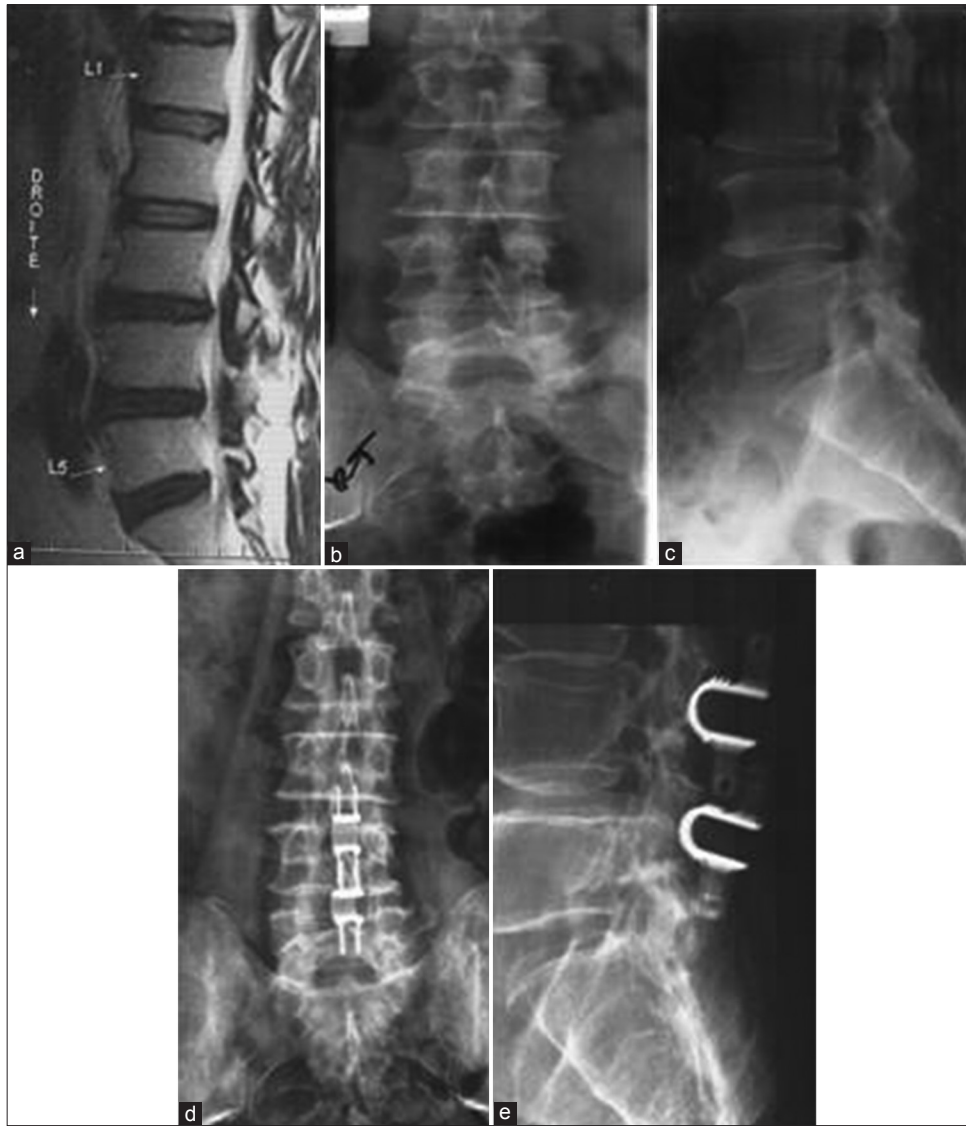

Figure 2: (a) Pre-operative magnetic resonance imaging Sagittal T2 showing L3-L4 suspended vertebrae. (b) Antero posterior lumbar spine X-ray showing L3-L4 suspended vertebrae. (c) Lateral lumbar spine X-ray showing L3-L4 suspended vertebrae. (d) Post-operative Antero posterior lumbar spine X-ray after insertion of L2-L3 and L3-L4 interspinous distracter. (e) Post-operative lateral lumbar spine X-ray after insertion of L2-L3 and L3-L4 ISD

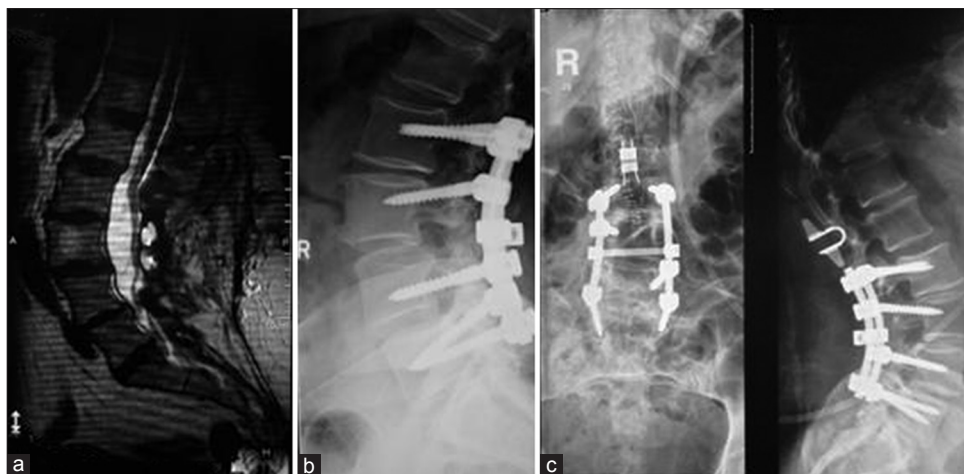


Figure 3: (a) Pre-operative T2 Sagittal lumbosacral spine magnetic resonance imaging for adjacent segment disease. (b) Pre-operative lumbosacral spine X-ray for adjacent segment disease. (c) Post-operative lumbosacral spine X-ray with interspinous distracter showing increase in adjacent segment disc height

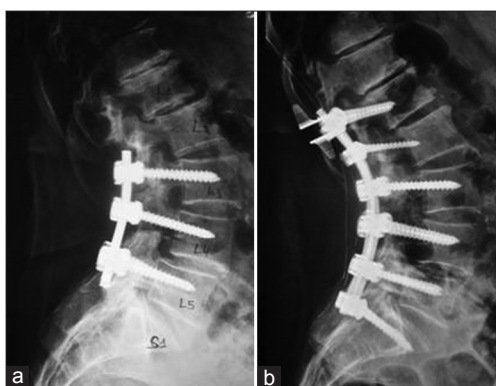

Figure 4: (a) Pre-operative lumbosacral spine X-ray before insertion of interspinous distracter at Th12-L1 level showing a degenerated disc at a level superior to the one necessitating posterior rigid fusion. (b) Post-operative lumbosacral spine X-ray after insertion of ISD at Th12-L1 level showing a degenerated disc at a level superior to the one necessitating posterior rigid fusion

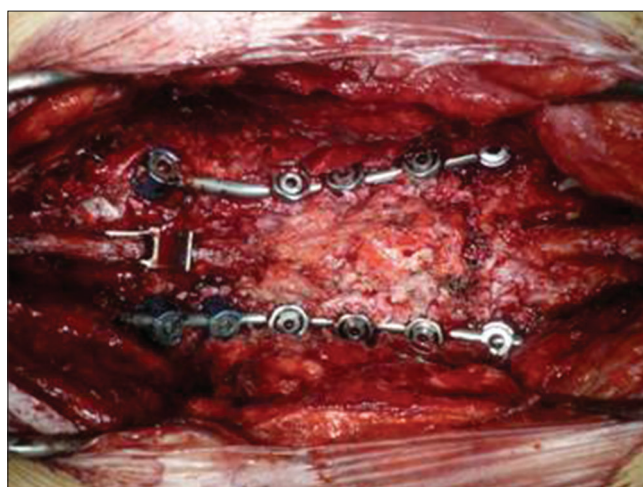


Figure 5: Pre-operative view of interspinous distracter at the level above a fused segment

laminectomy. For the insertion of the ISD the interspinous ligament is resected.

Adequate preparation of the interspinous space; removal of all soft-tissues and flattening of the bony walls to a straight parallel nidus were ended with an adequate insertion.

Proper depth of the incorporation of ISD was determined following direct spacing of 3-4 mm between the deepest point of the device and the dural sac placing through that space a midsize hook.

One or two interspinous spaces were treated according to the pre-operative plan and ISD were inserted.

Discectomy is performed in cases where the protruded/herniated disc is still compressing the root(s) despite the ligaments resection and the bone recalibrations are carried out.

In cases, where the disc is protruded/herniated, medially discectomy was not carried out.

In cases of degenerative or congenital spondylolysis is present, rigid fusion of the spondyloitic level was carried out with insertion of ISD at the level above [Figure 5].

Regular closure of layers and placing of deep hemovac drain ended the surgery.

Follow-up evaluation

Immediate post-operative care

The patient is out of bed the day after surgery and was discharged on day 3 after surgery, or on day 2 when drain was not inserted.

All patients wear a lumbar brace, for a period of 1 month during their daily activities.

Late post-operative evaluation

The following data were collected: VAS, ODI, pain medication, complications, and patient satisfaction.

Control lumbo-sacral X-ray is done in two views to evaluate the created distraction.

The plain radiographs (antero-posterior and lateral standing in neutral position) are obtained at day 1, day 90 and day 180 post-operatively. Disc height and Cobb's angle are measured and compared to the pre-operative values.

Complications

In general, materials are well tolerated. The rate of complications is between 1% and 10% in all series. Two sets of complications exist; the early and the delayed.

Early complications include device dislocation/malposition, spinous process fractures, erosion of the spinous process, infection, hematoma, and neurological sequelae.

One case of migration was observed in one series (Adelt D et al. 2007).^[10] There were no broken or permanently deformed implants in all series.

In our series, no cases of fracture of the superior spinous process occurred. In our experience, we do osteodensitometry for all patients to assess bone density in pre-operative. During operation, we avoid bone erosions of the adjacent spinous processes.

We had one case of recurrent neurological symptoms, and ISD was removed. Microsurgical decompression and postero-lateral fusion were carried out. To avoid this type of complications, a complete posterior decompression through Ligamentum flavum excision and discectomy in the presence of herniated disc should be done.

Selection of patients without spondylolysis is mandatory to avoid postero-lateral fusion later on. And in the presence of spondylotic segment, rigid fusion with insertion of ISD at the superior adjacent level protects from recurrence of neurological symptoms as well as from later adjacent segment disease.

Statistical analysis

The clinical and radiologic results were analyzed using *t* test, a *P* value of less than 0.05 is considered statistically significant. All analyses were carried out using SPSS ver. 16.00 (IL, Chicago, Inc.).

Results

Pain assessment

Overall improvement was noted in ISD-treated patients, with considerable satisfaction in 86% of patients on average.

The patients at first reported an improvement of their radicular pain with a mean reduction of 3/10 on VAS (scale for 0: Absent pain to 10: Severe intolerable pain necessitating intra venous treatment).

In the pre-operative, radicular pain had a mean score of 8.2/10 on VAS (6-10) whereas, in the immediate post-operative period, the pain mean score was at 4.9/10 on VAS (1-7).

Patients achieved maximum improvement after an average period of 6 months, with a mean score of 2.1/10 on VAS (0-5), and up to 78% of patients were pain free [Chart 1].

Disability assessment

The Oswestry low back disability questionnaire score (ODI) improved from a mean of 67.4% in the pre-operative period (25-90%) to 19.3% at 3 months (0-50%), and <10% at 6 months follow-up (*P* < 0.05) [Chart 2].

Disc height

The pre-operative disc height was measured by MRI, with a mean of 1.1 cm (0.6-1.5 cm) and intervertebral space on lateral X-ray view measured manually had a mean of 1.2 cm (0.7-1.5 cm) whereas, in post-operative evaluation, only spine X-ray was carried out (due to elevated cost of MRI) and the mean measured intervertebral space was 1.6 cm (1.1-2.3 cm).

Radiologic changes, on lateral views in neutral position in lumbosacral spine X-ray, in the disk-height of the stabilized segment were increased significantly from pre-operative to immediate post-operative evaluation (*P* < 0.05). This increase persisted at 3 months follow-up (*P* < 0.05) [Table 2].

Segmental lordotic angles

The range of motion measured by the segmental lordotic angle in stabilized segment decreased post-operatively ($3.97^\circ \pm 2.9^\circ$) compared to the pre-operative measured values ($5.23^\circ \pm 3.68^\circ$). This change was not statistically significant (*P* = 0.432).

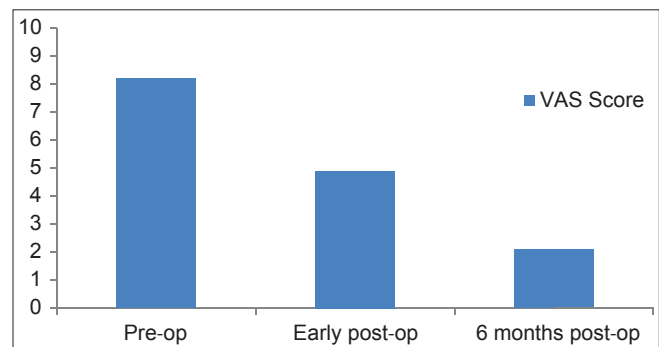


Chart 1: Comparative chart of mean visual analog scale from pre-operative period up to 6 months post-operative

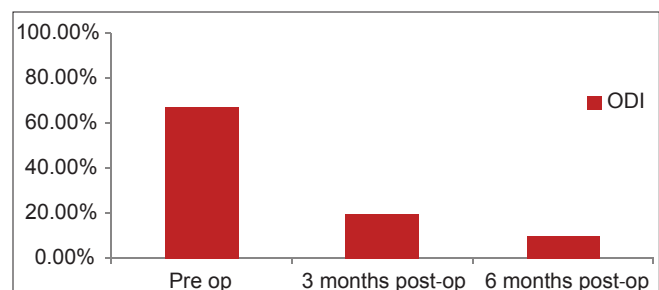


Chart 2: Oswestry low back disability score comparing pre-operative to 3 months and 6 months post-operative evaluation

Table 2: Comparative table between pre- and post-operative radiological changes

Variables	Pre-operative	Post-operative
Disc height in cm		
Stabilized segment	1.2	1.6
Segmental lordotic angle in degree	5.23±3.68	3.97±2.9

Although, adjacent segment range of motion (ROM) showed a decrease on post-operative X-ray, there was no statistical significance [Table 2].

Operative characteristics

The prominent characteristic of this surgery is a low-level of post-operative pain and so, the decompression carried out by removal of Ligamentum flavum and the re-establishment of the dynamics of the spine play a major role in the resolution of back pain. Restoration of the height of the intervertebral disc relieve the pressure on the Sino-vertebral nerve, which plays a major role in decreasing paraspinal muscles spasm and though the back pain.

In addition, the amount of blood loss with ISD procedure (51.8 cc ± 23.4 cc) compared to rigid stabilization (184.3 cc ± 67.8 cc) was found to be reduced ($P < 0.005$).

Discussion

It is well-known that rigid spinal fixation systems have a high-rate of complications, such as mechanical failure, osteoporosis and adjacent segment degeneration.^[11,12] For the latter, its exact mechanism remains uncertain, however, fusion technique specifically, shifts the center of rotation leading to increase stress on the facets and/or disc of the adjacent mobile segment. It increases the mobility of the adjacent segment and the intradiscal pressure and so, it can lead to disc degeneration. It was shown by Mehta JS *et al.*, that the lumbar discs degenerate earlier than the facets in the same time frame.^[13]

Not all authors agree with the theory of adjacent segment degeneration. In a prospective study, Pellise *et al.*, found that after instrumented posterior lumbar fusion, disc degeneration appeared homogeneously at several levels cephalad to fusion and seemed to be determined more by individual characteristics than by fusion itself.^[14]

In our experience, after a long follow-up period, we have remarked that adjacent segment disease is a serious problem that causes refractory pain to medical treatment, that necessitated long segment fusion, which leads to limitation of back motion and spinal deformities.^[15]

To avoid these adverse effects, the achievement of ideal mobility is important. Thus, dynamic stabilization devices would appear to represent a notable technological advantage.

Posterior dynamic stabilization is done to decrease and/or avoid the harmful effects of rigid fusion, such as listhesis, instability, hypertrophic facet joint arthritis, herniated nucleus pulposus, and stenosis.

The study carried out by Shang-Won Yu *et al.*, showed better results with the interspinous distractor compared to posterior lumbar interbody fusion.^[16] On the other side, Cansever *et al.*, showed benefit with dynamic pedicular system.^[17] We didn't try this system since we had satisfactory results with the interspinous spacer.

The interspinous dynamic stabilization system with preservation of the disc and facet, create a favorable environment in the motion segment by reducing the loading on these joints and allowing more normal motion.

The clinical outcomes of patients in our study improved significantly during the follow-up period, not only at 3 months and 6 months, but also in the early post-operative period.

The system increased the distraction posteriorly and improved the anterior disc space height, which decreased the stenosis and liberated the nerve roots and the foramina.^[16] The device also decreased articular process pressure and reduced the pain transmitted from these overloaded joints to the brain via the medial branch of the dorsal root ganglion.^[18]

The follow-up with serial X-rays showed no evidence of osteophytes at articular facets level as noted in rigid fixation. We conclude that ISD not only decreases the load on the facets, but also impairs osteophytes formation. By this method of stabilization, adjacent segment is treated when it exists and prevented after rigid fixation due to preservation of normal articular facets mobility.

In late post-operative X-ray follow-up of the patients examined, a mineralization of the spinous process in contact with the implant was found, in particular at its base, which appears to absorb high stresses due to lordosis, and this finding was described 10 years ago by Sawnsen *et al.*^[19]

Our results concerning disc height and segmental lordotic angles correlate with other studies carried out in China and Turkey.^[17,20] This means that the ISD is useful regardless of ethnic origin.

The dynamic stabilization system seems to not only preserve segmental motion, but also to maintain the patient's own lumbar kinematics. Posterior dynamic stabilization systems have stabilization effects in all three primary directions and tend to reduce instability.^[18]

They also allow for motion in the axial rotation. However, in flexion and extension, the ROM of the dynamic device is clearly higher.^[20]

Theoretically, these dynamic devices have the advantage of reduced stress shielding, protecting the adjacent segment from degeneration and diminishing implant failure.

The motion preserving implants are capable to keep the natural fiber strain and bulging distribution of the intervertebral disc. Comparing ISD to rigid fixation, rigid stabilization was found to decrease the fiber strain and transfer the load to the rod, changing all the biomechanics of the spinal cord and so, ISD leads to physiological conditions regarding the fiber strains and disc bulging. This condition was certified by the measurement of disc height in the pre- and post-operative period. A study done by Heuer *et al.*, on disc bulging and annular fibers strain certified the above mentioned results.^[18]

The ISD system slightly limits the bulging of the disc at the lateral and posterolateral site. This could be due to the decompression effect at the posterior elements by the implant.^[21] It results in good motion preservation, and compared to rigid stabilization surgery, it is associated with less blood loss and shorter surgical time and hospital stay. These findings correlate with Shang-Won Yu *et al.*, study comparing different ISD to rigid fixation systems.^[16]

Conclusion

Interspinous spacer after surgical decompression for spinal stenosis by excision of Ligamentum flavum demonstrates excellent short-term and long-term results for improvement in back pain, neurogenic claudication, and patient satisfaction. It provides restoration of disc height, reduction of vertebral slip, and lead to physiological condition concerning disc bulging. It's a necessary tool in the management and the prevention of adjacent segment disease.

References

- Chen CS, Cheng CK, Liu CL, Lo WH. Stress analysis of the disc adjacent to interbody fusion in lumbar spine. *Med Eng Phys* 2001;23:483-91.
- Kanayama M, Hashimoto T, Shigenobu K, Harada M, Oha F, Ohkoshi Y, *et al.* Adjacent-segment morbidity after Graf ligamentoplasty compared with posterolateral lumbar fusion. *J Neurosurg* 2001;95:5-10.
- Christie SD, Song JK, Fessler RG. Dynamic interspinous process technology. *Spine (Phila Pa 1976)* 2005;30 16 Suppl:S73-8.
- Adelt D, Samani J, Kim WK, Eif M, Lowery GL, Chomiak RJ. Coflex TM interspinous stabilisation: Clinical and radiographic results from an international multicenter retrospective study. *Paradigm spine J* 2001;1:1.
- Kaech DL, Fernandez C, Haninec P. Preliminary experience with the interspinous U device. *Rachis* 2001;13:303-4.
- Kaech DL, Fernandez C, Lombardi-Weber D. The Interspinous U: A new restabilization device for the lumbar spine. *Restabil Proc* 2000;30:355-62.
- Kaech DL, Jinkins JR. The interspinous "U": A new restabilization device for the lumbar spine. In: Kaech DL, editor. *Spinal Restabilization Procedures*. New York: Elsevier Science B.V.; 2002. p. 355-62.
- Bowers C, Amini A, Dailey AT, Schmidt MH. Dynamic interspinous process stabilization: Review of complications associated with the X-Stop device. *Neurosurg Focus* 2010;28:E8.
- Schlegel JD, Smith JA, Schleusener RL. Lumbar motion segment pathology adjacent to thoracolumbar, lumbar, and lumbosacral fusions. *Spine (Phila Pa 1976)* 1996;21:970-81.
- Adelt D. The interspinous U implant (now Coflex): Long-term outcome, study overview and differential indication. *Orthopade*. 2010;39:595-601.
- Resnick DK, Choudhri TF, Dailey AT, Groff MW, Khoo L, Matz PG, *et al.* Guidelines for the performance of fusion procedures for degenerative disease of the lumbar spine. Part 5: Correlation between radiographic and functional outcome. *J Neurosurg Spine* 2005;2:658-61.
- Kumar MN, Baklanov A, Chopin D. Correlation between sagittal plane changes and adjacent segment degeneration following lumbar spine fusion. *Eur Spine J* 2001;10:314-9.
- Mehta JS, Kochhar S, Harding IJ. A slip above a slip: Retrolisthesis of the motion segment above a spondylolytic spondylolisthesis. *Eur Spine J* 2012;21:2128-33.
- Pellisè F, Hernández A, Vidal X, Minguell J, Martínez C, Villanueva C. Radiologic assessment of all unfused lumbar segments 7.5 years after instrumented posterior spinal fusion. *Spine (Phila Pa 1976)* 2007;32:574-9.
- Nachanakian A, El Helou A, Alaywan M. Posterior dynamic stabilization: The interspinous spacer. In: Sakai Y, editor. *Low Back Pain Pathogenesis and Treatment*. Rijeka, Croatia: In Tech; 2012. p. 189-200.
- Yu SW, Yen CY, Wu CH, Kao FC, Kao YH, Tu YK. Radiographic and clinical results of posterior dynamic stabilization for the treatment of multisegment degenerative disc disease with a minimum follow-up of 3 years. *Arch Orthop Trauma Surg* 2012;132:583-9.
- Cansever T, Civelek E, Kabatas S, Yılmaz C, Caner H, Altınörs MN. Dysfunctional segmental motion treated with dynamic stabilization in the lumbar spine. *World Neurosurg* 2011;75:743-9.
- Heuer F, Schmidt H, Käfer W, Graf N, Wilke HJ. Posterior motion preserving implants evaluated by means of intervertebral disc bulging and annular fiber strains. *Clin Biomech (Bristol, Avon)* 2012;27:218-25.
- Swanson KE, Lindsey DP, Hsu KY, Zucherman JF, Yerby SA. The effects of an interspinous implant on intervertebral disc pressures. *Spine (Phila Pa 1976)* 2003;28:26-32.
- Jia YH, Sun PF. Preliminary evaluation of posterior dynamic lumbar stabilization in lumbar degenerative disease in Chinese patients. *Chin Med J (Engl)* 2012;125:253-6.
- Schmoelz W, Erhart S, Unger S, Disch AC. Biomechanical evaluation of a posterior non-fusion instrumentation of the lumbar spine. *Eur Spine J* 2012;21:939-45.

How to cite this article: Nachanakian A, El Helou A, Alaywan M. Posterior dynamic stabilization: The interspinous spacer from treatment to prevention. *Asian J Neurosurg* 2016;11:87-93.

Source of Support: Nil, **Conflict of Interest:** None declared.