

OPEN

Doxycycline reduces osteopenia in female rats

Fellipe A. T. de Figueiredo¹, Roberta C. Shimano¹, Edilson Ervolino², Dimitrius L. Pitol³, Raquel F. Gerlach³ & Joao Paulo M. Issa^{1,3*}

Doxycycline, a member of the tetracycline family, is a drug used as an antibiotic (dosage of 100 mg/day) and as an anti-inflammatory drug on the dosage of 20 mg twice a day, this use has Matrix Metalloproteinases (MMP) inhibitor action. Doxycycline is a calcium chelator and therefore interferes in bone remodeling. The main objective of this study was to evaluate the action of the drug doxycycline in the control of osteopenia. Sixty three Wistars rats were divided into 9 groups with $n=7$ each, as follow: the control group with doxycycline 10 mg/kg/day (C10), control with doxycycline 30 mg/kg/day (C30) and control (C), ovariectomized group with doxycycline 10 mg/kg/day (OVX10), ovariectomized with doxycycline 30 mg/kg/day (OVX30), and ovariectomized with water (OVX), sedentary group with 10 mg/kg/day (Se10), sedentary with doxycycline 30 mg/kg/day (Se30), and sedentary group with water (Se). Left femoral bone was used for bone densitometry, right femoral bone for histological analysis. The right tibia was intended for chemical quantifications, the total serum was used for cholesterol and calcium quantification. The length of the left femoral bone was measured after the densitometry analysis. Statistical analysis was performed using multivariate general linear model (ANOVA two factors with Bonferroni adjustment) and the TRAP analysis was subjected to normality test and then were subjected to nonparametric test, both with $p < 0.05$ significance. Statistically significant differences were found, with better results for the groups exposed to the medication (10 and 30 mg/kg/day): Se vs. Se10 and Se vs. Se30 for BMC, quantification of magnesium, amount of cancellous bone in the distal portion; OVX vs. OVX10 for BMC, BMD and calcium in serum; OVX vs. OVX10 and OVX30 for quantification in proximal and distal portion of cancellous bone; Se vs. Se30 and OVX vs. OVX30 for immunostaining for TRAP, all results with minimum of $p \leq 0.05$. Doxycycline had a deleterious effect on control groups and positive action for bone organization on female rats affected by bilateral ovariectomy-induced osteopenia and sedentary lifestyle.

The Role of Doxycycline

Doxycycline is a member of the tetracycline family, a drug used as an antibiotic (dosage of 100 mg/day) and as matrix Metalloproteinases (MMPs) inhibitor (dosage of 20 mg twice a day), which use has an anti-inflammatory effect. The molecule of tetracycline is defined as naphthacene carboxamide ring system¹. Doxycycline differs structurally from the tetracycline molecule in the modifications of substituent at positions 5 and 6 of the ring system, which make it more lipid soluble and could be presented in the anhydrous form (Fig. 1)². Doxycycline on this low-dose is considered for the treatment of chronic periodontitis³ and chronic inflammation in the skin⁴. For these uses doxycycline in “subdoses” (Subantimicrobial dose doxycycline or SDD) was approved in 1998 by the Food and Drug Administration (FDA) in the USA and also by the regulatory agencies of Canada and Europe. These formulations of doxycycline are named Periostat and Oracea (in the US) and the use can be done continuously for 9 months. This dose does not induce microbial resistance⁵.

Doxycycline and Bone Interactions

Doxycycline interacts with bone and teeth, accumulating on these tissues during their mineralization (teeth and bone) and during the physiologic remodeling (bone)⁶. In bone metastasis from breast cancer and prostate cancer, doxycycline has a curious role on the bone remodeling inducing the bone formation⁷ and inhibiting the MMP associated to this tumor⁸. SDD of this medication is related to reduction of serum biomarker of bone resorption

¹Department of Biomechanics, Medicine and Rehabilitation of the Locomotor System, Ribeirao Preto Medical School, University of Sao Paulo – Av. Dos Bandeirantes 3900, Ribeirao Preto, SP, CEP 14049-900, Brazil. ²Department of Basic Sciences, Sao Paulo State University Júlio de Mesquita Filho – R. Jose Bonifácio 1193, Araçatuba, SP, CEP: 16015-050, Brazil. ³Department of Basic and Oral Biology, School of Dentistry of Ribeirao Preto, University of Sao Paulo – Av. Cafe S/N, Ribeirao Preto, SP, CEP: 14040-904, Brazil. *email: jmissa@forp.usp.br

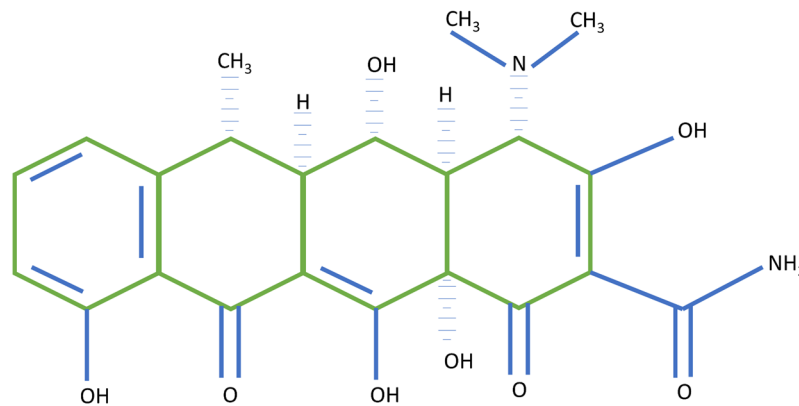


Figure 1. Representation of the chemical structure of Doxycycline.

and related to the increase of biomarker of bone formation⁹ in postmenopausal osteopenic women with 2 years follow-up. These interaction with the bone are not related to the antimicrobial interaction (SDD), but doxycycline can act as inhibitory inflammatory medication of the bone resorption¹⁰.

Osteoporosis, Public Health and Induction of Osteopenia

Osteoporosis is a classical disorder of elderlies, responsible for increased risk of bone fractures¹¹, characterized as an increase of skeletal fragility¹². Osteopenia is defined as “low bone mass” and it is a warning for the future osteoporosis. Exercises and a better quality of life might prevent the fracture of the bones affects by this low mass¹³.

The incidence of fractures due to osteoporosis is increasing and it also increases the costs of public health to treat this disorder^{14,15}. This information is important because it has been shown in study that during the youth practicing physical exercises and balanced diet are crucial for prevention of osteoporosis. Also during childhood and adolescence, it is essential for the increase of bone density and bone growth in humans¹⁶.

Bone remodeling depends on a balance between bone resorption and bone formation¹⁷. Considering the high prevalence of osteoporosis in many populations, researchers have proposed animal models for osteopenia induction. One of them is the ovariectomy-induced menopause that mimics the increase in osteoclastic activity which exceeds the osteoblastic activity, resulting an induction of osteoporosis¹⁸. Rats are the animal model used for this purpose¹⁹ because they supply enough sample for statistical purposes, easy feed and location. Different research groups worked with this type of osteopenia induction in Wistar rats^{20–24}.

Sedentarism and Osteopenia

Nowadays young people and children are being “victims” of modern life sedentarism and obesity^{25,26}, exactly during this time of life, prevention of chronic diseases of adult life needs to be initiated (high blood pressure, dyslipidemias, diabetes mellitus)^{16,27}. Moreover, it is pointed out that the practice of exercises in the youth, when the bones are more malleable, promotes better bone quality in the future^{28–31}. According to NiA (National institute of age, NIH, USA), weight training, walking, hiking, jogging, climbing stairs, tennis, and dancing can prevent the fractures of bones affected by this low bone mass. Karlsson and collaborators studied about football players who have left their profession for over 20 years, demonstrating a residual protective effect on bone quality after the long time without performing intense exercises³², characterizing that sports at early age contribute to a better quality of life in elderly phase.

A calcium deficient diet, common on sedentary diets, also induces osteopenia as demonstrated by a meta-analysis Specker (1996), who presented a result showing that a sedentary lifestyle (no exercise) combined with a calcium-poor diet worsens the picture of osteopenia, as shown by data obtained from bone densitometry³³.

With all of this important knowledge of osteopenia and it is relation with the drug doxycycline, the main objective of this study was to evaluate the action of the drug doxycycline in the control of osteopenia induced by bilateral ovariectomy and sedentary lifestyle in Wistar female rats.

Materials and Methods

This study was approved by the Ethics Committee on use of animals in research of the University of Sao Paulo: School of dentistry of Ribeirao Preto (in Portuguese CEUA/FORP-USP) under the Protocol of 2013.1.1528.58.5 in confirmation to all the methods and guidelines of CONCEA (National guideline of animal use on experimentation from Brazil), which follow the international parameters on use and handling of animals. Sixty three (63) female Wistar rats with 45 days of life (or 100 g) were obtained from the campus of the University of São Paulo, Ribeirao Preto and stayed at the School of Dentistry of Ribeirao Preto for ambience for 30 days until methodological procedure. Experimental procedures of groups were started with 75 days of age (or 150 g), this age has been considered as day1 of experimental time (Fig. 2). Wistar females reached sexual maturity at this age and it is known that bone maturity is acquired only by 10 months of age (or 300 days of life)¹⁹. The doxycycline administration starts on day 90 of treatment (or 165 days of life) and it was administered for 60 days until the induction of death.

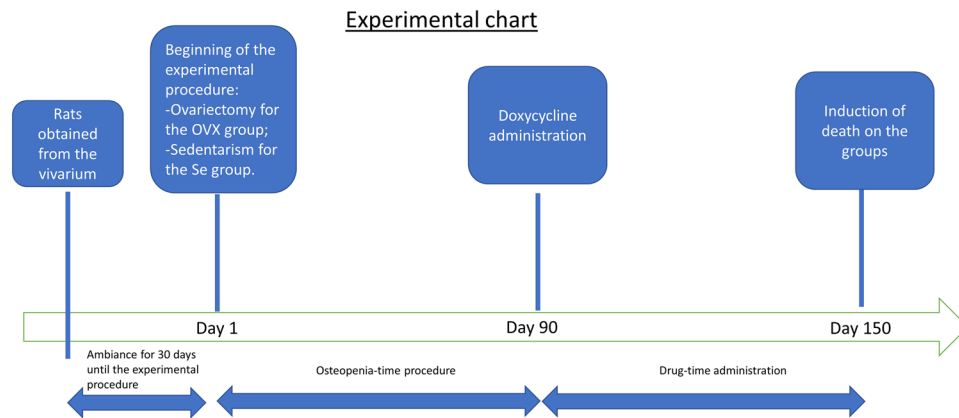


Figure 2. Flow chart with the interventions on present work.

As for the division of the groups. Control group with Doxycycline 10 mg/kg/day (C10), Control with Doxycycline 30 mg/kg/day (C30), and Control (C), Ovariectomized Group with Doxycycline 10 mg/kg/day (OVX10), Ovariectomized with Doxycycline 30 mg/kg/day (OVX30) and Ovariectomized with water (OVX), Sedentary group with 10 mg/kg/day (Se10), Sedentary group with 30 mg/kg/day (Se30) and Sedentary group with Water (Se).

Procedure of ovariectomy. The animals were anesthetized with Xylazine and Ketamine in concentration 10 mg/kg and 100 mg/kg, respectively, followed by trichotomy and the skin were prepared with antiseptic. A caudal midline incision was made from the umbilicus to the pelvis and the ovarian horn was exteriorized between the bottom of costal edge and the top of the pelvis. Shortly thereafter the evisceration of the ovary horn was executed followed by ovary ligation for containing the bleeding. The same procedure was performed on the opposite side to the excision to excise both ovaries^{20,22,23}. After the surgical procedure, the application of antibiotics was performed (Veterinary pentabiotic, Zoetis, Parsippany-Troy Hills, New Jersey, USA) once a day for a period of 48 hours after the surgery. The osteopenia was induced for 90 days after the surgical procedure, once significant findings occurring through this time of experiment^{34,35}. Then the groups received doxycycline (Bioquanti, compounding pharmacy, Ribeirao Preto, SP, Brazil) at 2 concentrations for 60 days.

Procedures for the sedentary groups. Females of this group were divided in individual cages with 30cmx20cmx16cm with superior grid, limiting their movements for 90 days to mimic a sedentary lifestyle^{24,36,37}. Then the Se10 and Se30 groups received the medicine for 60 days. The low locomotion induction of osteopenia (Sedentary lifestyle induction on rats) is used not as a method of disuse, but a method of restriction of movement, that culminates on osteopenia.

Administration of doxycycline. After the 90 days, doxycycline was administered for 60 days (for comparison between groups) in drinking water²², serviced according to a daily chart daily chart of total body weight (Fig. 3) and based on how much the rats drank water, with all duly noted and monitored. The two chosen doses were based on previously published studies^{38–41}, their application were assed because of it is safe use for 60 days and for the mimetics aspect with the SDD use in humans for 2 years.

At the end of the experiment, the animals were euthanized by an overdose of anesthetic (xylazine at 30 mg/kg and ketamine at 150 mg/kg) followed by CO₂ inhalation. The bones were removed and cleaned of soft tissue for the subsequent analyses.

Sampling and analysis. The left femoral bone samples were intended for bone densitometry and samples of right femoral bone were intended for histological analysis. It has been used samples of right tibia for chemical quantification of calcium, magnesium, zinc and phosphorus. The total weight of the rats was assessed in precision scales. The left femur (dry by an oven at 37 degrees Celsius) was weighted in laboratory precision scale BioPrecisa FA2104N (Curitiba, PR, Brazil) and the length of the femoral bones were measured with the aid of a digital caliper (MTX group, Guarulhos, Sao Paulo, Brazil) that measured the bones in your long axis. The blood serum was used for measurement of calcium and total cholesterol.

Quantification of calcium and cholesterol in serum. The whole blood of animals was obtained by cardiac puncture. Tubes containing the whole blood were centrifuged (800 × g, 6 min) to obtain serum^{42,43}. Syringes and needles were previously decontaminated in nitric acid 3%⁴⁴.

For calcium measurement, the catalyst of phosphorus (phosphate binder on medical activities^{45–47}) content of sample was the lanthanum that separate this typical interference of this sample in this kind of analysis⁴⁸. Lanthanum was placed on ratio of 0.5% of the total volume thinned and the samples were analyzed in a flame atomic absorption (Perkin Elmer AAS400, Norwalk, USA).

Quantification of total cholesterol was perform using the Cholesterol Liquiform Kit (Labtest Diagnóstica, Lagoa Santa, MG, Brazil) in a colorimetric plate adapted for the BioTek µQuant (BioTek, Winooski, VT, USA) equipment. The method used for this measurement was “End-point Colorimetric Assay - 500 nm”.

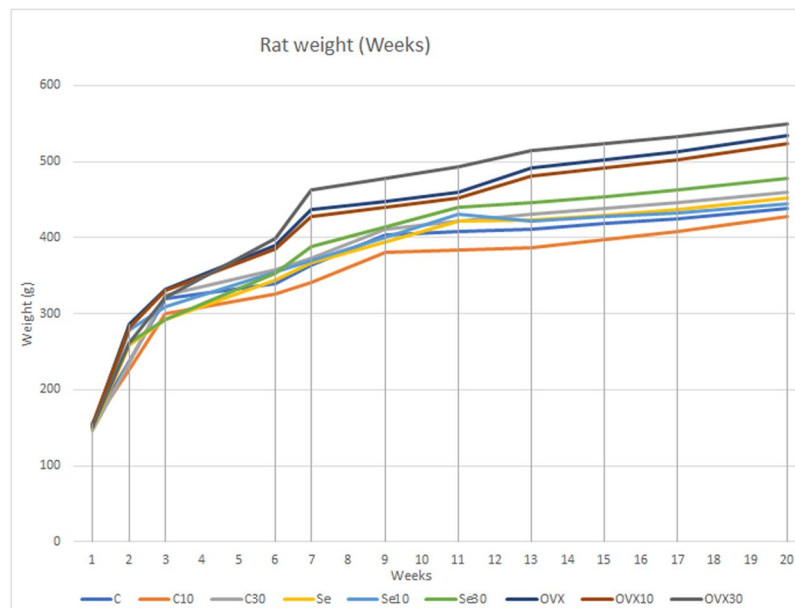


Figure 3. Graph of the weights of the rats from day of experiment until the day of induction of death (20th week).

Bone densitometry. The left femora were submitted to densitometric analysis using “dual-energy” x-ray densitometer equipment, Alpha, Lunar DPX[®] (Lunar, Madison, WI, United States) installed at the School of Medicine of Ribeirao Preto. Adapted for measurement small animals with the PIXImus software (Lunar, Madison, WI, United States)^{49,50}. The image acquisition is proceeded with the femurs (distal portion of the femur) position with ROI of 9 mm² (Fig. 4), immersed in a depth of 2 cm of deionized water (simulating soft tissues) and the following options have been selected: Type 1 Appendicular Bone; high resolution mode; 76 kVp; 150 μA; Collimation; standard 40 mm × 20 mm areas.

Bone mass content (BMC) and bone mineral density (BMD) were obtained.

Chemical analyses of calcium, magnesium and zinc in the bones. All materials used in the analysis were decontaminated in distilled nitric acid. To perform the analytical test a bi-distilled acid was diluted with deionized water ultrapure to reach 3% of acid on solution. Bone was dried in Chapel of laminar flow, to prevent the deposition of dust⁴⁴. All this was done to avoid contamination of specimens.

The right tibias were submerged in half on bi-distilled nitric acid 3% for 1 minute⁵¹, then the bone was withdraw and the solution were submitted to chemical analysis. The biopsy was performed to make the results measurable on the calibration curve.

Immunohistochemistry analysis by TRAP. The immunohistochemical analysis was performed by a certified morphologist and blind to the treatment. A semi-quantitative analysis was carried using a histological section of each animal, in the original increase of 200X. The pattern of immunolabeling was assigned a score. The criterion adopted for the establishment of the scores was based and modified from those established by Faria *et al.*⁵², where: 0 SCORE = absence of immunolabeling; 1 = low SCORE ± standard; 2 = moderate SCORE ± standard; 3 = high SCORE ± standard (Table 1 and Fig. 5).

Analysis of bone by masson trichrome and picrosirius-red staining. The quantitative analysis of the histological glasses allows to evaluate the bone microarchitecture in the proximal and distal epiphysis areas by Masson trichrome staining^{22,23}. Picrosirius-red staining allows to quantify the total collagen on the histological glasses. It was used a light microscope Axioimager Z2 Zeiss (Carl Zeiss, Oberkochen, Germany) coupled to a digital camera, aided by a DELL Precision T3500 workstation (DELL, São Paulo, Brazil). The digital images obtained from the Masson trichrome staining were analyzed by the software AxioVision 4.8 (Carl Zeiss, Oberkochen, Germany) on 25x of magnification. The quantification of total collagen obtained from picrosirius-red staining was obtained on magnification of 40x and was analyzed by ImageJ program (NIH, USA) using the plugins needed for this achievement. For quantitative analysis were focused the area of 30 mm² of the cancellous bone region (withdraw the growth plate), a distal and proximal acquisitions (Fig. 6), histological sections with 5 μm of thickness stained by Masson trichrome were analyzed by quantitative and qualitative analysis between the groups and were discussed below in the section “Results”⁵³ (Figs 7 and 8).

Analysis of the samples. Densitometry results were demonstrated in mg/mm² for BMD and Milligram (mg) for BMC with the x-rays focusing on 9 mm² on distal portion of femoral bone. Quantification data from calcium, magnesium and zinc were expressed in milligram per gram (mg/g). Quantification of cancellous bone was expressed on Pixels². Measures of total weight of animals were expressed in grams (g). Femur length was shown

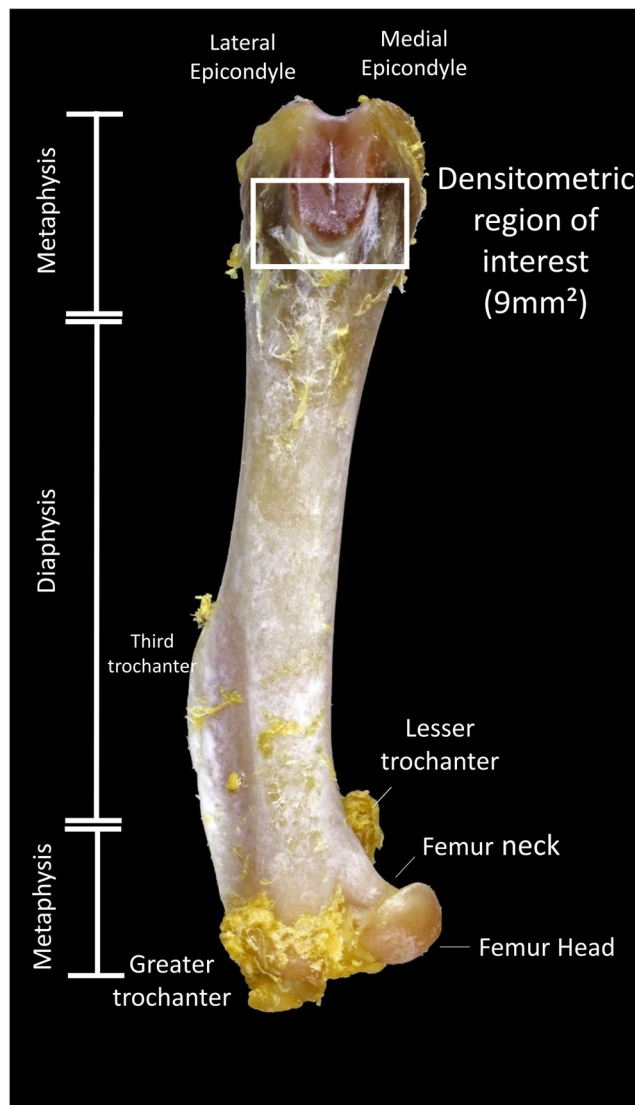


Figure 4. Photograph of a femur bone used on the present work showing the area of interest for the densitometric analysis (Square symbol on the photograph) and the anatomical points distinguishing the area of interest.

TRAP (ESCORE - MEDIAN)		
C	SCORE 2	MODERATED immunolabeling
C10	SCORE 1	LOW Immunolabeling
C30	SCORE 1	LOW Immunolabeling
OVX	SCORE 3 ^a	HIGH Immunolabeling
OVX10	SCORE 2	MODERATED Immunolabeling
OVX30	SCORE 1	LOW Immunolabeling
Se	SCORE 3 ^b	HIGH Immunolabeling
Se10	SCORE 2	MODERATED Immunolabeling
Se30	SCORE 1	LOW Immunolabeling

Table 1. Immunolabeling for TRAP. **A-i:** photomicrography showing the standard to TRAP in C (**A**), C10 (**B**), C30 (**C**), (**D**) OVX, OVX10 (**E**), OVX30 (**F**), Se (**G**), Se10 (**H**), Se30(**I**). ^aIndicates the difference between OVX vs. OVX30 and ^bindicates difference between Se and Se30 with $p < 0.00001$ between the groups with the same letter superscript. Symbols: Red arrows: immunostained cells. Against-coloration: Harris Hematoxylin. Magnification: 1000x. Scale bars: 30 micrometers.

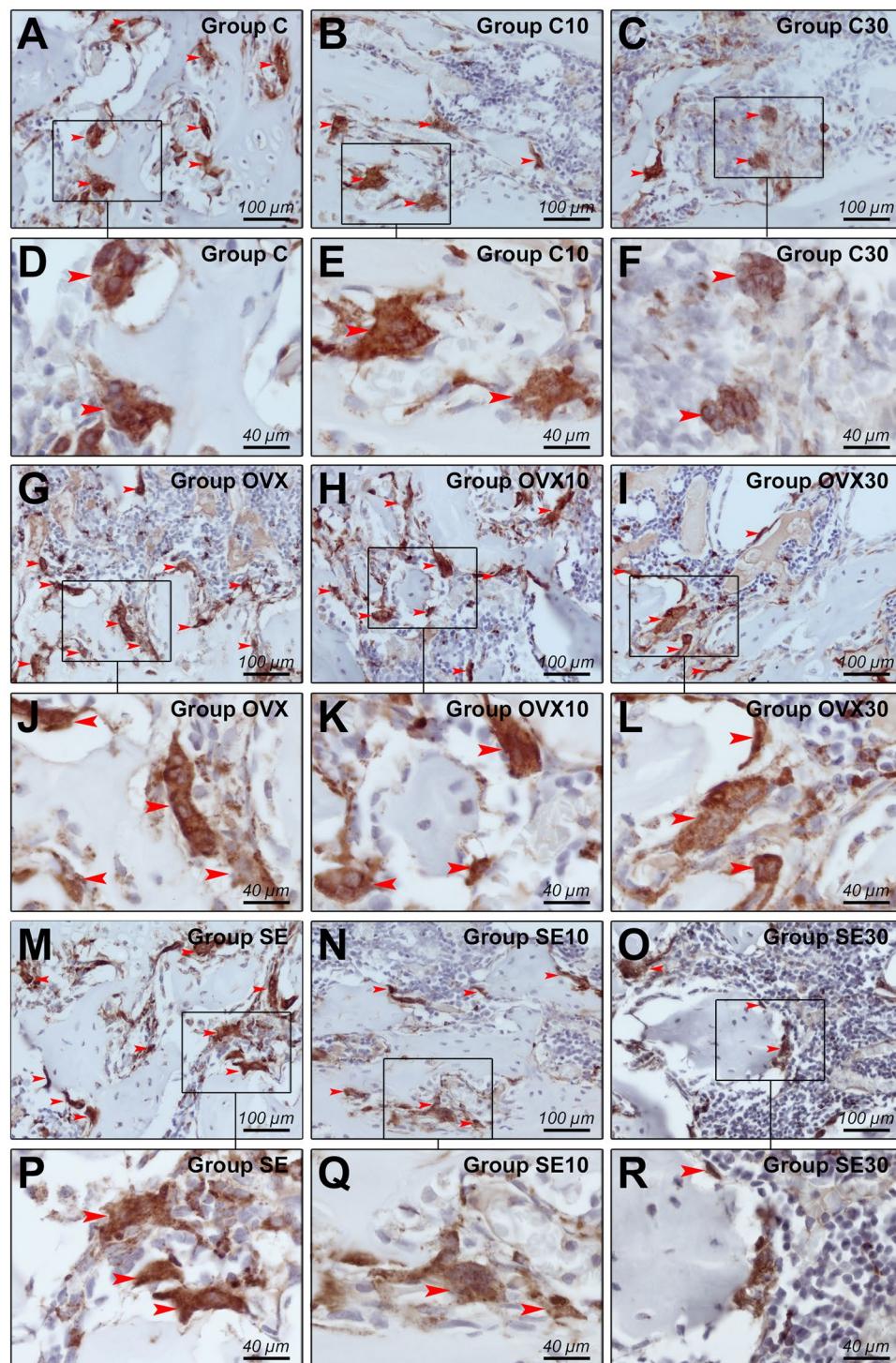


Figure 5. Immunolabeling for TRAP. (A–R) Photomicrographs showing the immunolabeling standard for TRAP in groups C (A,D), C10 (B,E), C30 (C,F), OVX (G,J), OVX10 (H,K), OVX30 (I,L), Se (M,P), Se10 (N,Q), Se30 (O,R). Symbols: Red arrows: Immunolabeling cells, and rectangles: increases in the areas listed. Counter-staining: Harris Hematoxylin. Increase: (A–C), (G–I), (M–O) 400x of magnification; (D–F), (J–L), (P–R) 1000x of magnification.

in centimeters (cm) and the bone weight was demonstrated in milligrams (mg). Serum samples were subjected to measurements of the quantity of total calcium and total cholesterol, these data were expressed in milligram per deciliter (mg/dL).

Statistical analysis. The software used for statistical analysis was SPSS 20.0 (IBM, New York, NY, USA) and the samples were submitted to the general linear model test, and all comparisons were submitted to Bonferroni

Histomorphometric area of interest

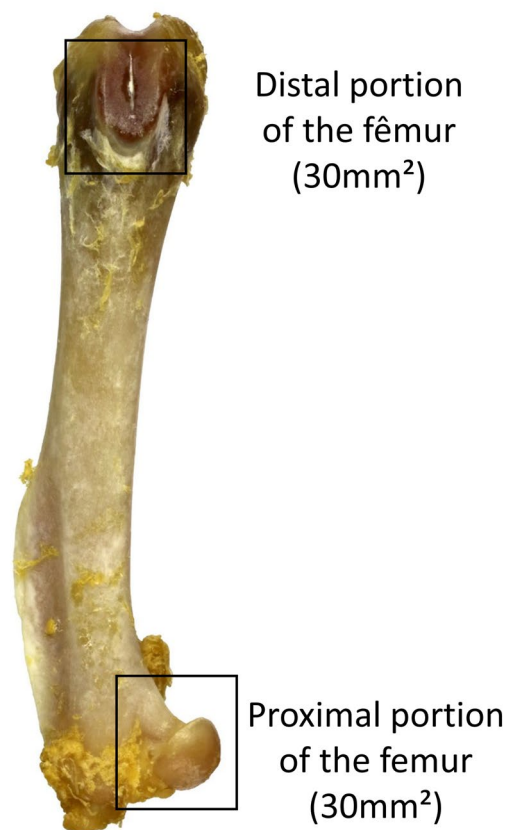


Figure 6. Photograph of a femur bone used on the present work showing the area of interest used for the quantification of cancellous bone (Square symbols on the photograph).

adjustment^{24,49}. Analysis of TRAP were subjected to normality test and then it was subjected to nonparametric test with Kruskal Wallis as analysis of variance, with a post-test of Dunn that was held to specify these differences. The results were considered different when $p \leq 0.05$.

Results

The results represented on the Table 2 have the first column with the analysis made. The other 3 columns have the results mean (standard deviation) and the fourth column have the p value with the differences points as “a” and “b” corresponding to the line of the analysis.

Preclinical findings. Twenty eight percent of the rats from Se group (because they were isolated in individual cages) presented eruptions on skin at the final week of the study, as a result of absence hygiene, motivated by the absence of contact with other animal of the same species. Due to this, it was managed a daily treatment with rifamycin (Rifocina Spray, Sanovi Aventis, Sao Paulo, Brazil) until the induction of death and it was guaranteed that the use of this medicine did not influence on the results of this study, according to studies of bone repair where it look for infections prevention of the surgical region⁵⁴. All the animals were on good health and well treated before the palliative treatment with rifamycin.

Quantitative analysis. Quantification of cancellous bone by Masson trichrome was expressed in Pixel^{22,23}, quantification by picosirius was expressed as percentage of total collagen (%)⁵⁵ and immunolabeling for TRAP was expressed by Scores²¹.

The immunohistochemical technique for TRAP (Tartrate-resistant acid phosphatase) showed high specificity in detecting such protein. This specificity indicates an immunolabeling of osteoclastic activity⁵⁶, which was proven by the total absence of markup in the negative control reaction. Immunoreactive cells showed a brownish staining confined exclusively to the cytoplasm. The differences found was Se vs. Se30 and OVX vs. OVX30 with $p < 0.00001$, been lower osteoclast expression on OVX30 and Se30, compared to control OVX and Se, data shown on Table 1.

Table 2 shows the values of the averages with their respective standard deviations in parentheses and followed by the p value when there are significant differences, showing a comparison between groups.

BMC demonstrated that the control C vs. C10 ($p = 0.018$) and C vs. C30 ($p < 0.0001$) had statistically significant differences, been higher values of BMC attributed to the control C. In the OVX group, OVX vs. OVX10

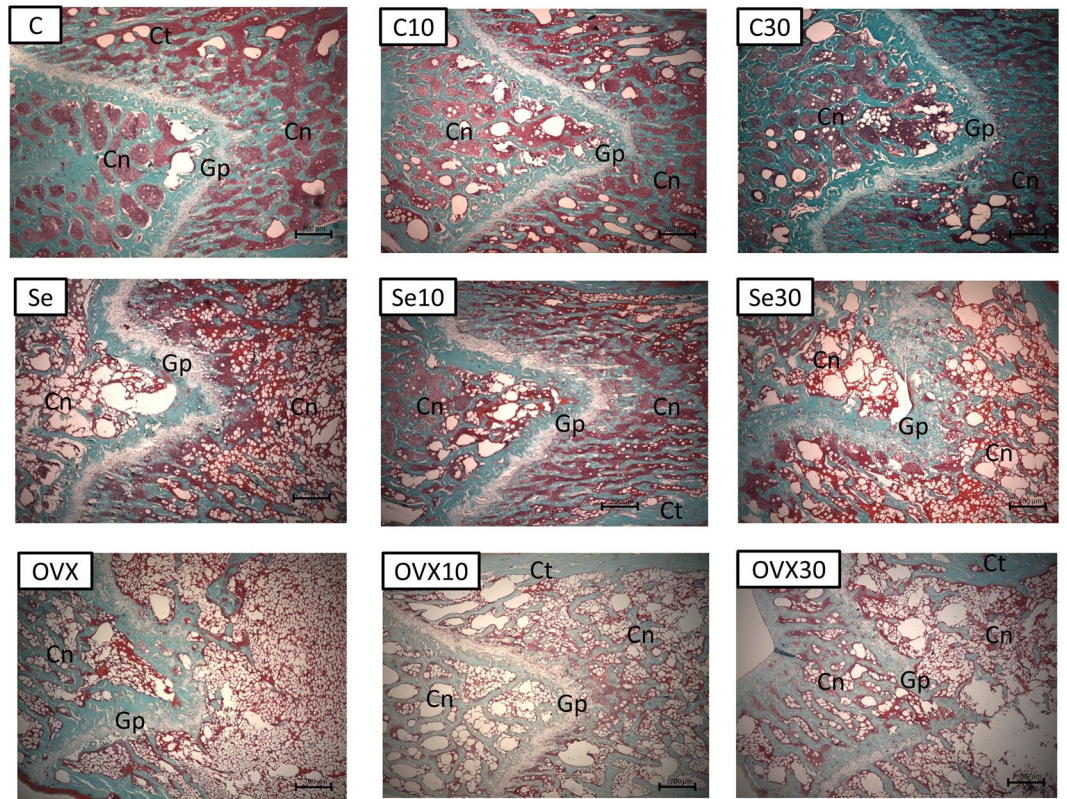


Figure 7. Histological photomicrograph of femur bone at distal portion, demonstrating the cancellous bone (Cn), growth plate (Gp) and cortical bone (Ct). Staining: Masson trichrome: 25x of magnification.

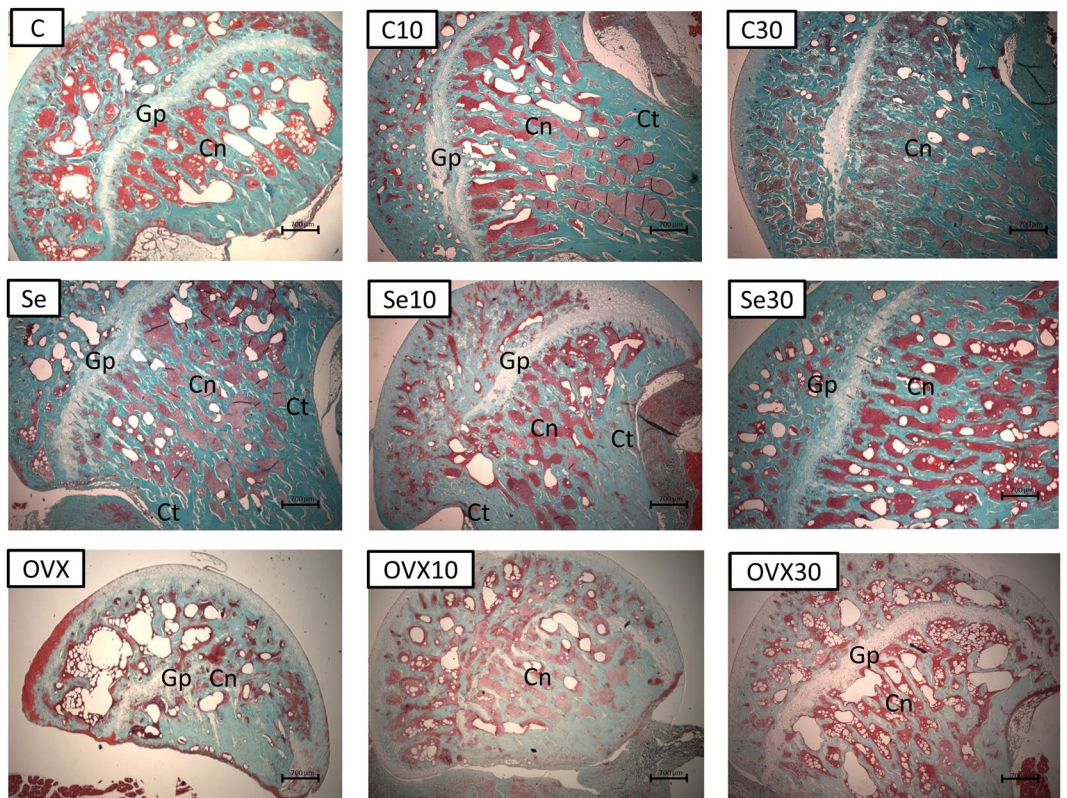


Figure 8. Histological photomicrograph of femur bone at proximal portion, demonstrating the cancellous bone (Cn), growth plate (Gp) and cortical bone (Ct). Staining: Masson trichrome: 25x of magnification.

Type of analysis\ Groups	C	C10	C30	p Value	Se	Se10	Se30	p Value	OVX	OVX10	OVX30	p Value
Results compared between the groups: Mean (Standard deviation) - $p \leq 0.05$												
BMC (mg)	26.7 (5.9) ^{ab}	21.8 (3.9)	18.6 (2.5)	^a $p = 0.018$ ^b $p < 0.0001$	12.7 (2.5) ^{ab}	21.3 (2.3)	20.4 (1.6)	^a $p < 0.0001$ ^b $p < 0.001$	8.8 (3.4) ^a	13.1 (1.3)	10.8 (2.3)	^a $p = 0.044$
BMD (mg/mm ²)	2.8 (0.6)	2.4 (0.4)	2 (0.2)		1.4 (0.2)	2.3 (0.2)	2.2 (0.2)		0.9 (0.4) ^a	1.4 (0.1)	1.2 (0.2)	^a $p = 0.031$
Calcium Bone Biopsy -mg/g	114.2 (8.2) ^{ab}	38 (5.5)	27 (8.5)	^a $p < 0.001$ ^b $p < 0.001$	27.1 (9.2)	32.5 (4.3)	32.9 (6.9)		48 (9.9)	54.2 (10.5)	54.3 (12.2)	
Magnesium Bone Biopsy -mg/g	10.5(2.8) ^{ab}	4.2(0.7)	4(0.9)	^a $p < 0.001$ ^b $p < 0.001$	3.4(1.4)	4.9(0.7)	7.8(2.7) ^{ab}	^a $p < 0.001$ ^b $p = 0.007$	6.2(1.6)	6.3(1.4)	6.3(1.3)	
Zinc Bone Biopsy -mg/g	0.7(0.2) ^{ab}	0.2 (0.1)	0.2(0.06)	^a $p < 0.001$ ^b $p < 0.001$	0.2(0.1)	0.3(0.1)	0.5(0.1)		0.4(0.08)	0.4(0.06)	0.4(0.1)	
Calcium on serum - mg/dL	12.87(23.5)	11.09(11.1)	11.84(38.6)		14.04(13.9)	14.14(20.3)	13.10(47.3)		9.36(89) ^a	12.22(21.6)	13.75(36.5)	^a $p = 0.013$
Total Cholesterol on serum - mg/dL	100(14.5)	103(15.5)	88(15.5)		115(17.7)	110(15.8)	94.7(15)		122.7(15.8)	164(17)	126(17)	
Total collagen on proximal portion of femur (%)	13.4(3.9)	16.6(4.2)	16.6(4.1)		21.9(4.2)	14.8(4.2)	20.9(4.3)		12.7(4.3)	12.2(4.7)	13.3(4.8)	
Total collagen on distal portion of femur (%)	13.3(3.4)	9.6(3.7)	11.7(3.7)		11.6(4.2)	15.3(3.7)	11.1(3.3)		9(3.7)	12.2(4.2)	19.4(4.1)	
Quantification of cancellous bone on proximal portion of femur (10 ⁻⁵) Pixel ²	15.5(1.6)	14.9(1.8)	19.6(1.7)		15.9(2)	15(1.8)	16.9(1.6)		8.7(1.8) ^{ab}	11.7(2)	17.6(2)	^a $p = 0.04$ ^b $p = 0.05$
Quantification of cancellous bone on distal portion of femur (10 ⁻⁵) Pixel ²	20.3(1.3) ^a	16.1 (1.5)	13.9 (1.4)	^a $p = 0.036$	9.4 (1.7) ^{ab}	14.7 (1.5)	17.4 (1)	^a $p = 0.05$ ^b $p = 0.02$	9.2 (1.5) ^{ab}	15.1 (1.7)	18.0 (1.5)	^a $p < 0.01$ ^b $p = 0.03$
Femur Height - mm	40.1(1.2)	36.9 (3.6)	38.4(2.9)		38.6(1.6)	37.6 (3)	37.2(4.2)		37.9 (2.4)	36.9 (4.2)	39.1 (2.6)	
Total weight - g	438.4 (43.5)	428 (44.1)	460.4 (30.1)		451.4 (30.2)	444 (34)	478 (33.2)		535 (26)	523.1 (41.1)	550.1 (39.1)	
Dry weight of femur bone- mg	731.2 (102.6)	684 (92.2)	782.7 (76.9)		791.8 (155.5)	850.7 (161.1)	851.1 (152.5)		885.4 (61)	827.8 (108.3)	872.1 (95.4)	

Table 2. Comparison between treatment groups considering only significant differences ($p \leq 0.05$). The value of p is shown on the column “p Value” with “^a” and “^b” superscript showing the differences, and if is not different it was shown no superscript letter.

($p = 0.044$) had significant differences. The group Se vs. Se10 ($p < 0.0001$) and Se vs. Se30 ($p < 0.001$) had significant differences with higher values attributed to the groups treated with doxycycline.

BMD for OVX group showed the following difference, OVX vs. OVX10 ($p = 0.031$). Sedentary group presented Se vs. Se10 ($p < 0.001$) and Se vs. Se30 ($p < 0.001$) with higher values attributed to the groups treated with doxycycline. No difference was found between C, C10 and C30.

For calcium quantification on periosteal surface of distal half of tibia bone biopsy, it was observed in the control group C vs. C10 ($p < 0.001$) and C vs. C30 ($p < 0.001$) had statistically significant differences with higher values of calcium concentration on the control C. Groups OVX and Se had no statistically significant, but have a tendency of increase of this alkaline earth metal on the groups exposed to doxycycline.

For magnesium and zinc measurements on periosteal surface of distal half of tibia bone biopsy, control group C vs. C10 ($p < 0.001$) and C vs. C30 ($p < 0.001$) had statistically significant differences with higher values of magnesium and zinc concentration on the control C. In the OVX group was not obtained significant differences on both analysis, but for quantification of magnesium on the Se group, it was observed differences when it compares the Groups Se vs. Se30 ($p < 0.001$) and Se vs. Se10 ($p = 0.007$) with higher values on the groups exposed to the doxycycline (Se10 and Se30).

Quantification of calcium on serum of control and sedentary groups, no significant differences were found, but for OVX group it was observed that OVX vs. OVX30 ($p = 0.013$) had statistically significant differences with higher concentration of calcium on serum on the group OVX30 and a tendency of increase dose-dependent of doxycycline medication on this particular group.

Quantification of cancellous bone by Masson trichrome on proximal portion of femur bone had OVX vs. OVX10 ($p = 0.04$) and OVX vs. OVX30 ($p = 0.05$) with statistical differences with an increase of cancellous bone on the groups treated with doxycycline.

Quantification of cancellous bone by Masson trichrome in distal portion of femur bone region had for the control group (C) vs. C30 ($p = 0.036$) significant differences. Ovariectomized group had OVX vs. OVX10 ($p < 0.01$) and OVX vs. OVX30 ($p = 0.03$) significant differences. Sedentary group presented the following statistical differences, Se vs. Se10 ($p = 0.05$) and Se vs. Se30 ($p = 0.02$). All the results of cancellous bone on distal portion of the bone showed that doxycycline took by control group were no beneficial, so the C has higher values than C30, but when the disease is established, the medication showed higher values for Se10 and S30 and OVX10 and OVX30 in comparison to its controls.

On the other hand, for total weight of the rats before death induction, total cholesterol, quantification of collagen by picrosirius, total length of femurs and femoral weight, no differences were found.

Qualitative analysis for histology. *Trichrome of masson.* Histological photomicrographs stained by Trichrome of Masson are represented at distal portion – Fig. 7 and proximal portion – Fig. 8. The cancellous bone (Cn), growth plate (Gp) and the cortical bone (Ct) are indicated in both figures.

The letters in the upper left corner are referred to the experimental groups of this work Group C: control without doxycycline or any treatments; Group C10: Doxycycline 10 mg/kg induced; Group C30: Doxycycline 30 mg/kg induced; Group Se: Sedentary control; Se10 Group: Sedentary 10 mg/kg/day; Se30 Group: sedentary lifestyle 30 mg/kg/day; OVX Group: control Ovariectomized; OVX10 Group: Ovariectomy 10 mg/kg/day and OVX30 Group: Ovariectomy 30 mg/kg/day.

Figures 7 and 8 shows histological images of cancellous bone with the thickness of 5 μm on the area of 30 mm^2 , the presented results was expressed in Pixel²^{22,23} by the software AxioVision 4.8 (Carl Zeiss, Oberkochen, Germany) which distinguishes the cancellous bone from cortical bone and the growth plate portion, using the spectrum of color to delimitated the area of interest.

Figure 7C presented a mineralized normal bone tissue with cancellous bone distributed uniformly (Cn) and the growth plate across the distal portion of the bone as normal and uniform mode (Gp). Figure 7 -C10 had a mineralized bone tissue with the same distributions, however to a lesser amount of cancellous bone when comparing with the bone tissue of Fig. 7C as the cancellous bone (Cn) appeared slightly more spaced. Growth plate (Gp) showed ticker aspect in this section. Figure 7 C30 had the presence of a mineralized bone tissue with slight decreases in bone quality. This fact may be caused by the reduced amount of cancellous bone (Cn) and wide space distance between cancellous tissue contrasting with the control (Fig. 7C).

Figure 7 -Se showed the presence of a bone tissue affected by a degenerative disease caused by sedentary Wistar rats induced in females. Cancellous bone (Cn) showed a large spacing between themselves and the growth plates (Gp) altered more their thicknesses. Figure 7 -Se10 showed a great improvement of the cancellous bone tissue (Cn) combined with an irregularity presented in growth plate (Gp) demonstrating that doxycycline is able to change the growth plate morphology. Figure 7 -Se30 demonstrated a large amount of cancellous bone tissue (Cn) and a change more evident in the growth plate (Gp).

Figure 7 -OVX had the presence of a bone tissue affected by a degenerative disease caused by bilateral ovariectomy in female Wistar rats, with spacing of cancellous bone (Cn) and thick growth plate (Gp) (Yao *et al.*, 2006). Figure 7 -OVX10 and -OVX30 had been an increase in the number of cancellous bone and a decrease in the changes in growth plate thickness (Gp).

Figure 8 (proximal femur) showed no significant differences in cancellous bone (Cn), in exception for OVX group. It was found changes in growth plate (Gp) on samples of rats exposed to Doxycycline for 60 days (Figures-C10, C30, Se10, Se30 and OVX30 and this growth plate was absent completely in Figure-OVX10). According to statistical differences found in Table 2, OVX vs. OVX10 $p = 0.04$ and OVX vs. OVX30 $p = 0.05$ had statistically significant.

Picrosirius-red. Data obtained from samples submitted to picrosirius red staining (data not shown) did not shown statistical differences on total collagen (Table 2). It suggests that the doses were not enough for changing the total amount of total collagen on bone, but it well known that the inhibition of collagenase is one of the actions of doxycycline⁵⁷⁻⁵⁹. This fact did not result in changes on the quantification of total collagen at this work.

Discussion

Data of immunolabeling for TRAP showed semi-quantitative differences, with higher immunostaining identification for control group compared to the exposed to doxycycline 10 mg/kg/day and 30 mg/kg/day, demonstrating that the doxycycline in these two doses inhibited osteoclast action in this study. This type of inhibition had been described in previous *in vitro* studies^{60,61}.

Figure 1- shows the molecule of doxycycline^{62,63} in the anhydrous form (Fig. 1). The lower portion of the molecule doxycycline is capable of bivalent metal binding⁴. A study affirmed that in the presence of Zn^{2+} ions, there is the occurrence of competition for the catalytic site of MMP-7 connected prior to Ca^{2+} Ion, thus inhibiting activity of MMP-7⁶⁴, although it is known that tetracyclines are chelators of Zn^{2+} ions⁶⁵, the actual mechanism of inhibition of MMPs are not yet clear.

Tetracyclines have 4 aromatic rings (Fig. 1) and also have characteristic of chelating bivalent metal in physiological conditions, forming chelate complexes⁶⁶. In this study, the authors tested the association (calculating the equilibrium constants of association) between several divalent metals and tetracycline, considering the following metals: Mg, Ca, Sr, Ba, Mn, Fe, Co, Ni, Cu, Zn and Cd. The constant of association varied in 3 orders of magnitude, and the results show that under physiological conditions, the metals with higher-to-low affinity for tetracycline are first order Ba, Sr, Cd, followed by the second order Ca, Mg, Cu, Mn and Zn. Only the third order

Fe, Ni and Co had lower affinity than zinc (about 5 times less). However, since the physiological levels of calcium are at the millimolar level, which is the metal that is connected to tetracycline. Other divalent metals are in much lower concentrations⁶⁶.

In addition, tetracyclines inhibit MMP-13 and this type of MMP is intrinsically related to the biology of growth plate of the bones. The type X collagen is found in smaller quantities in MMP-13 knockout mice and the lack of expression of this type of collagen are related to the dwarfism and is related to changes in activities of chondrocytes⁶⁷. It is known that the hypertrophic chondrocyte is responsible for three actions on bone: 60% of bone growth, 30% of the mineral deposition in the bone and 10% of cellular proliferation⁶⁸.

MMP-2 was first isolated from bone, and it is very important for normal bone maintenance⁶⁹. Lack of activity of MMP-14 (MT1-MMP) induces dwarfism, osteopenia, arthritis, and connective tissue disease⁷⁰. Therefore, the use of doxycycline would also inhibit MT1-MMP and other MMPs⁷¹, since this drug is not selective.

Morphological analysis showed a clear improvement on the quality of cancellous bone accordingly to histological analyses (Figs 7 and 8). Data from distal portion of the femur bone in Wistar rats with osteopenia induced exposed to two doses of doxycycline (Se10, Se30, OVX10 and OVX30), permits to infer that this medicine is able to improve the quality of the bone structure compared to the control groups (C, Se and OVX). This finding was described in Table 2 and Fig. 7 and is supported by another study using orthodontic tooth movement in mice⁷². On this related study there was a smaller dental root resorption in rats subjected to Doxycycline for 7, 10 and 14 days of orthodontic treatment and on orthodontic movement it was found lesser amount for TRAP immunostaining at the group exposed to Doxycycline during tooth movement⁷². Gomes and Fernandes concluded an *in vitro* study that doxycycline and minocycline promoted human osteoblastic cells proliferation and this led to a later mineralization, which allowed to consider that doxycycline may induce bone mineralization⁷³ and less bone resorption⁷². Considering this kind of dental intervention it is well sedimented in the literature that orthodontic movement induces an inflammatory reaction, which is considered a normal side effect for orthodontic practice⁷⁴.

Limirio and collaborators showed that doxycycline 10% associate to alendronate 1% increase the time of bone neoformation on 7 and 15 days on rats with femur osteotomy. Their findings suggest that doxycycline associated to alendronate on the defect suppress the osteoclasts and had less bone neoformed on 7 days⁷⁵, this data corroborate to our findings on control groups (C, C10 and C30), which doxycycline SDD have a negative rule on the physiological bone. But long-term treatment (60 days) of SDD on physiological bone, without osteopenia, was never tested. Normally the doxycycline is studied for bone repair or alveolar repair⁷⁶ with positive results, but never tested on long-term SDD on long bones.

Another study performed in dogs, showed that doxycycline is able to reduce bone loss caused by endodontic peri radicular surgery⁷⁷. However, another study showed that doxycycline does not improve the quantity and quality of tissue repair on bone in Wistar rats subjected to dental extraction and subsequently treated for 7 days on doxycycline and erythromycin⁷⁸. This fact may be comprehended in this previous cited work, explaining that the rats were subjected to a short period of treatment with doxycycline (7 days) and the quantification was injured because of this short time of treatment.

In this present research, doxycycline inhibited osteoclastic bone action⁷⁶, and therefore this drug was beneficial for bone under conditions of high osteoclastic activity. However, under normal physiological conditions, it is not beneficial for bone. It is worth pointing out that doxycycline can increase osteoblast action, perhaps by modifying the unbalance caused by osteoporosis where it had an increase in the action of osteoclasts cells, and a decrease in the action of osteoblasts cells^{18,76}. Apparently looking for this topic at current literature and results contained in this present work, we can summarize that doxycycline decreases osteoclastic action^{60,61,76} and increases osteoblast action^{73,76}. However, it is not known how this “re-balance” happens, further studies are needed to prove that.

It is well known that doxycycline chelates divalent metals⁶⁶ and this interaction between doxycycline and divalent metal calcium is important for the health of bone tissue, as in the study of Weaver and colleagues sought to measure bone quality via the urinary excretion of Calcium isotopes. The authors used an isotope of tetracycline to make this measurement and with that, the authors could measure almost immediately the differences after induction of osteopenia by ovariectomy⁷⁹.

There are several questionings about the fact that doxycycline being an antibiotic and does not present an increase of microbial resistance. In humans, the dose of 20 mg/kg/day does not present increased subgingival flora⁸⁰ and it is used as metalloproteinase inhibitor for treatment of periodontitis^{5,81}. Furthermore, the use of doxycycline at this dose has already been proven not antimicrobial (SDD), not affecting the skin floras⁸². As the tetracyclines, minocycline and doxycycline, are widely used for antimicrobial purpose (skin problems) at SDD^{83–88}.

Data shows that the amount of calcium present in serum seemed to have contributed positively for bone increase (with an increase in serum calcium of samples from the OVX10 and OVX30 groups compared with OVX). Densitometric and histological findings corroborate with the clinical improvement of bone quality. Calcium homeostasis is a mechanism closely regulated in our body⁸⁹, so, further studies are needed to determine whether doxycycline really changes serum calcium and whether those changes reflect bone changes or induce bone changes. It is tempting to say that doxycycline can carry calcium to the bone in osteoporotic rats. The same affirmation is not true with controls, in which doxycycline had deleterious effects.

In conclusion, SDDs for a long time (sixty days) in 2 models of osteopenia (hormone-dependent and sedentarism-induced) in female rats had positive effects on bone, particularly well characterized the decrease in osteoclastic activity. On the control groups doxycycline was mostly deleterious, with exception the quantification of cancellous bone with a slight increase of collagen quantification on proximal portion of the femur. Osteopenic animals also showed increased densitometric data in bone analyses in femurs, and a higher quality of cancellous bone was observed in the osteopenic groups that received doxycycline. According to the results of this study, doxycycline had a high therapeutic potential for the long-term treatment of osteopenia.

Received: 6 February 2019; Accepted: 30 September 2019;

Published online: 25 October 2019

References

- Sapadin, A. N. & Fleischmajer, R. Tetracyclines: nonantibiotic properties and their clinical implications. *J Am Acad Dermatol* **54**, 258–265, <https://doi.org/10.1016/j.jaad.2005.10.004> (2006).
- Valentín, S., Morales, A., Sánchez, J. L. & Rivera, A. Safety and efficacy of doxycycline in the treatment of rosacea. *Clin Cosmetol Invest Dermatol* **2**, 129–140 (2009).
- Golub, L. M. *et al.* Adjunctive treatment with subantimicrobial doses of doxycycline: effects on gingival fluid collagenase activity and attachment loss in adult periodontitis. *Journal of clinical periodontology* **28**, 146–156 (2001).
- Tan, K. R., Magill, A. J., Parise, M. E. & Arguin, P. M. Doxycycline for Malaria Chemoprophylaxis and Treatment: Report from the CDC Expert Meeting on Malaria Chemoprophylaxis. *The American Journal of Tropical Medicine and Hygiene* **84**, 517–531, <https://doi.org/10.4269/ajtmh.2011.10-0285> (2011).
- Thomas, J., Walker, C. & Bradshaw, M. Long-Term Use of Subantimicrobial Dose Doxycycline Does Not Lead to Changes in Antimicrobial Susceptibility. *Journal of Periodontology* **71**, 1472–1483, <https://doi.org/10.1902/jop.2000.71.9.1472> (2000).
- Wallner, H. J. & Schmiedel, A. Blood serum levels in mother and child after oral administration of doxycycline ante partum (author's transl). *MMW, Munchener medizinische Wochenschrift* **117**, 349–352 (1975).
- Duivenvoorden, W. C. *et al.* Doxycycline decreases tumor burden in a bone metastasis model of human breast cancer. *Cancer research* **62**, 1588–1591 (2002).
- Saikali, Z. & Singh, G. Doxycycline and other tetracyclines in the treatment of bone metastasis. *Anti-cancer drugs* **14**, 773–778, <https://doi.org/10.1097/01.cad.0000099002.92896.cf> (2003).
- Golub, L. M. *et al.* Doxycycline Effects on Serum Bone Biomarkers in Post-menopausal Women. *Journal of Dental Research* **89**, 644–649, <https://doi.org/10.1177/0022034510363367> (2010).
- Bezerra, M. M., Brito, G. A. C., Ribeiro, R. A. & Rocha, F. A. C. Low-dose doxycycline prevents inflammatory bone resorption in rats. *Brazilian Journal of Medical and Biological Research* **35**, 613–616 (2002).
- Riggs, B. L. & Melton, L. J. III Involutional osteoporosis. *The New England journal of medicine* **314**, 1676–1686, <https://doi.org/10.1056/nejm198606263142605> (1986).
- Turner, C. H. Biomechanics of bone: determinants of skeletal fragility and bone quality. *Osteoporosis international: a journal established as result of cooperation between the European Foundation for Osteoporosis and the National Osteoporosis Foundation of the USA* **13**, 97–104, <https://doi.org/10.1007/s001980200000> (2002).
- NIH. Osteoporosis, <https://www.nia.nih.gov/health/osteoporosis> (2019).
- Ross, P. D., Genant, H. K., Davis, J. W., Miller, P. D. & Wasnich, R. D. Predicting vertebral fracture incidence from prevalent fractures and bone density among non-black, osteoporotic women. *Osteoporosis international: a journal established as result of cooperation between the European Foundation for Osteoporosis and the National Osteoporosis Foundation of the USA* **3**, 120–126 (1993).
- Bandeira, F. & Carvalho, E. Fd Prevalência de osteoporose e fraturas vertebrais em mulheres na pós-menopausa atendidas em serviços de referência. *Revista Brasileira de Epidemiologia* **10**, 86–98 (2007).
- Malina, R. M., Bouchard, C. & Bar-Or, O. *Growth, Maturation, and Physical Activity*. (Human Kinetics, 2004).
- Matsuo, K. Cross-talk among bone cells. *Current opinion in nephrology and hypertension* **18**, 292–297, <https://doi.org/10.1097/MNH.0b013e32832b75f1> (2009).
- Teitelbaum, S. L. Bone Resorption by Osteoclasts. *Science (New York, N.Y.)* **289**, 1504–1508, <https://doi.org/10.1126/science.289.5484.1504> (2000).
- Jee, W. S. & Yao, W. Overview: animal models of osteopenia and osteoporosis. *J Musculoskeletal Neuronal Interact* **1**, 193–207 (2001).
- Shimano, A. C., Volpon, J. B. & Lima, R. S. *Ação do Treinamento Físico Antes e Após a Instalação da Osteopenia de Ratas Ovariectomizadas*. (Faculdade de Medicina de Ribeirão Preto/USP, 2008).
- Shimano, R. C. *et al.* Biomechanical and microstructural benefits of physical exercise associated with risedronate in bones of ovariectomized rats. *Microsc Res Tech* **77**, 431–438, <https://doi.org/10.1002/jemt.22363> (2014).
- Issa, J. P. M. *et al.* The effect of simvastatin treatment on bone repair of femoral fracture in animal model. *Growth Factors* **33**, 139–148, <https://doi.org/10.3109/08977194.2015.1011270> (2015).
- Monteiro, L. O. *et al.* Effect of treatment with simvastatin on bone microarchitecture of the femoral head in an osteoporosis animal model. *Microscopy Research and Technique* **79**, 684–690, <https://doi.org/10.1002/jemt.22682> (2016).
- Macedo, A. P. *et al.* Influence of treadmill training on bone structure under osteometabolic alteration in rats subjected to high-fat diet. *Scandinavian Journal of Medicine & Science in Sports* **27**, 167–176, <https://doi.org/10.1111/sms.12650> (2017).
- Wang, Y., Monteiro, C. & Popkin, B. M. Trends of obesity and underweight in older children and adolescents in the United States, Brazil, China, and Russia. *The American journal of clinical nutrition* **75**, 971–977 (2002).
- Duncan, S. *et al.* Modifiable risk factors for overweight and obesity in children and adolescents from Sao Paulo, Brazil. *BMC Public Health* **11**, 585 (2011).
- Fernandes, R. A. *et al.* Prevalence of dyslipidemia in individuals physically active during childhood, adolescence and adult age. *Arq Bras Cardiol* **97**, 317–323 (2011).
- Bass, S. *et al.* Exercise before puberty may confer residual benefits in bone density in adulthood: studies in active prepubertal and retired female gymnasts. *Journal of bone and mineral research: the official journal of the American Society for Bone and Mineral Research* **13**, 500–507, <https://doi.org/10.1359/jbmr.1998.13.3.500> (1998).
- Morris, F. L., Naughton, G. A., Gibbs, J. L., Carlson, J. S. & Wark, J. D. Prospective ten-month exercise intervention in premenarcheal girls: positive effects on bone and lean mass. *Journal of bone and mineral research: the official journal of the American Society for Bone and Mineral Research* **12**, 1453–1462, <https://doi.org/10.1359/jbmr.1997.12.9.1453> (1997).
- Kontulainen, S. *et al.* Good maintenance of exercise-induced bone gain with decreased training of female tennis and squash players: a prospective 5-year follow-up study of young and old starters and controls. *Journal of bone and mineral research: the official journal of the American Society for Bone and Mineral Research* **16**, 195–201, <https://doi.org/10.1359/jbmr.2001.16.2.195> (2001).
- MacKelvie, K. J., Khan, K. M., Petit, M. A., Janssen, P. A. & McKay, H. A. A school-based exercise intervention elicits substantial bone health benefits: a 2-year randomized controlled trial in girls. *Pediatrics* **112**, e447 (2003).
- Karlsson, M. K. *et al.* Exercise during growth and bone mineral density and fractures in old age. *Lancet (London, England)* **355**, 469–470 (2000).
- Specker, B. L. Evidence for an interaction between calcium intake and physical activity on changes in bone mineral density. *Journal of bone and mineral research: the official journal of the American Society for Bone and Mineral Research* **11**, 1539–1544, <https://doi.org/10.1002/jbmr.5650111022> (1996).
- Wronski, T. J., Cintron, M. & Dann, L. M. Temporal relationship between bone loss and increased bone turnover in ovariectomized rats. *Calcif Tissue Int* **43**, 179–183 (1988).
- Wronski, T. J., Dann, L. M., Scott, K. S. & Cintron, M. Long-term effects of ovariectomy and aging on the rat skeleton. *Calcif Tissue Int* **45**, 360–366 (1989).
- Tschoop, M. & Heiman, M. L. Rodent obesity models: an overview. *Exp Clin Endocrinol Diabetes* **109**, 307–319, <https://doi.org/10.1055/s-2001-17297> (2001).

37. Oliveira Milani, J. G. P., Matheus, J. P. C., Gomide, L. B., Volpon, J. B. & Shimano, A. C. Biomechanical Effects of Immobilization and Rehabilitation on the Skeletal Muscle of Trained and Sedentary Rats. *Annals of Biomedical Engineering* **36**, 1641–1648, <https://doi.org/10.1007/s10439-008-9542-8> (2008).
38. Castro, M. M. *et al.* Doxycycline ameliorates 2K-1C hypertension-induced vascular dysfunction in rats by attenuating oxidative stress and improving nitric oxide bioavailability. *Nitric Oxide* **26**, 162–168, <https://doi.org/10.1016/j.niox.2012.01.009> (2012).
39. Briest, W. *et al.* Significance of matrix metalloproteinases in norepinephrine-induced remodelling of rat hearts. *Cardiovasc Res* **57**, 379–387 (2003).
40. Guimaraes, D. A. *et al.* Doxycycline dose-dependently inhibits MMP-2-mediated vascular changes in 2K1C hypertension. *Basic Clin Pharmacol Toxicol* **108**, 318–325, <https://doi.org/10.1111/j.1742-7843.2010.00656.x> (2011).
41. Tharappel, J. C. *et al.* Doxycycline shows dose-dependent changes in hernia repair strength after mesh repair. *Surg Endosc* **30**, 2016–2021, <https://doi.org/10.1007/s00464-015-4434-0> (2016).
42. Amaral, J. H. *et al.* The Relationship between Blood and Serum Lead Levels in Peripartum Women and their Respective Umbilical Cords. *Basic & Clinical Pharmacology & Toxicology* **107**, 971–975, <https://doi.org/10.1111/j.1742-7843.2010.00616.x> (2010).
43. Rezende, V. B., Amaral, J. H., Gerlach, R. F., Barbosa, F. Jr. & Tanus-Santos, J. E. Should we measure serum or plasma lead concentrations? *J Trace Elem Med Biol* **24**, 147–151, <https://doi.org/10.1016/j.jtemb.2010.01.008> (2010).
44. de Figueiredo, F. A. *et al.* Reduced bone and body mass in young male rats exposed to lead. *Biomed Res Int* **2014**, 571065, <https://doi.org/10.1155/2014/571065> (2014).
45. Behets, G. J., Verberckmoes, S. C., D'Haese, P. C. & De Broe, M. E. Lanthanum carbonate: a new phosphate binder. *Current opinion in nephrology and hypertension* **13**, 403–409 (2004).
46. Sprague, S. M. A comparative review of the efficacy and safety of established phosphate binders: calcium, sevelamer, and lanthanum carbonate. *Current medical research and opinion* **23**, 3167–3175, <https://doi.org/10.1185/030079907x242719> (2007).
47. Chan, S. *et al.* Phosphate binders in patients with chronic kidney disease. *Australian prescriber* **40**, 10–14, <https://doi.org/10.18773/austprescr.2017.002> (2017).
48. Trudeau, D. L. & Freier, E. F. Determination of calcium in urine and serum by atomic absorption spectrophotometry (AAS). *Clinical chemistry* **13**, 101–114 (1967).
49. Shimano, R. C. *et al.* Effects of high-impact exercise on the physical properties of bones of ovariectomized rats fed to a high-protein diet. *Scandinavian Journal of Medicine & Science in Sports* **28**, 1523–1531, <https://doi.org/10.1111/sms.13058> (2018).
50. Yanagihara, G. R. *et al.* Influence of high-fat diet on bone tissue: An experimental study in growing rats. *The journal of nutrition, health & aging* **21**, 1337–1343, <https://doi.org/10.1007/s12603-017-0871-x> (2017).
51. Sawan, R. M. *et al.* Fluoride increases lead concentrations in whole blood and in calcified tissues from lead-exposed rats. *Toxicology* **271**, 21–26, <https://doi.org/10.1016/j.tox.2010.02.002> (2010).
52. Faria, P. E. *et al.* Immunohistochemical, tomographic and histological study on onlay iliac grafts remodeling. *Clinical oral implants research* **19**, 393–401, <https://doi.org/10.1111/j.1600-0501.2007.01485.x> (2008).
53. Dempster, D. W. *et al.* Standardized nomenclature, symbols, and units for bone histomorphometry: a 2012 update of the report of the ASBMR Histomorphometry Nomenclature Committee. *Journal of bone and mineral research: the official journal of the American Society for Bone and Mineral Research* **28**, 2–17, <https://doi.org/10.1002/jbmr.1805> (2013).
54. Freitas, S. H. D. *et al.* Tomographic imaging of fragmented cortical bone heteroimplant and methylmethacrylate in segmental bone defect of rabbit tibia. *Acta Cirurgica Brasileira* **29**, 794–800 (2014).
55. Pereira, B. F. *et al.* Effects of biodegradable detergents in morphological parameters of liver in two neotropical fish species (*Prochilodus lineatus* and *Astyanax altiparanae*). *Microscopy. Research* **2**, 39 (2014).
56. Habermann, B., Eberhardt, C., Feld, M., Zichner, L. & Kurth, A. A. Tartrate-resistant acid phosphatase 5b (TRAP 5b) as a marker of osteoclast activity in the early phase after cementless total hip replacement. *Acta Orthop* **78**, 221–225, <https://doi.org/10.1080/174536707010013717> (2007).
57. Golub, L. M. *et al.* Tetracyclines inhibit tissue collagenase activity. A new mechanism in the treatment of periodontal disease. *Journal of periodontal research* **19**, 651–655 (1984).
58. Belo, V. A. *et al.* Assessment of matrix metalloproteinase (MMP)-2, MMP-8, MMP-9, and their inhibitors, the tissue inhibitors of metalloproteinase (TIMP)-1 and TIMP-2 in obese children and adolescents. *Clinical biochemistry* **42**, 984–990, <https://doi.org/10.1016/j.clinbiochem.2009.03.025> (2009).
59. Castro, M. M., Tanus-Santos, J. E. & Gerlach, R. F. Matrix metalloproteinases: Targets for doxycycline to prevent the vascular alterations of hypertension. *Pharmacological research* **64**, 567–572, <https://doi.org/10.1016/j.phrs.2011.04.002> (2011).
60. Zhang, C., Tang, T. T., Ren, W. P., Zhang, X. L. & Dai, K. R. Inhibiting wear particles-induced osteolysis with doxycycline. *Acta Pharmacol Sin* **28**, 1603–1610, <https://doi.org/10.1111/j.1745-7254.2007.00638.x> (2007).
61. Zhou, X., Zhang, P., Zhang, C., An, B. & Zhu, Z. A. Tetracyclines Inhibit Rat Osteoclast Formation and Activity *In Vitro* and Affect Bone Turnover in Young Rats *In Vivo*. *Calcified Tissue International* **86**, 163–171, <https://doi.org/10.1007/s00223-009-9328-5> (2010).
62. Babu, E. *et al.* Human organic anion transporters mediate the transport of tetracycline. *Jpn J Pharmacol* **88**, 69–76 (2002).
63. Griffin, M. O., Fricovsky, E., Ceballos, G. & Villarreal, F. Tetracyclines: a pleiotropic family of compounds with promising therapeutic properties. Review of the literature. *American Journal of Physiology - Cell Physiology* **299**, C539–C548, <https://doi.org/10.1152/ajpcell.00047.2010> (2010).
64. García, R. A. *et al.* Molecular Interactions between Matrilysin and the Matrix Metalloproteinase Inhibitor Doxycycline Investigated by Deuterium Exchange Mass Spectrometry. *Molecular Pharmacology* **67**, 1128–1136, <https://doi.org/10.1124/mol.104.006346> (2005).
65. Peterson, J. T. Matrix metalloproteinase inhibitor development and the remodeling of drug discovery. *Heart Fail Rev* **9**, 63–79, <https://doi.org/10.1023/B:HREV.0000011395.11179.af> (2004).
66. Palm, G. J. *et al.* Specific binding of divalent metal ions to tetracycline and to the Tet repressor/tetracycline complex. *J Biol Inorg Chem* **13**, 1097–1110, <https://doi.org/10.1007/s00775-008-0395-2> (2008).
67. Ionescu, A. *et al.* FoxA family members are crucial regulators of the hypertrophic chondrocyte differentiation program. *Developmental Cell* **22**, 927–939, <https://doi.org/10.1016/j.devcel.2012.03.011> (2012).
68. Wilsman, N. J., Farnum, C. E., Leiferman, E. M., Fry, M. & Barreto, C. Differential growth by growth plates as a function of multiple parameters of chondrocytic kinetics. *Journal of orthopaedic research: official publication of the Orthopaedic Research Society* **14**, 927–936, <https://doi.org/10.1002/jor.1100140613> (1996).
69. Nagase, H. & Woessner, J. F. Jr. Matrix metalloproteinases. *The Journal of biological chemistry* **274**, 21491–21494 (1999).
70. Holmbeck, K. *et al.* MT1-MMP-deficient mice develop dwarfism, osteopenia, arthritis, and connective tissue disease due to inadequate collagen turnover. *Cell* **99**, 81–92 (1999).
71. Stechmiller, J., Cowan, L. & Schultz, G. The Role of Doxycycline as a Matrix Metalloproteinase Inhibitor for the Treatment of Chronic Wounds. *Biological Research For Nursing* **11**, 336–344, <https://doi.org/10.1177/1099800409346333> (2010).
72. Mavragani, M., Brudvik, P. & Selvig, K. A. Orthodontically induced root and alveolar bone resorption: inhibitory effect of systemic doxycycline administration in rats. *European Journal of Orthodontics* **27**, 215–225, <https://doi.org/10.1093/ejo/cji015> (2005).
73. Gomes, P. S. & Fernandes, M. H. Effect of therapeutic levels of doxycycline and minocycline in the proliferation and differentiation of human bone marrow osteoblastic cells. *Archives of oral biology* **52**, 251–259, <https://doi.org/10.1016/j.archoralbio.2006.10.005> (2007).

74. Rygh, P. Orthodontic root resorption studied by electron microscopy. *Angle Orthod* **47**, 1–16, doi:10.1043/0003-3219(1977)047<0001:orrsbe>2.0.co;2 (1977).
75. Limirio, P. H. *et al.* The Effect of Local Delivery Doxycycline and Alendronate on Bone Repair. *AAPS PharmSciTech* **17**, 872–877, <https://doi.org/10.1208/s12249-015-0411-0> (2016).
76. Gomes, K. D. N., Alves, A. P. N. N., Dutra, P. G. P. & Viana, G. S. B. Doxycycline induces bone repair and changes in Wnt signalling. *International Journal Of Oral Science* **9**, 158, <https://doi.org/10.1038/ijos.2017.28> (2017).
77. Cummings, G. R. & Torabinejad, M. Effect of Systemic Doxycycline on Alveolar Bone Loss after Periradicular Surgery. *Journal of endodontics* **26**, 325–327, <https://doi.org/10.1097/00004770-200006000-00004> (2000).
78. Shahabooei, M. *et al.* A histomorphometric study of the effect of doxycycline and erythromycin on bone formation in dental alveolar socket of rat. *Adv Biomed Res* **4**, 71, <https://doi.org/10.4103/2277-9175.153895> (2015).
79. Weaver, C. *et al.* (3)H-tetracycline as a proxy for (41)Ca for measuring dietary perturbations of bone resorption. Nuclear instruments & methods in physics research. Section B. *Beam interactions with materials and atoms* **259**, 790–795, <https://doi.org/10.1016/j.nimb.2007.02.004> (2007).
80. Walker, C. *et al.* Subantimicrobial dose doxycycline effects on osteopenic bone loss: microbiologic results. *J Periodontol* **78**, 1590–1601, <https://doi.org/10.1902/jop.2007.070015> (2007).
81. Golub, L. M. *et al.* Doxycycline inhibits neutrophil (PMN)-type matrix metalloproteinases in human adult periodontitis gingiva. *Journal of clinical periodontology* **22**, 100–109 (1995).
82. Skidmore, R. *et al.* Effects of subantimicrobial-dose doxycycline in the treatment of moderate acne. *Arch Dermatol* **139**, 459–464, <https://doi.org/10.1001/archderm.139.4.459> (2003).
83. Cohen, P. R. & Grossman, M. E. Management of cutaneous lesions associated with an emerging epidemic: community-acquired methicillin-resistant *Staphylococcus aureus* skin infections. *J Am Acad Dermatol* **51**, 132–135, <https://doi.org/10.1016/j.jaad.2004.03.010> (2004).
84. Del Rosso, J. Q. A status report on the use of subantimicrobial-dose doxycycline: a review of the biologic and antimicrobial effects of the tetracyclines. *Cutis* **74**, 118–122 (2004).
85. Pelle, M. T., Crawford, G. H. & James, W. D. Rosacea: II. Therapy. *J Am Acad Dermatol* **51**, 499–512; quiz 513–494, <https://doi.org/10.1016/j.jaad.2004.03.033> (2004).
86. Cohen, P. R. Community-acquired methicillin-resistant *Staphylococcus aureus* skin infections: implications for patients and practitioners. *Am J Clin Dermatol* **8**, 259–270 (2007).
87. Elston, D. M. Community-acquired methicillin-resistant *Staphylococcus aureus*. *J Am Acad Dermatol* **56**, 1–16; quiz 17–20, <https://doi.org/10.1016/j.jaad.2006.04.018> (2007).
88. Bhambri, S. & Kim, G. Use of Oral Doxycycline for Community-acquired Methicillin-resistant *Staphylococcus aureus* (CA-MRSA) Infections. *The Journal of Clinical and Aesthetic Dermatology* **2**, 45–50 (2009).
89. Boden, S. D. & Kaplan, F. S. Calcium homeostasis. *Orthop Clin North Am* **21**, 31–42 (1990).

Author contributions

Dr. Figueiredo were the head of the study, responsible for the figures, tables and the main writer of this article. Dr. Shimano was the responsible for the surgical experiment of the animals on the study. Prof. Ervolino was responsible for the TRAP experiment and the analysis of these findings. Dr. Pitol was the head of the histological experiment. Prof. Gerlach and Prof. Issa were the head of the two laboratories where all the experiments were made and the responsible for this study achievements. Prof. Issa is the responsible for this paper revision and respond for all the authors of this study.

Competing interests

The authors declare no competing interests.

Additional information

Supplementary information is available for this paper at <https://doi.org/10.1038/s41598-019-51702-y>.

Correspondence and requests for materials should be addressed to J.P.M.I.

Reprints and permissions information is available at www.nature.com/reprints.

Publisher's note Springer Nature remains neutral with regard to jurisdictional claims in published maps and institutional affiliations.



Open Access This article is licensed under a Creative Commons Attribution 4.0 International License, which permits use, sharing, adaptation, distribution and reproduction in any medium or format, as long as you give appropriate credit to the original author(s) and the source, provide a link to the Creative Commons license, and indicate if changes were made. The images or other third party material in this article are included in the article's Creative Commons license, unless indicated otherwise in a credit line to the material. If material is not included in the article's Creative Commons license and your intended use is not permitted by statutory regulation or exceeds the permitted use, you will need to obtain permission directly from the copyright holder. To view a copy of this license, visit <http://creativecommons.org/licenses/by/4.0/>.

© The Author(s) 2019