

Optic Disc Image Subtraction as an Aid to Detect Glaucoma Progression

Navid Amini^{1,✉}, Reza Alizadeh^{1,✉}, Nucharee Parivisutt^{1,✉}, EunAh Kim^{1,✉}, Kouros Nouri-Mahdavi^{1,✉}, and Joseph Caprioli^{1,✉}

¹ Glaucoma Division, Stein Eye Institute, David Geffen School of Medicine at UCLA, Los Angeles, CA, USA

Correspondence: Joseph Caprioli, 100 Stein Plaza, Los Angeles, CA, USA. e-mail: caprioli@jsei.ucla.edu

Received: 11 June 2017

Accepted: 22 July 2017

Published: 27 October 2017

Keywords: glaucoma; image subtraction; optic disc; structural progression

Citation: Amini N, Alizadeh R, Parivisutt N, Kim E, Nouri-Mahdavi K, Caprioli J. Optic disc image subtraction as an aid to detect glaucoma progression. *Trans Vis Sci Tech.* 2017;6(5):14, doi:10.1167/tvst.6.5.14 Copyright 2017 The Authors

Purpose: To present a digital image subtraction technique to alert clinicians to signs of glaucomatous optic disc progression.

Methods: Ninety-two glaucomatous eyes (65 patients) were included. Thirty-three eyes were identified as progressive and 59 as stable based on comparison of baseline and follow-up stereoscopic disc photographs by three masked glaucoma specialists. The disc images were aligned and converted to gray scale and underwent histogram matching to enhance contrast and account for illumination differences. The difference in image intensity between baseline and follow-up images was shown as a colormap superimposed on the grayscale follow-up image. A graded scale (1, no progression, to 5, definitive progression) was used by three masked glaucoma experts to score progression probability on the colormap images. Sensitivity, specificity, and accuracy of the classification were computed. Weighted κ statistics summarized agreement of categorical gradings.

Results: Median time interval between two visits was 4.4 years (range: 1.0–16.8). Clinicians detected glaucoma deterioration in 25 to 27 of the progressive group and 8 to 10 of stable eyes based on subtraction maps. Sensitivities/specificities of the clinicians were 0.76 to 0.82 and 0.86 to 0.89, respectively. Classification accuracy ranged from 81.5% to 84.8%. Agreement among clinicians was good (weighted $\kappa = 0.68$; 95% confidence interval [CI]: 0.60–0.77) for progression grades (1–5 scales) and was substantial (weighted $\kappa = 0.81$; 95% CI: 0.74–0.85) for binary scores.

Conclusions: The proposed software provides a single static image that clinicians can use with other structural/functional tests to detect glaucoma progression.

Translational Relevance: Provision of a subtraction colormap in the setting of electronic medical records can improve monitoring of glaucoma by alerting clinicians to possible signs of progression.

Introduction

Glaucoma is one of the leading causes of blindness in the world. At least 2 million people have primary open-angle glaucoma in the United States, and the number is rising.¹ Glaucoma is a progressive neurodegenerative disease, and patients need to be monitored so that clinicians can detect evidence of progression in a timely manner. By examining the optic nerve, clinicians can look for signs of progression or signs that may be associated with progression of the optic nerve, such as neuroretinal rim defects, optic disc hemorrhage, peripapillary atrophy, and retinal nerve fiber layer abnormalities, all of which are

important for the identification of glaucomatous progression.²

Optical coherence tomography (OCT) has been an important aid in monitoring glaucoma progression. To date, the retinal nerve fiber layer (RNFL) measurement concentric to the optic nerve has been the most commonly used parameter to achieve this goal.^{3–7} Nevertheless, detection of glaucoma progression remains one of the most challenging tasks in the management of glaucoma.

Review of stereoscopic disc photographs is one of the fundamental forms of image analysis that allows structural changes to be identified by clinicians.⁸ Determination of structural progression with serial

optic disc photographs suffers from poor interobserver agreement. Several studies such as the one conducted by Jampel and associates⁹ have shown this poor interobserver reliability ($j = 0.20$) when glaucoma specialists compared optic disc photographs for signs of structural progression.

This study was designed to compare the accuracy of optic disc photograph subtraction as an aid to detect glaucoma progression to that of the traditional method of examining serial stereoscopic disc photographs by glaucoma specialists. We propose an optic disc image subtraction method as part of a software tool that provides clinicians with supplemental information regarding signs of glaucoma deterioration as part of the electronic medical record and in real time, and we evaluate its performance with regard to detection of glaucoma progression.

Methods

Participants

Ninety-two glaucomatous eyes of 65 patients were selected from the Glaucoma Division's database at the University of California, Los Angeles (UCLA). Diagnosis of glaucoma was based on presence of thinning or notching of the neuroretinal rim, RNFL defects or significant asymmetry in the neuroretinal rim between the two eyes, and visual field loss that was entirely consistent with the optic nerve damage, as measured with standard automated perimetry. Eyes with a minimum of 1-year follow-up were included. Exclusion criteria were (1) concomitant ocular disease other than glaucoma; (2) any media opacity that would interfere with imaging and lead to poor-quality optic disc photographs; (3) poor illumination of the photographs; and (4) improper stereoscopy (large vertical shift on the screen between the stereoscopic pairs). The quality of the images was assessed on the basis of good-quality stereoscopy, contrast, clarity, illumination, and absence of excessive vertical shift between the stereoscopic pair. The study was approved by the Institutional Review Board of UCLA and was performed in adherence with the Declaration of Helsinki.

Disc Photograph Review

Stereoscopic disc photographs taken at baseline and last follow-up were reviewed by three expert glaucoma specialists (JC, KNM, and RA) 2 years prior to initiation of the study and were identified as

either progressive or stable. The experts were masked to clinical information and each other's decisions. Progression of glaucoma was defined as a loss of neuroretinal rim that could be accompanied by an increase in peripapillary atrophy, by worsening of visible RNFL defects, or by optic disc hemorrhages.¹⁰ A decision was made if at least two observers agreed on the progression (or stability) of the eyes. Thirty-three eyes were identified as having progressive optic nerve damage. Fifty-nine eyes were identified as stable based on review of stereoscopic disc photographs.

Imaging Methods

All photographs were obtained by the same fundus camera (Model 60306; Carl Zeiss, Oberkochen, West Germany) at the flash 3 setting (240 watts). One baseline and follow-up image each from each eye were aligned with software (i2k Align Retina; DualAlign, LLC, Clifton Park, NY) based on the dual-bootstrap algorithm. Only the right image of each stereo pair was used. In a preprocessing step, the original stereo fundus photographs (4400×3600 pixels) were rescaled to 1100×900 pixels for computational efficiency. Images were stored in an uncompressed, lossless TIFF format. These images were then converted to gray scale and underwent histogram matching to enhance contrast and remove the influence of changes in global illumination from baseline to follow-up visit (Fig. 1).

The intensity of the baseline image was subtracted from the follow-up image, and the difference was shown as a colormap superimposed on the grayscale follow-up image. Thresholding of the difference image was performed by the triangle method.^{11–13} In the subtraction colormaps, red pixels within the optic disc area indicate a decrease in intensity from the baseline to the follow-up image, and green pixels indicate an increase (Fig. 2). All green (or red) pixels have the same color intensity. In case of progressive neural rim thinning, red regions, indicating an increase in brightness, were superimposed on the thinning part of the rim (both examples in Fig. 2). If the optic disc was stable, no large areas of red or green pixels were created in the colormap (Fig. 3). All the image-processing procedures were streamlined and performed in MATLAB (R2015b; The Mathworks, Natick, MA). A software tool with a user-friendly interface was developed that allows clinicians to choose optic disc photographs with multiple image file formats.

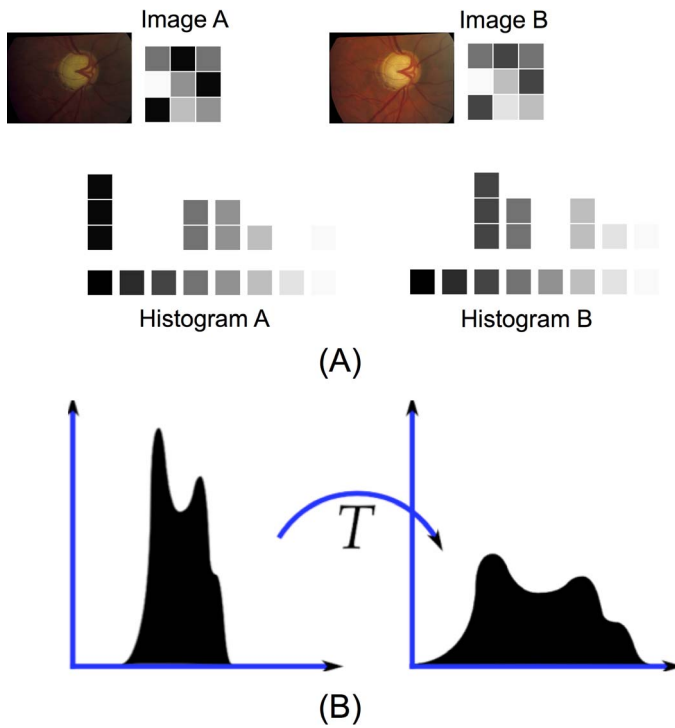


Figure 1. (A) Image A and image B differ in their global illumination. However, their histograms have similar patterns. The histograms are for demonstration purposes only. (B) Histogram matching is a process in which an image is modified such that its histogram matches that of another. Histogram equalization is a special case in which the specified histogram is uniformly distributed and, as such, the transformed histogram becomes flatter.

Grading Method

These subtraction colormap images were reviewed and graded by three masked glaucoma experts (RA, NP, and JC) solely based on these images. The grading was performed in two different scales: (1) a progression scale ranging from 1 (no progression) to 5 (significant progression) and (2) a binary scale where 1 represents glaucoma progression and 0 represents stability.

Statistical Analysis

The decision of the expert panel after review of follow-up and baseline stereoscopic disc photographs was considered the gold standard for the calculation of sensitivity, specificity, and accuracy of the gradings based on the colormaps. Sensitivity was calculated as the proportion of progressive eyes that were correctly identified as such. Specificity measured the proportion of stable eyes that were correctly identified as stable. Accuracy was the ratio of truly progressive and truly stable eyes to the total number of eyes.

κ Statistics (weighted κ) were used to estimate agreement of ordered categorical grading between observers. Agreement (κ) can be calculated by dividing the degree of agreement actually achieved beyond chance by the degree of agreement that is attainable beyond chance.

Results

Demographic and clinical characteristics of the study sample are shown in [Table 1](#). The median time interval between baseline and follow-up visits was 4.4 years (range: 1.0–16.8, interquartile range [IQR]: 3.2–5.9).

In this cohort, 31 (out of 33) progressive eyes had progressive rim loss, and only two eyes experienced RNFL thinning as the only sign of progression. In the areas of RNFL loss, the light is absorbed by the RPE; thus, the affected areas appear darker. As such, they are superimposed with green pixels in the subtraction colormap (green areas in the in the peripapillary area in [Fig. 2C](#)).

Three eyes had optic disc hemorrhages at baseline, which disappeared at the subsequent visit and were followed by progressive rim loss in the same location. The software was able to highlight the disappearance of all three disc hemorrhages indicated by red pixels in the corresponding area of the optic disc as shown in [Figure 4](#).

With the aid of subtraction maps, clinicians detected glaucoma progression in 25 to 27 (out of 33) of the progressive eyes and 8 to 10 (out of 59) of stable eyes. [Table 2](#) summarizes sensitivity, specificity, and accuracy results. Classification accuracy for the examination performed by the three clinicians was 81.5%, 81.5%, and 84.8%. Sensitivities of the examination performed by the three clinicians were 0.76, 0.79, and 0.82, and the specificities were 0.85, 0.83, and 0.86, respectively. Weighted κ scores revealed good agreement between clinicians (weighted $\kappa=0.68$; 95% confidence interval [CI]: 0.60–0.77) for progression grades (1–5 scales). Agreement among clinicians was substantial (weighted $\kappa = 0.81$; 95% CI: 0.74–0.85) for binary scores.

In order to validate the image subtraction algorithm and check for possible false-positive results, 10 pairs of disc photographs taken on the same day, as well as 10 pairs of identical disc photos, were fed to the software; as expected, no false-positive results were observed, and the resulting subtraction maps were all clear ([Fig. 5](#)).

On review of clinically progressing eyes where the

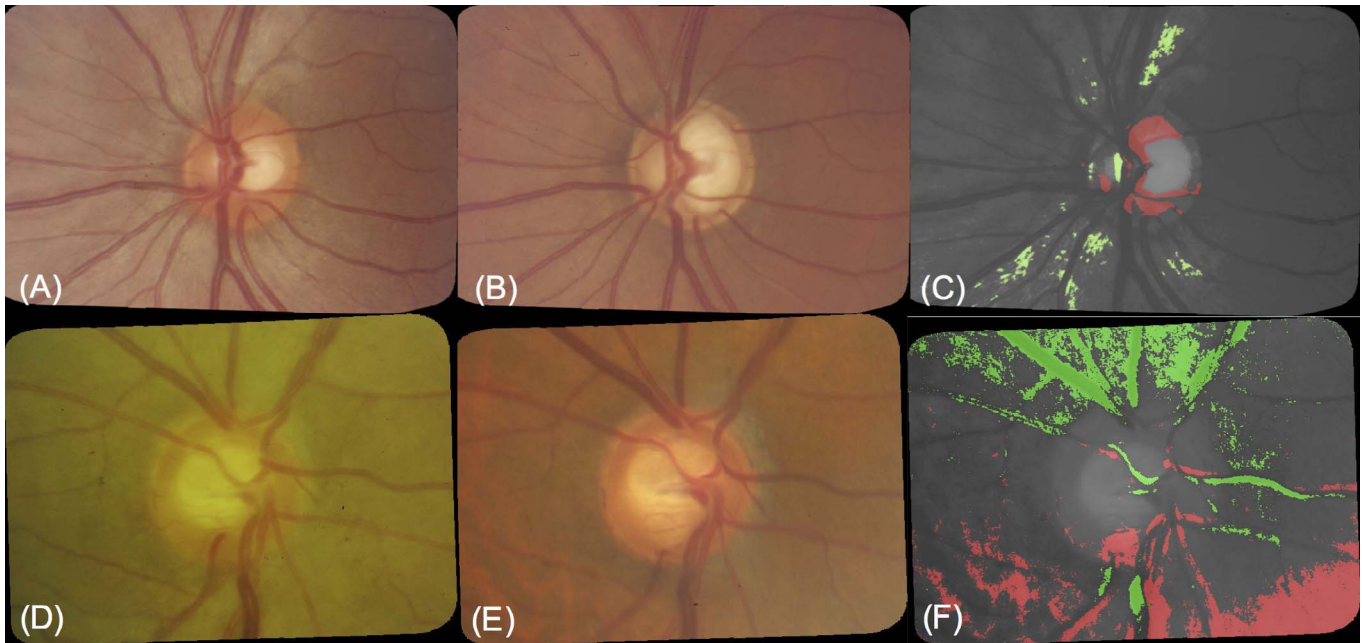

Figure 2. Baseline disc photograph from September 2002 (A), follow-up disc photography from April 2010 (B), and subtraction colormap (C), demonstrating significant neuroretinal rim (*red pixels*) and RNFL loss (*green pixels*) in the subtraction colormap. In the areas of RNFL loss, the light is absorbed by the RPE; thus, the affected areas appear darker. Baseline disc photograph from February 2005 (D), follow-up disc photography from March 2013 (E), and subtraction colormap (F), demonstrating inferior neuroretinal rim loss (*red pixels*).

colormaps failed to identify progression, we found that longitudinal optic disc changes tended to be more subtle; hence, a false-negative result was produced (Fig. 6). Also, in the case of uneven illumination in disc photographs, the histogram-matching technique failed in removing the effect of inhomogeneous illumination. Accordingly, distortions in the form of large areas of red and green pixels were produced in the periphery of subtraction colormaps for three progressive eyes as well as four stable eyes (Fig. 7). As a result of such distortions, clinicians might mistake

stable eyes for progressive eyes. Figure 8 shows how the software could highlight fundus camera artifacts in the form of circle-shaped darker areas in the central (red pixels) and temporal (green pixels) regions of the optic disc.

Discussion

Detection of glaucoma progression involves monitoring changes in both functional (visual field) and structural (optic disc or RNFL) domains. Stereoscopic

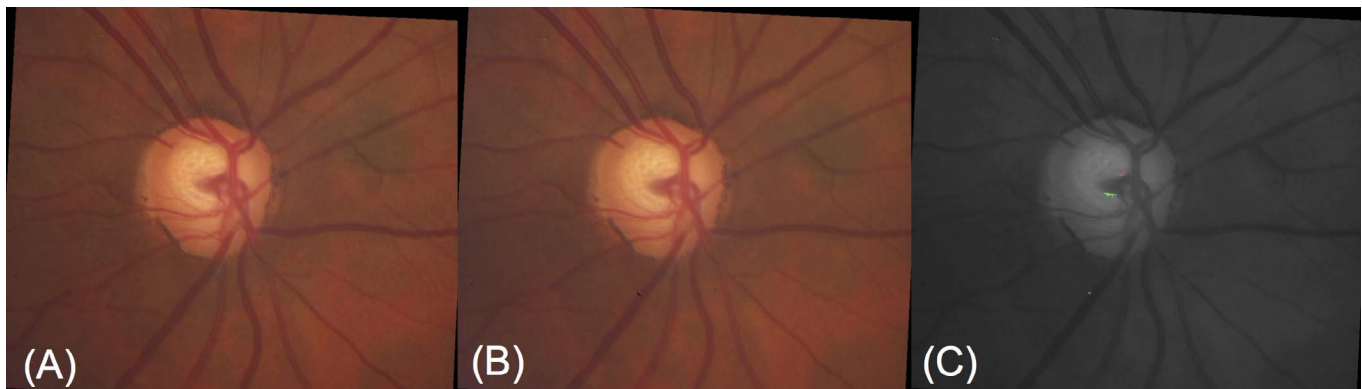

Figure 3. Disc photographs A and B were taken from a stable eye in August 2012 and September 2015, respectively. Subtraction colormap produced no sign of progression.

Table 1. Demographic Data and Baseline/Follow-up Characteristics of the Study Cohort

Number of eyes (patients)	92 (65)
Progression, progressive/stable (%)	33/59 (36%/64%)
Time difference between baseline and follow-up, median, y (range)	4.4 (1.0–16.8)
Age, mean, y (\pm SD)	63.5 (\pm 12.2)
Sex, female/male (%)	55/37 (60%/40%)
Race, AfA/HiA/AsA/CaA (%)	8/7/7/70 (8.7%/7.6%/7.6%/76.1%)
Laterality, right/left (%)	42/50 (45.7%/54.3%)
Diagnosis, POAG/GS/CACG/PXG (%)	71/12/9/5 (69.6%/13%/9.8%/5.4%)
Baseline IOP, mean, mm Hg (\pm SD)	14.1 (\pm 4.9)
Baseline number of medications, mean (\pm SD)	1.4 (\pm 1.5)
Baseline Snellen Visual Acuity, median (range)	20/30 (CF–20/20)
Baseline mean deviation, median, dB (IQR)	–2.3 (–5.69 to –0.4)
Baseline image quality, good/fair/low (%)	82/10/0 (89.1%/10.8%/0.0%)
Follow-up IOP, mean, mm Hg (\pm SD)	14.4 (\pm 5.2)
Follow-up number of medications, mean (\pm SD)	1.4 (\pm 1.4)
Follow-up Snellen Visual Acuity, median (range)	20/30 (CF–20/20)
Follow-up mean deviation, median, dB (IQR)	–3.5 (–9.85 to –0.76)
Follow-up image quality, good/fair/low (%)	86/6/0 (93.5%/6.5%/0.0%)

AfA, African American; HiA, Hispanic American; AsA, Asian American; CaA, Hispanic–Caucasian American; CF, counting fingers; POAG, primary open-angle glaucoma; GS, glaucoma suspect; CACG, chronic angle closure glaucoma; PXG, pseudoexfoliative glaucoma; IQR, interquartile range.

disc photographs have been used widely by ophthalmologists to document the optic disc appearance and detect changes over time. This approach has been demonstrated to be superior to subjective documentation and drawings of the disc.¹⁴ This method has been used in numerous glaucoma studies such as the Ocular Hypertension Treatment Study,¹⁵ Early Manifest Glaucoma Trial,¹⁶ and The Collaborative Initial Glaucoma Treatment Study.¹⁷

Evidence suggests that structural damage can often

be detected before development of detectable visual field defects.^{18–25} Some signs of structural progression are not easily detectable. With the proliferation of electronic medical record systems, incorporation of optic disc image subtraction tools, and in general, change detection software, may help clinicians detect glaucoma deterioration. The idea of utilizing image subtraction to detect optic nerve changes and glaucomatous damage progression is not novel.^{26–30} Reus and associates²⁰ found that the accuracy of

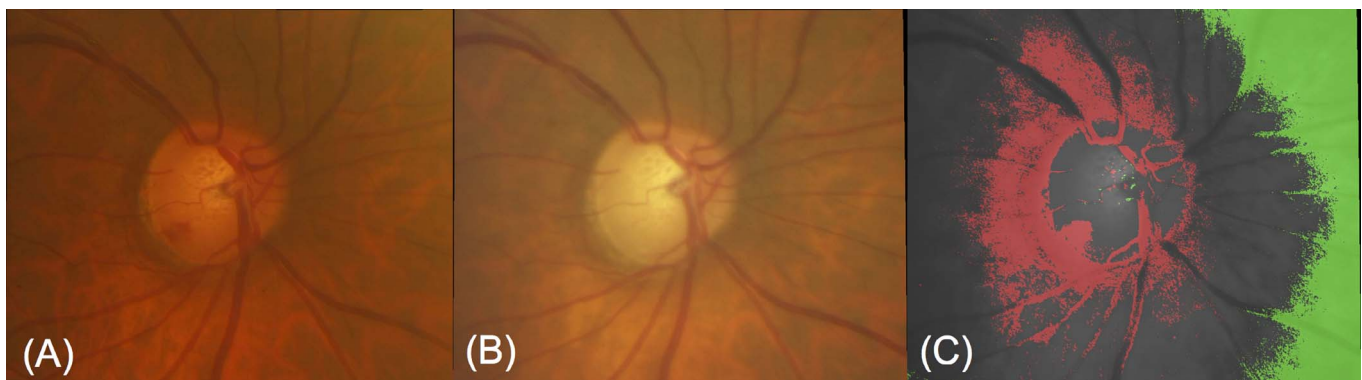


Figure 4. Disc photograph A was taken in March 2013, and B was taken in April 2016. Subtraction colormap demonstrates the disappearance of a disc hemorrhage at the inferotemporal area of the rim followed by rim loss in the same location. Due to inhomogeneous illumination, severe distortions in the form of large areas of *red* and *green* pixels were produced around the optic disc and in the periphery of subtraction colormaps.

Table 2. Analysis of Sensitivity, Specificity, and Accuracy of Individual Reviewers Using the Subtraction Colormaps Produced by the Software to Detect Glaucomatous Structural Changes

Reviewer	Sensitivity	Specificity	Accuracy of All Diagnoses
1	25/33 (76%)	50/59 (85%)	75/92 (81.5%)
2	26/33 (79%)	49/59 (83%)	75/92 (81.5%)
3	27/33 (82%)	51/59 (86%)	78/92 (84.8%)
Overall	78/99 (79%)	150/177 (84.7%)	228/276 (82.6%)

Sensitivity is the number of progressive eyes in which clinicians detected glaucoma progression to the total number of progressive eyes (33). Specificity is the number of stable eyes in which clinicians detected the absence of glaucoma progression to the total number of stable eyes (59).

diagnosing glaucoma by reviewing stereoscopic optic disc photographs to be at best 81%. New computer software such as matched flicker software programs^{31,32} or optic disc photograph subtraction proposed in this study could assist clinicians in highlighting possible changes of the optic nerve head.

With the subtraction colormaps, clinicians had an acceptable accuracy in finding glaucoma progression, which was consistent among three glaucoma experts, as measured by the weighted κ statistic. This interobserver agreement was good for progression grades, and it understandably improved when binary scores were used. Furthermore, fundus camera artifacts were highlighted by the software.

In this study, for the sake of analysis, clinicians used only the subtraction colormaps to find progression. However, the identification of glaucomatous optic nerve change is only a part of the bigger clinical picture for each patient and should be used along with all the other modalities. To reach this goal, as stated in previous studies,³² we believe that ancillary tests in glaucoma should have higher specificity (the percentage of negative designations that are truly negative) rather than higher sensitivity (the proportion of positive diagnoses that are truly positive) because of the low incidence of progression in eyes under treatment. In our study, the overall specificity was 85%. Distortions in the subtraction colormaps as a

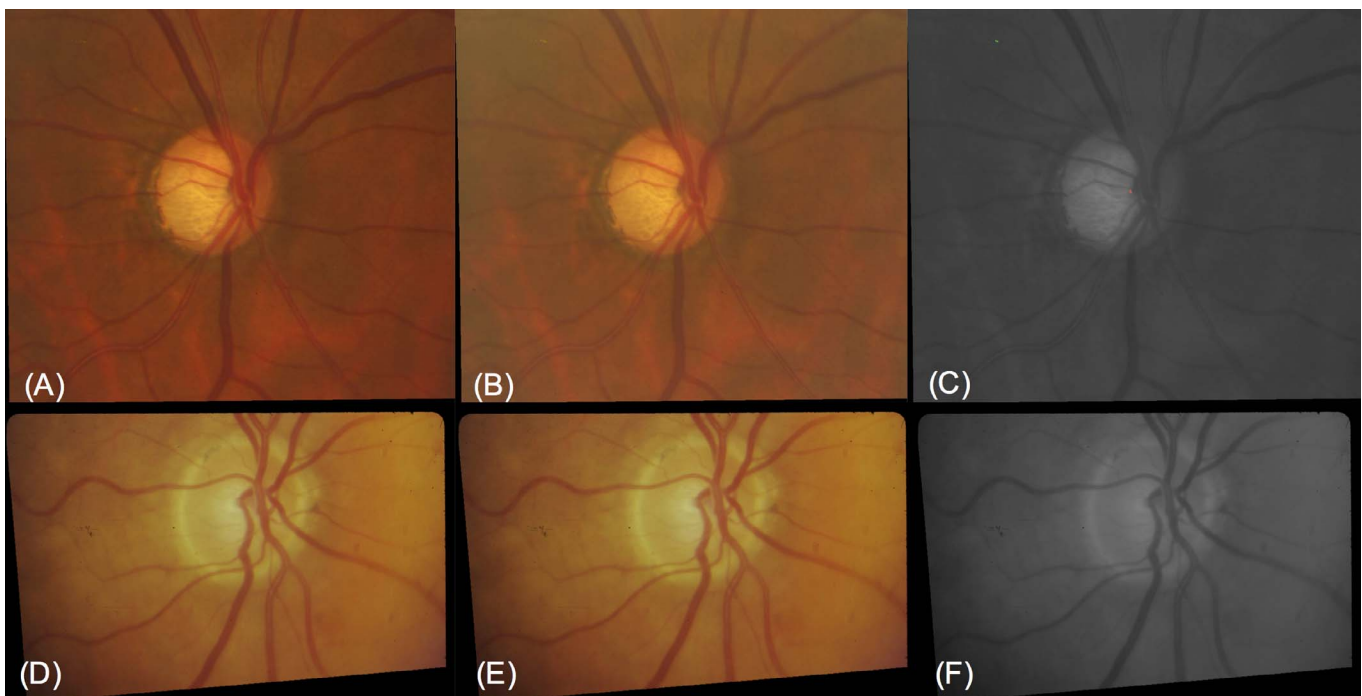


Figure 5. Photographs A and B were taken on the same day from the same glaucomatous eye. Subtraction colormap produced no false positive. Histogram-matching method (image C) showed promise in removing the effects of changes of global illumination from one image to another. Photographs D and E are identical. Subtraction colormap did not produce a false positive.

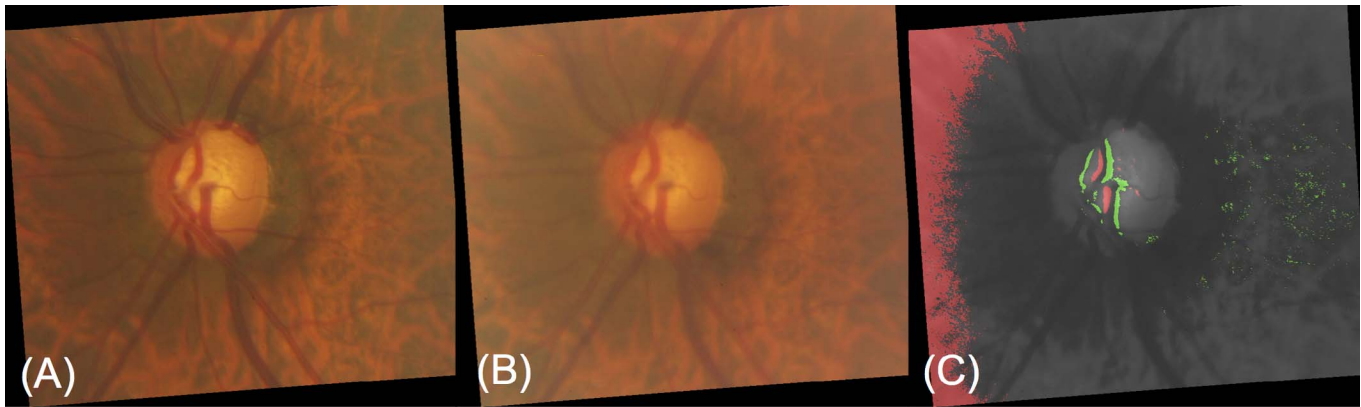


Figure 6. Disc photographs A and B were taken from a glaucomatous eye demonstrating evidence of progression between May 2013 and May 2014 with subtle changes in the superior region. Subtraction colormap demonstrated no sign of progression.

result of inhomogeneous illumination caused false-positive results. For instance, clinicians may perceive such distortions as RNFL thinning. Fundus camera artifacts are potentially another source of false positives. If these artifacts are located within the clinical disc margin, they could be mistaken for neural rim loss, although the pattern can usually be recognized as spurious.

Parallax often appeared on subtraction maps, suggesting that the proposed optic disc image subtraction method has the potential to automatically detect parallax. A separate study is worthwhile to evaluate the accuracy of parallax detection. Newer fundus cameras ensure that fixed-angle photographs of the optic disc can be taken. In the absence of fixed-angle optic disc photographs, parallax will cause apparent shifts in vessel position that may be perceived as glaucoma-related change. Radcliffe et al.³¹ have shown that retinal blood vessels shift locations in eyes with

progressive neuroretinal rim loss due to glaucoma. In general, only global blood vessel positional shifts may result from parallax, which is a global image transform and cannot distort a small region of a blood vessel. Less experienced clinicians should use caution when distinguishing focal blood vessel shift from global shifts or expansion/contraction of arteries (without displacement).

Our study demonstrated that the subtraction colormaps produced by the optic disc image subtraction software offered fair sensitivity for detecting glaucomatous progression and could also rule out its presence with a good specificity. Observation of subtraction colormaps yielded good to substantial interobserver agreement and provided additional information to the clinician, in a real time, for detecting glaucoma progression. Compared to viewing of stereoscopic optic disc photographs and matched flicker software, the advantages of the proposed image

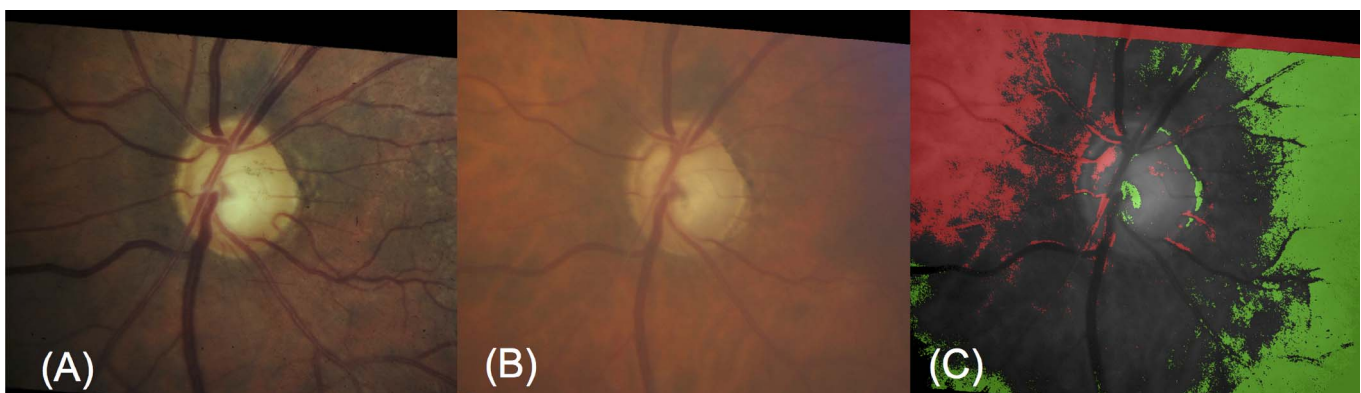


Figure 7. Disc photographs A and B were taken from a stable eye in September 1999 and May 2016, respectively. The presence of *red pixels* in the superonasal segment of the optic disc caused clinicians to identify this eye as progressive (false positive). Both photographs suffer from uneven illumination. For example, note the dark areas on the left side of photograph A. As expected, histogram matching failed in removing the effects of uneven illumination; hence, large areas of *red* and *green* were produced.

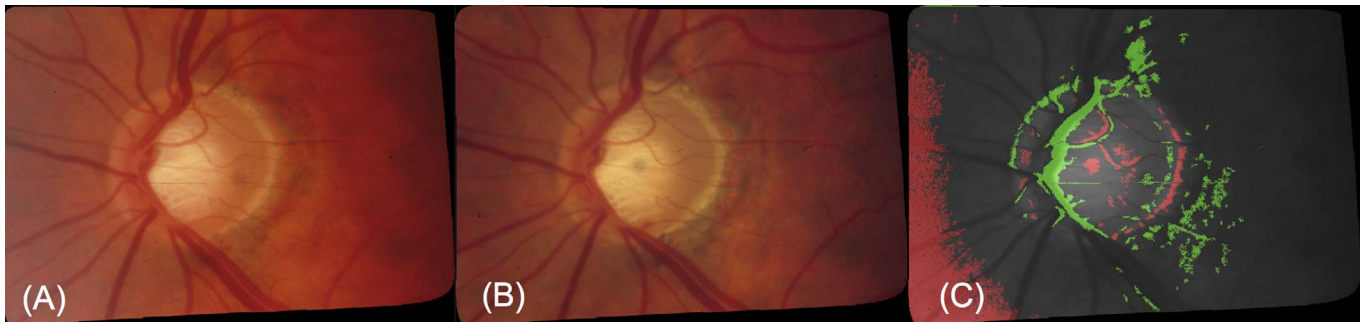

Figure 8. Disc photographs A and B were taken from a progressive eye in August 1989 and April 1993, respectively. Fundus camera artifacts are detected by the subtraction colormaps.

subtraction tool are the ease of use, independence from stereoscopic photographs, and its potential use in real time; the printout is static and can be placed either on physical charts or electronic medical records. It should be noted that the optic disc image subtraction tool is meant to complement existing methods for detection of progression, not to replace them.

This study had a number of limitations. First, image quality is a concern for every imaging modality and study. We used only images with acceptable quality in this study, although in clinical settings, suboptimal optic disc photos (decentered, motion artifact, low illumination) are not infrequent. The diagnostic value of subtraction colormaps significantly depends on the quality of the baseline and follow-up optic disc photographs. Several qualitative aspects are important as far as stereoscopic disc photographs are involved, such as image resolution (governed by camera resolution and field of view), uniformity of retinal illumination (determined by the acquisition condition and the spherical geometry of the eye), and the contrast of objects (blood vessels, optic disc, nerve fibers, hemorrhages, etc.) on the retina. Enhancement of the last item through histogram matching was considered in this study. As expected, the histogram-matching method was not able to compensate for uneven illumination on baseline or follow-up images. This was apparent in seven eyes in our cohort. Uneven illumination due to nonideal acquisition conditions can introduce distortions into optic disc images. These distortions are commonly perceived as smooth intensity variations across the optic disc photographs^{33,34} and must be eliminated in the future version of the proposed software. Presence of cataract or other media opacities could also compromise the results. In future work, we plan to enhance the histogram-matching method by subdividing the image into smaller segments and performing histogram-

matching in an adaptive manner. These modifications will enable the software to tolerate uneven illumination and moderate levels of media opacity.

Second, we used an external software tool to align the baseline and follow-up images. Incorporation of the image alignment step into the proposed software will produce a more clinically useful tool for use in routine care of patients.

Third, confirmation of progression in glaucomatous eyes can be challenging. Therefore, there may be no consensus among clinicians regarding progression in some glaucomatous eyes; in this study, we used the decision of an expert panel on progression (or stability) of each eye. Such decisions were considered the gold standard in evaluation of the performance of the proposed software. There is a possibility that subtle signs of glaucoma progression might have been missed.

The majority of progressing eyes in our study were identified based on changes in the neuroretinal rim. Since the number of eyes with disc hemorrhages or RNFL thinning was relatively low, a statistically meaningful subgroup analysis was not possible. We are planning to include more patients with disc hemorrhages or RNFL thinning in order to make this subgroup analysis statistically meaningful.

Last, although our approach has the potential to improve the interobserver agreement on structural progression, evaluation of serial optic disc photographs that are augmented with subtraction colormaps was still qualitative rather than quantitative, and expert opinions may vary. In the context of glaucoma progression detection with confocal scanning laser tomography, and in particular the Heidelberg Retina Tomograph (HRT; Heidelberg Engineering, Heidelberg, Germany), Chauhan and coinvestigators³⁵ have quantified and evaluated the size and depth of clusters of pixels that have undergone significant change from the baseline. They indicated that HRT's topographic

change analysis algorithm performs at least as well as observer classifications of disc photographs. Progressive RNFL thinning measured with OCT can be used to detect progressive disease. Leung and colleagues used the RNFL thickness map provided by event-based change analysis software, called the Guided Progression Analysis (GPA), for detecting and identifying patterns of RNFL progression.⁵ The GPA software compares the RNFL thickness patterns of follow-up scans to a baseline scan and indicates thinning as possible loss (yellow) or likely loss (red).

Even though we evaluated the performance of the proposed image subtraction technique by clinicians solely looking at the subtraction colormaps, in practice this technique must be used along with other routine structural (e.g., side-by-side viewing of stereoscopic optic disc photographs, circumpapillary RNFL thickness, and optic nerve head parameters) as well as functional tests. The correlation between the extent of change shown on subtraction colormaps and other structural/functional changes needs to be thoroughly explored.

The proposed software tool and the underlying image subtraction method produce a single static image (subtraction colormap) that can highlight areas of possible concern. The performance of the proposed image subtraction method will need to be compared to other means of detecting structural glaucomatous changes, such as alternation flicker, in future studies.³⁶

Acknowledgments

Supported by an unrestricted departmental grant from Research to Prevent Blindness.

Presented as a poster at the annual meeting of the Association for Research in Vision and Ophthalmology (ARVO), Baltimore, Maryland, United States, May 7–11, 2017.

Disclosure: **N. Amini**, None; **R. Alizadeh**, None; **N. Parivisutt**, None; **E. Kim**, None; **K. Nouri-Mahdavi**, None; **J. Caprioli**, None

References

1. Quigley HA, Broman AT. The number of people with glaucoma worldwide in 2010 and 2020. *Br J Ophthalmol*. 2006;90:262–267.

2. Mackenzie PJ, Mikelberg FS. Evaluating optic nerve damage: pearls and pitfalls. *Open Ophthalmol J*. 2009;3:54–58.
3. Leung CK. Diagnosing glaucoma progression with optical coherence tomography. *Curr Opin Ophthalmol*. 2014;25:104–111.
4. Bussel II, Wollstein G, Schuman JS. OCT for glaucoma diagnosis, screening and detection of glaucoma progression. *Br J Ophthalmol*. 2014;98(suppl 2):ii15–19.
5. Townsend KA, Wollstein G, Schuman JS. Imaging of the retinal nerve fibre layer for glaucoma. *Br J Ophthalmol*. 2008;93:139–143.
6. Wollstein G, Schuman JS, Price LL, et al. Optical coherence tomography longitudinal evaluation of retinal nerve fiber layer thickness in glaucoma. *Arch Ophthalmol*. 2005;123:464–470.
7. Miki A, Medeiros FA, Weinreb RN, et al. Rates of retinal nerve fiber layer thinning in glaucoma suspect eyes. *Ophthalmology*. 2014;121:1350–1358.
8. Caprioli J. Clinical evaluation of the optic nerve in glaucoma. *Trans Am Ophthalmol Soc*. 1994;92:589–641.
9. Jampel HD, Friedman D, Quigley H, et al. Agreement among glaucoma specialists in assessing progressive disc changes from photographs in open-angle glaucoma patients. *Am J Ophthalmol*. 2009;147:39–44.e31.
10. Jonas JB, Martus P, Budde WM, Hayler J. Morphologic predictive factors for development of optic disc hemorrhages in glaucoma. *Invest Ophthalmol Vis Sci*. 2002;43:2956–2961.
11. Xie J, Zhao T, Lee T, Myers E, Peng H. Automatic neuron tracing in volumetric microscopy images with anisotropic path searching. *Med Image Comput Comput Assist Interv*. 2010;13(pt 2):472–479.
12. Wu Q, Merchant F, Castleman KR. *Microscope Image Processing*. 1st ed. San Diego, CA: Academic Press; 2008.
13. Zack GW, Rogers WE, Latt SA. Automatic measurement of sister chromatid exchange frequency. *J Histochem Cytochem*. 1977;25:741–753.
14. Jamara RJ, Denial A, Valentini D, Thorn F. Clinical quality assessment using computer monitor photoimages of optic nerve head cupping. *Optom Vis Sci*. 2000;77:433–436.
15. Gordon MO, Beiser JA, Brandt JD, et al. The Ocular Hypertension Treatment Study: baseline factors that predict the onset of primary open-angle glaucoma. *Arch Ophthalmol*. 2002;120:714–720; discussion 829–830.

16. Leske MC, Heijl A, Hyman L, Bengtsson B. Early Manifest Glaucoma Trial: design and baseline data. *Ophthalmology*. 1999;106:2144–2153.
17. Musch DC, Lichter PR, Guire KE, Standardi CL. The Collaborative Initial Glaucoma Treatment Study: study design, methods, and baseline characteristics of enrolled patients. *Ophthalmology*. 1999;106:653–662.
18. Xu G, Weinreb RN, Leung CK. Optic nerve head deformation in glaucoma: the temporal relationship between optic nerve head surface depression and retinal nerve fiber layer thinning. *Ophthalmology*. 2014;121:2362–2370.
19. Kass MA, Heuer DK, Higginbotham EJ, et al. The Ocular Hypertension Treatment Study: a randomized trial determines that topical ocular hypotensive medication delays or prevents the onset of primary open-angle glaucoma. *Arch Ophthalmol*. 2002;120:701–713; discussion 829–830.
20. Reus NJ, Lemij HG, Garway-Heath DF, et al. Clinical assessment of stereoscopic optic disc photographs for glaucoma: the European Optic Disc Assessment Trial. *Ophthalmology*. 2010;117:717–723.
21. Breusegem C, Fieuws S, Stalmans I, Zeyen T. Agreement and accuracy of non-expert ophthalmologists in assessing glaucomatous changes in serial stereo optic disc photographs. *Ophthalmology*. 2011;118:742–746.
22. Sommer A, Katz J, Quigley HA, et al. Clinically detectable nerve fiber atrophy precedes the onset of glaucomatous field loss. *Arch Ophthalmol*. 1991;109:77–83.
23. Lisboa R, Weinreb RN, Medeiros FA. Combining structure and function to evaluate glaucomatous progression: implications for the design of clinical trials. *Curr Opin Pharmacol*. 2013;13:115–122.
24. Öhnell H, Heijl A, Brenner L, Anderson H, Bengtsson B. Structural and functional progression in the early manifest glaucoma trial. *Ophthalmology*. 2016;123:1173–1180.
25. Chauhan BC, McCormick TA, Nicoleta MT, LeBlanc RP. Optic disc and visual field changes in a prospective longitudinal study of patients with glaucoma: comparison of scanning laser tomography with conventional perimetry and optic disc photography. *Arch Ophthalmol*. 2001;119:1492–1499.
26. Alanko H, Jaanio E, Airaksinen PJ, Nieminen H. Demonstration of glaucomatous optic disc changes by electronic subtraction. *Acta Ophthalmol (Copenh)*. 1980;58:14–19.
27. Jaanio E, Alanko H, Airaksinen PJ, Nieminen H, Lähde S. Electronic subtraction method for ophthalmic photography. *Acta Ophthalmol (Copenh)*. 1980;58:7–13.
28. Heijl A, Bengtsson B. Diagnosis of early glaucoma with flicker comparisons of serial disc photographs. *Invest Ophthalmol Vis Sci*. 1989;30:2376–2384.
29. Mustonen E, Alanko HI, Nieminen H. Changes in optic disc drusen. Demonstration by stereophotographs and electronic subtraction. *Acta Ophthalmol (Copenh)*. 1982;60:3–15.
30. Marlow ED, McGlynn MM, Radcliffe NM. A novel optic nerve photograph alignment and subtraction technique for the detection of structural progression in glaucoma. *Acta Ophthalmol*. 2014;92:e267–272.
31. Radcliffe NM, Smith SD, Syed ZA, et al. Retinal blood vessel positional shifts and glaucoma progression. *Ophthalmology*. 2014;121:842–848.
32. Schaefer JL, Lukowski ZL, Meyer AM, et al. Comparing glaucomatous disc change using stereo disc viewing and the matched flicker software program in ophthalmologists-in-training. *Am J Ophthalmol*. 2016;167:88–95.
33. Youssif AR, Ghalwash AZ, Ghoneim AR. Optic disc detection from normalized digital fundus images by means of a vessels' direction matched filter. *IEEE Trans Med Imaging*. 2008;27:11–18.
34. Kubecka L, Jan J, Kolar R. Retrospective illumination correction of retinal images. *Int J Biomed Imaging*. 2010;2010:780262.
35. Chauhan BC, Hutchison DM, Artes PH, et al. Optic disc progression in glaucoma: comparison of confocal scanning laser tomography to optic disc photographs in a prospective study. *Invest Ophthalmol Vis Sci*. 2009;50:1682–1691.
36. Syed ZA, Radcliffe NM, De Moraes CG, Liebmann JM, Ritch R. Detection of progressive glaucomatous optic neuropathy using automated alternation flicker with stereophotography. *Arch Ophthalmol*. 2011;129:521–522.