

Role of Modified Endoscopic Medial Maxillectomy in Persistent Chronic Maxillary Sinusitis

Ponnaiah Thulasidas¹ Venkatraman Vaidyanathan²

¹Department of Otolaryngology Head and Neck Surgery, Sinus and Nose Hospital, Chennai, India

²Department of Otolaryngology Head and Neck Surgery, PSGIMSR, Coimbatore, India

Address for correspondence Venkatraman Vaidyanathan, MS (ENT), Department of Otolaryngology and Head and Neck Surgery, PSGIMSR, Peelamedu, Coimbatore 641004, India (e-mail: entvenky@gmail.com).

Int Arch Otorhinolaryngol 2014;18:159–164.

Abstract

Introduction Functional endoscopic sinus surgery has a long-term high rate of success for symptomatic improvement in patients with medically refractory chronic rhinosinusitis. As the popularity of the technique continues to grow, however, so does the population of patients with postsurgical persistent sinus disease, especially in those with a large window for ventilation and drainage. In addition, chronic infections of the sinuses especially fungal sinusitis have a higher incidence of recurrence even though a wide maxillary ostium had been performed earlier. This subset of patients often represents a challenge to the otorhinolaryngologist.

Objectives To identify the patients with chronic recalcitrant maxillary sinusitis and devise treatment protocols for this subset of patients.

Methods A retrospective review was done of all patients with persistent maxillary sinus disease who had undergone modified endoscopic medial maxillectomy between 2009 and 2012. We studied patient demographics, previous surgical history, and follow-up details and categorized the types of endoscopic medial maxillectomies performed in different disease situations.

Results We performed modified endoscopic medial maxillectomies in 37 maxillary sinuses of 24 patients. The average age was 43.83 years. Average follow-up was 14.58 months. All patients had good disease control in postoperative visits with no clinical evidence of recurrences.

Conclusion Modified endoscopic medial maxillectomy appears to be an effective surgery for treatment of chronic, recalcitrant maxillary sinusitis.

Keywords

- ▶ maxillary sinusitis
- ▶ endoscopy
- ▶ methylene blue

Introduction

The central dogma of functional endoscopic sinus surgery is restoration of the natural sinus physiology, namely mucociliary clearance and ventilation. The causes for failure include mucosal, environmental, and iatrogenic factors. Iatrogenic factors involve inadvertent stripping of sinus mucosa, damage to the cilia bearing mucosa with the microdebrider or other instruments, exposure of bone, circumferential damage

to the sinus ostium, improper widening of sinus ostium permitting recirculation of mucous, poor mucociliary clearance, among others.¹ The mucociliary clearance of the maxillary sinus, which is the largest of all the paranasal sinuses, is always toward the natural ostium. It begins from the floor of the sinus and proceeds along its walls toward the natural ostium and hence is against gravity, a factor that can work against the restoration of normal physiology in a disease situation. Previous surgeries such as Caldwell-Luc damage the

received
September 27, 2013
accepted
December 19, 2013

DOI <http://dx.doi.org/10.1055/s-0034-1368137>.
ISSN 1809-9777.

Copyright © 2014 by Thieme Publicações Ltda, Rio de Janeiro, Brazil

License terms



maxillary sinus mucosa leading to a loss of mucociliary function.² Allergic fungal rhinosinusitis (AFRS) is believed to account for 5 to 10% of chronic rhinosinusitis cases.³ The disease is typically recalcitrant despite medical and surgical therapy.⁴ Systemic steroids often provide some relief, but relapse usually follows once the steroids are withdrawn.³ Surgery is the cornerstone of treatment. The goals of surgery are threefold: complete extirpation of all allergic mucin and fungal debris, permanent drainage and ventilation for the affected sinuses while maintaining intact mucosa, and post-operative access to the previously diseased areas.⁵ Both systemic and topical steroids are important in preventing disease recurrence.⁶ However, despite the above measures, some patients experience recurrence and need revision surgery. Revision functional endoscopic sinus surgery aims to overcome these shortcomings but can fall short due to irreversible damage to the mucous membrane by prior surgery. Endoscopic medial maxillectomy is a radical procedure that includes removal of uncinata process, bulla, inferior turbinate, middle turbinate, and medial maxillary wall with the nasolacrimal duct.⁷ At present, its indication is for resection of sinonasal neoplasms including sinonasal papillomas.⁷ We have performed variations of this technique in patients with chronic recalcitrant maxillary sinusitis in accordance with the status and extent of the sinus disease. The purpose of this article is to share the cumulative experience of all the cases operated using this technique and to highlight the effectiveness of this technique in dealing with persistent maxillary sinusitis. We have also categorized the types of endoscopic medial maxillectomies performed in different disease situations.

Materials and Methods

Endoscopic medial maxillectomy as a means of treating recalcitrant maxillary sinusitis was performed on 24 patients between 2009 and 2012 in the Sinus and Nose Hospital (Santhome, Chennai, India), which is a tertiary care center for nasal and sinus diseases. These patients had undergone multiple endoscopic surgeries elsewhere or in our center in the past but were still symptomatic. Patients included those with chronic sinusitis, nasal polyposis, AFRS, osteomyelitis, and persistent sinusitis following surgery and chemotherapy. All patients underwent a diagnostic nasal endoscopy. All of them had a wide middle meatal antrostomy, but the antral mucosa was found to be unhealthy with persistent disease. A methylene blue dye test was performed in these patients to evaluate the efficiency of the mucociliary clearance mechanism.

This was done in two ways. When there was a large ostium, 0.5 mL of methylene blue dye was instilled into the antrum taking care not to soil the nasal mucosa. Alternatively, the dye could also be instilled into the sinus through a trocar in the canine fossa. We wait 10 to 15 minutes then we looked for the movement of the dye. We can deduce three conclusions from this test: normal movement of the dye, delayed movement of the dye, and no movement of the dye. Decision to surgically intervene and to determine the type of surgery was inferred by results of the dye test. "Normal movement of the dye" was

indicated by movement of the dye as blue streaks along the walls of the maxillary sinus toward the natural ostium. In patients with a normally functioning sinus, this movement can be observed within minutes of instilling the dye. "Delayed movement of the dye" was noted when appeared to be some movement of the dye in a few pockets but it did not quite reach the natural ostium. When no movement of the dye at all could be seen, the result was noted.

It should be noted that we do not perform the dye test in patients with fungal balls or polyps in the maxillary sinus, as the mucosa is deemed abnormal. We assess the extent of surgery based on the findings on the operating table.

All patients underwent a preoperative computed tomography (CT) scan and surgical profile. Preoperative CT scan is mandatory in all patients undergoing revision sinus surgery as it defines the bony anatomy (or rather the loss of it due to previous surgery) well.⁸ The middle meatal antrostomy should be examined for aspects of retained uncinata process in the region of the natural ostium of the maxillary sinus or unventilated cells missed on the primary procedure, such as the infraorbital (Haller) cells.⁸ The frontal recesses should be identified, and patency should be determined. Careful attention should be paid to the underlying bone for evidence of osteitis represented radiographically as thickened irregular bone.⁸

The surgery was performed under general anesthesia. Details of the surgery are described in the Surgical Method section. Following surgery, a Merocel (Medtronic, USA) pack was kept in the maxillary sinus and ethmoid cavity, which was removed after 5 days. The patient received parenteral antibiotics during his or her stay in the hospital (usually 24 hours) and was discharged on oral medications. Patients with AFRS were started on oral steroids, which were gradually tapered. We recommend nasal douche with saline solution once every alternate day for a period of 3 weeks after pack removal as it facilitates in the cleaning of the postoperative cavities. Follow-up visits are scheduled for 1 week and 1 and 3 months after surgery and 6-month intervals thereafter.

Surgical Method

The aim of the surgery is to provide gravity-dependent drainage of the maxillary sinus. All procedures were done under general anesthesia. Preoperative packing was done with 4% lignocaine and ephedrine-soaked pledgets in all of our patients. Infiltration of 2% xylocaine with 1/200,000 adrenaline was given. We performed three types of modified endoscopic medial maxillectomies (MEMMs; see ►Table 1 and ►Fig. 1). Type I and type IIa and b are performed for inflammatory disease of the maxillary sinus. Radical medial maxillectomy is reserved for maxillary sinus tumors, which falls outside the range of discussion in this article.

Type I Modified Endoscopic Medial Maxillectomy

The procedure involves removal of intervening tissue between the two windows. This is done in patients with a prior inferior meatal antrostomy and a middle meatal antrostomy (Caldwell-Luc). Using backbiting forceps, the antrostomy is

Table 1 Types of modified endoscopic medial maxillectomy and indications

| Type | Indication | Procedure |
|------|--|---|
| I | Recirculation mechanism due to two windows in middle meatus and inferior meatus (e.g., previous inferior meatal anrostomy) | Middle meatus and inferior meatal windows joined, creating a mega ostium, inferior turbinate partially resected |
| II | Abnormal dye test indicating disease of maxillary sinus mucosa | |
| Ila | Delayed clearance of dye; allergic fungal rhinosinusitis | Modified endoscopic medial maxillectomy, nasolacrimal duct preserved, maxillary sinus mucosa left intact |
| Ilb | No clearance of dye | Modified endoscopic medial maxillectomy, nasolacrimal duct preserved, maxillary sinus mucosa stripped off by through an antral window |

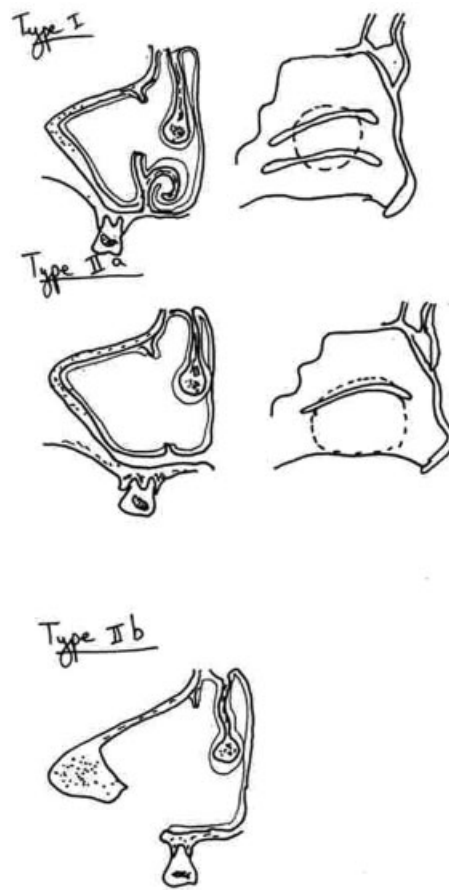
widened anteriorly. An anterior cut passes through the inferior turbinate encompassing the inferior meatal opening. The inferior cut is made along the floor of the nasal cavity in the inferior meatus extending posteriorly up to the posterior wall of the maxillary sinus. The superior and inferior cuts are joined by the posterior cut using an osteotomy. Note that the middle turbinate, nasolacrimal duct, and anterior portion of the inferior turbinate are preserved (►Fig. 1).

Type Ila Modified Endoscopic Medial Maxillectomy

This is performed for patients with delayed dye clearance. The surgery begins with the type I MEMM. The medial wall of the maxillary sinus is removed right down to the nasal floor inferiorly and up to the posterior wall posteriorly. The anterior limit of dissection is the nasolacrimal duct. The anterior end of the inferior turbinate and the medial wall anterior to the nasolacrimal duct is preserved. The drainage of the sinus is by gravity. Postoperative nasal douching will be very effective for these patients. However, the inferior turbinate is resected to provide complete exposure of the maxillary sinus for drainage. The nasolacrimal duct should be identified and preserved. In case of inadvertent injury, it should be transposed higher, near the attachment of the middle turbinate (►Fig. 1).

Type Ilb Modified Endoscopic Medial Maxillectomy

This surgery is an extension of the type Ila MEMM wherein the antral mucosa is completely stripped off by a canine fossa Caldwell-Luc approach. An endoscope facilitates the removal of mucosa from all nooks and corners of the antrum. A type Ila MEMM is performed. The sublabial region is then infil-

**Fig. 1** Types of modified endoscopic medial maxillectomy.

trated with 2% xylocaine and 1:200,000 adrenaline. A canine fossa antrostomy is made, and the opening is widened using bone nibbler. A freer elevator is then used to elevate the maxillary sinus mucosa. It is important to note that these patients have been operated on previously with varying degrees of damage to the mucous membrane. Hence there will be scarring, which will make mucosal elevation and stripping a challenging exercise and requires patience on the part of the surgeon. The areas that may offer difficulty include the sinus recesses and the anteromedial wall. In these areas, the mucosa may be adherent and may require drilling with a diamond burr (►Fig. 1).

Results

We performed MEMMs in 37 maxillary sinuses of 24 patients. Type I MEMM was performed in 4 patients. Type Ila MEMM was performed in 15 patients. Type Ilb MEMM was performed in 5 patients. The average age was 43.83 years. Sixteen patients had history of previous surgery. Four patients had AFRS, one of whom had been previously operated on. Six patients had prior Caldwell-Luc surgery. Four patients had fungal balls, and one patient had chronic indolent fungal sinusitis. Three patients had osteomyelitis of the maxilla due to prior surgery or fungal infection. The details of the patients are listed in ►Table 2.

Table 2 Patient details

| Age | History | Surgery (MEMM) | Complications | Follow-up (mo) | Recurrence |
|-----|--|-----------------------|-----------------------------|----------------|------------|
| 42 | 2× ESS | Type IIa u/l | Postoperative bleeding | 6 | None |
| 48 | Caldwell-Luc | Type I u/l | None | 24 | None |
| 20 | Fungal ball with osteomyelitis | Type IIa u/l | None | 14 | None |
| 62 | ESS | Type IIa b/l | None | 24 | None |
| 40 | Caldwell-Luc; 5× ESS | Type IIb b/l | None | 7 | None |
| 61 | Fungal ball | Type IIa u/l | None | 8 | None |
| 49 | Fungal ball | Type IIa u/l | None | 7 | None |
| 53 | Chronic sinusitis post-radiotherapy and chemotherapy | Type IIb u/l | Hypoplastic maxillary sinus | 5 | None |
| 65 | Osteomyelitis | Type I u/l | None | 5 | None |
| 45 | AFRS | Type IIb b/l | None | 36 | None |
| 45 | 3× ESS | Type IIb u/l | None | 8 | None |
| 19 | AFRS | Type IIa b/l | None | 5 | None |
| 44 | Caldwell-Luc | Type I u/l | None | 26 | None |
| 42 | AFRS; 3× ESS | Type IIa b/l | None | 24 | None |
| 50 | 2× ESS | Type IIa b/l | None | 8 | None |
| 41 | 2× ESS; Caldwell-Luc | Type IIa and type IIb | None | 19 | None |
| 44 | 3× ESS | Type IIa b/l | None | 22 | None |
| 52 | 2× ESS | Type IIa u/l | None | 21 | None |
| 48 | Caldwell-Luc | Type I b/l | None | 4 | None |
| 29 | Caldwell-Luc; Fungal ball | Type IIa u/l | None | 9 | None |
| 34 | 2× ESS | Type IIa b/l | None | 17 | None |
| 44 | 3× ESS | Type IIb b/l | None | 21 | None |
| 37 | AFRS | Type IIa b/l | None | 12 | None |
| 38 | 3× ESS | Type IIa b/l | None | 18 | None |

Abbreviations: AFRS, allergic fungal rhinosinusitis; b/l, bilateral; ESS, endoscopic sinus surgery; MEMM, modified endoscopic medial maxillectomy; u/l, unilateral.

Average follow-up was 14.58 months. One patient had postoperative bleeding from the sphenopalatine artery, which was controlled in the operation theater by cauterization. One patient had hypoplastic maxillary sinus 6 months after surgery, though he remains asymptomatic at present. All patients had good disease control in the postoperative visits with no clinical evidences of recurrences.

Discussion

Medial maxillectomy through a lateral rhinotomy incision involves the removal of the lateral nasal wall, ethmoid labyrinth, and medial portion of the maxilla. It was the gold standard for the removal of inverted papilloma. It has the advantages of excellent exposure of the lateral nasal wall and paranasal sinuses.^{9,10} Endoscopic modified medial maxillectomy is transnasal removal of uncinat process, bulla, inferior turbinate, middle turbinate, and medial maxillary wall with the nasolacrimal duct.⁷ Hitherto endoscopic MMM was re-

served for tumors of the maxillary sinus only.⁷ In the recent times, this thinking is slowly but steadily changing and one finds a few reports of endoscopic medial maxillectomy for recalcitrant maxillary sinusitis.¹¹⁻¹⁴ Simmen and Jones described three types of maxillary sinusotomy.¹⁵ Type I involves widening of the natural ostium to a diameter of 1 cm. Type II involves widening it posteriorly and inferiorly to a maximum of 2 cm. Type III involves widening it close to the level of the posterior wall of the maxillary antrum and anterior to the lacrimal sac and inferiorly to the base of the inferior turbinate. They recommend type III for extensive sinus disease, antrochoanal polyp removal, and previous surgery. We feel that merely taking down the medial wall of the maxillary antrum does not serve the purpose in patients with irreversible mucosal injury and necessitates a more radical procedure like a type IIb MEMM. This is because the goblet cells keep secreting mucus, which accumulates in the sinus and leads to a “sump” effect. In patients with chronically diseased maxillary sinuses, poor mucociliary

clearance may result from long-standing inflammation or scarring from previous surgery. This subset of patients often has persistent sinus disease despite medical therapy and adequate antrostomy. We are of the opinion that the mucociliary clearance is the single most important factor in determining the outcome in maxillary sinus after surgery. If the mucociliary clearance is competent, the sinus will function well; otherwise, the disease continues to persist. At present, there are no definitive guidelines for the treatment of this subset of patients. Woodworth et al reported in a retrospective review comprising 19 patients that MEMMs are both safe and an effective treatment for chronic maxillary sinusitis refractory to standard medical and endoscopic surgical management.¹¹ Wang et al reported complete resolution of the disease in 80% of their patients.¹² Cho and Hwang performed an endoscopic mega antrostomy, which involved extending the antrostomy through the posterior half of the inferior turbinate down to the floor of the nose, creating a significantly enlarged antrostomy in 28 patients; they reported a success rate of 74%.¹³ An interesting study conducted by Shatz on 15 children with cystic fibrosis revealed marked improvement in sinus drainage and symptoms after medial maxillectomy and Caldwell-Luc.¹⁴

The patients on whom we have operated can be likened to those suffering from cystic fibrosis as there is partial or complete loss of normal mucosa and hence mucociliary clearance due to the previous surgery. Hence we feel we are justified in performing a procedure aimed at providing gravity-dependent drainage for the sinus. We have also performed MEMMs for patients with AFRS and fungal ball of the maxillary sinus in accordance with the sinus mucosal status intraoperatively after the methylene blue dye test. We have observed no recurrence of the disease in any of these patients (see ►Table 2).

Our study is an attempt to define this subset of patients and a protocol for the treatment of these patients (see ►Fig. 2). We have attempted to evaluate the sinus physiology using a simple and easily reproducible methylene blue dye test, which can be performed in the office. Based on the ciliary movement and nasal endoscopy findings, we advocate three solutions to resolve the problem.

Normal Movement of Dye

A wide middle meatal antrostomy is usually sufficient in patients with normal movement of dye. These patients usually have normal maxillary sinus mucosa, and their persistent symptoms are a result of frontal or sphenoidal disease. Some patients have multiple windows for drainage, namely, an inferior antrostomy and a middle meatal antrostomy. These patients are still symptomatic due to recirculation phenomenon where there is circular movement of the mucous around the artificially created window. In these patients, it is preferable to perform a type 1 MEMM (see ►Table 1, ►Fig. 1).

Delayed Movement of Dye

Delayed dye movement indicates that there is a certain degree of mucociliary clearance that, despite being present, is inadequate to prevent recurrent infection of the sinus. We

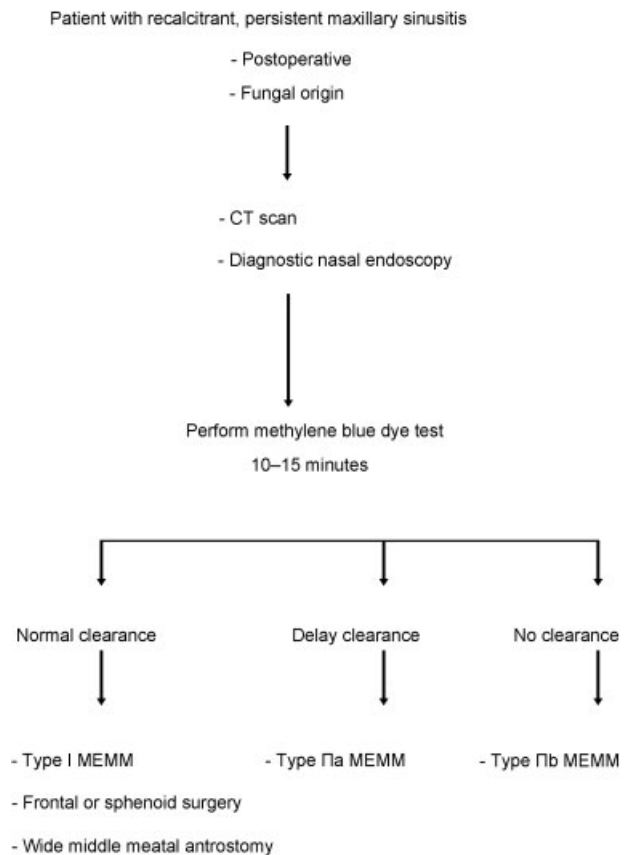


Fig. 2 Management of chronic recalcitrant maxillary sinusitis. Abbreviations: CT, computed tomography; MEMM, modified endoscopic medial maxillectomy.

advocate a surgery that would ensure gravity-dependent drainage of the sinus. In these patients, we performed a type IIa MEMM (see ►Table 1, ►Fig. 1). We do not advocate mucosal stripping in these patients due to presence of viable mucosa.

No Movement of Dye

No movement of dye indicates irreversible loss of ciliary function and hence a simple widening of the already widened ostium (i.e., a mega ostium) would not suffice. We advocate a surgery that would ensure gravity-dependent drainage of the sinus as it will be the only means for drainage in the absence of viable mucosa. We performed a MEMM type IIb (see ►Table 1, ►Fig. 1) for patients with this finding.

Conclusions

Though many would be reluctant to advocate a radical surgery like a medial maxillectomy for persistent maxillary sinusitis, it is imperative to understand the physiology and its alteration following surgery and chronic infection, which leads to a radical change in the functioning capacity of the maxillary sinus. The sinus has to work against gravity to expel its waste material, which is the single most important factor in the production of recalcitrant sinusitis that does not respond to surgical methods described hitherto. Bringing

the medial maxillary wall to the level of the nasal floor appears to alleviate symptoms in these patients. Though the ciliary mechanism is lost, the goblet cells continue to secrete mucus, which results in stasis, an additional factor. These patients would require removal of secreting mucosa in addition to MEMM. We have attempted to highlight this point through this article.

In summary:

- Recalcitrant, chronic maxillary sinusitis is an underreported entity.
- The treatment protocol is still not established.
- Endoscopic medial maxillectomy has been advocated by few authors.
- We have attempted to diagnose this subset of patients through simple outpatient tests.
- We have attempted to classify the severity of mucosal disease and advocate appropriate surgical treatment.

Authorship Contribution

P. Thulasidas: study design, data collection, data interpretation, analysis. V. Venkatraman: data collection, manuscript, analysis.

References

- 1 Richtsmeier WJ. Top 10 reasons for endoscopic maxillary sinus surgery failure. *Laryngoscope* 2001;111(11 Pt 1):1952–1956
- 2 Unlü HH, Caylan R, Nalça Y, Akyar S. An endoscopic and tomographic evaluation of patients with sinusitis after endoscopic sinus surgery and Caldwell–Luc operation: a comparative study. *J Otolaryngol* 1994;23(3):197–203
- 3 Houser SM, Corey JP. Allergic fungal rhinosinusitis: pathophysiology, epidemiology, and diagnosis. *Otolaryngol Clin North Am* 2000;33(2):399–409
- 4 Kuhn FA, Javer AR. Allergic fungal rhinosinusitis: perioperative management, prevention of recurrence, and role of steroids and antifungal agents. *Otolaryngol Clin North Am* 2000;33(2):419–433
- 5 Marple BF. Allergic fungal rhinosinusitis: current theories and management strategies. *Laryngoscope* 2001;111(6):1006–1019
- 6 Ferguson BJ. What role do systemic corticosteroids, immunotherapy, and antifungal drugs play in the therapy of allergic fungal rhinosinusitis? *Arch Otolaryngol Head Neck Surg* 1998;124(10):1174–1178
- 7 Kamel RH. Transnasal endoscopic medial maxillectomy in inverted papilloma. *Laryngoscope* 1995;105(8 Pt 1):847–853
- 8 Cohen NA, Kennedy DW. Revision endoscopic sinus surgery. *Otolaryngol Clin North Am* 2006;39(3):417–435, vii
- 9 Sessions RB, Humphreys DH. Technical modifications of the medial maxillectomy. *Arch Otolaryngol* 1983;109(9):575–577
- 10 Sessions RB, Larson DL. En bloc ethmoidectomy and medial maxillectomy. *Arch Otolaryngol* 1977;103(4):195–202
- 11 Woodworth BA, Parker RO, Schlosser RJ. Modified endoscopic medial maxillectomy for chronic maxillary sinusitis. *Am J Rhinol* 2006;20(3):317–319
- 12 Wang EW, Gullung JL, Schlosser RJ. Modified endoscopic medial maxillectomy for recalcitrant chronic maxillary sinusitis. *International Forum of Allergy & Rhinology* 2011;1(6):493–497
- 13 Cho DY, Hwang PH. Results of endoscopic maxillary mega-antrostomy in recalcitrant maxillary sinusitis. *Am J Rhinol* 2008;22(6):658–662
- 14 Shatz A. Management of recurrent sinus disease in children with cystic fibrosis: a combined approach. *Otolaryngol Head Neck Surg* 2006;135(2):248–252
- 15 Simmen D, Jones NS. *Manual of endoscopic sinus surgery and its extended applications*. New York: Thieme; 2005:pp. 50–51