



OPEN ACCESS

CASE REPORT

Dying art of a history and physical: pulsatile tinnitus

Jonathan Lee,^{1,2} Zoltan Fekete³¹Neurology, Orange Regional Medical Center, Middletown, New York, USA²D.O. Program, Touro College of Osteopathic Medicine - Middletown, Middletown, NY, United States³Crystal Run Healthcare, Rock Hill, New York, USA**Correspondence to**Mr. Jonathan Lee,
jlee35@student.touro.edu

Accepted 10 November 2017

SUMMARY

Modern medicine often leaves the history and physical by the wayside. Physicians instead skip directly to diagnostic modalities like MRI and angiography. In this case report, we discuss a patient who presented with migraine symptoms. Auscultation revealed signs of pulsatile tinnitus. Further imaging concluded that it was secondary to a type I dural arteriovenous fistula. Thanks to a proper and thorough history and physical, the patient was streamlined into an accurate and efficient work-up leading to symptomatic relief and quality of life improvement. Imaging is a powerful adjunctive technique in modern medicine, but physicians must not rely on machines to diagnose their patients. If this trend continues, it will have a tremendous negative impact on the cost and calibre of healthcare. Our hope is that this case will spread awareness in the medical community, urging physicians to use the lost art of a history and physical.

BACKGROUND

Our opinion is that it would interest the readership of *BMJ Case Reports* because it describes an important clinical lesson regarding performing a thorough history and physical before using adjunctive radiographic modalities. Examining the patient is the basis of medicine and should not be forgotten. It is an elementary but significant fact that has long-lasting implications. Our hope is that by urging those in medicine to continue to utilising skills such as auscultation, it will decrease patient costs and improve the quality of healthcare.

CASE PRESENTATION

The patient is a 52 year-old Caucasian woman who presented to the neurology clinic due to worsening migraine symptoms and because she was 'hearing sounds'. The migraines have been recurring for the past 2 months. The migraines are lateralised to her right retroaural region and have a pulsatile nature. She hears a 'whooshing sound' which rises and falls in concordance with her pulse. Motrin temporarily gives temporary relief of her symptoms but they always return. She denies changes in vision, hearing, smell, taste, facial weakness, dysphagia, weakness, paresthesias and numbness. She has no medical or surgical history. She has no contributory family history. She denies use of tobacco or alcohol. She is taking no other medications other than Motrin orally 200 mg pro re nata (PRN). She states she has seen several other providers who were not able to alleviate her symptoms.

On physical exam, the patient has tenderness to palpation in her right retroaural region. During auscultation, there is a distinct bruit on her right retroaural region, which rises and falls according to her pulse. There is no bruit on her left retroaural region. The rest of her neurological exam was benign. The patient was alert and oriented 3 ×. cranial nerves (CN) I–XII were intact. No carotid bruits were auscultated. Upper and lower extremity reflexes were 2/3. Upper and lower extremities pulses were 2/4. Muscle strength is 5/5.

INVESTIGATIONS

The patient was sent to Westchester Medical Center for a same-day magnetic resonance angiogram and venogram (MRA and MRV) of her head using two-dimensional (2D) and three-dimensional (3D) time-of-flight technique without contrast (Figure 1). Imaging demonstrated a type I dural arteriovenous fistula localised mostly over the right transverse sinus.

DIFFERENTIAL DIAGNOSIS

Pulsatile tinnitus secondary to the following:

1. Most likely: steno-occlusive arterial disease, arteriovenous (AV) shunts (fistulae, vascularised tumours, inflammation), normal variants of veins and sinuses, and intracranial hypertension.
2. Unlikely: aneurysms, semicircular duct dehiscence and normal variants of arteries.^{1,2}

TREATMENT

The patient was counselled on two options:

1. Observation with repeat catheter angiography in 6–9 months, with Motrin for temporary episodic relief.
2. Endovascular treatment.

OUTCOME AND FOLLOW-UP

After being counselled on the risks, benefits and alternatives, the patient elected to receive endovascular treatment. There were no complications. The patient has stated that she has had full relief of her symptoms with the procedure.

DISCUSSION

This case is a prime example of the importance of using physical diagnosis before any adjunctive techniques. The patient had seen several doctors before and none could reason out her condition. However, after auscultating her right retroaural region, the bruit was extremely distinct and pathognomonic for pulsatile tinnitus, mostly likely secondary to some sort of anatomical vascular issue. So clear, in



CrossMark

To cite: Lee J, Fekete Z. *BMJ Case Rep* Published Online First: [please include Day Month Year]. doi:10.1136/bcr-2017-221697

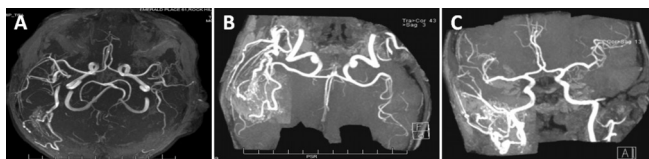


Figure 1 (A) Time of flight (TOF) three-dimensional, multislab, MRI time resolved angiography (TRA) of the brain without contrast. (B) Anterior circulation, tumble view without contrast. (C) Anterior circulation, rotation view without contrast.

fact, that even a medical student could discern something was amiss. This further emphasises the importance of utilising basic techniques such as auscultation, palpation and others. After performing a thorough physical exam, we reasoned that additional techniques such as MRI, MRA and MRV were necessary to further the diagnosis so the patient could receive the best care possible.

Before metals and electronics, a physician's diagnosis was based solely on history and what they could feel with their hands. According to Roguin,³ centuries later the stethoscope was invented by Laënnec in 1816. Since then, it has become one of the hallmark symbols of medicine. Every physician is taught to use this instrument, and as a result needs to actually examine the patient himself or herself. Since then, there has been an explosion of technological development in the field of medicine. All of it is extremely beneficial, but it has driven physicians to rely on what technology perceives rather than their own senses.

For instance, the MRI. Since its invention, it has rapidly risen to become a staple imaging and diagnostic technique in many fields of medicine. The beginnings of MRI stemmed from Bloch and Purcell, the winners of the 1952 Nobel Prize in Physics,⁴ for their novel methods of using nuclear magnetic resonance (NMR) spectroscopy for precision measurements. Later on, Damadian⁵ tweaked the concept on NMR after scanning tumour tissue, noticed it had a prolonged T1 relaxation time compared with normal tissue. Damadian *et al*⁶ would then go on to perform the first full body scan using magnetic resonance technology in 1977. A few years later, the MRI would be further improved both in practicality and functionality. Lauterbur⁷ was able to combine a series of rotating one-dimensional NMR images into one 2D or 3D image. Ordidge *et al*^{8,9} tempered the technique by inventing 'slice selection' and developed the MRI protocol called 'echo-planar imaging', making functional MRI more feasible.

Another popular imaging modality is angiography. Early trailblazers in angiography¹⁰ focused on developing fluoroscopy and radiography techniques while studying cardiac diseases from 1899 to 1902. Tan and Yip cite Monize¹¹ as the first to use the technique in 1927 for contrasted X-ray cerebral angiography to diagnose nervous diseases such as tumours and arteriovenous malformations. From there, angiography further evolved through the efforts of Forsmann¹² in 1929 with his attempts at cardiac catheterisation and angiocardiology. These advances paved the way for many clinicians to continue honing the technique during the 1930s and 1940s. In 1941, Cournand¹³ demonstrated that cardiac catheterisation was safe to use on the human body. As the years rolled on, more advances such as rapid filming, demonstration of coronary anatomy and balloon angioplasty came into being.

With the inception of both the MRI and angiography, physicians began to use these techniques more and more, eventually merging both into MRA and MRV.^{14,15} However, there

were two large issues that made MRA and MRV techniques suboptimal procedures in many situations: the inability to produce simultaneous bilateral images and the long time it took to produce images. Then, during 2003 and then 2004, the advent of parallel imaging coupled with new pulse sequences¹⁶ reduced the total time of imaging by one-third to half the original time.

In the present, due to their wide availability, modern physicians oftentimes overuse imaging techniques. Hawasli *et al*¹⁷ state that headaches consist of 1.5% of all chief complaints in a primary care setting. Irrespective of many neuroimaging guidelines, expenditures for neuroimaging of headaches and migraines in the USA reached nearly US\$1.2 billion. This exorbitant cost is attributed to the practice of 'defensive medicine', which results in neuroimaging solely done to reduce malpractice liability and medical errors. It has been shown that discovery of certain diseases earlier, such as brain tumours, improves outcomes. Moreover, with certain criteria such as the Choosing Wisely guidelines, false-negatives have been shown to be anywhere from 3% to 7%. However, even taking these facts into account, this is not an excuse for performing a haphazard history and physical, and skip directly to neuroimaging.

There is no universally accepted guideline for neuroimaging, especially for headaches. A physician must exercise excellent clinical judgement in order to reduce the amount of unnecessary neuroimaging.

MRIs are notoriously overused. They do not use ionising radiation, which decreases risks of stochastic effects, have better soft tissue resolution, and the contrast agents have less risk of allergic reactions when compared with CTs.^{18,19}

In the case above, the positive finding of pulsatile tinnitus was an indication for use of MRI/MRA rather than starting with CT angiography. Moreover, the neurovascular surgeon requested an MRI/MRA, so regardless of the findings on CT the former would be needed regardless. Given the patient's physical exam findings and rather than subjecting the patient to two procedures, we decided to expedite the process by skipping the CT.

It is important to remember that patient disposition ought to be contingent on performing a comprehensive exam. Cultivating a conscientious style of medicine would lead towards improved clinical judgement and yield less expenditures and better quality of healthcare overall.

Learning points

- ▶ A thorough history and physical is a necessity and should not be taken lightly.
- ▶ Imaging modalities are purely adjunctive; they should not dictate treatment until after a thorough history and physical.
- ▶ Decreasing unnecessary imaging will decrease both institutional and patient costs while concurrently increasing quality of healthcare.

Contributors JL conceived of the study, initiated the study design, performed the necessary data collection and research, and drafted the article. ZF helped with interpretation of the research and critically revised the article. This work has not been published and is not under consideration elsewhere nor does it duplicate other published work. We have had no previous submission of this manuscript to BMJ.

Competing interests None declared.

Patient consent Obtained.

Provenance and peer review Not commissioned; externally peer reviewed.

Open Access This is an Open Access article distributed in accordance with the Creative Commons Attribution Non Commercial (CC BY-NC 4.0) license, which permits others to distribute, remix, adapt, build upon this work non-commercially, and license their derivative works on different terms, provided the original work is properly cited and the use is non-commercial. See: <http://creativecommons.org/licenses/by-nc/4.0/>

© BMJ Publishing Group Ltd (unless otherwise stated in the text of the article) 2017. All rights reserved. No commercial use is permitted unless otherwise expressly granted.

REFERENCES

- 1 Pegge SAH, Steens SCA, Kunst HPM, *et al*. Pulsatile tinnitus: differential diagnosis and radiological work-up. *Curr Radiol Rep* 2017;5:5.
- 2 Hofmann E, Behr R, Neumann-Haefelin T, *et al*. Pulsatile tinnitus: imaging and differential diagnosis. *Dtsch Arztebl Int* 2013;110:451–8.
- 3 Roguin A. Rene Theophile Hyacinthe Laënnec (1781-1826): the man behind the stethoscope. *Clin Med Res* 2006;4:230–5.
- 4 The Nobel Prize in Physics 1952 Nobelprize.org. Nobel Media AB 2017; 2014 http://www.nobelprize.org/nobel_prizes/physics/laureates/1952
- 5 Damadian R. Tumor detection by nuclear magnetic resonance. *Science* 1971;171:1151–3.
- 6 Damadian R, Goldsmith M, Minkoff L. NMR in cancer: XVI. FONAR image of the live human body. *Physiol Chem Phys* 1977;9:97–100, 108.
- 7 Lauterbur P. MRI – a new way of seeing. *Nature* 1973;242:190–1.
- 8 Ordidge RJ, Mansfield P, Coupland RE. Rapid biomedical imaging by NMR. *Br J Radiol* 1981;54:850–5.
- 9 Ordidge RJ, Mansfield P, Doyle M, *et al*. Real time movie images by NMR. *Br J Radiol* 1982;55:729–33.
- 10 Wilms G, Baert AL. The history of angiography. *J Belge Radiol* 1995;78:299–302.
- 11 Tan SY, Yip A. Antonio egas monize (1874 – 1955): lobotomy pioneer and nobel laureate. *Singapore Medical Journal*;55:175–6.
- 12 Meyer JA. Werner Forssmann and catheterization of the heart, 1929. *Ann Thorac Surg* 1990;49:497–9.
- 13 André F. Cournand – Facts. Nobelprize.org. Nobel Media AB 2014. 2017. http://www.nobelprize.org/nobel_prizes/medicine/laureates/1956/cournand-facts.html
- 14 Muhs BE, Verhagen HJ, Huddle MG, *et al*. Theory, technique, and practice of magnetic resonance angiography. *Vascular* 2007;15:376–83.
- 15 Glockner JK, Lee CU. Magnetic resonance venography. *Appl Radiol* 2010;39:36–42.
- 16 Chevrier R. How MRA finally replaced conventional angiography in assessing peripheral vascular disease, part 1: an expert interview with glenn krinsky, MD. *Medscape* 2016. <http://www.medscape.com/viewarticle/529337>
- 17 Hawasli AH, Chicoine MR, Dacey RG. Choosing Wisely: a neurosurgical perspective on neuroimaging for headaches. *Neurosurgery* 2015;76:1–6.
- 18 Hess CP, Purcell D. Exploring the brain: is CT or MRI better for brain imaging? *UCSF Department of Radiology & Biomedical Imaging* 2012;11. <https://radiology.ucsf.edu/blog/neuroradiology/exploring-the-brain-is-ct-or-mri-better-for-brain-imaging>
- 19 Lin EC. Radiation risk from medical imaging. *Mayo Clin Proc* 2010;85:1142–6.

Copyright 2017 BMJ Publishing Group. All rights reserved. For permission to reuse any of this content visit <http://group.bmj.com/group/rights-licensing/permissions>.

BMJ Case Report Fellows may re-use this article for personal use and teaching without any further permission.

Become a Fellow of BMJ Case Reports today and you can:

- ▶ Submit as many cases as you like
- ▶ Enjoy fast sympathetic peer review and rapid publication of accepted articles
- ▶ Access all the published articles
- ▶ Re-use any of the published material for personal use and teaching without further permission

For information on Institutional Fellowships contact consortiasales@bmjgroup.com

Visit casereports.bmj.com for more articles like this and to become a Fellow