



Case report

Endoscopic foreign body retrieval from the caecum – A case report and push for intervention guidelines

Sharie Apikotoa^{*}, Helen Ballal, Ruwan Wijesuriya

St John of God Hospital, Midland, 1 Clayton Street, Midland 6056, Western Australia, Australia

ARTICLE INFO

Keywords:
Colonoscopy
Foreign body
Case report

ABSTRACT

Introduction and importance: Endoscopic foreign body retrieval in the upper gastrointestinal tract is well established, however indications for endoscopy for retained foreign bodies in the lower gastrointestinal tract and specifically the right colon is still being navigated [3]. A PubMed and Google Scholar search discovered a variety of case reports detailing various methods and indications for endoscopic retrieval of right sided colonic foreign bodies. This case report endeavors to supplement the literature so that guidelines can one day be established for colonoscopic retrieval of right-sided foreign bodies.

Case presentation: 36-year-old male prisoner swallowed 6.5 cm nail clippers with a long-standing history of intentional foreign body ingestion (FBI) including multiple laparotomies for foreign body retrievals. Computerized tomography (CT) was used initially to confirm the position of the nail clippers. After almost two weeks of failure of the foreign body (FB) to move beyond the caecum as demonstrated on plain abdominal X-rays, the patient had a colonoscopy with successful retrieval of the FB.

Clinical discussion: This case report hopes to encourage the consideration of colonoscopy for retrieval of right sided colonic foreign bodies that have failed to pass on their own and where an operation may come with increased risk (multiple laparotomies, multiple comorbidities, and higher anaesthetic risk for a general anaesthetic). Colonoscopy/endoscopy still has inherent risk and this patient did have an episode of temporary laryngospasm that required intubation and monitoring in the intensive care unit post operatively. Despite this the patient recovered and was discharged day one post procedure without further complication. The case report has been reported in line with the SCARE 2020 criteria (Agha et al., 2020 [2]).

Conclusion: Indications for consideration of endoscopic retrieval of foreign bodies in the right colon have not been entirely detailed as endoscopy is for upper gastrointestinal foreign bodies. This case report documents the indications for endoscopy in the clinical context of a recurrent FBI and a history of multiple laparotomies with failure of the FB to move beyond the caecum.

1. Introduction

Foreign body ingestion (FBI) is a common presentation in the emergency department and mostly occurs in the pediatric population. In the majority of cases, most of these foreign bodies (FB) will pass through the gastrointestinal tract without any complications. However, 10–20% of patients who ingest foreign bodies will require intervention by means of endoscopy and up to 1% of patients requiring surgery [3]. This is because retained ingested foreign bodies can precipitate perforation, bleeding, ulceration, or obstruction and therefore interventions in these higher risk groups are required [4]. If intervention is required for FBI, commonly gastroscopy is performed or flexible sigmoidoscopy. The

literature has not commonly documented right-sided colonic endoscopic retrievals of FBI as much as left sided FB, perhaps due to the need for full bowel preparation for right sided colonic foreign bodies and the increased risk of bowel perforation.

2. Case presentation

A 36-year-old male prisoner had intentionally swallowed 6.5 cm nail clippers and had presented to a peripheral hospital. He had reported some right upper quadrant abdominal pain. Bowels were opened, although reportedly more constipated, no nausea or vomiting and otherwise was well. The patient had multiple comorbidities including

^{*} Corresponding author.

E-mail address: Sharie.apikotoa@sjog.org.au (S. Apikotoa).

<https://doi.org/10.1016/j.ijscr.2022.106755>

Received 27 August 2021; Received in revised form 31 December 2021; Accepted 1 January 2022

Available online 4 January 2022

2210-2612/© 2022 Published by Elsevier Ltd on behalf of IJS Publishing Group Ltd. This is an open access article under the CC BY-NC-ND license

(<http://creativecommons.org/licenses/by-nc-nd/4.0/>).

schizophrenia that had been well controlled, intellectual impairment, chronic kidney disease (stage 3), hypertension, hypercholesterolemia, laparoscopic cholecystectomy and two previous laparotomies within two years for FBI. The patient was also a smoker and an ex- intravenous drug user. On examination, the patient was hemodynamically stable, afebrile and had a soft abdomen with mild right upper quadrant tenderness. Initial X-ray was unable to determine the exact location of the foreign body (Fig. 1).

On presentation, there was eventual confirmation of the nail clippers in D2/D3 of the duodenum on computerized tomography (CT) of the abdomen and pelvis (Fig. 2). Gastroscopy was unsuccessful as the objects had advanced through the gastrointestinal tract, eventually progressing to the caecum, demonstrated on X-rays of the abdomen. Assuming from this point they would likely pass, the patient was discharged on day five of that admission. Six days later he re-presented with right upper quadrant pain. Repeat imaging confirmed the nail clippers remained in the same position with no complications of FBI (Fig. 3). Given his previous laparotomies and recurrent FBI, a decision was made to give bowel preparation and endoscopically retrieve the nail clippers.

On day 14 after the patient had intentionally ingested the FB and after 2 days of bowel preparation an AXR again confirmed that the objects were still contained in the caecum despite bowel preparation. The patient proceeded to have a colonoscopy, which was performed by a gastroenterology consultant. The colonoscope was inserted into the caecum with visualisation of the ileo-caecal valve, appendiceal orifice and tri-radiate caecal folds confirming caecal intubation. Nail clippers were lodged in the caecum in pieces (Figs. 4 & 5). Each foreign body was retrieved individually using a snare (Fig. 6). There was a minor mucosal injury, but no perforation seen and the remainder of colon normal. Unfortunately, after the procedure, the patient had laryngospasm requiring intubation. He was taken to ICU post procedure for monitoring and extubation that was performed successfully with no ongoing issues. An X-ray performed on day 1 post procedure confirmed complete retrieval of FB (Fig. 7). He was discharged day 1 post procedure.

The patient did not require any ongoing follow up, however 3 months later he re-presented to hospital with intentional FBI again, this time able to be retrieved with gastroscopy. Case report written in line with the SCARE criteria [2].

3. Discussion

Foreign body ingestion is a common reason for presentation to the emergency department particularly in a pediatric cohort. Risk factors for

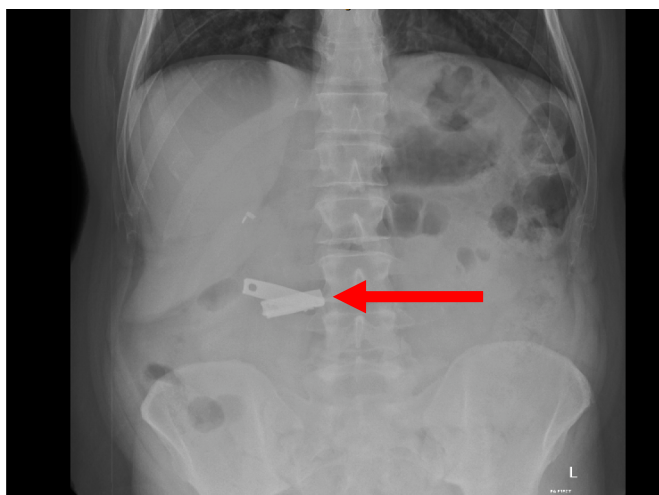


Fig. 1. Day of ingestion abdominal X-ray (AXR): Nail clippers seen in D2/D3 of duodenum (red arrow).

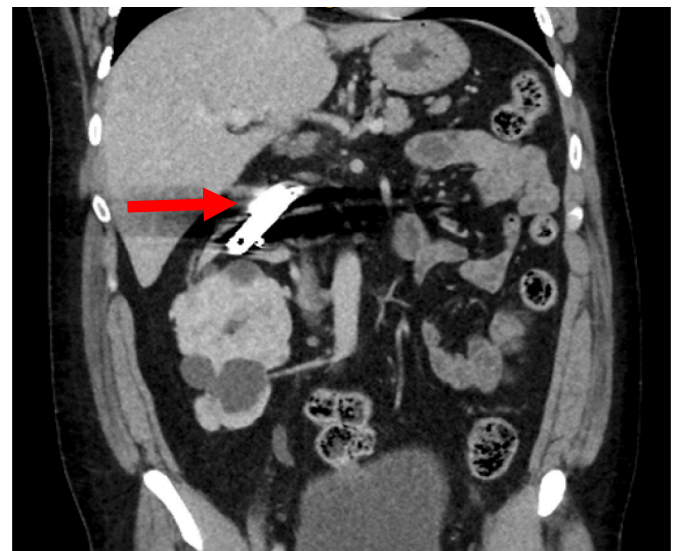


Fig. 2. Day of ingestion CT abdomen/pelvis (CTAP) coronal slice: Nail clippers seen in D2/D3 of duodenum (red arrow).

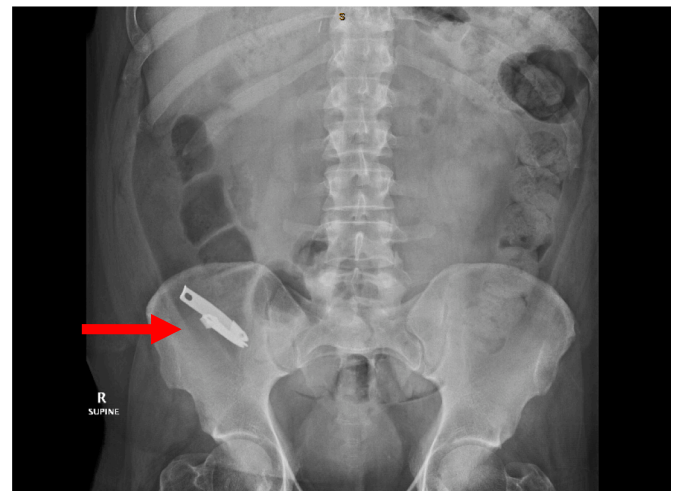


Fig. 3. Day 11 post ingestion of FBI AXR: nail clippers seen in caecum.

FBI in adult populations include developmental delay, alcohol intoxication, psychiatric illness, and incarceration [6]. Approximately 80% of foreign bodies pass spontaneously and do not require intervention, with less than 1% of all cases necessitating surgical intervention [3].

It is important to note that once a foreign body is in the stomach, the majority will pass within 4–6 days [3]. Conservative management has been proven to be effective in the management of many asymptomatic gastric foreign bodies [1]. Having said that, there are clear guidelines for the indications of interventions of FBI when the object lies in the gastrointestinal tract proximal to the ligament of Treitz [3].

When sharp objects have migrated beyond the ligament of Treitz the basis of intervention is not always entirely straightforward in patients with no obvious complications of FBI. Specifically, the role for use of colonoscopy in impacted caecal foreign bodies is still being navigated. Typically, surgical intervention is endorsed if the object has not passed after 3–4 days and the FB is well beyond the duodenum [3].

On a retrospective study of 542 cases, it was found that 4.8% of patients required surgical intervention for FBI. 15.4% of which were for sharp object perforation and 53.8% for ileocaecal impaction [7]. The majority of surgical interventions could have potentially been avoided if

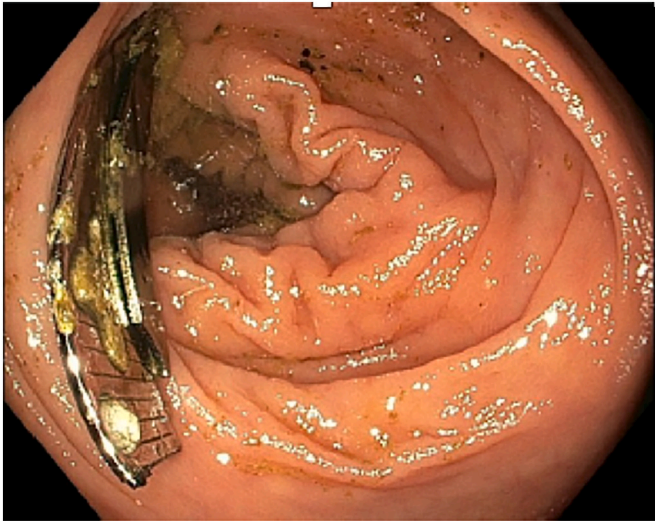


Fig. 4. Caecum with FB lodged.

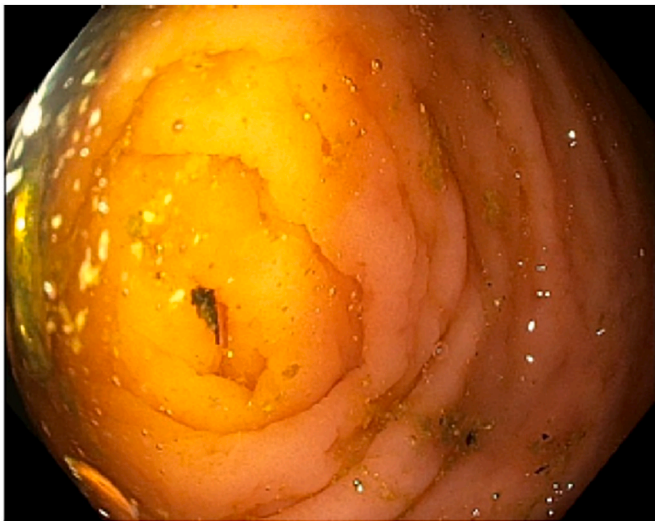

Fig. 5. Caecum post retrieval of FB.




Fig. 6. Nail clippers (4 pieces) retrieved.

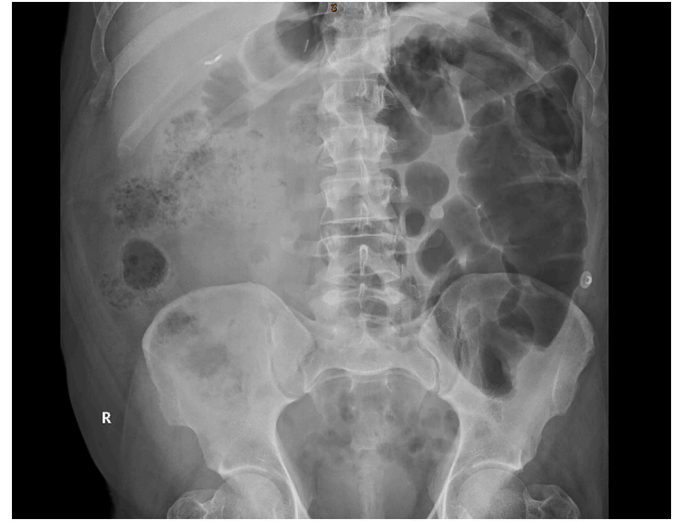

Fig. 7. Day 15 post FBI AXR (post retrieval).

endoscopic methods had been used and were successful. In this specific case presentation, there were no overt complications of FBI and therefore no straightforward need for surgical intervention. We had opted for endoscopic retrieval given the patients prior surgical history and recurrent intentional FBI.

The most common locations in the large intestine that tends to show a tendency for objects to get stuck are the ileocaecal valve, appendiceal lumen, caecal-ascending colon junction, colonic flexures and haustrae [9]. Right-side colonic endoscopic retrieval of FB is uncommon and indications for its use are not entirely well documented although a few case reports have documented various indications and instruments used. One case report described retrieval of a 4.4 cm pin from the caecum with good effect using the hot biopsy forceps ensuring the pin was withdrawn into the hood [8]. Within that same case report was another case of a 3.4 cm glass shard removed using a Roth net retriever. Another case report noted 2 nails and a bolt (<3 cm) that failed to progress past the hepatic flexure after a period of two weeks post ingestion [9]. In this scenario they used a polypectomy snare and a transparent hood to successfully retrieve these objects without complication. A retrospective study conducted at a level 1 trauma centre (with an acute surgical unit on site) on foreign body presentations revealed that patients were at higher risk of requiring surgery with larger objects 6 ± 3 cm, than those who had endoscopy 3 ± 2 cm [10]. This is supported by the fact that majority of the published case reports describe objects <5 cm and that larger objects are more likely to cause immediate FBI complications. In this case report, not only did this object exceed 6 cm but did not cause complications or progress beyond the right colon. Colonoscopy was used by a skilled consultant gastroenterologist and as a result the patient avoided another laparotomy.

In instances where sharp foreign bodies have made it to the colon, have not caused immediate FBI complications and whereby there has been failure to progress on serial imaging, high surgical or anaesthetic risk -colonoscopy should be encouraged.

4. Conclusion

There is a current lack of evidence-based guidelines with the endoscopic retrieval of right sided colonic impacted foreign bodies. We consider endoscopy to be a more favourable option compared to surgery when intervention is required. Although not without its own risks, it is less invasive and should be considered in these or similar circumstances.

Consent

Written informed consent was obtained from the patient's public guardian for publication of this case report and accompanying images. A copy of the written consent is available for review by the Editor-in-Chief of this journal on request.

Provenance and peer review

Not commissioned, externally peer-reviewed.

Ethical approval

N/A.

Funding

None.

Guarantor

Dr Sharie Apikotoa
Dr Helen Ballal
A/Prof Wijesuriya.

Research registration number

N/A.

CRediT authorship contribution statement

Dr Sharie Apikotoa – Interpretation, writing the paper.

Dr Helen Ballal – Treating consultant

A/Prof Ruwan Wijesuriya – Advisor.

Declaration of competing interest

None.

References

- [1] P. Ambe, S. Weber, M. Schauer, W. Knoefel, Swallowed Foreign Bodies in Adults, *Deutsches Aertzblatt Online*, 2012.
- [2] R.A. Agha, T. Franchi, C. Sohrabi, G. Mathew, for the SCARE Group, The SCARE 2020 guideline: updating consensus Surgical CASE REport (SCARE) guidelines, *Int. J. Surg.* 84 (2020) 226–230.
- [3] M. Bekkerman, A. Sachdev, J. Andrade, Y. Twersky, S. Iqbal, Endoscopic management of foreign bodies in the gastrointestinal tract: a review of the literature, *Gastroenterol. Res. Pract.* 2016 (2016) 1–6.
- [4] B. Erbil, Emergency admissions due to swallowed foreign bodies in adults, *World J. Gastroenterol.* 19 (38) (2013) 6447.
- [6] R. Palta, A. Sahota, A. Bemarki, P. Salama, N. Simpson, L. Laine, Foreign-body ingestion: characteristics and outcomes in a lower socioeconomic population with predominantly intentional ingestion, *Gastrointest. Endosc.* 69 (3) (2009) 426–433, doi.
- [7] N. Velitchkov, G. Grigorov, J. Losanoff, K. Kjossev, Ingested foreign bodies of the gastrointestinal tract: retrospective analysis of 542 cases, *World J. Surg.* 20 (8) (1996) 1001–1005, <https://doi.org/10.1007/s00268990015210.1016/j.gie.2008.05.072>.
- [8] M. Hershman, Pointing towards colonoscopy: sharp foreign body removal via colonoscopy, *Ann. Gastroenterol.* (2016), <https://doi.org/10.20524/aog.2016.0116>.
- [9] H. Vachhani, A. Fialho, A. Fialho, A. Shuja, M. Malespin, S. De Melo, Foreign body removal from the colon: a successful approach, *Am. J. Gastroenterol.* 113 (Supplement) (2018) S1083–S1084, <https://doi.org/10.14309/00000434-201810001-01909>.
- [10] K. Zarny, J. Davis, E. Ament, R. Dirks, J. Garry, This too shall pass, *J. Trauma Acute Care Surg.* 82 (1) (2017) 150–155, <https://doi.org/10.1097/ta.0000000000001265>.