

A Unique Conglomeration of Variations in the Celiac, Hepatic, and Superior Mesenteric Artery: A Clinico-Embryological Perspective

Abstract

This paper highlights a rare variation in the branching pattern of the celiac trunk and superior mesenteric arteries, as observed during cadaveric dissection. It was found that the celiac trunk gave origin to the following: (1) left inferior phrenic artery, (2) hepatogastric trunk which gave three branches: the left gastric artery, esophageal branch, and a left hepatic artery, (3) splenic artery, and (4) common hepatic artery. The superior mesenteric artery gave origin to the right hepatic artery, and the common hepatic artery gave origin to a middle hepatic artery. Such rare variations must be brought to the notice of surgeons and radiologists to prevent any undue complications during any interventional procedures and surgeries.

Keywords: Celiac trunk, hepatic artery, variations

Introduction

A detailed knowledge of the normal anatomy and variations of the major blood vessels of the abdomen is of immense importance for surgeons and interventional radiologists. We live in an era of laparoscopic surgeries where the operative field is quite restricted, thereby increasing the chances of vascular injuries if these variations are overlooked.

The abdominal vasculature mainly comprises vessels arising from three ventral branches of the abdominal aorta, namely, the celiac, superior mesenteric, and inferior mesenteric arteries. The celiac trunk is the artery of the foregut. Studies have revealed that the origin of the celiac trunk can be at the level of twelfth thoracic vertebra or in between T12 and L1 vertebra or in between T11 and T12 vertebra.^[1,2] It supplies the gastrointestinal tract from the distal esophagus to the mid-part of the second part of the duodenum. It also supplies the associated adnexa such as the liver, gallbladder, biliary tree, dorsal pancreas, and greater and lesser omentum. Classically, the celiac artery divides into three branches the left gastric, splenic, and the common hepatic arteries. The common hepatic artery gives the gastroduodenal artery and thereafter continues as the

hepatic artery proper. The hepatic artery, at the porta hepatis, divides into the right and left hepatic arteries that supply the liver. Usually, the right hepatic artery supplies segment V, VI, VII, and VIII, whereas segment II, III, and IV are supplied by the left branch. Segment I is supplied by both the right and left hepatic arteries. If a part of the liver is receiving supply from the normal artery as well as an additional artery, then the additional one is named “accessory artery.” When a hepatic artery does not originate from the standard source and is the only supply for a part of the liver, it is termed “replaced artery.”

The superior mesenteric artery arises from the abdominal aorta at the level of lower border of the body of the first lumbar vertebra. It gives the ileocolic, right colic, and middle colic arteries to supply the derivatives of the midgut from the duodenum till the proximal two-thirds of the transverse colon.

Case Report

During routine cadaveric dissection for teaching undergraduate students, it was found that in a 52-year-old male cadaver, the celiac artery originated as a ventral branch of the abdominal aorta. The left inferior phrenic artery arose from the main trunk of the celiac artery at a distance of

**Anita Mahajan,
Swati Tiwari,
Sabita Mishra**

*Department of Anatomy,
Maulana Azad Medical College,
New Delhi, India*

Received: 23 November, 2017.
Accepted: 07 June, 2018.

Address for correspondence:

*Dr. Swati Tiwari,
2403, Sector – 9,
Faridabad - 121 006.
Haryana, India.
E-mail: doctorswatiwari@
gmail.com*

This is an open access journal, and articles are distributed under the terms of the Creative Commons Attribution-NonCommercial-ShareAlike 4.0 License, which allows others to remix, tweak, and build upon the work non-commercially, as long as appropriate credit is given and the new creations are licensed under the identical terms.

For reprints contact: reprints@medknow.com

How to cite this article: Mahajan A, Tiwari S, Mishra S. A unique conglomeration of variations in the celiac, hepatic, and superior mesenteric artery: A clinico-embryological perspective. *Int J App Basic Med Res* 2018;8:256-8.

Access this article online

Website:

www.ijabmr.org

DOI:

10.4103/ijabmr.IJABMR_395_17

Quick Response Code:



2 cm from the origin of the celiac trunk. It went on to supply the left dome of the diaphragm. The right inferior phrenic artery had a normal origin from the abdominal aorta, and it followed its usual course. The celiac artery then gave a hepatogastric trunk at a distance of 2.5 cm from its origin. The hepatogastric trunk gave three branches: the left gastric artery (LGA) at a distance of 3 cm from the origin, esophageal branch at a distance of 4 cm from the origin, and thereafter it continued as the left hepatic artery. Further, from the celiac trunk arose the splenic artery and a common hepatic artery. The common hepatic artery trifurcated into three terminal branches: a middle hepatic artery, the right gastric artery, and the gastroduodenal artery [Figure 1]. The gastroduodenal artery traversed behind the first part of duodenum and bifurcated into the right gastroepiploic artery and the superior pancreaticoduodenal artery.

The right hepatic artery arose as a branch of the superior mesenteric artery at a distance of 3 cm from the origin of superior mesenteric artery. It gave origin to the cystic artery at a distance of 8 cm from its origin. On exploration of the three hepatic arteries, we found that the middle hepatic artery supplied segment I or the caudate lobe, the right hepatic artery supplied segment V, VI, VII, and VIII and the left hepatic artery supplied segment II, III, and IV of the liver. In addition, the middle hepatic artery had a relatively smaller diameter in comparison to the left and right hepatic arteries.

Discussion

There have been several classifications of the celiac trunk based on its branching pattern. According to the classification of the variations in hepatic arteries given by Michels NA, this case showed the double replaced pattern or Type IV pattern. In this type, the left hepatic artery arises from the LGA, and the right hepatic artery is a branch of the superior mesenteric artery.^[1] However, what makes this case unique is that, in addition to these, in this case, there is another artery supplying the liver. This artery arose from the common hepatic artery. We have referred to it as the middle

hepatic artery. Standard textbooks of anatomy state that the segment I of liver receives blood supply from both the right and left hepatic arteries of the liver.^[3] However, we found that the middle hepatic artery was supplying this segment.

The embryological basis for such variations is that during the development, the dorsal aortae give many paired splanchnic branches to supply the developing gut. As the dorsal aortae fuse with each other, these paired branches also fuse forming a ventral longitudinal anastomosis. Normally, the 10th, 13th, and 21st vitelline segments form the celiac, superior, and inferior mesenteric arteries, respectively, and the others disappear.^[4] Variations arise due to the failure of regression of the ventral anastomosis or due to persistence of the vitelline arteries that should normally disappear.^[5] A review of literature reveals that the classic trifurcation pattern of the celiac trunk is seen in 66%–92% of the normal population.^[6-9] Rarely, the complete absence of celiac trunk has also been reported. In such cases, the gastric, hepatic, and splenic arteries arose as direct branches of the abdominal aorta.^[10] A computed tomographic angiographic study found the coeliac trunk to be absent in as high as 4% of the cases.^[11]

A replaced left hepatic artery arising from LGA as in this case, may provide a source for collaterals during obstruction of structures in porta hepatis. In addition, it may get damaged during esophagogastrectomy. This may lead to increased mortality due to hepatic necrosis.^[12] Replaced hepatic arteries as seen in this case, may prove to be a boon for bile duct cancer patients. This is because these arteries are spared from cancer infiltration as they are away from the bile duct, thereby facilitating ease of operation. These variations pose a challenge during various surgeries such as liver transplant in cases of hepatic lobe donation from live donors, chemoembolization of hepatic carcinomas, lymphadenectomy around hepatosplenomesenteric trunk, and surgical repair in blunt abdominal trauma.^[13,14]

Thus, we conclude that aberrations in celiac and hepatic arterial tree are a result of an error during embryological

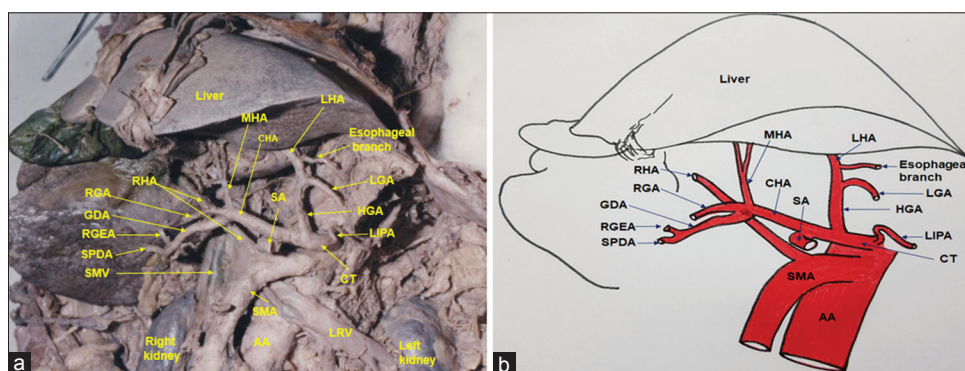


Figure 1: (a) Dissection of the abdomen showing celiac trunk giving left inferior phrenic, hepatogastric, splenic and common hepatic artery. The left hepatic artery is originating from hepatogastric, right hepatic artery (RHA) from the superior mesenteric artery and Middle hepatic artery from the common hepatic artery. (LGA: Left gastric artery; GDA: Gastroduodenal artery; RGEA: Right gastroepiploic artery; SPDA: Superior pancreaticoduodenal artery; RHA: Right hepatic artery; AA: Abdominal aorta; SMV: Superior mesenteric vein; LRV: Left renal vein). (b) A line diagram showing the findings as mentioned in Figure 1a

development. This case report sheds light on one such rare variation and will be of use to the clinicians, researchers, and anatomists. We reiterate that the surgeons and radiologists pay consideration to these variations before planning any procedures.

Acknowledgment

We are thankful to the staff of the dissection hall, Department of Anatomy, Maulana Azad Medical College, for their unrelenting cooperation during this study.

Financial support and sponsorship

Nil.

Conflicts of interest

There are no conflicts of interest.

References

1. Michels NA. Observations on the blood supply of liver and gallbladder. In: Blood Supply and Anatomy of Upper Abdominal Organs, with a Descriptive Atlas. Philadelphia: Lippincott; 1955. p. 139-40.
2. Reuter SR. Accentuation of celiac compression by the median arcuate ligament of the diaphragm during deep expiration. *Radiology* 1971;98:561-4.
3. Peter J, Lodge A. Liver. In: Standring S, editor. *Gray's Anatomy: The Anatomical Basis of Clinical Practice*. 41st ed. New York: Elsevier Limited; 2016. p. 1162-6.
4. Walker TG. Mesenteric vasculature and collateral pathways. *Semin Intervent Radiol* 2009;26:167-74.
5. Tandler J. About the varieties of the celiac artery and their development. *Anat Hefte* 1904;25:473-500.
6. De Cecco CN, Ferrari R, Rengo M, Paolantonio P, Vecchietti F, Laghi A, *et al.* Anatomic variations of the hepatic arteries in 250 patients studied with 64-row CT angiography. *Eur Radiol* 2009;19:2765-70.
7. Venieratos D, Panagouli E, Lolis E, Tsaraklis A, Skandalakis P. A morphometric study of the celiac trunk and review of the literature. *Clin Anat* 2013;26:741-50.
8. Higashi N, Shimada H, Simamura E, Hatta T. Branching patterns of the celiac artery as the hepato-gastro-splenic trunk. *Kaibogaku Zasshi* 2009;84:7-10.
9. Panagouli E, Venieratos D, Lolis E, Skandalakis P. Variations in the anatomy of the celiac trunk: A systematic review and clinical implications. *Ann Anat* 2013;195:501-11.
10. Yi SQ, Terayama H, Naito M, Hirai S, Alimujang S, Yi N, *et al.* Absence of the celiac trunk: Case report and review of the literature. *Clin Anat* 2008;21:283-6.
11. Sehgal G, Srivastava AK, Sharma PK, Kumar N, Singh R, Parihar A, *et al.* Morphometry of the celiac trunk: A multidetector computed tomographic angiographic study. *J Anat Soc India* 2013;62:23-7.
12. Hemming AW, Finley RJ, Evans KG, Nelems B, Fradet G. Esophagogastrectomy and the variant left hepatic artery. *Ann Thorac Surg* 1992;54:166-8.
13. Song SY, Chung JW, Yin YH, Jae HJ, Kim HC, Jeon UB, *et al.* Celiac axis and common hepatic artery variations in 5002 patients: Systematic analysis with spiral CT and DSA. *Radiology* 2010;255:278-88.
14. Munshi IA, Fusco D, Tashjian D, Kirkwood JR, Polga J, Wait RB, *et al.* Occlusion of an aberrant right hepatic artery, originating from the superior mesenteric artery, secondary to blunt trauma. *J Trauma* 2000;48:325-6.